

Case Report

Cutaneous lesions from a blastic plasmacytoid dendritic cell neoplasm: a case report and literature review

Xing Xin¹, Ming Tian², Lifang Huang¹, Gaoxiang Wang¹, Ling Cheng¹, Zhaojun Liu¹, Peiyuan Dong¹, Fankai Meng¹, Hanying Sun¹

¹Department of Hematology, Tongji Hospital, Tongji Medical College, Huazhong University of Science and Technology, Wuhan, Hubei, China; ²Department of Training, Tongji Hospital, Tongji Medical College, Huazhong University of Science and Technology, Wuhan, Hubei, China

Received October 18, 2015; Accepted January 6, 2016; Epub February 15, 2016; Published February 29, 2016

Abstract: Blastic plasmacytoid dendritic cell neoplasm (BPDCN) is a rare and highly aggressive hematological malignancy that is derived from the precursors of plasmacytoid dendritic cells. Although BPDCN typically manifests in the skin, it can also evolve into a leukemic form or be complicated by acute myeloid leukemia, and some cases involve preceding myelodysplastic syndrome. We report the case of a 73-year-old Chinese man who presented with 2-year-old erythematous papules on his prothorax and back. Skin biopsy and immunohistochemistry revealed that the cells exhibited an immature blastic appearance (positive for CD4, CD123, and CD56, and negative for CD2, CD3, and CD20), which indicated a diagnosis of BPDCN. Due to his age, the patient was treated using methylprednisolone (20 mg/m²/day on days 1-7), which was followed by a mini-CHOP regimen (cyclophosphamide, doxorubicin, vincristine, and prednisone). We observed a significant treatment effect, and report this case to describe and discuss our experience with this successful treatment.

Keywords: Blastic plasmacytoid dendritic cell neoplasm (BPDCN), cutaneous lesions, mini-CHOP

Introduction

Blastic plasmacytoid dendritic cell neoplasm (BPDCN) is a rare and aggressive hematological malignancy [1] with a poor prognosis, and is typically observed among elderly patients. It was previously referred to as a natural killer cell leukemia or blastic natural killer lymphoma, and often initially presents as cutaneous lesions that progress to bone marrow involvement (the leukemic phase). The immunophenotype of BPDCN cells is co-expression of CD4, CD56, and CD123 in the absence of lineage-specific markers for myeloid, lymphoid, or natural killer cells [2, 3]. There is no standard treatment, and BPDCN is occasionally treated using classic chemotherapy strategies. However, bone marrow transplantation should be considered as the first therapeutic option, at least in the disseminated stage of the disease. Unfortunately, bone marrow transplantation has obvious shortcomings for older patients, compared to the expected benefits for young

patients [4, 5]. In the present case, we successfully treated an elderly patient with BPDCN using methylprednisolone followed by the mini-CHOP regimen. Therefore, we report and discuss our experience with this patient.

Case report

This study complied with the tenets of the Declaration of Helsinki, and was approved by the ethics committee of Tongji Hospital (Tongji Medical College, Huazhong University of Science and Technology).

A 73-year-old Chinese man presented with 2-year-old erythematous papules on his prothorax and back. He had not received formal treatment, and subsequently developed disseminated cutaneous lesions (which were composed of multiple macules and nodules) all over his body, as well as enlarged inguinal lymph nodes, over a 2-month period. Therefore, the patient visited our hospital for further diagnosis and treatment.

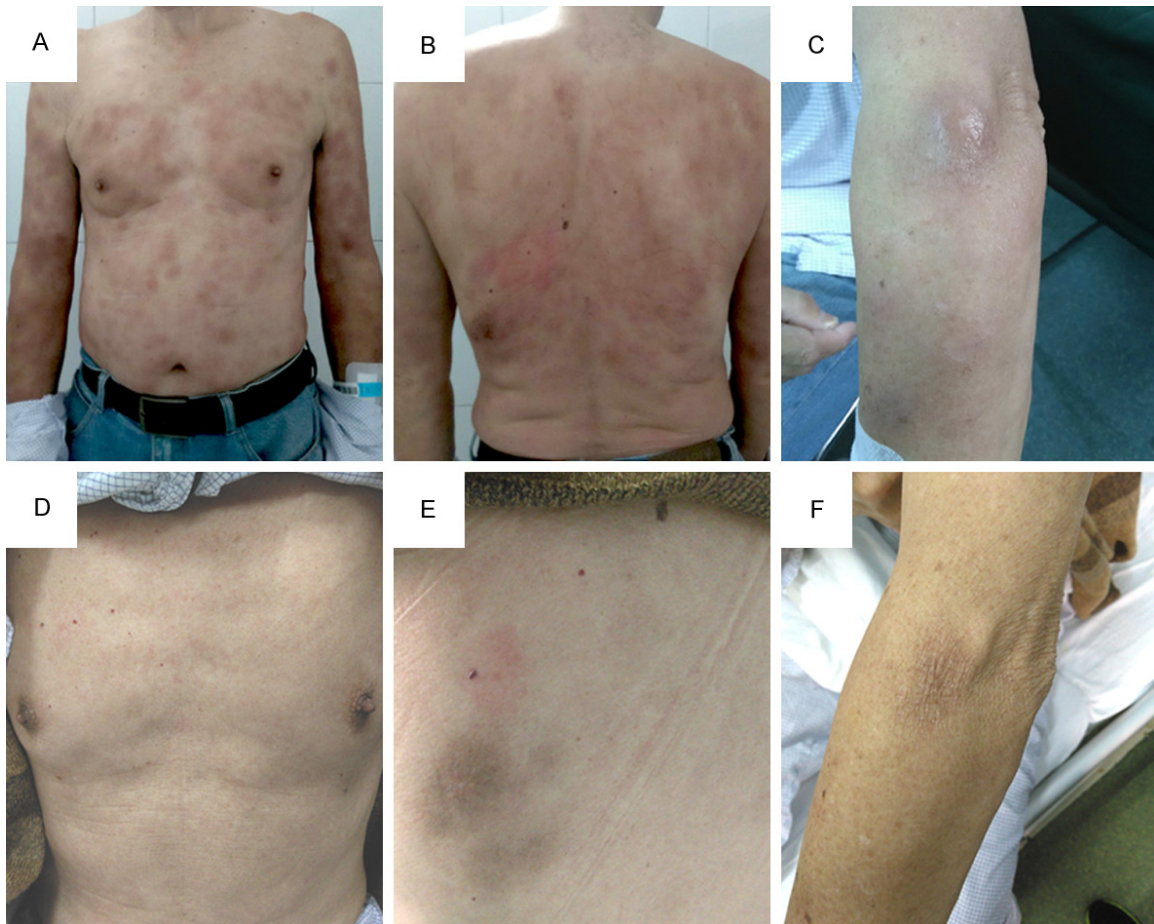


Figure 1. The patient at the initial examination (A-C) and after undergoing mini-CHOP chemotherapy (D-F).

We performed a series of comprehensive examinations, and found that the nodules on his left forearm and back had a diameter of approximately 5 cm (**Figure 1**), and were mildly pruritic and painful. The patient did not have a fever, and the bilateral axillary and inguinal lymph nodes were palpable. A complete blood count revealed a red blood cell count of $2.43 \times 10^{12}/L$, hemoglobin of 108 g/L, and a platelet count of $61 \times 10^9/L$. A blood biochemistry test revealed an estimated glomerular filtration rate of 78.8 mL/min/L, which was below the lower limit of the normal range. We also observed $\beta 2$ -microglobulin and antinuclear antibody levels of 2.78 mg/L and 1:1,000, respectively. Other laboratory tests revealed no obvious abnormalities.

The patient's bone marrow aspirate exhibited hypoplasia, although biopsy subsequently revealed that the hyperplasia was located in different zones and did not include blast cells.

Sanger sequencing revealed no mutations in exon 26 of *DNMT3A*, exon 4 of *IDH1*, exon 4 of *IDH2*, exon 15 of *SF3B1*, exon 1 of *SRSF2*, exon 15 of *EZH*, and exon 2 of *U2AF1*. Furthermore, there were no mutations in the leukemia fusion genes (*E2A/PBX1*, *MLL/AF4*, *BCR/ABL*, *TEL/AML1*, and *SIL/TAL1*). Fluorescence in situ hybridization revealed normal structures and levels for p53, IgH, and c-Myc. Chromosome analysis revealed the 46, XY karyotype [20].

Flow cytometry revealed approximately 0.5% karyocytes, which abnormally expressed CD4, CD56, and CD123 (**Figure 2**). This led us to suspect BPDCN, and we performed a skin biopsy with immunohistochemical analysis to confirm the diagnosis of BPDCN. In addition, ^{18}F -fluorodeoxyglucose positron emission tomography-computed tomography revealed that the skin of the bilateral upper limbs, left back, hypochondriac region, and left buttock was thickened, with a maximum standardized

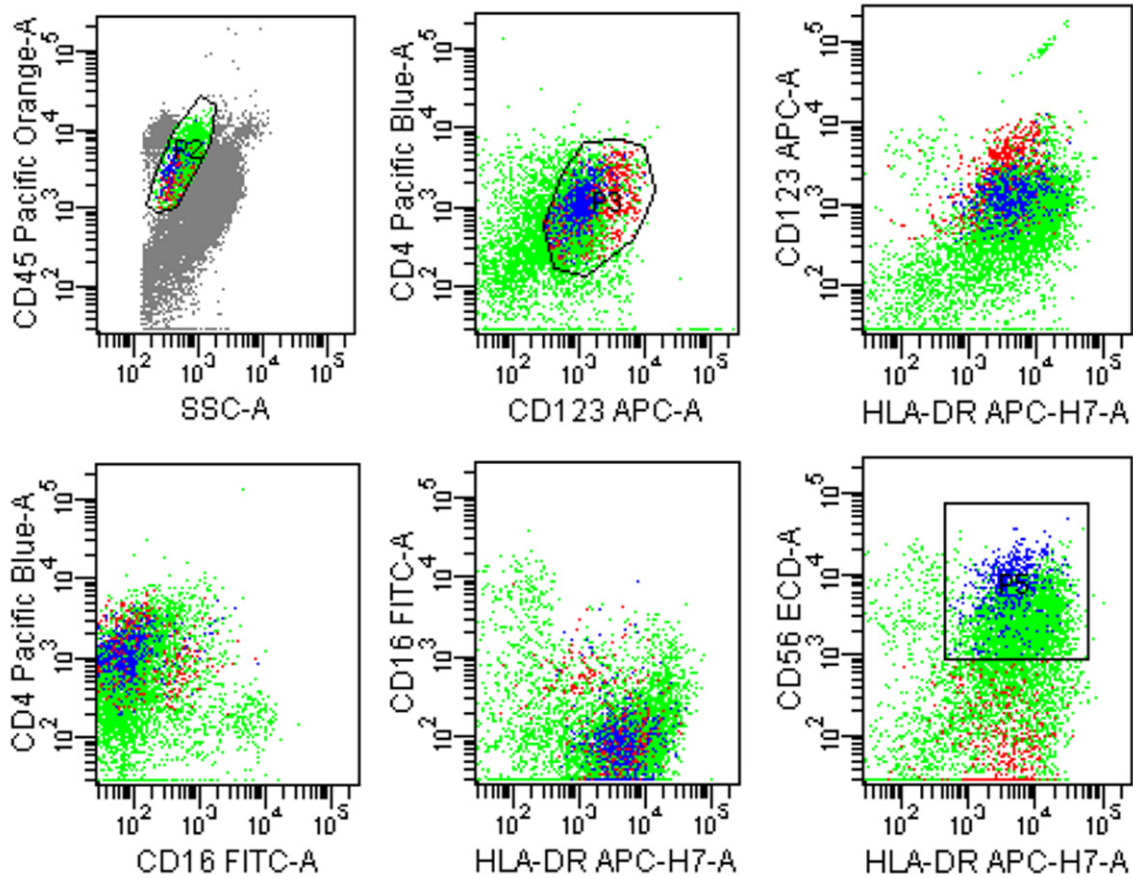


Figure 2. Flow cytometry findings. The cells from the blastic plasmacytoid dendritic cell neoplasm (blue) co-express CD4, CD56, and CD123, and are negative for CD16.

uptake value (maxSUV) of 2.2 (slightly above the normal value). The bone marrow metabolism was uneven, with a maxSUV of 5.9. Based on the patient's clinical features and bone marrow abnormalities, a roentgenologist provided a diagnosis of BPDCN infiltration. The metabolism indexes of the bilateral axillary fossa and inguen, mediastinum, and retro-peritoneum were also elevated, and several lymph nodes were enlarged.

Immunohistochemical staining revealed that the neoplastic cells from the skin biopsy were positive for CD45 (leukocyte common antigen); diffusely positive for CD43, CD56, and Bcl-2; focally positive for CD123 and CD4; and weakly positive for terminal deoxynucleotidyl transferase and T-cell intracellular antigen 1. The neoplastic cells were negative for pan cytokeratin, epithelial membrane antigen, cytokeratin 8 and 18, granzyme B, S-100, human melanoma black, Melan-A, CD68, CD163, CD1a, CD21,

CD23, CD35, langerin, CD20, CD79a, PAX-5, CD2, CD3, CD5, CD8, CD34, CD30, ALK1, CD10, and Bcl-6. The Ki-67 index was approximately 70% (**Figure 3**). Immunohistochemical staining of the bone marrow biopsy revealed that the cells were positive for myeloperoxidase, CD235a, and CD42b; focally positive for CD138; and weakly positive for CD3, CD20, and CD79a.

Based on these findings, we reached a diagnosis of stage IVABPDCN. Due to the patient's age (which contraindicated a bone marrow transplant), we started the patient on methylprednisolone (20 mg/day as an intravenous drip) for 7 days, and noticed that the cutaneous ecchymotic lesions became lighter and the nodules on his left forearm and back became softer. However, we did not observe any obvious changes in his lymph nodes. Therefore, we started the patient on the mini-CHOP regimen. Surprisingly, we observed that the cutaneous

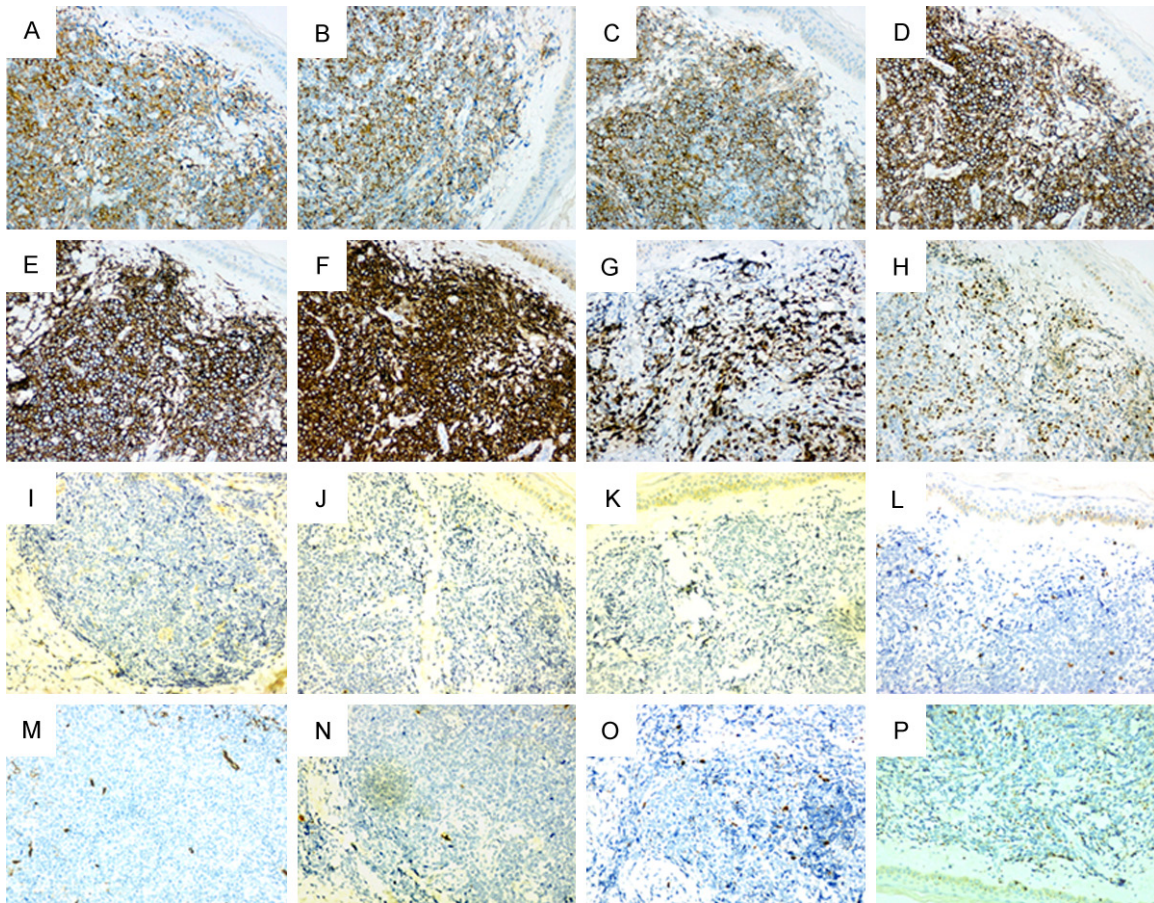


Figure 3. Immunohistochemical findings. The neoplastic cells are positive for CD4 (A), CD56 (B), CD123 (C), CD43 (D), CD45 (E), Bcl-2 (F), Ki-67 (70%; G), and terminal deoxynucleotidyl transferase (H). The neoplastic cells are negative for epithelial membrane antigen, PAX5, cytokeratin 8, CD5, CD34, CD20, CD79a, and CD68 (I-P). Magnification: $\times 200$.

lesions gradually faded away, the nodules disappeared (**Figure 1**), and the lymph nodes exhibited an obvious reduction in size. However, the patient developed serious pancytopenia and post-chemotherapy complications, which included fever, oral ulcers, pneumonia (confirmed via computed tomography), and perianal infection. The patient was treated using antibiotics and other supportive treatment, and computed tomography at 2 weeks revealed that the pneumonia had resolved.

Discussion

BPDCN was initially referred to as blastic natural killer cell lymphoma/leukemia, and is derived from the precursors of dendritic cells. Although BPDCN usually occurs in men who are 60-70 years old, it can also occur in children [6]. The neoplastic cells mainly infiltrate the skin

and lymph nodes, and may involve the bone marrow, which leads to the leukemic phase [7]. The diagnosis is mainly dependent on the patient's clinical symptoms and the immunophenotypes of the blast cells from the skin, lymph nodes, or bone marrow. For example, BPDCN cells are positive for CD4, CD56, and CD123 when tested using immunohistochemistry or flow cytometry [6, 8]. In addition, other immunohistochemical markers can potentially be used to confirm the diagnosis, such as CD43, CD45, CD303, CD2AP, TCL1, CTLA, BDCA-4, SPIB, BCL11A, IRF-8. Furthermore, genetic abnormalities (e.g., in *TET2*, *TP53*, *RB1*, *CDKN1B*, and *CDKN2A*) may play important roles in the occurrence and progression of BPDCN [6, 9, 10]. For example, Cigudosa et al. evaluated several patients with BPDCN using exon sequencing and found mutations in 29 genes, which a mean number of 3.6 muta-

tions per case. *TET2* was the most frequently mutated gene (36%), which was followed by *ASXL1* (32%), *NRAS* (20%), *NPM1* (20%), the *IKAROS* family (20%), and *ZEB2* (16%). Mutations in *DNMT3A*, *U2AF1*, *SF3B1*, and *SRSF2* have also been observed in patients with BPDCN [11] _ENREF_6. However, because the immune phenotype and genetic abnormalities overlap with the characteristics of other hematopoietic neoplasias, it is very important to reach a definitive diagnosis of BPDCN. In this context, a diagnosis of BPDCN should only be made after excluding myeloid sarcoma, acute myeloid leukemia, myelodysplastic syndrome, natural killer cell lymphoma/leukemia, T-cell lymphoblastic leukemia, and cutaneous peripheral T-cell lymphoma [6] _ENREF_2.

Because BPDCN is an aggressive malignancy with insidious skin manifestations and rapid progression to the leukemic phase, the median survival from diagnosis is 9-13 months, regardless of the initial presentation [12] _ENREF_7. Advanced age and clinical stage are both indicators of a poor prognosis. Although bone marrow transplantation is typically a better therapeutic choice (vs. traditional chemotherapy), BPDCN mainly occurs in older patients, who are not ideal candidates for autologous stem cell transplantation. Therefore, there is no consensus regarding the optimal treatment for BPDCN. Most patients are treated using multi-agent chemotherapy regimens for acute myeloid leukemia, acute lymphoblastic leukemia, or lymphoma, such as DA (idarubicin hydrochloride at 12 mg/m²/day on days 1-3 and cytarabine at 100 mg/m²/day on days 1-7), hyper-CVAD (course A: cyclophosphamide at 300 mg/m² every 12 h on days 1-3, vincristine at 2 mg/day on days 4 and 11, doxorubicin at 40 mg/m²/day on day 4, and dexamethasone at 40 mg/day on days 1-4 and days 11-14; course B: methotrexate at 1,000 mg/m²/day on day 1 and cytarabine at 3,000 mg/m²/day every 12 h on days 2-3, in an alternating fashion), or CHOP (cyclophosphamide at 750 mg/m²/day on day 1, doxorubicin at 45 mg/m²/day on day 1, vincristine at 1.4 mg/m²/day on day 1, and prednisone at 100 mg/day on days 1-5) [13-16]. Patients often respond well to the initial chemotherapy, although many patients relapse, and the relapsed disease is obviously resistant to the previously used chemotherapeutic agents. Unlike adult patients, children

with BPDCN have less aggressive disease and are typically treated using a regimen that is similar to that for high-risk acute lymphoblastic leukemia. Bone marrow transplantation may also be the best choice for pediatric patients. Furthermore, Frankel et al. have reported a high rate of complete remission in patients with BPDCN who received SL-401 (a fusion of diphtheria toxin and IL-3) as a single-agent treatment [12, 17]. Based on these results, SL-401 is currently being evaluated in phase II clinical trials.

In conclusion, we successfully treated an elderly patient with BPDCN using the mini-CHOP regimen. However, prospectively multi-center trials are needed to identify the optimal therapy regimen, which can hopefully be used to improve patient outcomes.

Acknowledgements

This work was supported by the Natural Science Foundation of China (No. 81200353).

Disclosure of conflict of interest

None.

Address correspondence to: Hanying Sun, Department of Hematology, Tongji Hospital, Tongji Medical College, Huazhong University of Science and Technology, Wuhan, Hubei, China. Tel: +86-13807165617; Fax: +86-027-83662680; E-mail: sunhanying2015@163.com

References

- [1] Riaz W, Zhang L, Horna P and Sokol L. Blastic plasmacytoid dendritic cell neoplasm: update on molecular biology, diagnosis, and therapy. *Cancer Control* 2014; 21: 279-89.
- [2] Hwang K, Park CJ, Jang S, Chi HS, Huh JR, Lee JH, Suh C and Lee KH. Immunohistochemical analysis of CD123, CD56 and CD4 for the diagnosis of minimal bone marrow involvement by blastic plasmacytoid dendritic cell neoplasm. *Histopathology* 2013; 62: 764-70.
- [3] Osaki Y, Yokohama A, Saito A, Tahara K, Yanagisawa K, Ogawa Y, Ishizaki T, Mitsui T, Koiso H, Takizawa M, Uchiumi H, Saitoh T, Handa H, Murakami H, Tsukamoto N and Nojima Y. Characterization of CD56+ dendritic-like cells: a normal counterpart of blastic plasmacytoid dendritic cell neoplasm? *PLoS One* 2013; 8: e81722.

- [4] Feuillard J, Jacob MC, Valensi F, Maynadie M, Gressin R, Chaperot L, Arnoulet C, Brignole-Baudouin F, Drenou B, Duchayne E, Falkenrodt A, Garand R, Homolle E, Husson B, Kuhlein E, Le Calvez G, Sainty D, Sotto MF, Trimoreau F and Bene MC. Clinical and biologic features of CD4 (+) CD56 (+) malignancies. *Blood* 2002; 99: 1556-63.
- [5] Dietrich S, Andrulis M, Hegenbart U, Schmitt T, Bellos F, Martens UM, Meissner J, Kramer A, Ho AD and Dreger P. Blastic plasmacytoid dendritic cell neoplasia (BPDC) in elderly patients: results of a treatment algorithm employing allogeneic stem cell transplantation with moderately reduced conditioning intensity. *Biol Blood Marrow Transplant* 2011; 17: 1250-4.
- [6] Shi Y and Wang E. Blastic plasmacytoid dendritic cell neoplasm: a clinicopathologic review. *Arch Pathol Lab Med* 2014; 138: 564-9.
- [7] Gera S, Dekmezian MS, Duvic M, Tschen JA, Vega F and Cho-Vega JH. Blastic plasmacytoid dendritic cell neoplasm: evolving insights in an aggressive hematopoietic malignancy with a predilection of skin involvement. *Am J Dermatopathol* 2014; 36: 244-51.
- [8] Julia F, Petrella T, Beylot-Barry M, Bagot M, Lipsker D, Machet L, Joly P, Dereure O, Wetterwald M, d'Incan M, Grange F, Cornillon J, Tertian G, Maubec E, Saiag P, Barete S, Templier I, Aubin F and Dalle S. Blastic plasmacytoid dendritic cell neoplasm: clinical features in 90 patients. *Br J Dermatol* 2013; 169: 579-86.
- [9] Alayed K, Patel KP, Konoplev S, Singh RR, Routbort MJ, Reddy N, Pemmaraju N, Zhang L, Shaikh AA, Aladily TN, Jain N, Luthra R, Medeiros LJ and Khoury JD. TET2 mutations, myelodysplastic features, and a distinct immunoprofile characterize blastic plasmacytoid dendritic cell neoplasm in the bone marrow. *Am J Hematol* 2013; 88: 1055-61.
- [10] Stenzinger A, Endris V, Pfarr N, Andrulis M, Johrens K, Klauschen F, Siebolts U, Wolf T, Koch PS, Schulz M, Hartschuh W, Goerdts S, Lennerz JK, Wickenhauser C, Klapper W, Anagnostopoulos I and Weichert W. Targeted ultra-deep sequencing reveals recurrent and mutually exclusive mutations of cancer genes in blastic plasmacytoid dendritic cell neoplasm. *Oncotarget* 2014; 5: 6404-13.
- [11] Menezes J, Acquadro F, Wiseman M, Gomez-Lopez G, Salgado RN, Talavera-Casanas JG, Buno I, Cervera JV, Montes-Moreno S, Hernandez-Rivas JM, Ayala R, Calasanz MJ, Larrayoz MJ, Brichs LF, Gonzalez-Vicent M, Pisano DG, Piris MA, Alvarez S and Cigudosa JC. Exome sequencing reveals novel and recurrent mutations with clinical impact in blastic plasmacytoid dendritic cell neoplasm. *Leukemia* 2014; 28: 823-9.
- [12] Frankel AE, Woo JH, Ahn C, Pemmaraju N, Medeiros BC, Carraway HE, Frankfurt O, Forman SJ, Yang XA, Konopleva M, Garnache-Ottou F, Angelot-Delette F, Brooks C, Szarek M and Rowinsky E. Activity of SL-401, a targeted therapy directed to interleukin-3 receptor, in blastic plasmacytoid dendritic cell neoplasm patients. *Blood* 2014; 124: 385-92.
- [13] Lu JP, Li X, Jin YI and Chen MX. Endoplasmic reticulum stress-mediated aldosterone-induced apoptosis in vascular endothelial cells. *J Huazhong Univ Sci Technolog Med Sci* 2014; 34: 821-4.
- [14] Wang ZC, Wang JF, Li YB, Guo CX, Liu Y, Fang F and Gong SL. Involvement of endoplasmic reticulum stress in apoptosis of testicular cells induced by low-dose radiation. *J Huazhong Univ Sci Technolog Med Sci* 2013; 33: 551-8.
- [15] Yasuda H, Takaku T, Tomomatsu J, Hosone M, Tanaka H and Komatsu N. Spontaneous regression of cutaneous blastic plasmacytoid dendritic cell neoplasm followed by acute monocytic leukemia evolving from myelodysplastic syndrome. *Intern Med* 2014; 53: 2717-20.
- [16] Alacacioglu I, Medeni SS, Ozsan GH, Payzin B, Sevindik OG, Acar C, Katgi A, Ozdemirkan F, Piskin O, Ozcan MA, Undar B and Demirkan F. Is the BFM regimen feasible for the treatment of adult acute lymphoblastic leukemia? A Retrospective Analysis of the Outcomes of BFM and Hyper-CVAD Chemotherapy in Two Centers. *Chemotherapy* 2014; 60: 219-23.
- [17] FitzGerald DJ. Targeted diphtheria toxin to treat BPDCN. *Blood* 2014; 124: 310-2.