

## Case Report

# Two-year follow-up results of artificial disc replacement C7-T1

Yi Yang<sup>1</sup>, Litai Ma<sup>1</sup>, Shan Wu<sup>1</sup>, Ying Hong<sup>2</sup>, Hao Liu<sup>1</sup>

<sup>1</sup>Department of Orthopaedics, West China Hospital, Sichuan University, Chengdu, Sichuan Province, P. R. China;

<sup>2</sup>Operation Room, West China Hospital, Sichuan University, Chengdu, Sichuan Province, P. R. China

Received November 1, 2015; Accepted January 15, 2016; Epub February 15, 2016; Published February 29, 2016

**Abstract:** Artificial disc replacement has been widely used in the lumbar spine since the 1980s, and more recently in the cervical spine. However, artificial disc replacement in the cervicothoracic and thoracic regions is very rare. A 43-year-old otherwise healthy male suffered from right sided cervicobrachialgia. X-rays and MRI revealed left C5/6, C6/7 and C7-T1 disc herniation, compromising the neural foramen at the right C6 and C8 nerve roots seriously. A hybrid surgery of artificial disc replacement C7-T1 combined with fusion C5-C6 was performed via a standard anterior Smith-Robinson approach. In this case, a 7 # Zero-P spacer (Synthes GmbH, Oberdorf, Switzerland) was implanted at the level of C5-6 and a 6\*16 mm Prestige-LP (Medtronic) was implanted at the level of C7-T1. Postoperative complications such as hoarseness, dysphagia, cerebrospinal fluid leakage, were not found. His clinical symptoms including pain, numbness and faint were completely relieved 3 months after surgery. The 24 months postoperative X-ray shows the good position of the implant. A hybrid surgery of artificial disc replacement C7-T1 combined with fusion C5-C6 can be safely and successfully performed via a classic right Smith-Robinson approach. Artificial disc replacement C7-T1 may be an attractive option in these carefully selected patients. However, larger studies of longer follow-up duration are needed.

**Keywords:** ACDF, artificial disc replacement, hybrid, Zero-P spacer, Prestige-LP, C7-T1

## Introduction

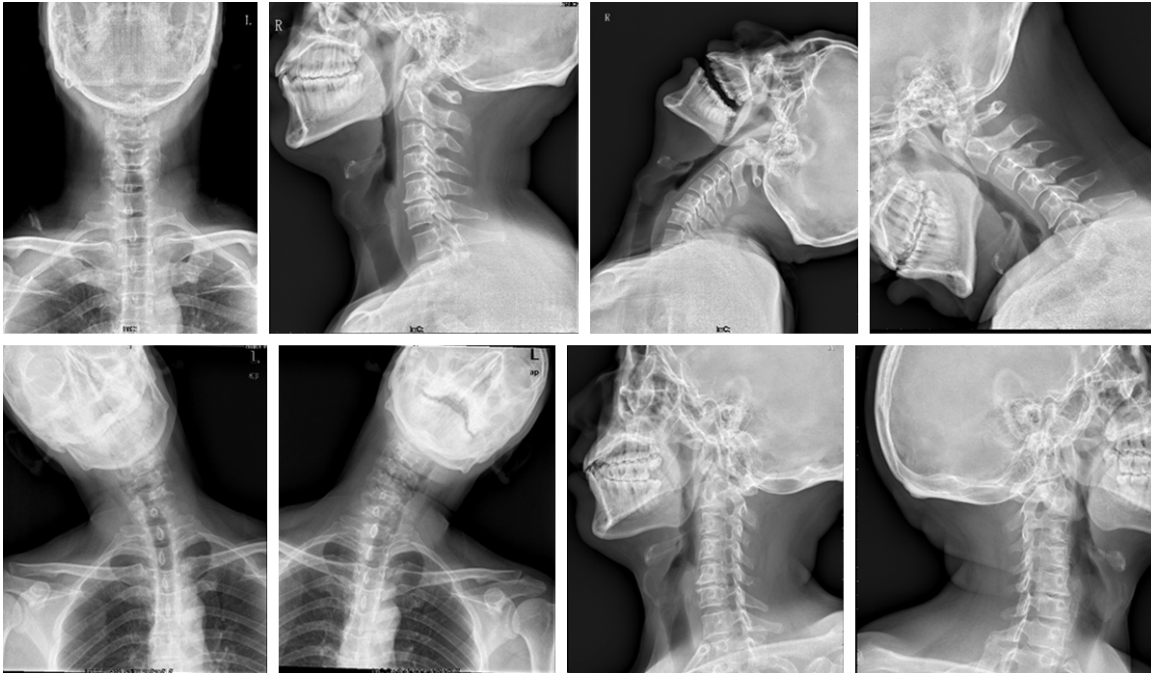Artificial disc replacement has been widely used in the lumbar spine since the 1980s, and more recently in the cervical spine [1]. However, artificial disc replacement in the cervicothoracic and thoracic regions is very rare. Disc herniation at these levels is not common and spine in these regions does not normally have significant mobility that would justify a motion-preserving treatment strategy. However, cervical arthrodesis next to C-7 can affect the normal biomechanics at the cervicothoracic and upper thoracic spine, resulting higher intradiscal pressures and increased mobility [2]. Artificial disc replacement C7-T1 has been little reported and the efficacy and safety were unknown, by sharing our experience of this special case with a short follow-up of 24 months, we are hoping to add new information to the literature.

## Case description

This 43-year-old otherwise healthy male suffered from right sided cervicobrachialgia. Mild

spondylotic changes in segment C5/6 were detected on plain films and dynamic flexion and extension X-rays showed the segmental movement well preserved (**Figure 1**). Magnetic resonance imaging (MRI) revealed left C5/6, C6/7 and C7-T1 disc herniation, compromising the neural foramen at the right C6 and C8 nerve roots (**Figure 2**). Computed Tomography confirms significant osteophytes at the level of C5-C6. Despite an 8-month intensive conservative treatment, the neck, right shoulder and right arm pain has worsened in the last month. Currently he has some neck pain, right shoulder pain and right side arm pain in the C6 and C8 roots distribution. He also feels numbness and faint in his right arm now.

After successful induction of general anesthesia, the surgical procedure was performed using a standard anterior Smith-Robinson approach. The patient was carefully placed supine on a radiolucent operating table with his head and neck in slightly lordotic cervical spine position. A small towel roll was placed under the neck to achieve an appropriate positioning

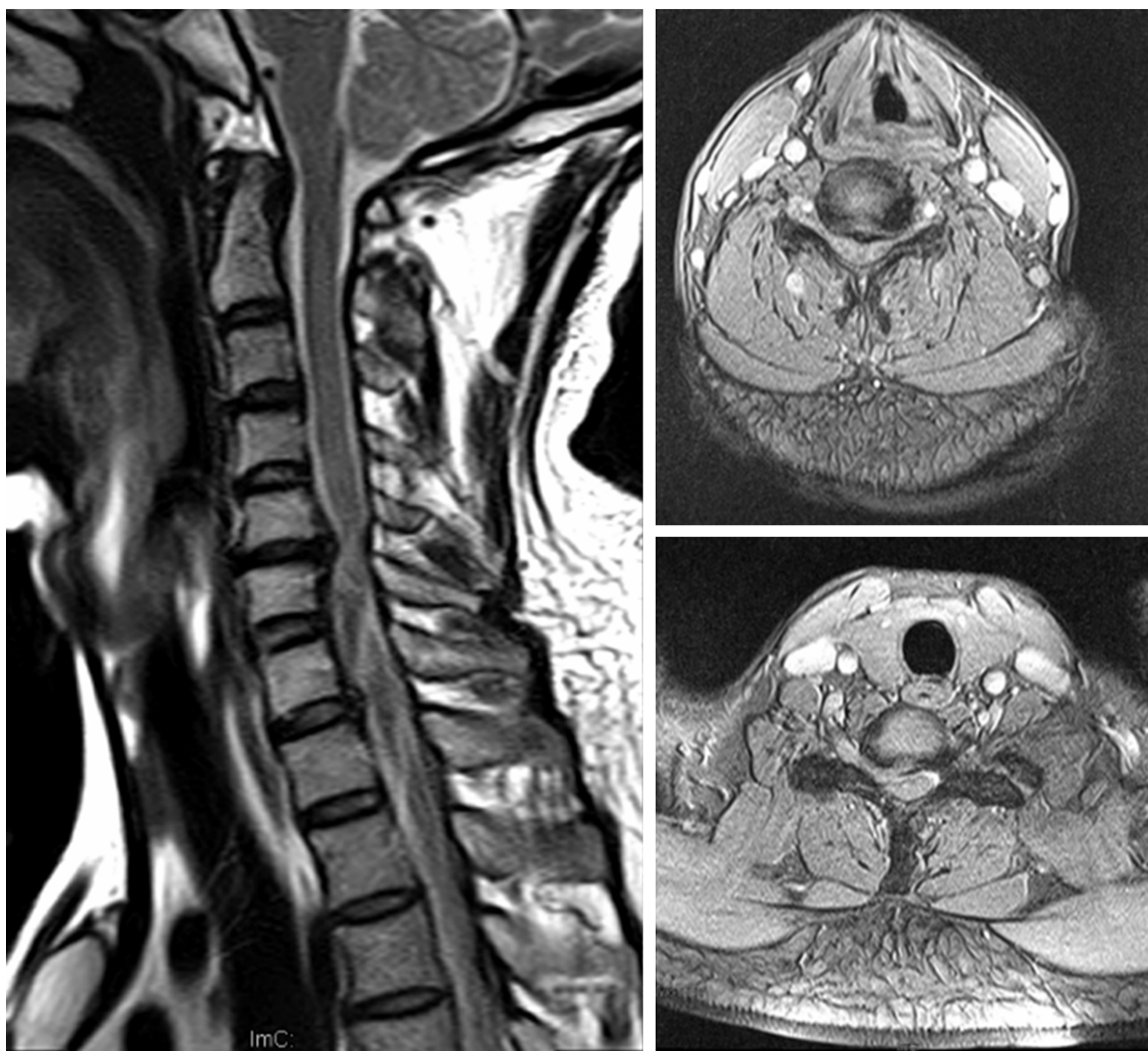


**Figure 1.** Preoperative anteroposterior, lateral and functional X-rays.

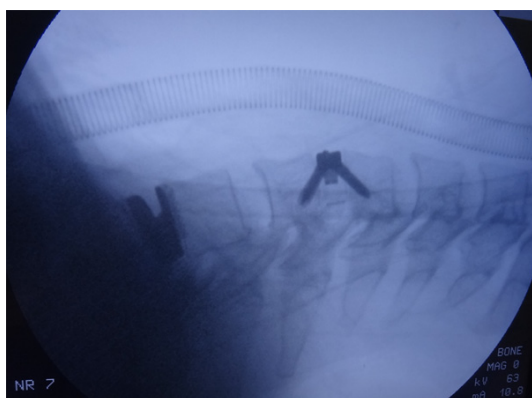
of the neck and shoulders and to keep a physiologic lordosis without creating a hyperlordosis. The head is placed on a folded towel to prevent it from rolling during the procedure. Gentle traction was given to the upper limbs and strapped by the side of body. The correct incision point was determined with the help of fluoroscopy and metal markers. A horizontal right side skin incision (about 5 cm long, at the level of C6-7) was performed to reach the perpendicularly spreading fibres of the platysma muscle. To allow deeper access along the anterior border of sternocleidomastoid muscle, the platysma was separated from the subcutis and splitted sharply longitudinally. Then the approach to the prevertebral fascia and the spine was opened by retracting the trachea and esophagus to the left side. The disc level was confirmed by fluoroscopy and C5-6 discectomy was done and long shaft Caspar screws for interbody retraction were inserted into the middle of the adjacent vertebral bodies. Anterior, posterior and lateral osteophytes were resected with rongeurs. After thorough decompression and scraping off the cartilaginous endplate (The subchondral end-plates are preserved for the prevention of implant subsidence), a 7 # Zero-P spacer (Synthes GmbH, Oberdorf, Switzerland) was implanted at the level of C5-6 at last. The

artificial disc replacement C7-T1 was also approached anteriorly by a standard cervical supramanubrial-Smith-Robinson approach from the right side without resection of manubrium or sternum. After implantation of Zero-P spacer at the level of C5-6, the affected level of C7-T1 was also accomplished neurologic decompression using the same method listed above. Posterior longitudinal ligament along with anterior, posterior and lateral osteophytes were also resected with rongeurs and subchondral end-plates were also preserved. When the endplate preparation completed, the disc space was distracted and a trial implant of appropriate size was inserted with the help of fluoroscopy. In this case, a 6\*16 mm Prestige-LP was implanted at the level of C7-T1. Final imaging of the device implantation is performed before wound closure (**Figure 3**). Hemostasis is rechecked and the skin was sutured subcutaneously.

The patient was placed in a recovery room at first night for fear of potential cervical wound bleeding and discharged home on the third day. One week postoperative X-ray and CT scan showed the good position of implant and the good segmental movement (**Figure 4**). The patient was obeyed to perform cervical func-



**Figure 2.** Preoperative magnetic resonance imaging.



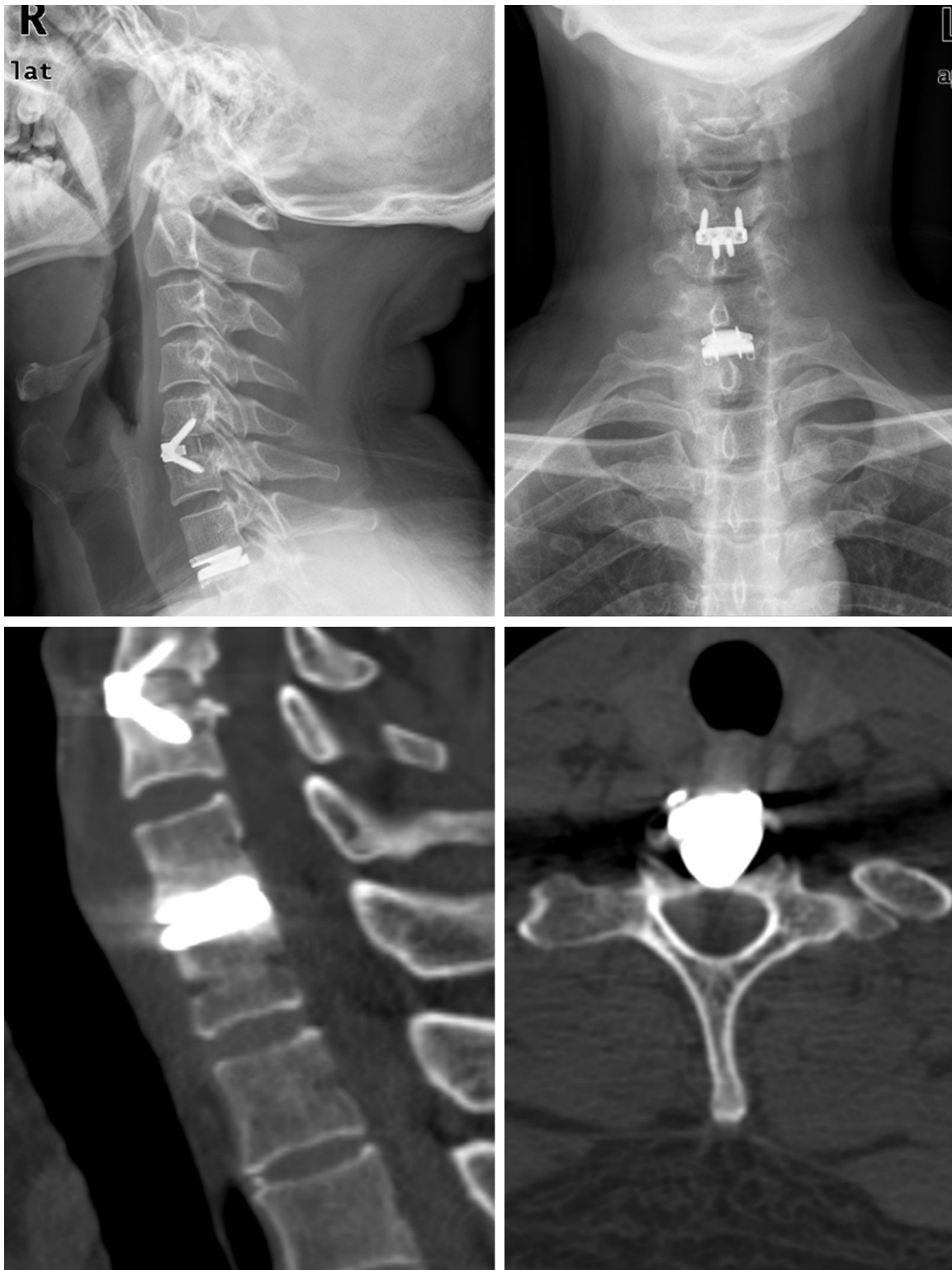
**Figure 3.** Intraoperative fluoroscopy.

tion exercise in the first 3 weeks, which means he would be mobilised from 4 weeks after sur-

gery until bony fusion C5/6 confirmed by CT scan. He was also obeyed to follow at 1, 3, 6, 12, 24 months after operation. Postoperative complications such as hoarseness, dysphagia, cerebrospinal fluid leakage, were not found. His clinical symptoms including pain, numbness and faint were completely relieved 3 months after surgery. The 24 months postoperative X-ray showed the good position of the implant and well preserved segmental movement (**Figure 5**).

### Discussion

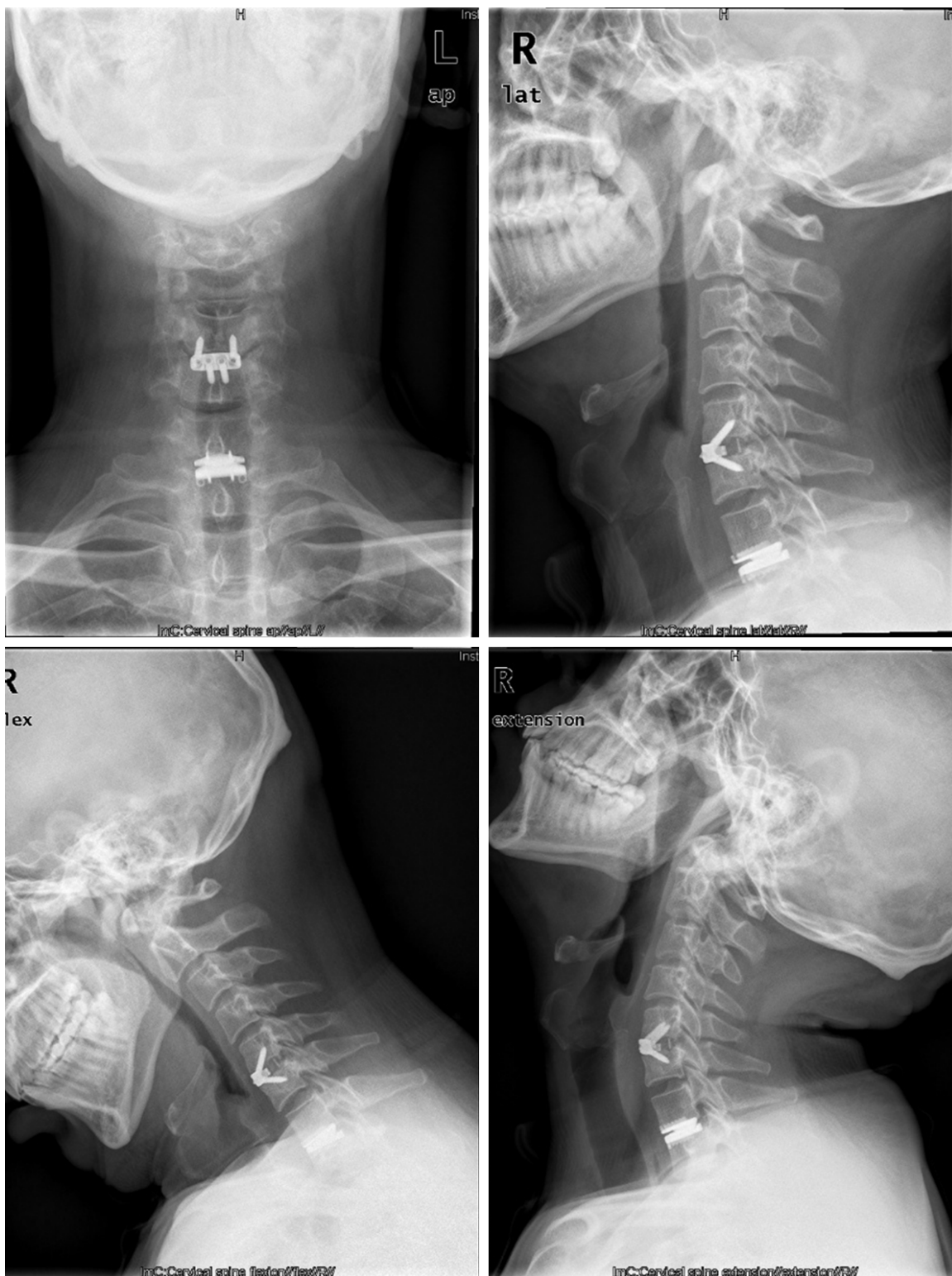Results from previous studies have demonstrated the satisfactory clinical outcomes of cervical disc replacement [3, 4]. A recent meta-analysis demonstrated that cervical disc



**Figure 4.** One week postoperative X-rays and CT scan.

replacement are superior to anterior cervical discectomy and fusion [5]. However, artificial disc replacement in the cervicothoracic and thoracic regions is rarely reported. Sekhon

reported the first case of artificial disc replacement C7-T1 using the Bryan Cervical Disc Prosthesis System in the management of adjacent segment degeneration associated with



**Figure 5.** 24 months postoperative X-rays.

previous fusion surgery adjacent the cervico-thoracic junction [6]. And after that, Keachie et al. reported a 52-year-old woman who had pre-

viously undergone C3-7 fusion and the patient underwent T1-2 arthroplasty in which a Prestige artificial cervical disc was placed via an anteri-

or cervicothoracic approach [7]. Liu et al. reported the first case of two-level cervical artificial disc replacements combined with the nearby segments fusion for the treatment of the multi-level disc herniation [8].

The range of motion at C7-T1 is so little that most surgeons would often think it is not necessary to perform an artificial disc replacement. However, cervical arthrodesis next to C-7 can affect the normal biomechanics at the cervicothoracic and upper thoracic spine, resulting higher intradiscal pressures and increased mobility. In this case, the disc height of C5/6 is impaired and osteophytes are very obvious, so artificial disc replacement may be not suitable for C5/6. If C5/6 and C7/T1 segments were both fused, there is no doubt that the intradiscal pressure at C6/7 would be much higher and the mobility would become much high to compensate the loss of mobility at C5/6 and C7/T1, which will result of disc degeneration acceleration at C6/7. So in these cases, preservation of mobility at C7/T1 is so important and artificial disc replacement would be recommended.

Artificial disc replacement at this region is different from fusion as the artificial disc replacement requiring a well exploration space and a much higher technique of decompression. The skin incision may be a little longer than traditional fusion surgery if you plan to perform a disc replacement at C7/T1. In most cases, Smith-Robinson approach can be successfully used to allow exposure of this region to implant the artificial disc prosthesis. The overall results from this hybrid surgery of artificial disc replacement C7-T1 combined with the segment fusion were good. However, larger studies of longer follow-up duration are needed.

## Disclosure of conflict of interest

None.

**Address correspondence to:** Hao Liu, Department of orthopaedics, West China Hospital, Sichuan University, 37 Guoxuexiang, Chengdu 610041, Sichuan Province, P. R. China. E-mail: liuhao6304@hotmail.com

## References

- [1] Vital JM, Boissière L. Total disc replacement. *Orthop Traumatol Surg Res* 2014; 100: S1-S14.
- [2] An HS, Vaccaro A, Cotler JM, Lin S. Spinal disorders at the cervicothoracic junction. *Spine (Phila Pa 1976)* 1994; 19: 2557-2564.
- [3] Li J, Liang L, Ye XF, Qi M, Chen HJ, Yuan W. Cervical arthroplasty with Discover prosthesis: clinical outcomes and analysis of factors that may influence postoperative range of motion. *Eur Spine J* 2013; 22: 2303-2309.
- [4] Huppert J, Beaurain J, Steib JP, Bernard P, Dufour T, Hovorka I, Stecken J, Dam-Hieu P, Fuentes JM, Vital JM, Vila T, Aubourg L. Comparison between single- and multi-level patients: clinical and radiological outcomes 2 years after cervical disc replacement. *Eur Spine J* 2011; 20: 1417-1426.
- [5] Zhang Y, Liang C, Tao Y, Zhou X, Li H, Li F, Chen Q. Cervical Total Disc Replacement is Superior to Anterior Cervical Decompression and Fusion: A Meta-Analysis of Prospective Randomized Controlled Trials. *PLoS One* 2015; 10: e0117826.
- [6] Sekhon L. Cervicothoracic junction arthroplasty after previous fusion surgery for adjacent segment degeneration: case report. *Neurosurgery* 2005; 56: E205; discussion E205.
- [7] Keachie K, Shahlaie K, Muizelaar JP. Upper thoracic spine arthroplasty via the anterior approach. *J Neurosurg Spine* 2010; 13: 240-245.
- [8] Liu H, Liu X, Shi R. [Two-level cervical artificial disc replacement combined with nearby segments fused for multi-level disc herniations]. *Zhongguo Xiu Fu Chong Jian Wai Ke Za Zhi*. 2006; 20: 383-6.