

## Original Article

# A modified transperitoneal laparoscopic approach combined with transvaginal access to repair complex vesicovaginal fistula: our technique and 7-year experience

Chen Jiang<sup>1\*</sup>, Yu Wang<sup>2\*</sup>, Jianwei Lv<sup>1</sup>, Qibo Fu<sup>1</sup>, Zhendong Li<sup>1</sup>, Feng Qiu<sup>1</sup>, Yiran Huang<sup>1</sup>, Yidong Liu<sup>1</sup>

<sup>1</sup>Department of Urology, South Campus, Renji Hospital, Shanghai Jiao Tong University School of Medicine, No. 2000, Jiangyue Road, Shanghai 201112, China; <sup>2</sup>Department of Gynecology and Obstetrics, South Campus, Renji Hospital, Shanghai Jiao Tong University School of Medicine, No. 2000, Jiangyue Road, Shanghai 201112, China.  
\*Equal contributors.

Received November 27, 2015; Accepted December 28, 2015; Epub February 15, 2016; Published February 29, 2016

**Abstract:** Objective: To investigate the clinical efficacy of modified transperitoneal laparoscopic approach combined with transvaginal access without omental flap to repair complex vesicovaginal fistula after total hysterectomy. Methods: A total of 68 patients with high-up vesicovaginal fistula were retrospectively reviewed. In 15 cases, the surgery was completed using the laparoscopic transabdominal approach. The number of cases using other approaches included: 18 for open extraperitoneal transvesical approach, 12 for transabdominal approach, and 23 for transvaginal approach. Surgical techniques: In the laparoscopic transabdominal approach, the fistula was dissected under direct visual guidance without opening the bladder. The bladder side of the fistula was closed with a single-layer of continuous suture with 3-0 V-Loc barbed suture. The vagina side of the fistula was closed under a vaginoscope or laparoscope. Omental flap was not used in any of the 15 cases. Surgery under other approaches was conducted as reported previously. Results: In comparison with all other three approaches, the laparoscopic transabdominal approach was associated with shorter operation duration, less blood loss and shorter hospital stay. The incidence of post-surgical infection and urinary incontinence did not differ among the treatments. The rate of overactive bladder syndrome and intestinal obstruction was lower in the patients under laparoscopic transabdominal approach, whereas the rate of surgical success was higher with this approach. Conclusions: For high-up complex vesicovaginal fistula, laparoscopic transabdominal repair is a viable approach. The advantage included direct visual guidance, and therefore more efficiency. Omental flap was not needed under this approach.

**Keywords:** laparoscopy, transperitoneal approach, extravesical repair, vesicovaginal fistula

## Introduction

Vesicovaginal fistula produces a dramatic impact on the life quality of affected individuals [1]. In most cases, vesicovaginal fistula develop as a result of iatrogenic injury (mostly total abdominal hysterectomy) or ischemia and necrosis of the bladder and vagina caused by excessively long duration of the delivery process [2-4].

Surgical repair of vesicovaginal fistula is typically carried out under transvaginal or transabdominal approach. The transvaginal approach is frequently-used for fistula located at the

lower segment of vagina with relatively less intestinal adhesion. However, most vesicovaginal fistula cases after total hysterectomy develop at the upper end of the remaining vagina and the trigone region of bladder. It is therefore very challenging to dissect the fistula sufficiently under the transvaginal approach, resulting in a low success rate of repair [5, 6]. For high-up complex vesicovaginal fistula, transabdominal approach could provide more effective visual guidance and adequate fistula dissection. However, the bladder would create a large blind area. Accurate positioning of the fistula often requires the opening of the bladder (conven-

# Transperitoneal laparoscopic combined transvaginal to repair vesicovaginal fistula

**Table 1.** Basic clinical characteristics

Characteristics	Extraperitoneal approach (opening bladder)	Transabdominal approach (opening bladder)	Transvaginal approach	Laparoscopic approach	P
No. cases	18	12	23	15	/
Age (years)	48.6±9.3	49.8±10.4	47.5±8.7	48.4±10.2	0.92
Duration of disease (month)	11.6±6.0	10.2±5.8	11.4±5.6	10.9±5.4	0.91
Fistula size (mm)	27.2±6.9	28.3±7.2	28.3±6.8	27.7±7.3	0.95
Type of fistula	High VVF	High VVF	High VVF	High VVF	/
Number of fistula	Single	9	18	13	/
	Double	4	3	5	/
Cause	Hysteromyoma	6	10	7	/
	Malignant uterine tumor	8	6	13	/
Number of repair	First repair	9	14	9	/
	Second repair	2	7	4	/
	Third repair	1	1	2	/

tional O'Coner method) [7], which could lead to bladder injury [8, 9].

Laparoscopic repair of vesicovaginal fistula was firstly reported by Nezhat *et al.* in 1994 [10]. Subsequent case series (n=20) confirmed the feasibility of such approach [11]. In comparison with conventional transabdominal approach, laparoscopy-assisted operation could provide better surgical field [8, 12, 13], and allow for sufficient dissection and tension-free suture of the fistula. The potential for ureter damage is also minimized [5].

In our current retrospective study, a number of modifications were made to the laparoscopic surgery, including fistula positioning, dissection and closing, to investigate its clinical efficiency comparing with extraperitoneal transvesical, transabdominal, and transvaginal approaches.

## Subjects and methods

### Subjects

The current retrospective study included a total of 68 patients receiving surgical repair for high-up (posterior to ureter ridge) vesicovaginal fistula at the Department of Urology of Renji Hospital Affiliated to Shanghai Jiaotong University, School of Medicine, between January 2009 and June 2015. In all 68 cases, the vesicovaginal fistula developed after total abdominal hysterectomy. Presenting feature was urine leakage in all cases. The diagnosis was established using computer tomography urography (CTU), methylene blue test and cystoscopy. Cases co-morbid with uretero-vaginal

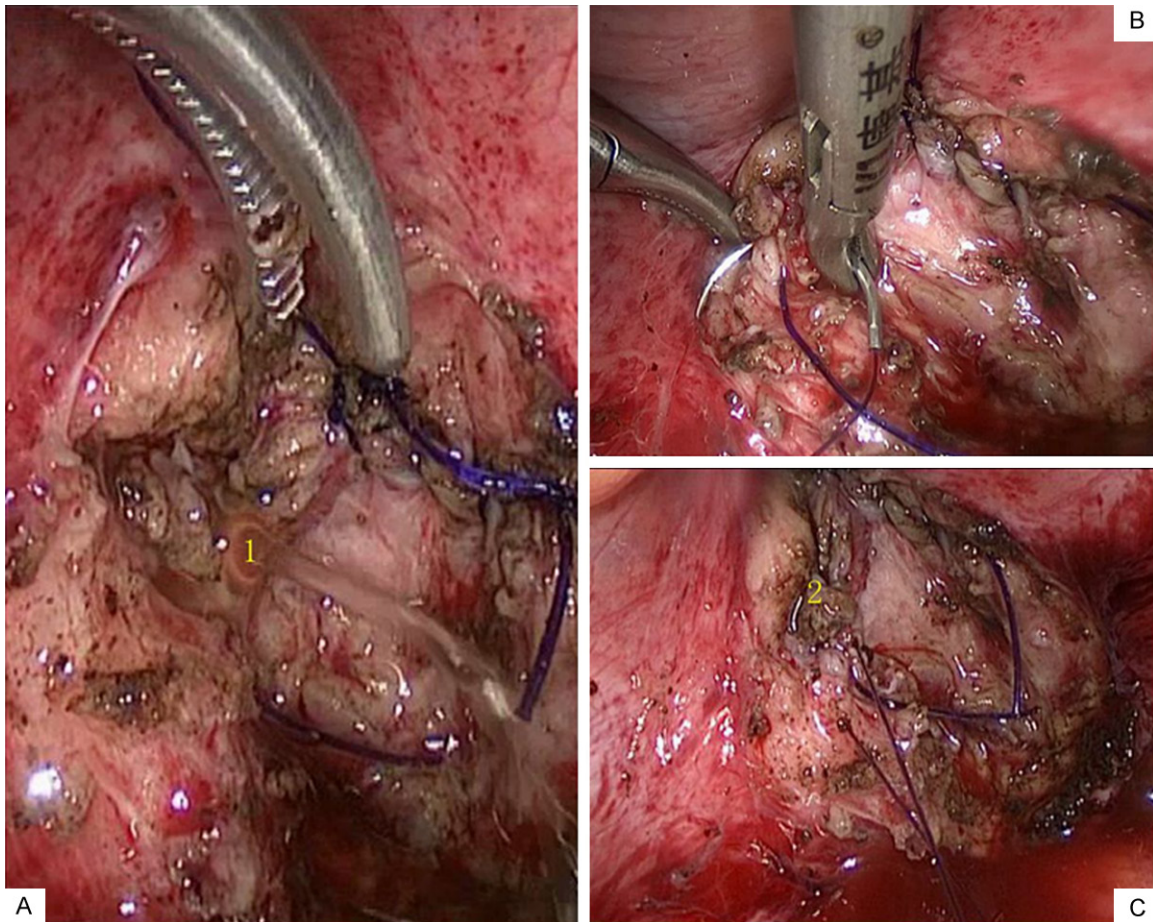
fistula and hydronephrosis were excluded from the current study. The surgical approaches included extraperitoneal transvesical with bladder opening (n=18), transabdominal with bladder opening (n=12), transvaginal (n=23), and laparoscopic transabdominal (n=15) (**Table 1**).

### Surgical procedures and follow-up

The surgeries under extraperitoneal transvesical, transabdominal-transversical, and transvaginal approaches were carried out using conventional methods as previously described [7, 14, 15].

For surgery using the laparoscopic approach, patients were placed in a lithotomy position under general anesthesia. A 5F ureteral catheters were inserted bilaterally under a cystoscope, and the fistula was identified. An observation port (12 mm) was made above the navel. Conventional pneumoperitoneum was not employed due to previous surgical history. Two operating ports were established outside the outer edge of rectus abdominis, 5 and 10 mm on the left and right sides, respectively.

Laparoscopic scissors were used for enterolysis and the surgical field exposure. The residual end of the vagina was pushed forwards and downwards to the abdomen with a uterine manipulator, and the boundary between the bladder and vagina was identified. Under the guide of uterine manipulator and cystoscope, the peritoneum and vagina were opened along the fistula using an electric hook. The fistula tract was identified and fully dissected. The fistula end on the bladder side was identified by



**Figure 1.** Cystometry and suture of vesicovaginal fistula. 1. Leakage during cystometry. 2. No leakage of water after suture of vesicovaginal fistula.

balloon catheter and ureteral catheters on both sides. The electric hook was used to separate the fistula on the bladder and vagina sides along the mucosal transition line. The fistula ends on the bladder and vagina sides were dissected as much as possible without damaging the ureter.

The fistula end on the bladder side was closed under a vaginoscope or laparoscope. Pneumoperitoneum and water injection into vagina were introduced to verify the closure. Scar tissues surrounding the fistula end on the bladder side were removed as much as possible before closing the fistula with a single layer suture of 3-0 V-Loc barbed suture to maximize blood supply. Water was injected into the bladder to verify fistula closure. For leakage upon testing, the site was enforced with 3-0 single-bridge suture (**Figure 1**).

Urinary catheter was removed 4 weeks after surgery. One week later, cystostomy catheter

was closed to test the fistula closure. Upon urine leakage through the vagina, the cystostomy catheter remained in place for 2 additional weeks prior to testing of fistula closure. The cystostomy catheter was removed upon fistula closure. All 68 patients were followed up for 6 months.

#### Statistical analysis

All statistical analyses were performed using the statistical software SPSS version 22.0 (SPSS, Inc.; Chicago, IL, USA). Continuous variables were analyzed using Student's t-test, and categorical variables were analyzed using Chi-square test. A *P* value < 0.05 was considered statistically significant.

#### Results

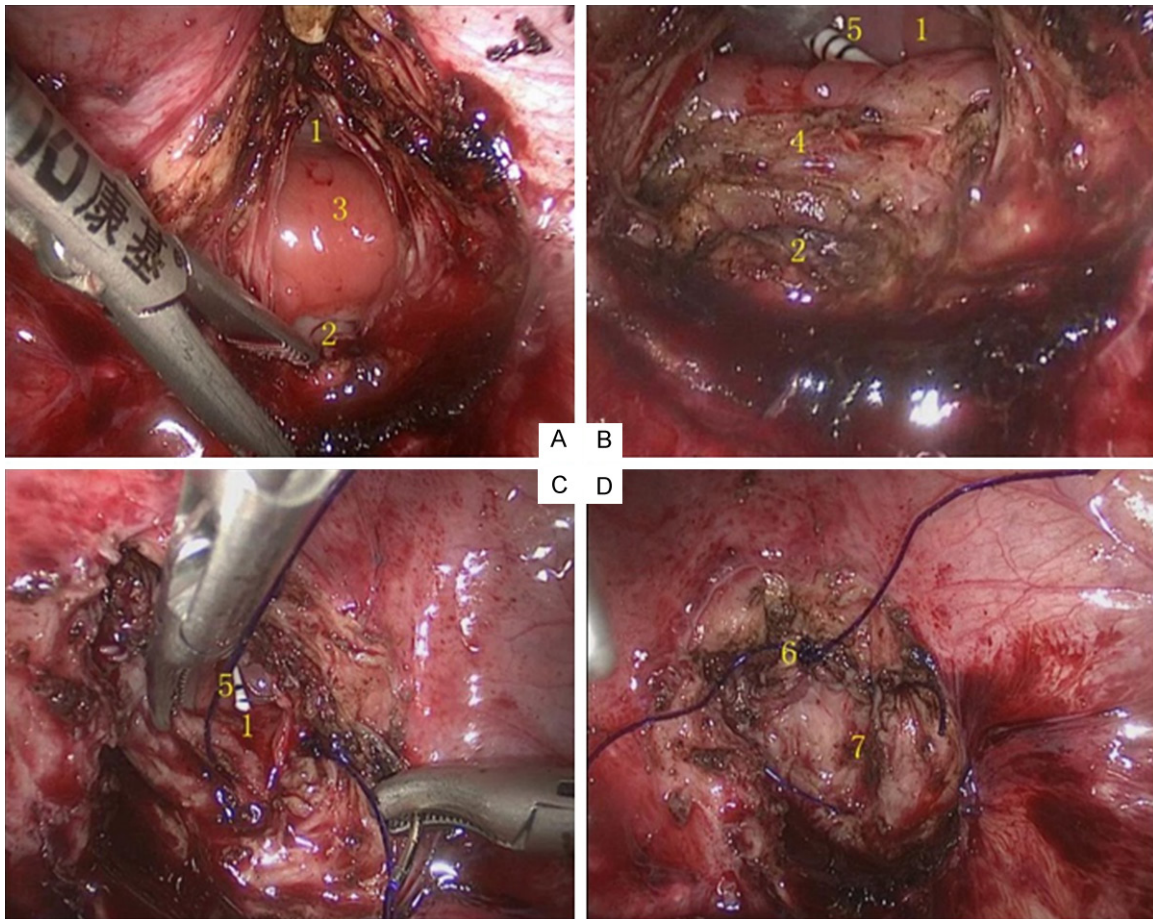
##### Characteristics of included patients

No death occurred perioperatively or in the follow-up. No major injury to the surrounding

## Transperitoneal laparoscopic combined transvaginal to repair vesicovaginal fistula

**Table 2.** Comparison of therapeutic efficacy with the surgery through various approaches

Characteristics	Extraperitoneal approach (A)	Transabdominal approach (B)	Transvaginal approach (C)	Laparoscopic approach (D)	P <sub>A-D</sub>	P <sub>B-D</sub>	P <sub>C-D</sub>
No. cases	18	12	23	15	/	/	/
Duration of surgery (min)	201.2±60.8	210.5±56.8	250.6±63.3	205.3±67.4	>0.05	<0.05	<0.05
Intra-operative blood loss (ml)	95.4±39.6	106.3±38.9	70.2±43.3	60.7±43.2	<0.05	<0.05	<0.05
Duration of stay in hospital (d)	12.4±2.1	17.4±6.4	11.2±1.3	10.3±1.7	<0.05	<0.05	<0.05
Post-surgical infections	38.9% (7/18)	16.7% (2/12)	34.8% (8/23)	13.3% (2/15)	>0.05	>0.05	>0.05
Post-surgical urinary incontinence	11.1% (2/18)	8.3% (1/12)	21.7% (5/23)	13.3% (2/15)	>0.05	>0.05	>0.05
Post-surgical overactive bladder syndrome	55.6% (10/18)	33.3% (4/12)	26.1% (6/23)	20.0% (3/15)	<0.05	>0.05	>0.05
Post-surgical intestinal obstruction	5.6% (1/18)	41.7% (5/12)	4.3% (1/23)	6.7% (1/15)	>0.05	<0.05	>0.05
Success rate of surgery	72.2% (14/18)	83.3% (10/12)	69.6% (16/23)	100.0% (15/15)	>0.05	>0.05	<0.05

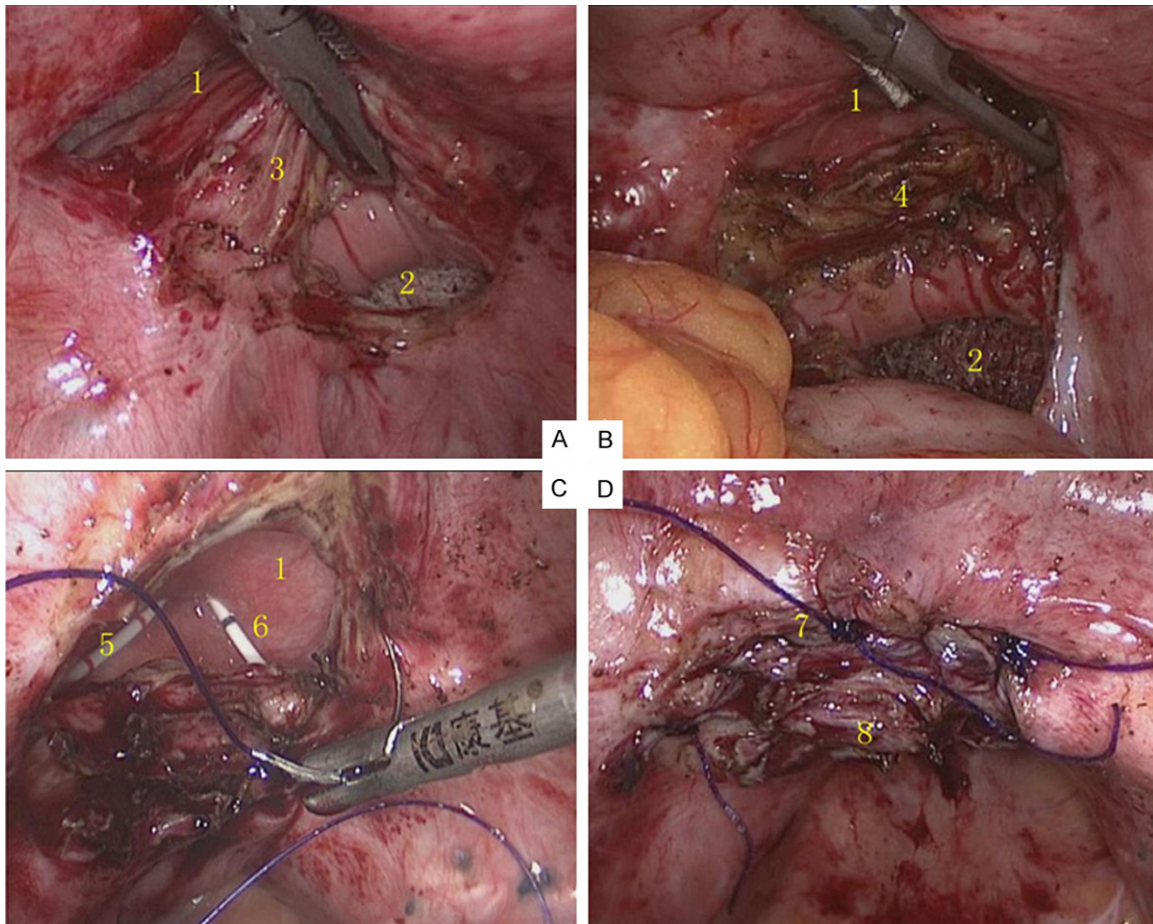


**Figure 2.** Case 1. 1. Fistula at the bladder side. 2. Fistula at the vagina side. 3. Mucosal migration junction between the fistulas at the bladder and vagina sides (bridge-shape structure). 4. The isolated bridge-shape structure. 5. Right-sided ureteral catheter. 6. The fistula at the bladder side following suture. 7. The fistula at the vagina side following suture.

organs or major blood vessels was noted during the surgery. There is no significant difference in terms of age, fistula size, duration of disease, etc. among all the 4 approaches. (Table 1)

### Comparison of surgical approaches

The duration of surgery was shorter in patients receiving operation under the laparoscopic or extraperitoneal transvesical approach (vs.



**Figure 3.** Case 2. 1. Fistula at the bladder side. 2. Fistula at the vagina side. 3. Mucosal migration junction between the fistulas at the bladder and vagina sides (bridge-shape structure). 4. The isolated bridge-shape structure. 5. Left-sided ureteral catheter. 6. Right-sided ureteral catheter. 7. The fistula at the bladder side following suture. 8. The fistula at the vagina side following suture.

transvaginal or open transabdominal approach). Patients in the laparoscopic group suffered less intra-operative blood loss and shorter hospital stay than the other three groups.

The success rate of repair was the highest in the laparoscopic transabdominal group. The incidence of post-surgical infection and urinary incontinence did not differ among the 4 groups. The rate of overactive bladder syndrome was higher in the extraperitoneal transvesical group. The rate of post-surgical intestinal obstruction was higher in the open transabdominal group (Table 2).

#### Representative cases

**Case 1 (Figure 2):** a 44-year-old woman with vesicovaginal fistula after total abdominal hysterectomy and chemoradiotherapy for cervical cancer.

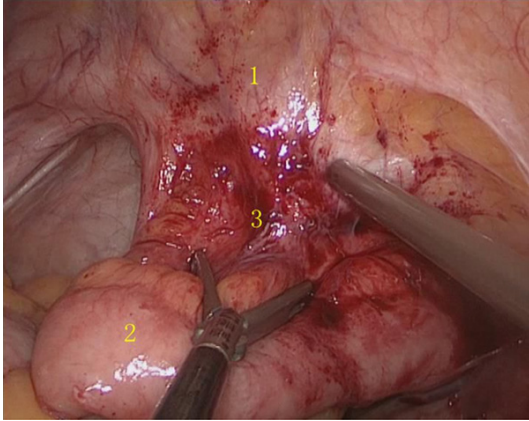
**Case 2 (Figure 3):** a 49-year-old woman with vesicovaginal fistula after total abdominal hysterectomy for hysteromyoma.

**Case 3 (Figures 4 & 5):** a 33-year-old woman with vesicovaginal fistula after total abdominal hysterectomy and adjuvant radiotherapy for cervical cancer. The vagina was re-constructed using ileum. A fistula between bladder and re-constructed vagina developed. An attempt of surgical repair was unsuccessful.

#### Discussion

The choice of surgical treatment modality to repair vesicovaginal fistula largely depends on the location, size, and complexity of the fistula. Other factors, such as past surgical history, also contribute to medical decision. However, there is few consensus on the selection of surgical approach.

## Transperitoneal laparoscopic combined transvaginal to repair vesicovaginal fistula



**Figure 4.** Case 3. 1. Bladder. 2. Use of ileum for vaginal replacement. 3. The site of anastomosis between vaginal residue and ileum.

Zombon *et al.* recommended transvaginal approach for majority of the cases because of its simplicity and reasonably high cure rate [14]. Nesrallah *et al.* reported a 100% success rate of transperitoneal supravescical technique in 29 patients with iatrogenic supratrigonal vesicovaginal fistula, and considered O'Connor technique as the gold standard for the repair of supratrigonal vesicovaginal fistula [16]. We, as well as others [17], believe that O'Connor technique could be modified to minimize damage to the bladder.

Based on the results of the current retrospective analysis, we believe that, high-up vesicovaginal fistula after total abdominal hysterectomy could be managed satisfactorily with laparoscopic transabdominal approach. The traditional transabdominal or transvaginal approach apparently could not achieve both high cure rate and minimized damage to surrounding organs.

All patients in the current study had at least one past episode of surgery, where surgical repair under transabdominal approach is difficult. The choice of laparoscopic transabdominal approach (vs. transabdominal approach) seemed appropriate due to comparable duration of surgery, less blood loss, shorter hospital stay, lower incidence of post-surgical overactive bladder syndrome and intestinal obstruction. In addition to minimally invasive surgery, these benefits could be attributed to non-involvement of the bladder and non-use of omental flap.

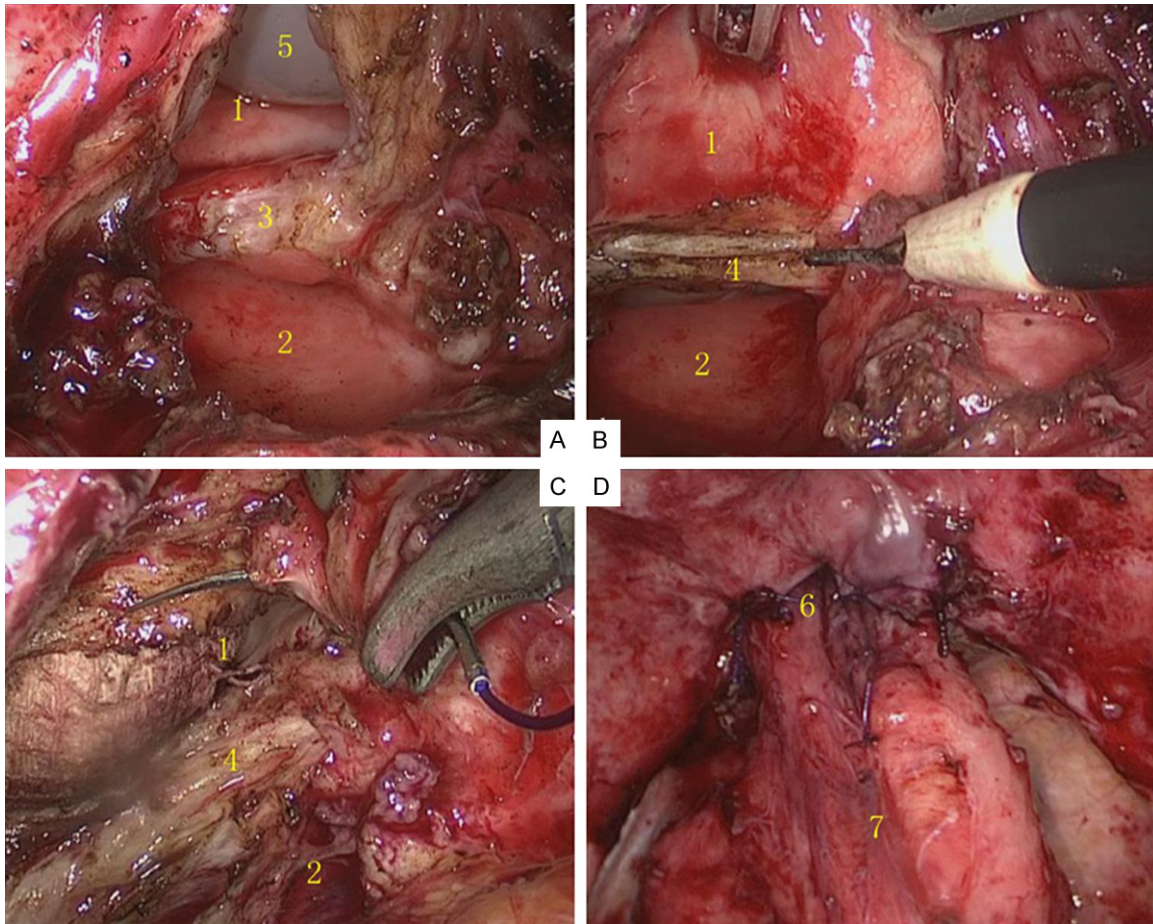
In comparison with transabdominal approach, transvaginal approach is less invasive, but technically challenging due to limited vision and space for maneuver (as evidenced by longer duration of surgery). Complete and tension-free dissection of the fistula is difficult to achieve. Such limitation is evidenced by the relatively low success rate of repair in the transvaginal approach.

The biggest advantage of surgical repair under the laparoscopic approach is the "horizontal-view" field of vision that allows for relatively easy fistula dissection and final tension-free suture without involving the bladder. Under the laparoscopic approach, the residual end of the vagina was pushed forwards and downwards with the guide of a uterine manipulator under a laparoscope. The peritoneum is opened using an electric hook along the direction of fistula site revealed by cystoscopical observation. For large fistula, the peritoneum was opened to reveal the exact fistulous tract. For small fistula, the vaginal canal was entered to provide exact positioning of the fistula. These technical features represent key differences from the conventional O'Connor technique [7].

Based on our observation, the fistulous tract is often the first identifiable structure after the opening of the peritoneum, with a clear bridge (mucosal transition) between the vesical and vaginal ends of the fistula. Breaking this bridge is critical for thorough dissection of the fistula, and ensures adequate tissue on the vaginal end of the fistula sites for tension-free suture. According to our experience, scar tissue on the vesical end of the fistula could be more readily removed using electric hood instead of scissors.

After complete dissection of the fistula, the vaginal end was closed first. The vesical end of the fistula was closed with a single-layer of 3-0 V-Loc barbed suture to minimize the damage to blood supply [18]. The closing started from the left- and right-sided corners of the fistula to protect the ureters and to ensure satisfying results at the weakest sites.

The use of omental flap enhances the barrier between the vagina and bladder, and could increase the blood supply to the tissues surrounding the fistula [4, 19, 20]. However, omental flap could increase post-surgical complica-



**Figure 5.** Case 3. 1. Fistula at the bladder side. 2. Fistula at the vagina side. 3. Mucosal migration junction between the fistulas at the bladder and vagina sides (bridge-shape structure). 4. The isolated bridge-shape structure. 5. The balloon of the ureteral catheter. 6. The fistula at the bladder side following suture. 7. Re-anastomosis between the fistula at the bladder side and ileum.

tions, for example, intestinal obstruction and chronic pelvic pain [18, 21]. In the present study, omental flap was used in all 12 patients in the transabdominal transvesical group. The success rate was 83.3% (n=2 for fistula recurrence). The rate of post-surgical intestinal obstruction was 41.7% (n=5/12). Omental flap was not used in any of the 15 cases in the laparoscopic group. However, the success rate was 100%.

All the 15 patients under the laparoscopic approach had complicated past surgical history, including total abdominal hysterectomy for benign diseases and total abdominal hysterectomy and local radiotherapy for malignant tumors. In one case, the fistula was between the bladder and vagina re-constructed with ileum. The success of surgical repair in such a highly complex case highlights the potential of

laparoscopic approach for complex vesicovaginal fistula.

#### Declaration of conflict of interest

None.

**Address correspondence to:** Yidong Liu, Department of Urology, South Campus, Renji Hospital, Shanghai Jiao Tong University School of Medicine, No. 2000, Jiangyue Road, Shanghai 201112, China. Fax: 86-021-54435631; E-mail: lydsh12345@163.com

#### References

- [1] Coben BL, Gousse AE. Current techniques for vesicovaginal fistula repair: surgical pearls to optimize cure rate. *Curr Urol Rep* 2007; 8: 413-418.
- [2] Lee JH, Choi JS, Lee KW, Han JS, Choi PS, Hoh JK. Immediate laparoscopic nontransvesical

## Transperitoneal laparoscopic combined transvaginal to repair vesicovaginal fistula

- repair without omental interposition for vesicovaginal fistula developing after total abdominal hysterectomy. *JLS* 2010; 14: 187-191.
- [3] Wadie BS, Kamal MM. Repair of vesicovaginal fistula: single-centre experience and analysis of outcome predictors. *Arab J Urol* 2011; 9: 135-138.
- [4] Kohli N, Miklos JR. Meeting the challenge of vesicovaginal fistula repair: conservative and surgical measures. *OBG Manag* 2003; 15: 16-27.
- [5] Das Mahapatra P, Bhattacharyya P. Laparoscopic intraperitoneal repair of high-up urinary bladder fistula: a review of 12 cases. *IntUrogynecol J Pelvic Floor Dysfunct* 2007; 18: 635-639.
- [6] Aayed M, El Atat R, Hassine LB, Sfaxi M, Chebil M, Zmerli S. Prognostic factors of recurrence after vesicovaginal fistula repair. *Int J Urol* 2006; 13: 345-349.
- [7] O'Connor VJ Jr, Sokol JK, Bulkley GJ, Nanninga JB. Suprapubic closure of vesicovaginal fistula. *J Urol* 1973; 109: 515-54.
- [8] Chu L, Wang JJ, Li L, Tong XW, Fan BZ, Guo Y, Li HF. Laparoscopic repair of iatrogenic vesicovaginal and rectovaginal fistula. *Int J Clin Exp Med* 2015; 8: 2364-2370.
- [9] Javali TD, Katti A, Nagaraj HK. A simplified laparoscopic approach to repair vesicovaginal fistula: the M.S. Ramaiah technique *Urology* 2015; 85: 544-546.
- [10] Nezhat CH, Nezhat F, Nezhat C, Rottenberg H. Laparoscopic repair of a vesicovaginal fistula: a case report. *Obstet Gynecol* 1994; 83: 899-901.
- [11] von Theobald P, Hamel P, Febbraro W. Laparoscopic repair of a vesicovaginal fistula using an omental J flap. *Br J ObstetGynaecol* 1998; 105: 1216-1218.
- [12] Miklos JR, Moore RD. Laparoscopic extravesicalvesicovaginal fistula repair: our technique and 15-year experience. *IntUrogynecol J* 2015; 26: 441-446.
- [13] Miklos JR. Laparoscopic treatment of vesicouterine fistula. *J Am Assoc GynecolLaparosc* 1999; 6: 3395-3341.
- [14] Zambon JP, Batezini NS, Pinto ER, Skaff M, Girotti ME, Almeida FG. Do we need new surgical techniques to repair vesico-vaginal fistulas? *IntUrogynecol J* 2010; 21: 3375-3342.
- [15] Singh V, Sinha RJ, Mehrotra S, Gupta DK, Gupta S. Transperitoneal transvesical laparoscopic repair of vesicovaginal fistulae: experience of a tertiary care centre in northern India. *Curr Urol* 2013 Nov; 7: 75-82.
- [16] Nesrallah LJ, Srougi M, Gittes RF. The O'Conor technique: the gold standard for supratrigonalvesicovaginal fistula repair. *J Urol* 1999; 161: 566-568.
- [17] Raz S, Bregg KJ, Nitti VW, Sussman E. Transvaginal repair of vesicovaginal fistula using a peritoneal flap. *J Urol* 1993; 150: 56-59.
- [18] Miklos JR, Moore RD. Vesicovaginal fistula failing multiple surgical attempts salvaged laparoscopically without an interposition omental flap. *J Minim Invasive Gynecol* 2012; 19: 794-797.
- [19] Evans DH, Madjar S, Politano VA, Bejany DE, Lynne CM, Gousse AE. Interposition flaps in transabdominalvesicovaginal fistula repairs: are they really necessary? *Urology* 2001; 57: 670-674.
- [20] Miklos JR, Sobolewski C, Lucente V. Laparoscopic management of recurrent vesicovaginal fistula. *IntUrogynecol J Pelvic Floor Dysfunct* 1999; 10: 16-17.
- [21] Miklos JR, Moore RD. Failed omental flap vesicovaginal fistula repair subsequently repaired laparoscopically without an omental flap. *Female Pelvic Med Reconstr Surg* 2012; 18: 372-373.