

## Case Report

# Giant intraosseous Schwannoma of the calcaneus

Kaihu Li<sup>1\*</sup>, Qin Yang<sup>2\*</sup>, Beibei Gao<sup>3</sup>, Fei Deng<sup>4</sup>, Zhengxiao Ouyang<sup>5</sup>, Bo Liu<sup>1</sup>, Yi Shen<sup>1</sup>, Dan Peng<sup>1</sup>

Departments of <sup>1</sup>Orthopedics, <sup>2</sup>Oncology, <sup>3</sup>Pathology, The Second Xiangya Hospital of Central South University, Changsha, Hunan, P. R. China; <sup>4</sup>Department of Urology, The Third Xiangya Hospital of Central South University, Changsha, Hunan, P. R. China; <sup>5</sup>Department of Orthopedics, Hunan Cancer Hospital and The Affiliated Cancer Hospital of Xiangya School of Medicine, Central South University, Changsha, Hunan, P. R. China. \*Equal contributors and co-first authors.

Received November 3, 2015; Accepted February 14, 2016; Epub March 15, 2016; Published March 30, 2016

**Abstract:** Schwannoma is a benign nerve sheath neoplasm which mainly locates in the soft tissue but rarely originates in the bone. Intraosseous Schwannoma is prone to occur in the mandible and sacrum, while its occurrence is seldom seen in the calcaneus. Herein we report an 18-year-old man with a chief complaint of pain in the right heel. Radiographs revealed a huge, osteolytic, and expansile lesion with well-defined margins in the right calcaneus. Then, an open biopsy was performed and the frozen-section test revealed benign spindle cell tumor. Consequently, the curettage and allograft bone implantation were performed. And the postoperative pathologic results confirmed the diagnosis of intraosseous Schwannoma. The aim of this report is to bring attention to the possibility of Schwannoma in the differential diagnosis of benign-appearing osseous neoplasm in the calcaneus.

**Keywords:** Intraosseous schwannoma, neurilemmoma, calcaneus, radiograph, pathologic result

### Introduction

Schwannoma, or neurilemmoma, is a benign neurogenic tumor arising from the Schwann cells of the nerve sheath [1]. Though accounting for approximately 5% of all benign soft tissue tumors, Schwannoma is very rare in the bone, comprising less than 1% of benign bone tumors [2]. Intraosseous Schwannoma shows no sex- or age-dependent predilections [2]. Apart from the sacrum and mandible, which are the most frequently affected sites, intraosseous Schwannoma also occurs in other bones such as humerus, ulna, metacarpals, phalanges, femur, fibula, and tibia [3, 4]. However, only two cases of intraosseous Schwannoma of the calcaneus have been described in English literature so far [4, 5]. Herein we report a case of giant intraosseous Schwannoma in the right calcaneus.

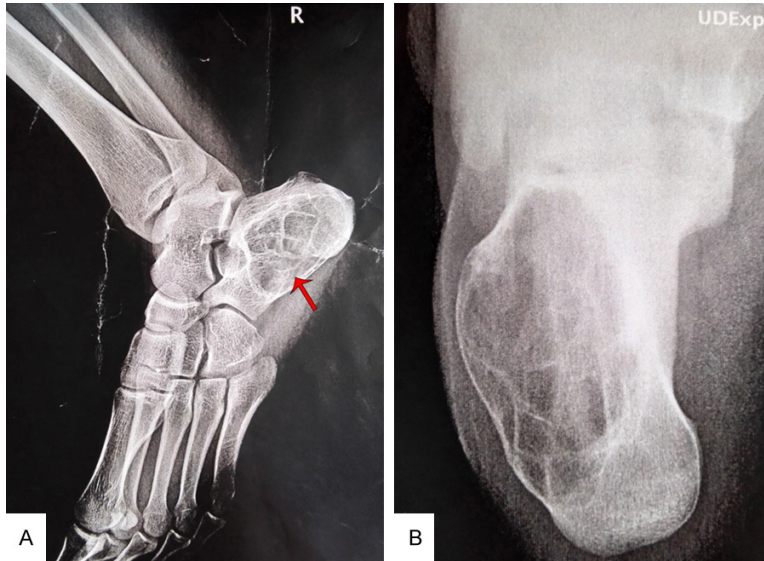
### Case report

An 18-year-old male presented to our department of orthopedics on September 23th 2015 with a 3-month history of dull pain in the right heel. On physical examination, there was full-

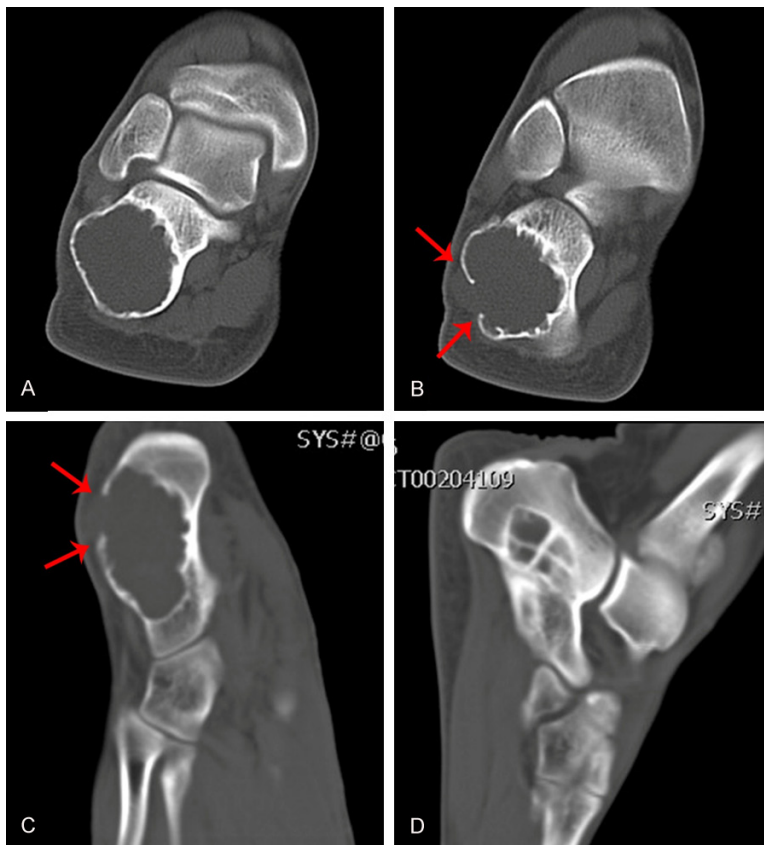
ness and point tenderness at the lateral side of the right calcaneus without numbness. The local skin and temperature were normal. His laboratory test results were unremarkable.

Plain radiographs conducted in his local hospital showed a large, osteolytic, and expansile lesion with a thin sclerotic margin and trabeculation in the right calcaneus (**Figure 1**). Computerized tomography (CT) conducted in our hospital demonstrated a well-defined, multiloculated, and homogeneous lesion with partial destruction of the cortex of the calcaneus, but no periosteal reaction and central calcification were found. The tumor, measuring 10.9×6.5 cm, was invasive, extending to the subcutaneous tissue (**Figure 2**).

Because of the uncertainty in the biological behavior and histological origin of the lesion, an open biopsy was performed. Grossly, the tremellose specimen was yellowish and pinkish-grey (**Figure 3**). The frozen-section test revealed a benign spindle cell tumor suggestive of a Schwannoma. A definitive procedure was subsequently performed, consisting of the curettage of the tumor, phenol cauterization, allograft



**Figure 1.** Plain radiographs of the right calcaneus. The oblique (A) and axial (B) plain radiographs show a large, osteolytic, and expansile lesion with a thin sclerotic margin and trabeculation in the right calcaneus (arrow).



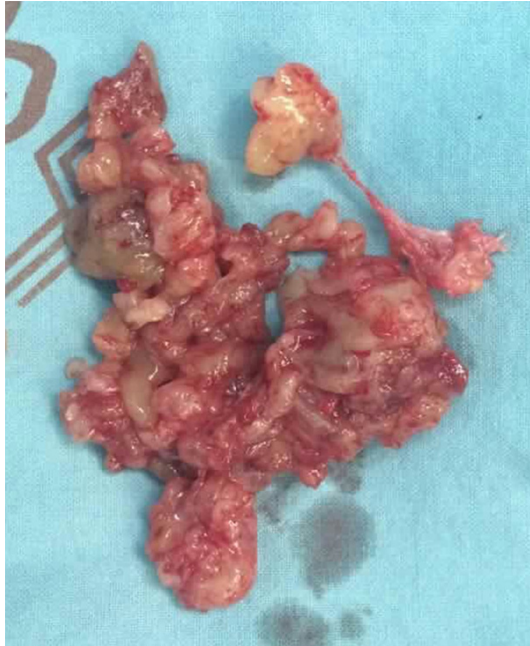**Figure 2.** Computed tomography (CT) of the right calcaneus. The coronal (A, B) and sagittal (C, D) CT scans demonstrate a well-defined, multiloculated, and homogeneous lesion with partial destruction of the cortex of the calcaneus. The tumor is invasive, extending into the adjacent tissue (arrows), but no periosteal reaction and central calcification are found.

bone implantation, and plaster external fixation.

The postoperative pathologic examination was performed. Microscopically, the tumor mass was composed of compact spindle cells arranged in bundles (Antoni Type A) with palisading nuclei (Verocay bodies) and loose connective tissue (Antoni Type B) with haphazardly arranged cells (Figure 4). Hemorrhage and blood vessels can be seen in focal areas (Figure 4B, 4D). Immunostaining for S-100 protein was strong and diffuse (Figure 4E). Besides, the neoplastic cells were positive for Vimentin and negative to Desmin, epithelial membrane antigen, smooth muscle actin, and neurofilament protein (Figure 4F). In addition, atypical nuclei and mitotic figures could not be found in the whole specimen. The histological features above confirmed the diagnosis of intraosseous Schwannoma of the calcaneus. The patient then recovered well.

### Discussion

Schwannoma, a benign tumor, is a kind of nerve sheath tumors which include Schwannoma, neurofibroma, perineurioma, malignant peripheral nerve sheath tumor (MPNST), and so forth [6]. Schwannoma is associated closely with sensory nerves that are of low density within the bone. Therefore, the occurrence of intraosseous Schwannoma is exceedingly low [3, 6]. The tumor is usually asymptomatic until it becomes larger with visible swelling or pain because of the compression and invasion of adjacent organs [1].



**Figure 3.** A part of gross specimen of the tumor in the right calcaneus. The tremellose specimen is yellowish and pinkish-grey.

Moreover, intraosseous Schwannomas are usually less than 5 cm in diameter. Those tumors, which are larger than 5 cm as our case, are known as giant Schwannomas [7].

Schwannoma can involve the bone via three mechanisms: (1) it may be extraosseous, eroding into the bone; (2) it may be located within the nutrient canal, with the formation of a dumbbell-shaped tumor; or (3) it may arise centrally within the bone [2, 6, 8]. According to the study by Kito et al., the edge of the destructed cortex overhung by a soft tissue mass was an important feature of the intraosseous Schwannoma [2]. Therefore, we believed that the tumor in our case was intraosseous Schwannoma, rather than soft tissue Schwannoma, eroding into the bone. In addition, the lesion, which may arise from a branch of the common peroneal nerve, was the combined effects of its spreading within the nutrient canal and direct compression on the bone because of its similarity of radiographic appearance to the case described by Wang et al. [8].

There are some radiographic features of intraosseous Schwannoma presented below. The X-ray or CT usually shows a well-defined, osteolytic, lobulated, and expansile bone tumor with

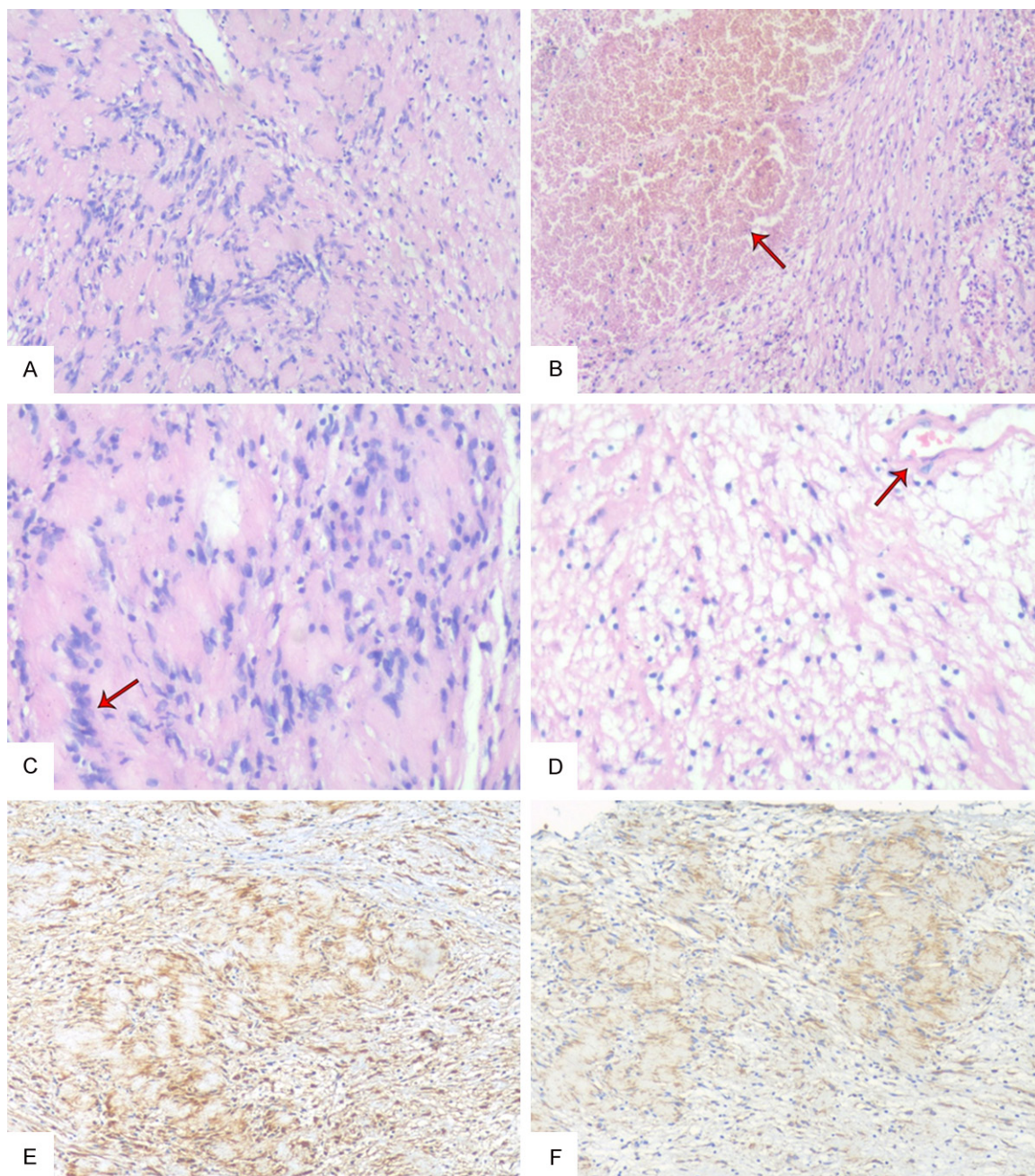
thin sclerotic margin. Besides, the characteristic features also include the absence of periosteal reaction and central calcification or ossification [3, 9]. Furthermore, magnetic resonance imaging (MRI) is particularly helpful in preoperative diagnosis as it shows an isointense signal to skeletal muscle on T1-weighted images and a hyperintense signal to subcutaneous fat on T2-weighted images [8, 10], which reveals peripheral intense enhancement with gadolinium [6]. Nevertheless, the radiographic findings are non-specific and it is difficult to differentiate intraosseous Schwannoma from other benign osseous tumors, including aneurysmal bone cyst, giant cell tumor, multiloculated bone cyst, chondromyxoid fibroma, and enchondroma [4].

The definitive diagnosis of intraosseous Schwannoma is dependent on the histological features, which are similar to those of soft tissue Schwannoma [3]. Microscopically, the histopathology reveals densely cellular Antoni-A areas with well-developed palisading nuclei that form the Verocay bodies. These alternate irregularly with Antoni-B areas containing irregular cells, variable amounts of collagen tissue, thick-walled blood vessels, and considerable microcyst formation [3, 11]. Furthermore, the diffuse immunoreactivity for S-100 protein helps distinguish it from other benign spindle cell lesions of similar histology [6, 12]. Long-standing Schwannoma with advanced degeneration, also referred to as an ancient Schwannoma, often exhibits hyalinization, cystic degeneration, and hemorrhage which has been seen in the present case, suggesting a long-term clinical course and slow tumor growth [13].

Intraosseous Schwannoma is associated with a good prognosis, independently of its size or bone invasion [12]. The most recommended treatment is curettage and bone grafting [10, 14]. Long-term relief is often obtained after adequate curettage alone, but the recurrence rate is high which has been attributed to incomplete tumor excision [7].

Almost all the intraosseous Schwannomas behave in a benign manner, similar to soft tissue Schwannomas, but low malignant potential could not be completely ruled out, given that cases of Schwannomas with malignant transformation have been reported [15,

## Intraosseous schwannoma and calcaneus



**Figure 4.** Pathologic results of the lesion. A. Hematoxylin and eosin stain shows compact spindle cells in Antoni A area (magnification  $\times 100$ ). B. Hematoxylin and eosin stain reveals hemorrhage in Antoni B areal (arrow) (magnification  $\times 100$ ). C. The nuclei in Antoni A area are palisading, forming Verocay bodies (arrow) (magnification  $\times 200$ ). D. The Antoni B area is composed of the loose connective tissue, haphazardly arranged cells, and a blood vessel (arrow) (magnification  $\times 200$ ). E. Immunohistochemical staining for S-100 is strongly positive and diffuse (magnification  $\times 100$ ). F. Immunohistochemical staining for Vimentin is positive (magnification  $\times 100$ ).

16]. In view of the huge tumor size in our case, accompanied with degeneration, a long-term follow-up is needed to observe the biological behavior of this tumor. Furthermore, it still remains unknown whether the tumor will recur or the allograft bone will be incorporated.

In conclusion, we report an especial case of giant intraosseous Schwannoma in the calcaneus. The diagnosis was made on the basis of imaging, and pathologic features. And the intralesional excision and allograft bone implantation were performed. Despite its rareness,

## Intraosseous schwannoma and calcaneus

Intraosseous schwannoma should be taken into consideration as one of the possibilities in the differential diagnosis of radiographically benign-appearing osseous tumors in the calcaneus.

### Disclosure of conflict of interest

None.

**Address correspondence to:** Drs. Yi Shen and Dan Peng, Department of Orthopedics, The Second Xiangya Hospital of Central South University, No. 139, Renmin Road, Changsha 410011, Hunan, P. R. China. E-mail: shenyiak487@163.com (YS); xyeypd@163.com (DP)

### References

- [1] Tian YW, Zhang LY and Liu ZQ. Giant intraosseous schwannoma of scapula: a rare case report and review of the literature. *Diagn Pathol* 2014; 9: 31.
- [2] Kito M, Yoshimura Y, Isobe K, Aoki K, Momose T and Kato H. Intraosseous neurilemmoma of the proximal ulna. *Int J Surg Case Rep* 2014; 5: 914-918.
- [3] de la Monte SM, Dorfman HD, Chandra R and Malawer M. Intraosseous schwannoma: histologic features, ultrastructure, and review of the literature. *Hum Pathol* 1984; 15: 551-558.
- [4] Pyati PS and Sanzone AG. Intraosseous neurilemmoma of the calcaneus. *Orthopedics* 1996; 19: 353-355.
- [5] Cucolo GF, Pearlman HS and Ramachandran VS. Neurilemmoma of Os Calcis. *N Y State J Med* 1964; 64: 3015-3016.
- [6] Rais F, Benhmidou N, Rais G, Kouhen F, Bellahamou K, Loughlimi H, Maghous A, Elmejjiaoui S, Elkacemi H, Kebdani T and Benjaafar N. Solitary intraosseous schwannoma of the base and vault of the skull: a summary review of such unusual location. *Clin Sarcoma Res* 2015; 5: 6.
- [7] Ansari MT, Rastogi S, Khan SA, Yadav C and Rijal L. Giant schwannoma of the first metatarsal: a rare entity. *J Foot Ankle Surg* 2014; 53: 335-339.
- [8] Wang G, Wen X, Qu L, Qi X and Yang C. Intraosseous Schwannoma Involving Multiple Bones of the Foot: A Case Report. *J Foot Ankle Surg* 2016; 55: 201-6.
- [9] Minowa K, Sakakibara N, Yoshikawa K, Ohmori K, Kitagawa Y, Inoue N, Totsuka Y and Nakamura M. CT and MRI findings of intraosseous schwannoma of the mandible: a case report. *Dentomaxillofac Radiol* 2007; 36: 113-116.
- [10] Afshar A and Afaghi F. Intraosseous schwannoma of the second metacarpal: case report. *J Hand Surg Am* 2010; 35: 776-779.
- [11] Abdelwahab IF, Hermann G, Stollman A, Wolfe D, Lewis M and Zawin J. Case report 564: Giant intraosseous schwannoma. *Skeletal Radiol* 1989; 18: 466-469.
- [12] Flores Santos F, Pinheiro M and Felicissimo P. Large foot schwannoma with bone invasion-a case report. *Foot Ankle Surg* 2014; 20: e23-26.
- [13] Kato H, Kanematsu M, Ohno T, Oshima K, Nagano A, Hatano Y and Nishibori H. Intraosseous schwannoma of the ilium. *Clin Imaging* 2015; 39: 161-164.
- [14] Turk PS, Peters N, Libbey NP and Wanebo HJ. Diagnosis and management of giant intrasacral schwannoma. *Cancer* 1992; 70: 2650-2657.
- [15] Woodruff JM, Selig AM, Crowley K and Allen PW. Schwannoma (neurilemmoma) with malignant transformation. A rare, distinctive peripheral nerve tumor. *Am J Surg Pathol* 1994; 18: 882-895.
- [16] McMenamin ME and Fletcher CD. Expanding the spectrum of malignant change in schwannomas: epithelioid malignant change, epithelioid malignant peripheral nerve sheath tumor, and epithelioid angiosarcoma: a study of 17 cases. *Am J Surg Pathol* 2001; 25: 13-25.