

## Case Report

# Neonatal distal humeral physeal separation during caesarean section: a case report and review of a literature

Rui-Lan Lin, Zhen-Jiang Liu, Li-Jun Zhang

*Department of Pediatric Orthopaedics, The Shengjing Hospital, China Medical University, Heping District, Shenyang, Liaoning Province, People's Republic of China*

Received November 3, 2015; Accepted February 10, 2016; Epub March 15, 2016; Published March 30, 2016

**Abstract:** In children, fracture-separation of the epiphyseal plate near the elbow joint is a common occurrence. However, separation of the distal humeral epiphysis is very rare, especially in the newborn. There have been very few reports of this rare injury since 1926. When it occurs in the newborn, it may be difficult to diagnose and is easily mistaken for a dislocation of the elbow. Caesarean deliveries with considerable traction applied to extract the baby can be the risk factor of such injury. The unimpressive clinical appearance of such injury of the elbow, as well as the absence of ossific nuclei of the distal humerus in the newborn is responsible for the dilemma in making the diagnosis. The correct diagnosis was made from plain radiographs and often supplemented with ultrasonography, magnetic resonance imaging (MRI), and arthrography. Opened reduction with percutaneous Kirschner wire fixation is one of the treatments of choice for these injuries. In this article, we report a rare injury of distal humeral epiphyseal separation in a newborn during a caesarean section.

**Keywords:** Physeal separation, epiphysis, distal humerus, newborn

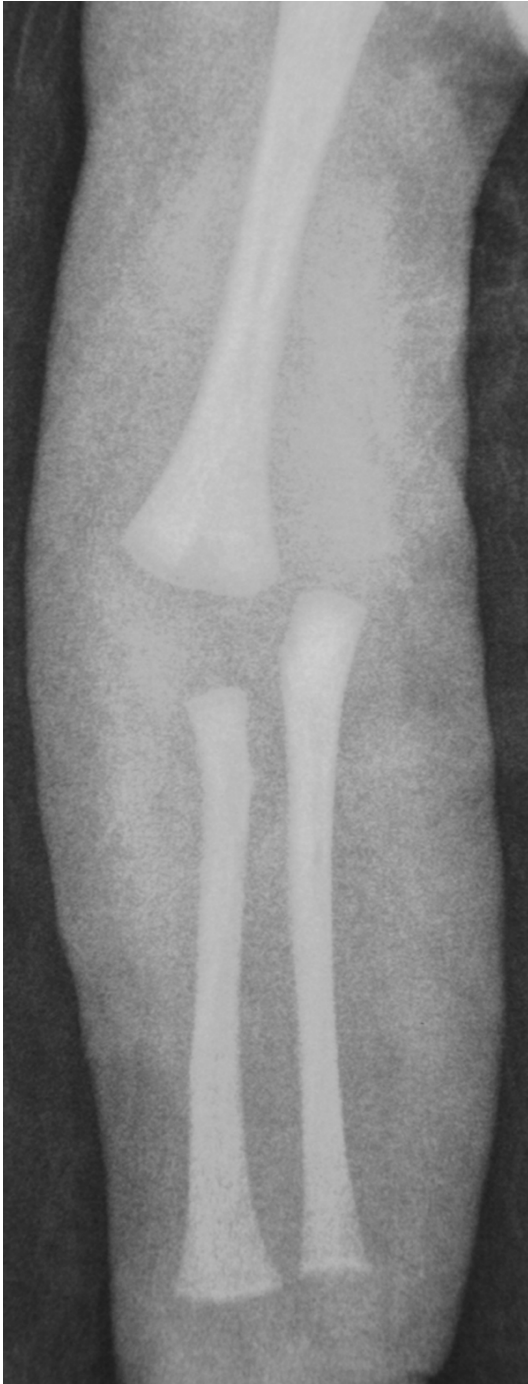## Introduction

Neonatal separation of the distal epiphysis of the humerus was first reported in 1926 by Camera, there have been very few reports of this rare injury since then [1-4]. Epiphyseal injuries are encountered in 17.9% of all pediatric fractures, and are more common in the upper limbs. However, separation of the distal humeral epiphysis is very rare among children with epiphyseal injuries near the elbow joint, and reportedly accounts for 0.7% of pediatric cases of epiphyseal plate separation [5]. Neonatal separation of the distal epiphysis of the humerus is a rare injury, and when it occurs in the newborn, there is usually a rotatory or shear force associated with birth trauma or child abuse [6, 7]. The major problem is the initial recognition of this injury. As the ossification centre of the capitellum arises at 3 to 9 months after birth [6, 8], its alignment with the radius cannot be ascertained in plain radiograph. It is thus difficult to differentiate this injury from dislocation of the elbow [8]. The correct diagnosis

was made from plain radiograph and often supplemented with ultrasonography, MRI and arthrography [7]. Caesarean section has been reported to reduce the incidence of birth-associated injuries to nearly zero, but may result in fractures of the femur and humerus [8]. Caesarean deliveries with considerable traction applied to extract the baby may confer the risk of traumatic separation of the distal humeral epiphysis. The mechanism of injury could be hyperextension of the elbow or a backward thrust on the forearm with the elbow flexed [4].

## Case report

On March 23, 2015, a female newborn was delivered by caesarean section after 33 weeks of gestation. Birth weight was 2400 g. Half an hour after birth, swelling and reduced movement of the right elbow were noticed by the pediatrician. Unfortunately, no radiographic examination was performed at that time. The fifth day after birth, the first plain radiograph of right elbow showed a separation of the distal



**Figure 1.** Anteroposterior (AP) view of elbow radiograph showing the ossification centre of the capitulum is not visible in this newborn. The proximal radius and ulna maintain an anatomic relationship to each other but are displaced medially in relation to the distal humerus.

humeral epiphysis with posteromedial displacement (**Figure 1**). The sixth day after birth, the MRI of right elbow confirmed the diagnosis of this injury (**Figure 2A** and **2B**). The ninth day

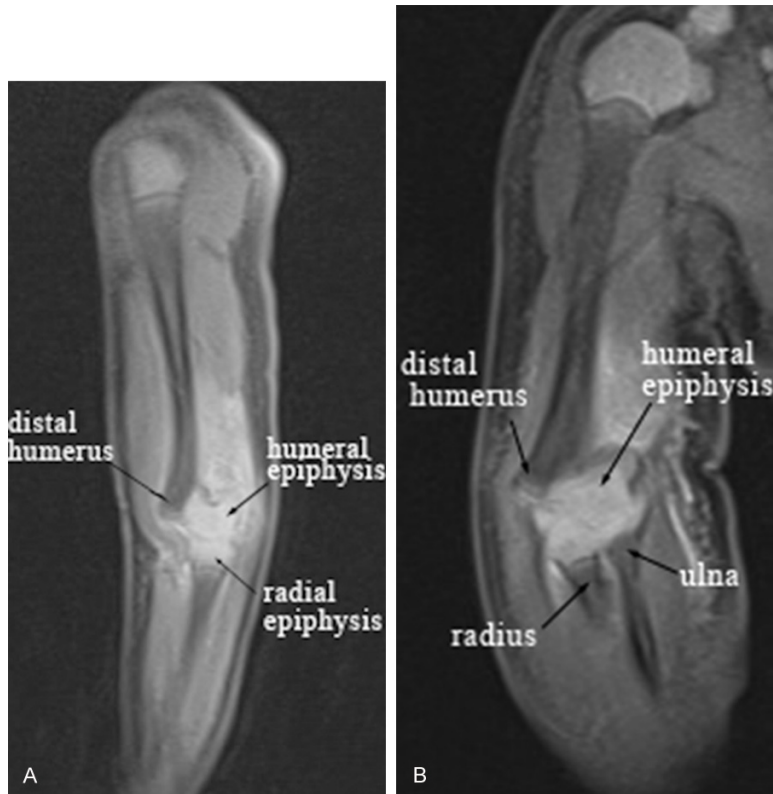after birth, the patient was referred to Shengjing Hospital of China Medical University. The clinical examination revealed obvious swelling of the distal humerus and limited movement of right elbow. The surgery was performed at the tenth day after birth. During the surgery, the tentative close reduction was failed, and the open reduction had to be performed. The arthrography of right elbow showed it was not an intra-articular fracture (**Figure 3**). The surgeons selected a medial approach of right elbow. The new periosteal bone formed around the distal humerus, and the whole epiphysis remained displaced posteriorly and medially. Complete reduction of the fracture was achieved and fixation with two percutaneous crossing Kirschner wires (diameter, 1.0 mm) was performed (**Figure 4A** and **4B**) and application of plaster cast for immobilisation. No limitation of flexion or function was evident. Pronation and supination were normal. The right and left carrying angles were equal. The patient had a full range of movement and a normal carrying angle of right elbow after two months. The plain radiograph of right elbow showed a normal alignment between distal humerus and proximal radius and ulna (**Figure 5**).

### Discussion

In 1818, Gurlt has been credited by Stimson with the first description of fracture-separation of the distal humeral epiphysis. The first explicit description of this injury was by Smith in 1850, and single cases have been reported by Poland and by Ashhurst. In 1926, Camera first reported such a fracture in the neonate, and in 1954, Smith described the fracture in a monograph [9]. Most fractures involving the entire distal humeral physis occur before the age of 5 or 7 and are most common under the age of 2. In children, fracture-separation of the epiphyseal plate near the elbow joint is a common occurrence. However, separation of the distal humeral epiphysis is very rare, especially in the newborn. Neonatal separation of the distal epiphysis of the humerus has an incidence of approximately 1:35,000 live births [1].

The exact mechanism of this injury is unknown. A few consistent factors are evident. First, many fractures of the entire distal humeral physis have occurred as birth injuries associated with difficult deliveries [2, 9, 10]. Second, rota-

## Neonatal distal humeral physeal separation



**Figure 2.** A. MRI scan of the injured right elbow. Sagittal image showing the cartilaginous distal humeral epiphysis. It has fractured and displaced posterior in relation to the shaft of the humerus. The humero-radial articulation is intact. This confirms the diagnosis as fracture-separation of the distal humeral epiphysis. B. MRI scan of the injured right elbow. Coronal image showing the cartilaginous distal humeral epiphysis. It has fractured and displaced medial in relation to the shaft of the humerus. The humero-ulnar articulation is intact. This confirms the diagnosis as fracture-separation of the distal humeral epiphysis.

ry or shear forces on the elbow, which can be caused by child abuse or birth trauma in young infants, are probably more responsible for this injury in young children [11]. Third, a hyperextension force on an outstretched arm may cause the injury in children [12].

Since 1976, we were able to find only twenty-four reported cases in the orthopaedic literatures [1, 2, 4, 6-8, 10, 13-23]. Most of these had complicated births (**Table 1**). The three-point relationship between the olecranon process, the medial humeral epicondyle, and the lateral humeral epicondyle may not be ascertained due to elbow swelling. Therefore, the clinical findings and physical examination do not always allow a definitive diagnosis, and the injury can be overlooked in the infant [1, 10]. The nature and etiology of this injury was fur-

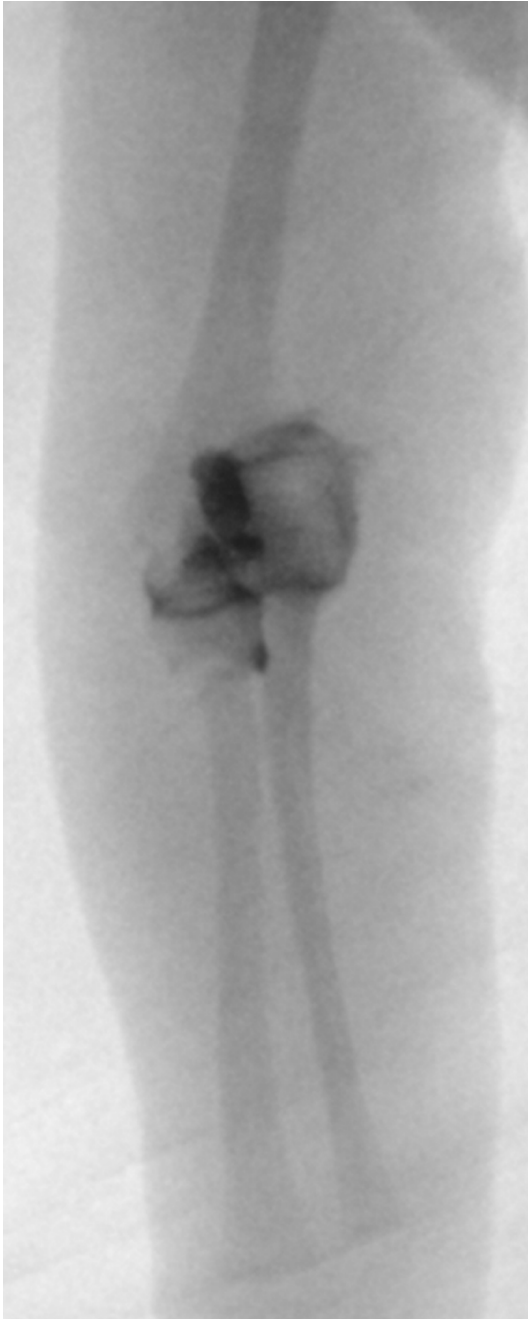ther obscured by its delayed presentation. These injuries are commonly suspected or diagnosed at or closely after birth [19].

The clinical findings in most of cases are notably swelling, deformity and limited motion of the elbow [2, 4, 6-8, 10, 13-16, 19, 23]. The ecchymotic in skin [2], and muffled crepitus with manipulation [2, 8, 10, 14, 23], and pseudoparalysis of the arm [7, 15] exist in some cases. Moderate swelling or tenderness may be the only abnormal finding in some infant with an epiphyseal separation [1, 14, 18]. The unimpressive clinical appearance of such an injury of the elbow, as well as the absence of ossific nuclei of the distal humerus in the newborn, are responsible for the dilemma in making the diagnosis [13]. A dislocation of the elbow was initially diagnosed both radiologically and clinically in Navallas's report [6]. The correct diagnosis was made at open operation in Macafee's report [18].

The differential diagnosis includes dislocation of the radial head, which has also been described after a difficult birth [6]; dislocation of the elbow, to our knowledge, the proximal radius and ulna is almost always posterolateral and the relationship between the proximal radius and lateral condylar epiphysis is disrupted [6]; and fracture of the lateral humeral condyle [4].

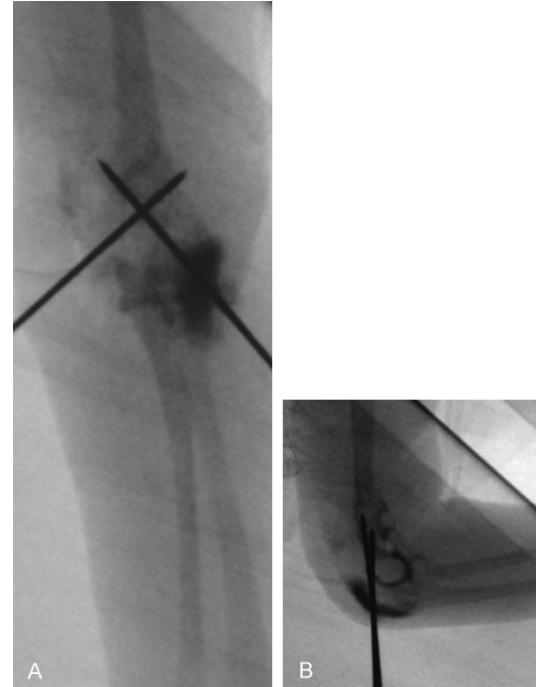
Radiograph revealed posteromedial displacement of the proximal radius and ulna with respect to the distal humerus [1, 2, 4, 6-8, 10, 13, 14, 16, 21-23]. The mechanism of injury for a posterior displacement injury of the distal humerus appears to be a rotation-extension mechanism [2]. Normal relationship of the proximal radius and ulna was apparently maintained. There was no evidence of bone frac-

## Neonatal distal humeral physeal separation



**Figure 3.** The elbow arthrography before closed reduction demonstrating the proximal radius and ulna are displaced medially in relation to the distal humerus.

tures in the distal metaphyseal region of the humerus or in the proximal radius and ulna [6]. Plain radiographs cannot detect fracture-separation until the capitellar ossification center appears or until some new bone is laid down by the elevated periosteum. Thus, radiography is inconclusive in distinguishing between dislocation and fracture-separation [14].

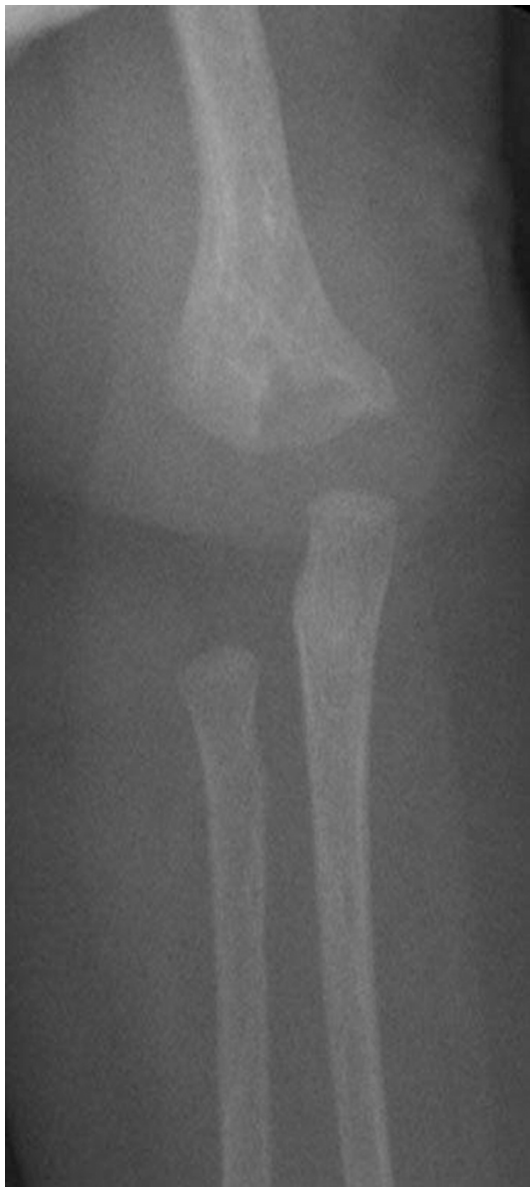

**Figure 4.** A. Anteroposterior (AP) view of elbow radiograph showing two crossing pinning are necessary for stable fracture fixation. It demonstrating realignment after pin fixation. Medial displacement injury of the distal humerus were reduced. B. Lateral radiograph of elbow demonstrating realignment after pin fixation. Posterior displacement of the distal humerus was reduced.

Ultrasound can be used to differentiate elbow dislocation from fracture-separation of the distal humeral epiphysis [15, 16, 24], and it is a cheap, available [6]. Ten cases who had been performed ultrasound examination had been reported in the past literatures [1, 6, 7, 13, 14-16, 19]. The images showed posterior displacement of the radial and ulnar diaphysis with respect to the humeral diaphysis, as well as posteromedial displacement of the distal humeral epiphysis. Ultrasonography showed irregularity and the changed relationship between the distal epiphysis and metaphysis of the humerus [1, 14]. In the presence of fracture, the ultrasound examination can be uncomfortable and painful. Furthermore, it does not normally provide good images of the bone or the epiphysis, but the periosteum and its elevation can be well visualized [4].

MRI scanning has the distinct advantage that it provides direct depiction of the cartilage, bone and soft tissue. Furthermore, these can be displayed in sagittal, coronal, or oblique long axis

## Neonatal distal humeral physeal separation



**Figure 5.** Anteroposterior (AP) radiograph of the elbow taken two months postoperatively showing a normal alignment between the proximal radius and ulna with respect to the distal humerus.

planes. All components of the injury are directly visualised, allowing more precise definition of the acute injury. It does not use ionising radiation and the elbow does not have to be manipulated to obtain the images [14]. Six cases who had been performed MRI had been reported in the past literatures [1, 4, 7, 8, 14, 19]. MRI revealed a fracture-separation of the distal humeral physis with posteromedial displacement. The potential problem with MRI is getting the baby to lie still in the scanner and this usu-

ally means use of anaesthesia [4], and it is an expensive technique, which is not always available [6].

Elbow arthrography, which delineates the cartilaginous epiphysis, may demonstrate the injury. It is a useful tool that is quick and minimally invasive and allows adequate visualization of joint anatomy during surgery, which aids intra-operative decision making. In pediatric patients, arthrography is most useful for visualization of the elbow, knee, and hip joints. It can help the surgeon to refine the diagnosis and management of pediatric fractures and aids in surgical assessment during joint and limb reconstruction [25]. Two cases who had been performed arthrography had been reported in the past literatures [10, 16]. The arthrogram of the elbow performed under general anaesthesia showed separation of the distal humeral epiphysis with posteromedial displacement. Arthrography is invasive and there is a risk of infection [10, 24].

Treatment is first directed toward prompt injury recognition. The goal of treatment is to obtain acceptable alignment until the fracture heals over 2 to 3 weeks. Closed treatment of these fractures in newborns and infants has been advocated [10]. The results of nonoperative treatment in the literature in the short term have been satisfactory. However, review of the results from the series of Delee et al [3] showed a 25% incidence of cubitus varus 5-10°. In the present case report, we had to treat this patient with open reduction and percutaneous crossing pin fixation because of the delayed diagnosis and treatment. It was impossible for closed reduction because of the new bone around the distal humerus. We believed that it would be difficult to maintain 90° of flexion with use of a cast alone for so small a patient. The result of the surgical treatment in the present patient in the short-term is satisfactory, but long-term follow-up is necessary to assess any important growth disturbance. Usually, the varus deformity that seems to be the most common complication of traumatic separation of the distal epiphysis of the humerus is not progressive [3].

Other treatment includes simple splint or cast immobilization, closed reduction with splint or cast immobilization, and opened reduction with percutaneous pinning fixation and splint or cast immobilization. In the present review, 6 of 24

## Neonatal distal humeral physeal separation

**Table 1.** Management and outcome in 24 reported cases of neonatal separation of the distal humeral

Author	Case	Presentation	Injury mechanism	Diagnosis	Treatment	ROM	Remodeling	Follow-up
Macafee [18] 1967	1	2 d	Birth trauma	X-ray	OR	Full	Normal	9 m
Berman [23] 1980	1	2 d	Difficult labour	X-ray	OR+pinning+cast	Full	Normal	8 m
Downs [2] 1982	1	36 h	Difficult labour	X-ray	Traction	Loss of 12°	Normal	6 m
Menon [22] 1982	1	At birth	Difficult labour	X-ray	CR+collar+cuff	Loss of 10°	Normal	10 m
Barrett [10] 1984	2	4 d	Cesarean	X-ray+Arthrogram	OR+pinning+splint	Loss of 20°	Normal	24 m
		2 d	Difficult labour	X-ray+Arthrogram	CR+splint	Full	Normal	5 y
Paige [17] 1985	1	At birth	Normal delivery	X-ray	CR+splint	Full	N/A	N/A
Dias [16] 1988	1	0.5 h	Normal delivery	X-ray+Ultrasound+Arthrogram	N/A	Full	Normal	4 w
Princic [20] 1995	1	N/A	Birth trauma	X-ray+Ultrasound	CR+cast	Full	Normal	9 m
Ziv [15] 1996	1	A few hours	Normal delivery	X-ray+Ultrasound	CR+splint	N/A	N/A	N/A
Brown [19] 1997	1	3 d	Difficult labour	X-ray+Ultrasound+MRI	Cast	Full	Normal	N/A
Costa [21] 2001	1	19 d	Normal delivery	X-ray+MRI	Traction	Full	Normal	1 m
Sawant [4] 2002	1	12 h	Normal delivery	X-ray+MRI	N/A	N/A	N/A	N/A
Rose [13] 2002	1	At birth	Normal delivery	X-ray+Ultrasound	OR+pinning+splint	Full	Mild varus	6 m
Raupp [1] 2002	1	9 d	Normal delivery	X-ray+Ultrasound+MRI	Cast	Full	Normal	8 m
Söyüncü [14] 2009	1	2 d	Normal delivery	X-ray+Ultrasound+MRI	OR+pinning+splint	Full	Normal	16 m
Jacobsen [7] 2009	6	12 d	Difficult labour	X-ray+Arthrogram	Cast	Full	Normal	16 m
		2 d	Normal delivery	X-ray+Ultrasound	Traction+CR+cast	Full	Normal	28 m
		14 d	Difficult labour	X-ray	Cast	Full*	Normal	60 m
		9 d	Cephalic fast delivery	X-ray+Ultrasound	Cast	Full	Normal	54 m
		1 d	Long delivery	X-ray+Ultrasound+MRI	CR+cast	Full	Valgus 5°	21 m
		30 d	Normal delivery	X-ray	Cast	Full	Normal	2 y
Sabatl [8] 2011	1	2 d	Cesarean	X-ray+MRI	CR+plaster slab	Full	Normal	7 w
Navallas [6] 2013	1	At birth	Cesarean	X-ray+Ultrasound	CR+cast	Full	Varus 10°	4 m

Note: N/A = Not Available; CR = Closed Reduction; OR = Open Reduction; ROM = Range of Movement; \* = slightly reduced range of movement.

## Neonatal distal humeral physeal separation

cases had been only used splint or cast immobilization [1, 7, 19], and the final follow-up examination revealed normal bony alignment at the elbow and normal range of motion. 9 of 24 cases underwent closed reduction with splint or cast or collar and cuff immobilization [6-8, 10, 15, 17, 20, 22], and 3 of 9 cases showed a cubitus varus 10° and cubitus valgus 5° respectively and the elbow lacked 10° of extension [6, 7, 22], the follow-up in 2 of 9 cases were unknown [15, 17], 4 of 9 cases revealed normal bony alignment and normal range of motion [8, 10, 20]. 5 of 24 cases underwent open reduction with percutaneous pinning fixation and splint or cast immobilization [10, 13, 14, 18, 23]. 1 of 5 cases had a 20° lack of full extension [10], 1 of 5 cases had mild cubitus varus deformity [13], and 3 of 5 cases showed normal elbow [14, 18, 23]. Other 4 of 24 cases included 2 cases underwent traction [2, 21], and 2 cases with unknown treatment [4, 16]. 1 of 4 cases showed the elbow lacked 12° of extension [2]. 2 of 4 cases showed normal elbow [16, 21], the follow-up in 1 of 4 cases were unknown [4].

### Disclosure of conflict of interest

None.

**Address correspondence to:** Dr. Zhen-Jiang Liu, Department of Pediatric Orthopaedics, The Shengjing Hospital, China Medical University, Heping District, Shenyang, Liaoning Province, People's Republic of China. Tel: 18940259970; Fax: 0086-24-96615-57511; E-mail: ljzsdd@163.com

### References

- [1] Raupp P, Haas D and Lovasz G. Epiphyseal separation of the distal humerus. *J Perinat Med* 2002; 30: 528-530.
- [2] Downs DM and Wirth CR. Fracture of the distal humeral Chondroepiphysis in the neonate. A case report. *Clin Orthop Relat Res* 1982; 155-158.
- [3] DeLee JC, Wilkins KE, Rogers LF and Rockwood CA. Fractures eparation of the distal humeral epiphysis. *J Bone Joint Surg Am* 1980; 62: 46-51.
- [4] Sawant MR, Narayanan S, O'Neill K and Hudson I. Distal humeral epiphysis fracture separation in neonates-diagnosis using MRI scan. *Injury* 2002; 33: 179-181.
- [5] Oda R, Fujiwara H, Ichimaru K, Morihara T, Ikeda T and Kubo T. Chronic slipping of bilateral distal humeral epiphyses in a gymnast. *J Pediatr Orthop B* 2015; 24: 67-70.
- [6] Navallas M, Díaz-Ledo F, Ares J, Sánchez-Buenavida A, López-Vilchez MA, Solano A, García García J, Maiques JM, Mur-Sierra A and Alier A. Distal humeral epiphysiolysis in the newborn: utility of sonography and differential diagnosis. *Clin Imaging* 2013; 37: 180-184.
- [7] Jacobsen S, Hansson G and Nathorst-Westfelt J. Traumatic separation of the distal epiphysis of the humerus sustained at birth. *J Bone Joint Surg Br* 2009; 91: 797-802.
- [8] Sabat D, Maini L and Gautam VK. Neonatal separation of distal humeral epiphysis during Caesarean section: a case report. *J Orthop Surg (Hong Kong)* 2011; 19: 376-378.
- [9] Akbarnia BA, Silberstein MJ, Rende RJ, Graviss ER and Luisiri A. Arthrography in the diagnosis of fractures of the distal end of the humerus in infants. *J Bone Joint Surg Am* 1986; 68: 599-602.
- [10] Barrett WP, Almquist EA and Staheli LT. Fracture separation of the distal humeral physis in the newborn. *J Pediatr Orthop* 1984; 4: 617-619.
- [11] Bright RW, Burstein AH and Elmore SM. Epiphyseal-plate cartilage. A biomechanical and histological analysis of failure modes. *J Bone Joint Surg Am* 1974; 56: 688-703.
- [12] Abe M, Ishizu T, Nagaoka T and Onomura T. Epiphyseal separation of the distal end of the humeral epiphysis: a follow-up note. *J Pediatr Orthop* 1995; 15: 426-434.
- [13] Rose RE, Dixon R and Bullock R. Chondro-epiphyseal separation of the distal humerus in the newborn. A case report and review of the literature. *West Indian Med J* 2002; 51: 268-271.
- [14] Söyüncü Y, Cevikol C, Söyüncü S, Yildirim A and Akyildiz F. Detection and treatment of traumatic separation of the distal humeral epiphysis in a neonate: a case report. *Ulus Travma Acil Cerrahi Derg* 2009; 15: 99-102.
- [15] Ziv N, Litwin A, Katz K, Merlob P and Grunebaum M. Definitive diagnosis of fracture-separation of the distal humeral epiphysis in neonates by ultrasonography. *Pediatr Radiol* 1996; 26: 493-496.
- [16] Dias JJ, Lamont AC and Jones JM. Ultrasonic diagnosis of neonatal separation of the distal humeral epiphysis. *J Bone Joint Surg Br* 1988; 70: 825-828.
- [17] Paige ML and Port RB. Separation of the distal humeral epiphysis in the neonate. A combined clinical and roentgenographic diagnosis. *Am J Dis Child* 1985; 139: 1203-1205.
- [18] Macafee AL. Infantile supracondylar fracture. *J Bone Joint Surg Br* 1967; 49: 768-770.
- [19] Brown J and Eustace S. Neonatal transphyseal supracondylar fracture detected by ultrasonography. *Pediatr Emerg Care* 1997; 13: 410-412.

## Neonatal distal humeral physeal separation

- [20] Princic J, Tonin M and Ales A. Birth trauma as the cause of fracture of the distal epiphysis of the humerus. A case report. *Unfallchirurg* 1995; 98: 487-488.
- [21] Costa M, Owen-Johnstone S, Tucker JK and Marshall T. The value of MRI in the assessment of an elbow injury in a neonate. *J Bone Joint Surg Br* 2001; 83: 544-546.
- [22] Menon TJ. Fracture separation of the lower humeral epiphysis due to birth injury; a case report. *Injury* 1982; 14: 168-169.
- [23] Berman JM and Weiner DS. Neonatal fracture-separation of the distal humeral chondroepiphysis: a case report. *Orthopedics* 1980; 3: 875-879.
- [24] Davidson RS, Markowitz RI, Dormans J and Drummond DS. Ultrasonographic evaluation of the elbow in infants and young children after suspected trauma. *J Bone Joint Surg Am* 1994; 76: 1804-1813.
- [25] Nowicki PD and Duhn R. The use of arthrography in pediatric orthopaedic surgery. *J Am Acad Orthop Surg* 2014; 22: 472-481.