

Original Article

The role of pterional keyhole approach in the microsurgical clipping of anterior circulation artery aneurysms: experiences with 26 cases and literature review

Xiaojian Wang^{1*}, Jing Luo^{1*}, Ping Li^{2*}, Baochun Cheng¹, Zhifan Li¹, Hongwei Cheng¹

¹Department of Neurosurgery, The First Affiliated Hospital of Anhui Medical University, Hefei, Anhui 230022, China; ²Department of Neurosurgery, Anhui Provincial Hospital Affiliated to Anhui Medical University, Anhui Province Key Laboratory of Brain Function and Brain Disease, Hefei, Anhui 230001, China. *Equal contributors.

Received November 24, 2015; Accepted February 10, 2016; Epub March 15, 2016; Published March 30, 2016

Abstract: Background: Although the pterional approach is commonly used for microsurgical clipping of intracranial aneurysms of anterior circulation, the incision and temporalis muscle dissection impact postoperative recovery and cosmetic outcomes. The pterional keyhole approach offers similar microsurgical corridors with a substantially shorter incision, less muscle dissection, and a smaller craniotomy flap. The purpose of this study was to report our experience with the minimally invasive pterional keyhole approach in microsurgical clipping of anterior circulation aneurysms. Material and methods: Retrospective analysis was performed in 26 patients with anterior circulation aneurysms that were surgically treated via the pterional keyhole approach between January 2012 and June 2013. Various outcomes were recorded including clinical grade, cosmetic problems, patient satisfaction, and complications such as hyposmia and infection. Digital subtraction angiography (DSA) or computer tomography angiography (CTA) were used in follow-up analyses. Results: Anterior circulation aneurysms in all 26 patients were clipped successfully via the pterional keyhole approach. None of the patients died or experienced severe neurological dysfunction. No facial paralysis occurred due to damage of the facial nerve. DSA and CTA showed that the clipping through pterional keyhole approach was successful. Conclusion: The pterional keyhole approach reduced surgical trauma and complications and promoted recovery relative to surgery requiring a larger incision. This minimally invasive, safe, and effective surgical method approach was used successfully to treat 26 patients with anterior circulation artery aneurysms.

Keywords: Aneurysm, microsurgery, surgical clip

Introduction

Anterior circulation artery aneurysms (ACAAs) account for 3.2% of cerebral intracranial aneurysms [1]. These aneurysms occur adjacent to the front of the third ventricle, hypothalamus, optic chiasm, and other important brain structures. Microsurgical techniques now allow surgeons to clip the necks of these aneurysms. Keyhole techniques have also been developed, meaning that minimally invasive intracranial aneurysm surgery can be performed with good results.

Intracranial aneurysms can be treated with endovascular or microsurgical techniques. Pa-

tient outcomes at 1 year and incidence of later rebleeding showed no difference between the two methods [2]. In 2005, the International Subarachnoid Aneurysm Trial (ISAT) compared neurosurgical clipping versus endovascular coiling in 2,143 patients with ruptured intracranial aneurysms. Data from these patients led to the conclusion that the survival benefit of neurosurgical clipping continues for at least 7 years. The risk of late rebleeding is low for both techniques but is more common after endovascular coiling than after neurosurgical clipping [3]. Importantly, the microsurgical treatment is less expensive and is safer. Ning Lin and coworkers identified morphological parameter associated with anterior communicating artery

Table 1. Patient and aneurysm characteristics and recovery information

Number	M/F	Age (Years)	Location of aneurysm	Size (mm) length*width*neck	Hunt-Hess grade	GOS score pre-operation, post-operation outcome
1	F	37	ACoAA	7.2*6.9*4.3	SAH, II	15, good recovery
2	F	70	Left MCAA, M1	4.4*4.7*3.0	SAH, II	15, good recovery
3	M	22	ACoAA	4.5*5.0*3.0	SAH, I	15, good recovery
4	F	63	ACoAA	2.0*4.7*4.7	SAH, II	15, good recovery
5	F	44	Left MCAA, M1	3.0*3.0*2.5	SAH, II	15, good recovery
6	M	67	ACoAA	4.0*6.0*2.5	SAH, II	15, good recovery
7	F	60	Bilateral PCoAA	3.5*3.5*3.0 2.0*1.5*1.0	SAH, III	13, infarction paralysis aphasia
8	M	40	ACoAA	1.0*0.5*0.5	SAH, II	15, good recovery
9	M	57	ACoAA	2.5*3.5*2.5	SAH, II	15, good recovery
10	M	38	Right PCoAA	6.0*4.4*3.5	SAH, II	15, good recovery
11	F	52	Left MCAA, M2	6.0*4.5*4.0	SAH, II	15, good recovery
12	F	53	Left PCoAA	3.9*5.5*2.5	SAH, II	15, good recovery
13	F	51	Right PCoAA	4.5*3.2*2.5	SAH, II	15, good recovery
14	F	49	Left PCoAA	5.0*6.0*2.5	SAH, II	15, good recovery
15	M	70	Right PCoAA	3.5*4.5*4.0	SAH, II	15, good recovery
16	F	39	Right MCAA, M2	5.0*3.2*3.0	SAH, II	15, good recovery
17	F	33	Right MCAA, M1	5.5*4.5*4.0	SAH, II	15, good recovery
18	F	38	Right PCoAA	3.7*3.2*2.0	SAH, II	15, good recovery
19	M	49	ACoAA	2.5*2.5*1.0	SAH, I	15, good recovery
20	F	49	ACoAA	1.4*1.4*1.0	SAH, II	15, good recovery
21	M	62	Right MCAA, M2	4.0*2.0*2.0	SAH, I	15, good recovery
22	M	55	ACoAA	7.2*5.7*3.0	Unruptured, 0	15, good recovery
23	F	60	ACoAA	3.0*2.0*2.2	SAH, II	15, good recovery
24	M	46	ACoAA	2.7*2.0*1.8	SAH, I	15, good recovery
25	F	58	Bilateral PCoAA	7.0*4.0*2.5 1.0*1.5*1.0	SAH, II	15, good recovery
26	M	46	Left PCoAA	3.0*2.2*2.0	SAH, II	15, good recovery

ACoAA, anterior communicating artery aneurysm; PCoAA, posterior communicating artery aneurysm; MCAA, middle cerebral artery aneurysm.

aneurysm rupture [4]. These parameters may be used in conjunction with aneurysm size, location, and other demographic and clinical risk factors to aid in the prediction of the rupture risk.

The pterional approach is well-established for the treatment of a variety of intracranial pathologies including intracranial aneurysms [5-7]. Despite the advantages of the pterional craniotomy, there are several limitations such as potential for temporalis muscle atrophy and damage to the frontal branch of the facial nerve. Entirely different surgical approaches have also been described [8]. The pterional keyhole approach was developed as an alterna-

tive to the standard pterional approach; it uses similar surgical corridors through a smaller incision and craniotomy [9, 10]. Microsurgery via the pterional keyhole approach rather than use of the standard approach can reduce surgical trauma and promote recovery [11]. The keyhole approach is especially applicable for small, noncomplex aneurysms [12] and can be applied selectively to some patients with anterior circulation aneurysms [13, 14]. From January 2012 to June 2013, The department of neurosurgery of the First Affiliated Hospital of Anhui Medical University treated 26 patients using straight incision microsurgical pterional keyhole clipping of anterior circulation aneurysms. Satisfactory results were summarized and reported

Table 2. Characteristics of patients and anterior circulation aneurysms

Patient characteristics	
Female, n (%)	15 (57.7)
Male, n (%)	11 (42.3)
Mean age (years)	50.31
Mode of presentation	
SAH, n (%)	25 (96.2)
Incidental, n (%)	1 (3.8)
Partial seizures, n (%)	1 (3.8)
Headache, n (%)	25 (96.2)
Aneurysm locations	
Bilateral, n (%)	2 (7.7)
MCAA, n (%)	6 (23.1)
PCoAA, n (%)	7 (26.9)
ACoAA, n (%)	11 (42.3)
Multiple, n (%)	2 (7.7)
Aneurysm size	
Small (< 3 mm), n (%)	7 (25)
Medium (3-10 mm), n (%)	21 (75)
Large (> 10 mm), n (%)	0 (0)

as below as are the lessons learned during these surgeries.

Material and methods

Patients' selection

Patients' selection proceeded as follows: Patients were first screened for aneurysm location and presence of subarachnoid hemorrhage (SAH). Patients were treated using the pterional keyhole approach if they had middle cerebral artery aneurysms (MCAAs), anterior communicating artery aneurysms (ACoAAs), or posterior communicating artery aneurysms (PCoAAs). Patients with internal carotid artery (ICA) terminal aneurysms or basilar apex or superior cerebellar artery aneurysms were treated with standard pterional surgery.

General clinical information

Aneurysm clipping through the pterional keyhole approach was performed in 26 patients with a total of 28 anterior circulation aneurysms. Eleven patients had ACoAAs, nine patients had PCoAAs, six patients had MCAAs, and two patients had more than one aneurysm. Of the aneurysms, one was unruptured and 27 were ruptured. Preoperatively, four cases were grade

I on the Hunt-Hess scale, 20 were grade II, and one was grade III. Patient demographic data and aneurysm characteristics are summarized in **Tables 1** and **2**. Preoperative computer tomography angiography (CTA) showed SAH in 25 cases including four cases of combined frontal small hematoma, three cases of intraventricular hemorrhage, and two cases of temporal lobe hematoma. All patients underwent CTA or digital subtraction angiography (DSA) during the 1-year follow-up period.

Imaging examination

Preoperative DSA and CT examinations of the cerebral vascular and brain were performed in all patients. The findings revealed the location and the shape of the anterior circulation artery aneurysms in 26 patients. We also could judge the degree of the Hunt-Hess of patients and whether the patients were suitable for microsurgical clipping. In addition, postoperative DSA and CT examinations were performed in all patients. We evaluated the effect of the microsurgical clipping of the anterior circulation artery aneurysms via the pterional keyhole approach according to the imaging examination and the improvement of symptoms.

Microsurgical pterional keyhole approach

During surgery, the patients were supine and a DORO head frame was used to fix the head at a 15 to 20 degree angle. The zygomatic was processed at the highest point, based on aneurysm location; the rotation angle of the head was usually contralateral with rotation of between 15 and 20 degrees for ACoAAs and 45 to 60 degrees for PCoAAs and cerebral aneurysms. The skin on the operative side scalp was marked, and a straight vertical incision of 5 cm to 6 cm was made. The temporalis muscle incision was then made. The micro bone window craniotomy, or keyhole, was made by first drilling a small hole and then cutting a hole of diameter of about 2.5 to 3 cm. The dural incision was then made under fixed wire suspension. During surgery aneurysm separation and clipping was performed as in the standard pterional approach. Finally, the skull was closed with a titanium bone plate, lavaged with nimodipine diluted in normal saline (1:5), and the skin was sutured. No drainage tubes were used.

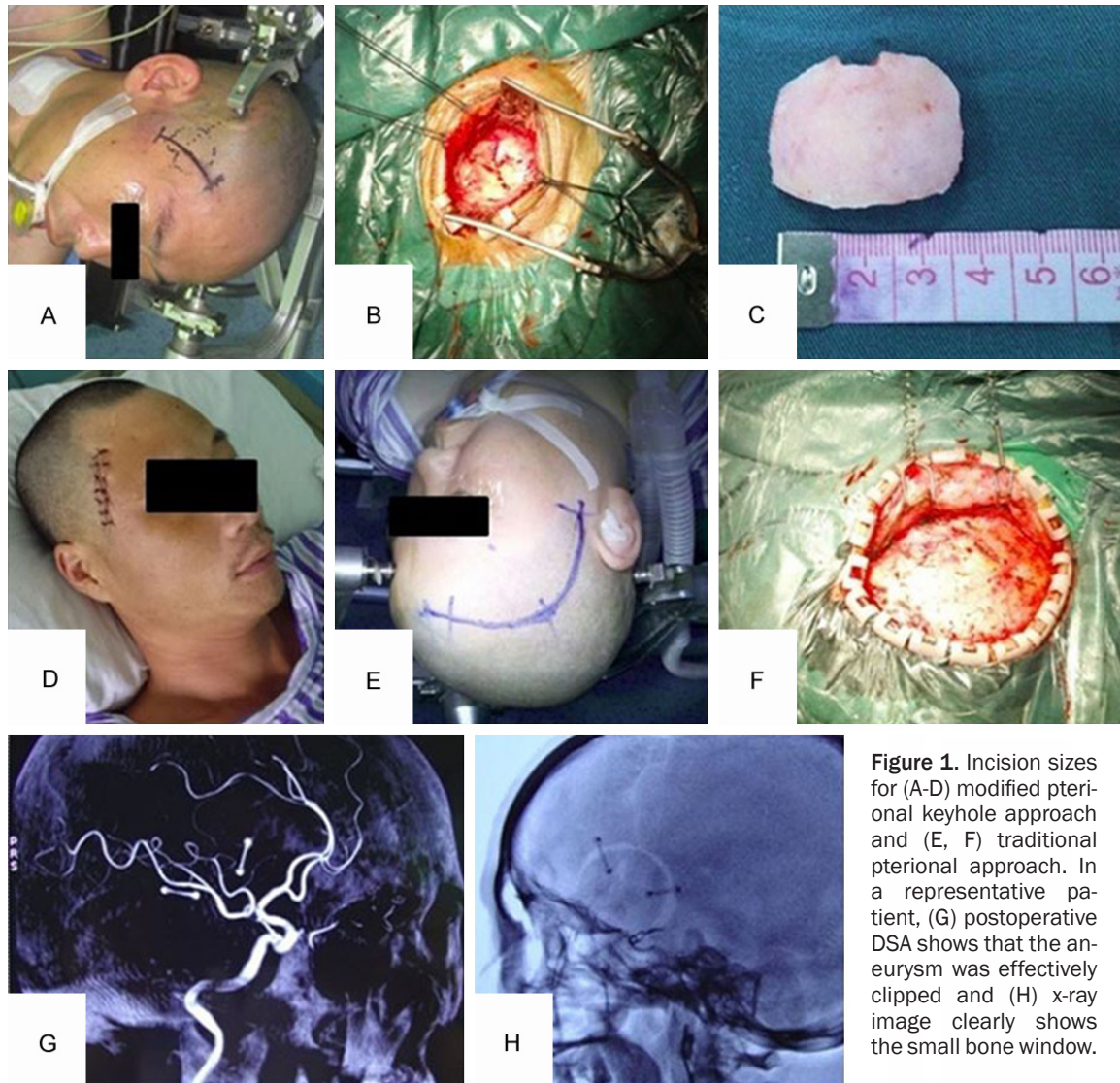


Figure 1. Incision sizes for (A-D) modified pterional keyhole approach and (E, F) traditional pterional approach. In a representative patient, (G) postoperative DSA shows that the aneurysm was effectively clipped and (H) x-ray image clearly shows the small bone window.

Results

Results, analyses, and follow up

Twenty patients underwent surgery in the acute phase (i.e., within 3 days after spontaneous SAH). Four patients were treated in the middle phase (i.e., 4 to 14 days after SAH), and two patients underwent surgery in the chronic phase (i.e., 15 days after SAH). One patient with no symptoms underwent the operation as an examination found an aneurysm.

Aneurysms in each of the 26 patients were successfully clipped via pterional keyhole approach. The skin lesions were small relative to incisions made using the traditional pterional approach (**Figure 1A-F**). Postoperative DSA for a representative patient shows that the aneu-

rysm was repaired using the keyhole approach (**Figure 1G**). An x-ray image of the same patient shows that the bone window was small (**Figure 1H**). In four cases, bleeding occurred during surgery. In these cases parent artery occlusion techniques were applied and severe ischemic brain damage did not occur. Operations lasted from 2.0 to 3.5 hours with an average of 2.5 hours. No patient had damage to the frontal branch of the facial nerve; this type of damage can cause facial paralysis.

After one year, all patients had recovered well. One cerebral aneurysm patient who had cerebral vasospasm, cerebral infarction, and hemiplegia and was treated with hyperbaric oxygen was nearly normal after one year. Whole brain or skull CTA or DSA was performed on each patient during follow up. These analyses indi-

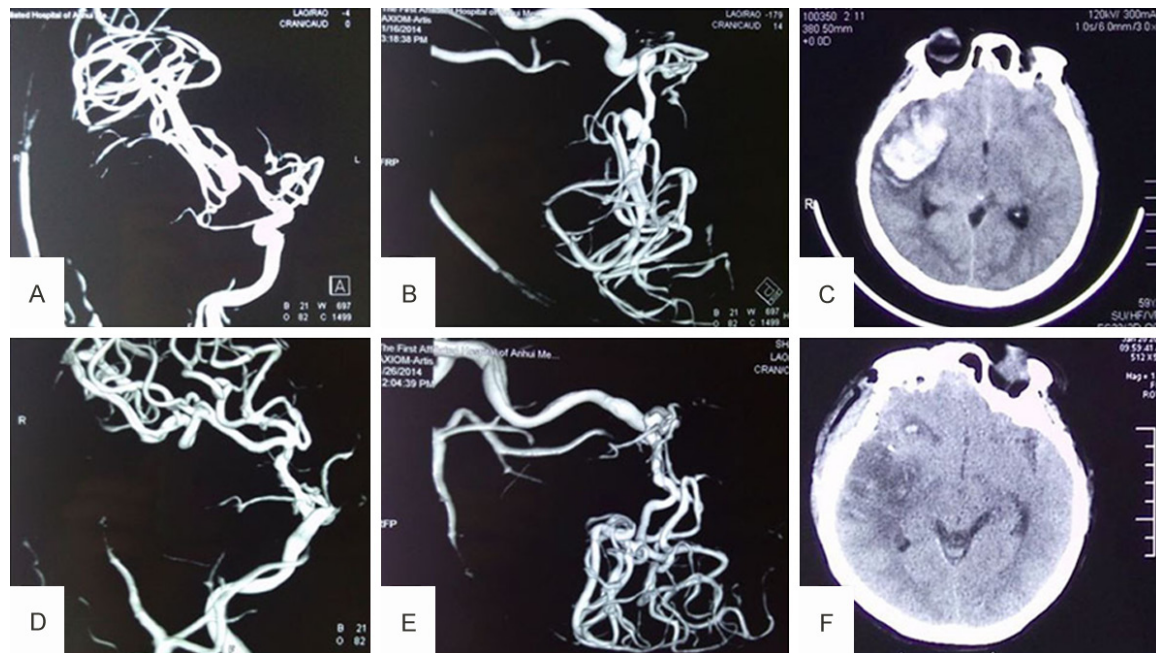


Figure 2. A patient with a right MCAA in the M2 segment was treated after 7 days of hemorrhage. Preoperative (A, B) DSA and (C) CT show SAH in the right temporal lobe and the MCAA. Postoperative (D, E) DSA and (F) CT show that the aneurysm was clipped and the hemorrhage removed.

cated that aneurysms were completely repaired; there were no cases of residual aneurysm recurrence or parent artery patency.

Clinical and therapeutic considerations

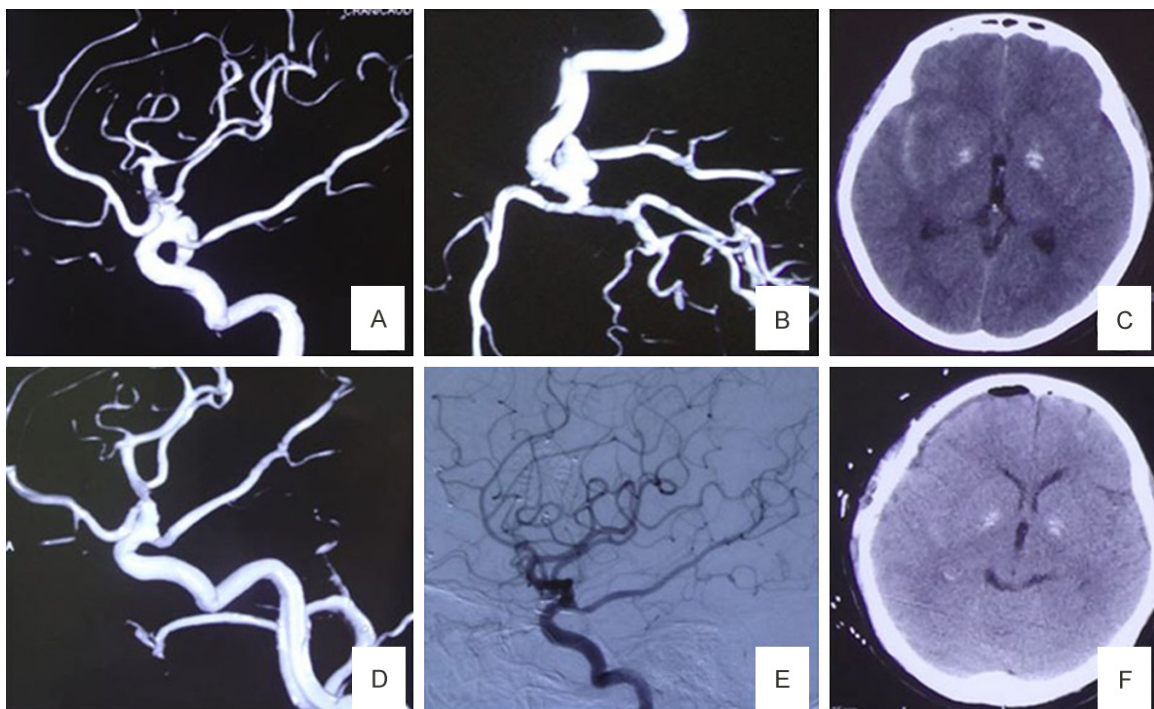
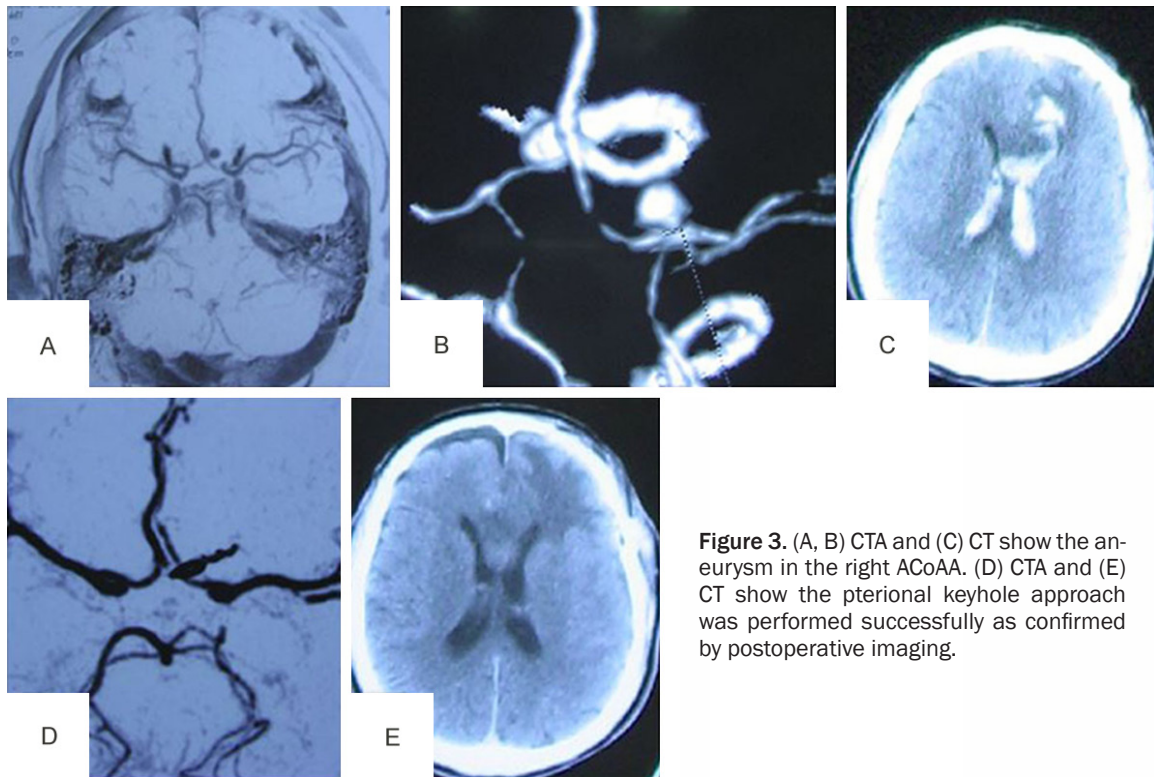
The position of intraoperative aneurysm rupture (IAR) has a significant impact on surgical outcome. When bleeding occurs at the neck of the aneurysm morbidity and mortality are increased relative to bleeding at other sites [15]. In one patient in this study, a right MCAA in the M2 segment that was irregular and lobulated aneurysm was detected by DSA (**Figure 2A, 2B**) and CT (**Figure 2C**). The patient was successfully treated after 7 days of hemorrhage using the pterional keyhole approach, as confirmed by postoperative DSA (**Figure 2D, 2E**) and CT (**Figure 2F**).

ACoAAs present frequently with SAH of small size. Patients with ACoAAs have high risk of rupture regardless of size. The aim in micro-neurosurgical management of an ACoAA is total occlusion of the aneurysm sac with preservation of flow in all branching and perforating arteries [16]. CTA (**Figure 3A, 3B**) and CT (**Figure 3C**) shows images of a patient with an ACoAA. The aneurysm was successfully repaired using the pterional keyhole approach as confirmed by postoperative CTA (**Figure 3D**) and CT (**Figure 3E**).

PCoAAs are very rare and have unique diagnostic features. The PCoA gives rise to a group of perforating arteries that irrigate the posterior limb of the internal capsule, the anterior third of the optic tract, the rostral midbrain, subthalamic nucleus, and ventral aspect of the thalamus. These patients sometimes present with ipsilateral infraction in those areas without any subarachnoid hemorrhage, regardless of the aneurysm size. The third cranial nerve is in close proximity to these aneurysms. Hence, giant PCoAAs can cause symptoms related to the third nerve dysfunction [17]. One of our patients, a 38-year-old male, had paroxysmal headache for more than 1 month prior to diagnosis. DSA (**Figure 4A, 4B**) and CT (**Figure 4C**) showed a PCoAA with a subarachnoid hemorrhage. A right pterional keyhole approach through a small bone window was used. DSA (**Figure 4D, 4E**), and CT (**Figure 4F**) images taken one day postoperatively clearly show that the aneurysm was clipped. This patient had attained a very good recovery after 1 year.

Discussion

The aim of keyhole surgery is to reduce unnecessary exposure or destruction of the brain structure and to minimize trauma during surgery [18, 19]. From our experience most anterior circulation aneurysms, including ACoAAs,



PCoAAs, and aneurysms located at M1 and M2 segments of the MCA, can be treated using the

pterional keyhole approach. For patients with severe subarachnoid hemorrhage and Hunt-

Hess grades IV or V, due to bleeding, secondary brain edema, cerebral vasospasm, or cerebral ischemia that could lead to uncontrollable intracranial hypertension, endovascular embolization, conventional craniotomy, or decompressive craniectomy pterional surgery is not recommended.

Compared with the traditional pterional approach, the smaller incision used for the pterional keyhole approach that can often be placed inside the hairline is cosmetically more appealing to patients. More importantly, the pterional keyhole approach reduces trauma, decreases damage of skin and soft tissue, limits exposure of the brain tissue, and reduces the risk of infection. The pterional keyhole dissection technique also limits damage to branches of the facial nerve and minimizes temporal muscle damage [20]. Compared with the traditional pterional approach, patients treated using the pterional keyhole have more rapid physical rehabilitation and spend fewer days in hospital resulting in lower costs. In our study, the two patients with multiple aneurysms were treated with a bilateral pterional keyhole approach and had little trauma and rapid recoveries. Paladino J et al. [21] analyzed the keyhole versus standard craniotomy in aneurysm surgery, and they indicated that the type of craniotomy is selected according to the experience of the surgical team, and familiarity with certain approach. The authors have good experience with the minimally invasive approach for different intracranial pathology and recommend it especially in neurovascular surgery.

The minimally invasive pterional keyhole approach is particularly suited for treatment of anterior circulation aneurysms. These patients require decompression of the oculomotor nerve, and good results were achieved in the patients with these aneurysms in our study. This technique also allows simultaneous intracranial hemorrhage removal and lavage of the surgical cavity with Nimotop solution to prevent or reduce cerebral vasospasm.

According to a previous report, the major risk of rebleeding occurs within 6 to 12 hours after SAH [22]. For aneurysms of Hunt-Hess grades I, II and III, most experts recommend surgery within 3 days. Patients with grades IV and V account for approximately 20-40% of patients with SAH, receiving surgery at different times

[23]; no patients with Hunt-Hess grades IV or V were treated in this study. Surgery early after rupture is not contra-indicated and might enable optimal treatment of vasospasm. Aneurysmal surgery, especially between 3-12 days following SAH, in the presence of asymptomatic pre-operative angiographic vasospasm can be associated with a good outcome; early surgery is not contraindicated and appears to result in better outcomes [24]. The advantages of early surgery include (I) prevention of rebleeding of the ruptured aneurysms; (II) prevention of delayed vasospasm due to clearing of subarachnoid and cerebral hemorrhages; (III) reductions in mortality and morbidity of patients with Hunt-Hess grades I, II, and III aneurysms and improvements in quality of life; and (IV) earlier initiation of rehabilitation therapy leading to greater functional recovery. Patients with stable vital signs may begin rehabilitation within 48 hours after surgery. For Hunt-Hess grades I and II aneurysms surgery should be carried out as soon as possible after diagnosis. Larger studies with long-term follow-up are necessary to determine the optimal treatment that leads to the highest rate of obliteration and best clinical outcomes.

Preoperative analysis and a detailed surgery plan are necessary prior to use of the pterional keyhole approach. The scalp incision for the pterional keyhole approach is shifted toward the bottom of the skull compared with the standard pterional approach and, thus, is closer to the area of the facial nerve [25]. To meet the needs of microsurgery and to avoid to damage the frontal branch of the facial nerve, we suggest that the incision should originate from the temple, pass inside the edge of hair, and end at the point of the ear, no more than 3.9 cm from the ear. None of the patients in our study cohort had facial paralysis due to facial nerve damage.

Tang C et al. [19] and Park HS et al. [26] indicated that supraorbital craniotomy to be effective and safe for anterior circulation aneurysms. Nevertheless, this approach cannot be a standard approach for all lesions, it can be applied to only very special aneurysms with an intense preop evaluation and the decision to approach these aneurysms by supraorbital craniotomies should be based on aneurysms features, size, growth pattern, and the surgeon's experience, some of the aneurysms with this approach to

be difficult. Previous studies have assessed that the pterional keyhole approach offers the same surgical possibilities as conventional pterional approaches for the treatment of anterior circulation aneurysms. Careful patient selection and sufficient opening of the sylvian fissure are the key points for good outcomes and the prevention of intraoperative complications [27]. Chalouhi N et al. [12] compared the pterional and the supraorbital keyhole approach in patients with ruptured anterior circulation aneurysms, they found that the pterional approach is associated with a lower rate of procedural complications and intraoperative aneurysm ruptures. Shorter operative time was the advantage of the supraorbital approach over the pterional approach. Although both techniques can be safely applied in aneurysm surgery, the pterional approach is a simple, reliable, and efficient procedure. The keyhole approach may be an acceptable alternative for neurosurgeons who have gained sufficient experience with the technique, especially for small noncomplex aneurysms.

Intraoperative aneurysm rupture (IAR) is a serious event that is difficult to manage. The site of IAR has a significant impact on surgical outcome [15]. Due to the small window in the skull used for the pterional keyhole approach, the operating space is limited, so the treatment of IAR is more difficult when using this approach than in traditional surgery. In order to prevent or facilitate handling of a rupture, application of a temporary occlusion may be necessary during surgery. If an aneurysm rupture occurs during opening of the lateral fissure or during separation of the parent artery, it is critical to maintain retraction of the frontal and temporal lobes and to use suction to reveal and control bleeding. There were four cases of aneurysm rupture during the separation of the parent artery in our study, temporary occlusion for from 4 to 8 minutes allowed us to fully reveal and clip the neck of aneurysm.

Only cases with Hunt-Hess grades I to III were treated with pterional keyhole surgery, as patient with Hunt-Hess grades IV and V level aneurysms may have significant brain swelling. In the process of surgery, we reduced risks due to intracranial pressure by dehydration and pre-treatment with diuretics or released the cerebrospinal fluid by puncture of the ventricle for external drainage. We also carefully separated

the lateral fissure of the cistern; this release of bloody cerebrospinal fluid lessened pressure and resulted in brain tissue collapse to achieve full exposure.

Conclusion

Microsurgical treatment is the main treatment for patients with intracranial aneurysms. From our experience with 26 patients with anterior circulation aneurysms of Hunt-Hess grades I, II, and III, the pterional keyhole approach is a good choice, but surgical skill and experience are important to success. In order to ensure benefit to the patient, it is first necessary that the aneurysm location, its size, shape, and neck morphology, and the relationships to the parent artery, collateral circulation, peripheral blood vessels, and surrounding bones are known prior to surgery. Successful pterional keyhole surgery requires significant preoperative planning. Secondly, it is important to perform surgery at a proper time after rupture. Finally, postoperative follow-up is also very important. Due to improvements in diagnostic imaging, advanced surgical instruments, and microsurgical skills, the keyhole pterional approach is an effective craniotomy technique in the hands of experienced neurosurgeons for the treatment of patients with ACAAs and with multiple aneurysms who do not have diffuse SAH, severe cerebral vasospasm, severe brain edema, or brain swelling. The surgery team must remain calm and have the capability to handle intraoperative incidents including IAR or brain swelling.

Acknowledgements

This work is supported by the National Key Technology R&D Program of the Ministry of Science and Technology of China (grant number 2011BAI08B06 (YM)) and the Anhui Provincial Natural Science Foundation (grant number 1308085QH151).

Disclosure of conflict of interest

None.

Abbreviations

ACAA, Anterior circulation artery aneurysm; ACoAA, Anterior communication artery aneurysm; CT, Computer tomography; CTA, Computer

tomography angiography; DSA, Digital subtraction angiography; GOS, Glasgow outcome scale; IAR, Intraoperative aneurysm rupture; ICAA, Internal carotid artery aneurysm; MCAA, Middle cerebral artery aneurysm; PCoAA, Posterior communicating artery aneurysm; SAH, Subarachnoid hemorrhage.

Address correspondence to: Xiaojian Wang, Department of Neurosurgery, The First Affiliated Hospital of Anhui Medical University, Hefei 230022, China. Tel: +86 13956047992; Fax: +86 0551 6292 2237; E-mail: wangxj2015q@sina.com

References

- [1] Deshmukh VR, Hott JS, Dumont T, Nakaji P and Spetzler RF. Treatment of recurrent previously coiled anterior circulation aneurysm with minimally invasive keyhole craniotomy: report of two cases. *Minim Invasive Neurosurg* 2006; 49: 70-73.
- [2] Qureshi AI, Janardhan V, Hanel RA and Lanzino G. Comparison of endovascular and surgical treatments for intracranial aneurysms: an evidence-based review. *Lancet Neurol* 2007; 6: 816-825.
- [3] Molyneux AJ, Kerr RS, Yu LM, Clarke M, Sneade M, Yarnold JA and Sandercock P. International subarachnoid aneurysm trial (ISAT) of neurosurgical clipping versus endovascular coiling in 2143 patients with ruptured intracranial aneurysms: a randomised comparison of effects on survival, dependency, seizures, rebleeding, subgroups, and aneurysm occlusion. *Lancet* 2005; 366: 809-817.
- [4] Lin N, Ho A, Charoenvimolphan N, Frerichs KU, Day AL and Du R. Analysis of morphological parameters to differentiate rupture status in anterior communicating artery aneurysms. *PLoS One* 2013; 8: e79635.
- [5] Yasargil MG and Fox JL. The microsurgical approach to intracranial aneurysms. *Surg Neurol* 1975; 3: 7-14.
- [6] Figueiredo EG, Oliveira AM, Plese JP and Teixeira MJ. Perspective of the frontolateral craniotomies. *Arq Neuropsiquiatr* 2010; 68: 430-432.
- [7] Ngando HM, Maslehaty H, Schreiber L, Blaeser K, Scholz M and Petridis AK. Anatomical configuration of the Sylvian fissure and its influence on outcome after pterional approach for microsurgical aneurysm clipping. *Surg Neurol Int* 2013; 4: 129.
- [8] Nathal E and Gomez-Amador JL. Anatomic and surgical basis of the sphenoid ridge keyhole approach for cerebral aneurysms. *Neurosurgery* 2005; 56: 178-185; discussion 178-185.
- [9] Figueiredo EG, Deshmukh P, Nakaji P, Crusius MU, Crawford N, Spetzler RF and Preul MC. The minipterional craniotomy: technical description and anatomic assessment. *Neurosurgery* 2007; 61: 256-264; discussion 264-255.
- [10] Caplan JM, Papadimitriou K, Yang W, Colby GP, Coon AL, Olivi A, Tamargo RJ and Huang J. The minipterional craniotomy for anterior circulation aneurysms: initial experience with 72 patients. *Neurosurgery* 2014; 10 Suppl 2: 200-207.
- [11] Mocco J, Komotar RJ, Raper DM, Kellner CP, Connolly ES and Solomon RA. The modified pterional keyhole craniotomy for open cerebrovascular surgery: a new workhorse? *J Neurol Surg A Cent Eur Neurosurg* 2013; 74: 400-404.
- [12] Chalouhi N, Jabbour P, Ibrahim I, Starke RM, Younes P, El Hage G and Samaha E. Surgical treatment of ruptured anterior circulation aneurysms: comparison of pterional and supraorbital keyhole approaches. *Neurosurgery* 2013; 72: 437-441; discussion 441-432.
- [13] Fischer G, Stadie A, Reisch R, Hopf NJ, Fries G, Bocher-Schwarz H, van Lindert E, Ungersbock K, Knosp E, Oertel J and Perneczky A. The keyhole concept in aneurysm surgery: results of the past 20 years. *Neurosurgery* 2011; 68: 45-51; discussion 51.
- [14] Park J, Woo H, Kang DH, Sung JK and Kim Y. Superciliary keyhole approach for small unruptured aneurysms in anterior cerebral circulation. *Neurosurgery* 2011; 68: 300-309; discussion 309.
- [15] Zhen Y, Yan K, Zhang H, Zhao S, Xu Y, Zhang H, He L and Shen L. Analysis of the relationship between different bleeding positions on intraoperative rupture anterior circulation aneurysm and surgical treatment outcome. *Acta Neurochir (Wien)* 2014; 156: 481-491.
- [16] Hernesniemi J, Dashti R, Lehecka M, Niemela M, Rinne J, Lehto H, Ronkainen A, Koivisto T and Jaaskelainen JE. Microneurosurgical management of anterior communicating artery aneurysms. *Surg Neurol* 2008; 70: 8-28; discussion 29.
- [17] Kocak B, Tureci E, Kizilkilic O, Islak C and Kocer N. Dissecting aneurysms of posterior communicating artery itself: anatomical, diagnostic, clinical, and therapeutical considerations. *Neuroradiology* 2013; 55: 1103-1112.
- [18] Lan Q, Gong Z, Kang D, Zhang H, Qian Z, Chen J and Huang Q. Microsurgical experience with keyhole operations on intracranial aneurysms. *Surg Neurol* 2006; 66 Suppl 1: S2-9.
- [19] Tang C, Sun J, Xue H, Yu Y and Xu F. Supraorbital keyhole approach for anterior circulation aneurysms. *Turk Neurosurg* 2013; 23: 434-438.
- [20] McLaughlin N, Cutler A and Martin NA. Technical nuances of temporal muscle dissection

- and reconstruction for the pterional keyhole craniotomy. *J Neurosurg* 2013; 118: 309-314.
- [21] Paladino J, Mrak G, Miklic P, Jednacak H and Mihaljevic D. The keyhole concept in aneurysm surgery—a comparative study: keyhole versus standard craniotomy. *Minim Invasive Neurosurg* 2005; 48: 251-258.
- [22] Khandelwal P, Kato Y, Sano H, Yoneda M and Kanno T. Treatment of ruptured intracranial aneurysms: our approach. *Minim Invasive Neurosurg* 2005; 48: 325-329.
- [23] Zhang Q, Ma L, Liu Y, He M, Sun H, Wang X, Fang Y, Hui XH and You C. Timing of operation for poor-grade aneurysmal subarachnoid hemorrhage: study protocol for a randomized controlled trial. *BMC Neurol* 2013; 13: 108.
- [24] McLaughlin N and Bojanowski MW. Aneurysmal surgery in the presence of angiographic vasospasm: an outcome assessment. *Can J Neurol Sci* 2006; 33: 181-188.
- [25] Mori K, Osada H, Yamamoto T, Nakao Y and Maeda M. Pterional keyhole approach to middle cerebral artery aneurysms through an outer canthal skin incision. *Minim Invasive Neurosurg* 2007; 50: 195-201.
- [26] Park HS, Park SK and Han YM. Microsurgical experience with supraorbital keyhole operations on anterior circulation aneurysms. *J Korean Neurosurg Soc* 2009; 46: 103-108.
- [27] Yamahata H, Tokimura H, Tajitsu K, Tsuchiya M, Taniguchi A, Hirabaru M, Takayama K, Shinsato T, Hirayama T and Arita K. Efficacy and safety of the pterional keyhole approach for the treatment of anterior circulation aneurysms. *Neurosurg Rev* 2014; 37: 629-636.