

## Original Article

# Reconstruction of orbital blowout fractures using MEDPOR titanium mesh implants

Xiaohui Han, Shunhai Yang, Zhizhang Dong, Wangqiang Feng

*Department of Ophthalmology, The Second Affiliated Hospital of Wenzhou Medical University, Wenzhou 325000, China*

Received November 8, 2015; Accepted March 31, 2016; Epub June 15, 2016; Published June 30, 2016

**Abstract:** The aim of this study was to evaluate the use of titanium mesh (MEDPOR®TITAN™) implants in the surgical reconstruction of orbital blowout fractures. A total of 19 patients with orbital blowout fractures as confirmed with computed tomography who underwent orbital reconstruction with MEDPOR®TITAN™ implants were evaluated in this study. Postoperative wound healing, vision, eye position, and occurrence of enophthalmos were evaluated and compared. The wounds healed well, and follow-up examination did not show prolapsed or rejected implants. Of 13 cases of diplopia, 11 resolved, 1 persisted but was less severe, and 1 showed no improvement. Surgery did not affect vision, and no significant visual acuity changes were observed. In general, patients were better postoperatively. Eye position improved and all eye movements returned to normal, although 1 case had residual esotropia and diplopia. A total of 19 cases of postoperative enophthalmos were corrected to varying degrees, 15 cases of enophthalmos underwent full correction of protruding eyes, and 4 cases still had mild retraction averaging  $0.55 \pm 0.1$  mm compared with preoperative enophthalmos, which increased by 1.5 mm to 2 mm. Pre- and postoperative differences were statistically significant. Complications of orbital blowout fractures should be treated early via surgery. A titanium mesh (MEDPOR®TITAN™) implant is an excellent material for reconstruction of the orbital wall.

**Keywords:** Orbital blow-out fracture, titanium mesh (MEDPOR®TITAN™), implantation

## Introduction

The incidence of traffic accidents, industrial injuries, and traumatic orbital fractures has increased annually. Thus, orbital blowout fractures are commonly seen in clinical trauma [1]. An orbital blowout fracture undermines the integrity of the extraocular muscles and is often accompanied by incarceration, which results in enophthalmos, eye movement disorders, orbital deformities, and diplopia. Orbital reconstruction is performed to improve appearance and correct visual function. The area around the eye and its anatomical structure are very complicated. Thus, effectively rebuilding the orbital anatomy of the eye to restore visual function can be difficult. In recent years, our hospital has been utilizing a MEDPOR composite titanium mesh for orbital wall reconstruction in patients with orbital blowout fractures, and the results have been favorable.


## Materials and methods

### General information

From January to July 2012, 19 eyes of 19 patients were treated for orbital blowout fractures (**Table 1**). Of these, 8 involved the right eye, and 11 the left eye. Of 19 subjects, 14 were male and 5 were female, aged 12 to 45 years, with a median age of 30 years. The cases included 10 due to car accidents, 6 due to inflicted injury, 2 due to blunt impact injury, and 1 due to a fall. The fracture types included 12 simple orbital blowout fractures, with 5 cases of orbital wall and 7 cases of orbital floor fracture, and 7 cases with combined floor and orbital medial wall fracture. The mean preoperative visual acuity was 20/30. The interval between injury and surgery was 2 to 4 weeks. This study was conducted in accordance with the declaration of Helsinki. This study was conducted with

**Table 1.** Demographic information and clinic feature of included patients

No.	Sex	Age	Causes of injury	Fracture types
1	male	12	car accident	orbital floor fracture
2	male	33	inflicted injury	orbital floor fracture
3	male	45	inflicted injury	orbital wall fracture
4	male	30	car accident	orbital floor fracture
5	male	22	inflicted injury	orbital floor fracture
6	male	24	car accident	orbital wall fracture
7	male	31	car accident	Combined fracture
8	male	35	car accident	orbital floor fracture
9	male	38	car accident	orbital floor fracture
10	male	40	inflicted injury	orbital floor fracture
11	male	20	inflicted injury	Combined fracture
12	male	33	car accident	orbital wall fracture
13	male	27	car accident	orbital wall fracture
14	male	30	blunt impact injury	Combined fracture
15	female	25	blunt impact injury	Combined fracture
16	female	35	car accident	Combined fracture
17	female	27	car accident	Combined fracture
18	female	33	inflicted injury	orbital wall fracture
19	female	30	falling	Combined fracture



**Figure 1.** MEDPOR composite titanium mesh.

approval from the Ethics Committee of Second Affiliated Hospital of Wenzhou Medical University. Written informed consent was obtained from all participants.

## Clinical examination

All patients underwent a comprehensive examination, which included visual acuity testing, slit-lamp examination, and indirect ophthalmoscopy. In addition, the degree of proptosis, eye position, computed tomography (CT) and visual evoked potential (VEP) testing were also neces-

sary. A standard logarithmic visual inspection table provided preoperative and postoperative corrected visual acuity. A Hertel exophthalmos meter was used three times for each patient to measure enophthalmos, and recorded measurements of orbital distance were averaged. The degree of strabismus was measured by the same examiner.

CT clearly showed the fracture location, extent, size of fracture fragments, and shifting, as well as soft tissue changes and cumulative fracture-related optic nerve damage. Pre- and postoperative CT was performed by using horizontal and coronal orbital line scans and conventional three-dimensional reconstruction. VEP examination was performed to exclude clear cases of optic nerve damage.

## Procedures

All patients underwent general anesthesia. A subconjunctival incision was made for orbital wall and floor fractures about 4 mm from the lower edge of the lower tarsal conjunctiva, extending about 1 cm parallel to the lower edge of the tarsal conjunctival incision. Blunt dissection was performed to expose the orbital septum, followed by angled separation of the septum with gradual forward separation of the orbital margin. A transverse incision was made at the edge of the orbital periosteum along the inferior orbital wall and the periosteum was peeled back to expose the fracture of the orbital separation zone into the sinus. Bone chips were removed after periosteal stripping, with careful separation of incarcerated orbital soft tissue, followed by final resetting to fit the MEDPOR composite titanium mesh (Porex Surgical) (**Figure 1**), which was trimmed to an appropriate size and shape. Subperiosteal bone defects were filled in, and the mesh was fixed in the orbital rim with titanium screws. Proptosis was measured to determine whether the degree of eye protrusion was equal or if there was overcorrection by 1 mm. Traction testing showed rectus activity with no soft tissue impaction. The periosteum was sutured, followed by continuous suturing of the conjunctival incision. Finally, a pressure bandage was placed [2].

**Table 2.** Degree Enophthalmos patients before and after comparison (number of eyes)

	0 mm	1 mm	2 mm	3 mm	4 mm	5 mm	6 mm
Preoperative	0	0	18	1	0	0	0
Postoperative	15	3	1	0	0	0	0

## Follow-up

All patients had follow-up examinations after surgery. The schedule of follow-up varied, but the average time was 12 months postoperatively. A Hertel exophthalmos meter showed prominent differences in proptosis between pre- and postoperative states at the same orbital distance.

## Statistical analysis

All statistical analyses were conducted using SPSS software version 17.0. The Kolmogorov-Smirnov test was used to test the distribution type (Gaussian or non-Gaussian) of all continuous variables. The data were presented as mean  $\pm$  standard deviation (SD) for normally distributed continuous numeric variables.

Degrees of exophthalmos were compared pre- and postoperatively using the Wilcoxon signed-rank test. A difference of  $P \leq 0.05$  was considered statistically significant.

## Results

### Visual function status

Of 14 patients with preoperative diplopia, 12 were treated successfully by surgery, 1 had varying degrees of diplopia, and 1 had uncorrected diplopia which affected binocular vision. The mean postoperative visual acuity was 20/30. No vision loss occurred.

### Eye position status

Normal preoperative primary position was seen in 16 cases. One case had an internal oblique problem, 1 had an eye in downward position, and 1 had esotropia. Postoperative eye movement in all primary directions relative to eye position with level gaze was normal in 18 patients.

### Enophthalmos

All patients had  $\geq 2$  mm preoperative retraction with an average of  $2.7 \pm 0.5$  mm. Early postop-

erative conjunctival edema was caused by swelling of the eye and slight protrusion of the orbital tissue. About 1 week after tissue edema and swelling subsided, the patients were treated to correct varying degrees of enophthalmos. A

total of 15 cases of enophthalmos were completely corrected with consistent degrees of binocular prominence; 2 cases had residual mild retraction, with an average of  $0.55 \pm 0.1$  mm compared with preoperative enophthalmos, which increased by 1.5 to 2 mm ( $P < 0.001$ ) (Table 2).

### CT examination

Preoperative CT was done to confirm orbital fracture type, whereas postoperative examination was done for implant location and assessment of orbital wall repair (Figure 2). No implant prolapse was seen.

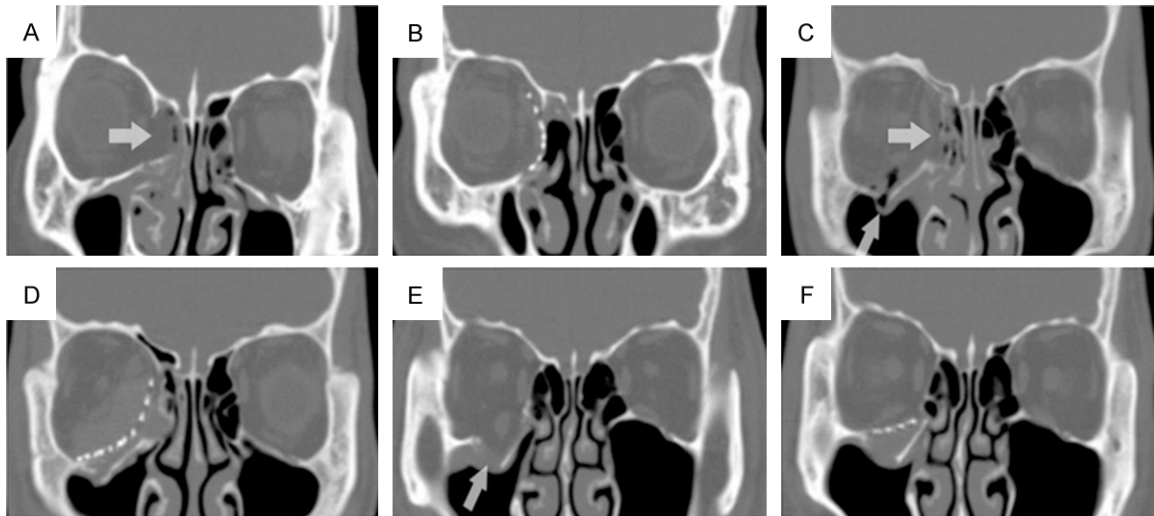
### Incision status

Incisions healed without implant extrusion, rejection, or loss of vision.

## Discussion

Traumatic orbital blowout fracture [3] is often accompanied by orbital soft tissue impaction and orbital volume change associated with visual dysfunction. Clinical research has focused on how to deal effectively with orbital blowout fractures and their complications [4]. High-resolution CT was used to perform axial scanning without anatomical structure overlap. CT was coupled with Multiplanar Reconstruction (MPR) imaging technology to provide early and effective diagnosis of right orbital fracture pathology [5].

The definite diagnosis of orbital blowout fracture and the timing of surgical intervention have been controversial [6]. Surgery may be considered: 1) if the orbital blowout fracture is found in the adjacent orbital tissue cavity or in the paranasal sinus, or if fracture impaction is observed in crevices, or there is diplopia formation, eye movement disorder, eye position change, or a positive extraocular muscle traction test, with no significant improvement after one week of treatment; 2) with collapse of the orbital rim and orbital deformities; 3) or with the presence of eyeball retraction. No uniform



**Figure 2.** CT views showed the pre-operative orbital fractures and the position and shape of the titanium mesh post-operatively. It was a 24-year-old male patient with car accident. He had medial and inferior orbital fracture. A: Preoperative axial computed tomography views of patient; B: Preoperative coronal computed tomography views of patient; C: Postoperative axial computed tomography views of patient; D: Postoperative coronal computed tomography; E: 3-D computed tomogram demonstrating TITAN implant position. F: Postoperative orbital wall fracture under (coronal). (The arrow head pointing out the changes after the surgery).

standard currently exists for surgery based on the degree and extent of strabismus and enophthalmos. Lee and Chiu [7] reported that the orbital cavity volume expands to 8% in normal surgical indications. This study adopts the perspective of Song Guoxiang, which considers surgery if the enophthalmos is  $\geq 2$  mm [8]. In the present study, patients underwent surgery 2 to 4 weeks after injury, when early inflammatory edema had subsided and hemorrhage was mostly absorbed. The delay is not more than four weeks to avoid disrupting the late development of fibrosis, which could affect the outcome. We compared the values for preoperative retraction, which were  $\geq 2$  mm, with an average of  $2.2 \pm 0.5$  mm and a mean postoperative retraction of  $0.55 \pm 0.1$  mm, which indicates enophthalmos improvement compared with preoperative values of 1.5 to 2 mm. The results suggest that the degree of enophthalmos can be used as an indicator for surgery. Postoperative changes in values for less depression are feasible treatment indicators. Unfortunately, we could not make further calculations for pre- and postoperative volume changes because of the limitations of our instruments.

In addition to orbital wall repair with an implant, orbital wall reconstruction was performed to

completely treat orbital fractures [9-11]. In the repair of an orbital defect, the filling materials used are mainly autologous bone, hydroxyapatite, and MEDPOR tablets [12-14]. The application and postoperative results may be affected by the novelty of the method, severity of trauma, difficulties in shaping and grinding hard material, poor fixation, tendency to shift, and inability to recover after surgery. MEDPOR repair composite filling materials containing titanium mesh have good tissue compatibility with minimal postoperative reactions such as infection and rejection. The material is also easy to shape, and communication through micropores firmly bonds bone tissue so that the surrounding tissue can grow effectively with good blood supply. The material is simple to use, and fixation is easy [15, 16]. Although not used often, MEDPOR composite titanium mesh orthopedic implant materials are ideal for orbital blowout fracture reconstruction. This study used a conjunctival incision for orbital wall surgical repair. The use of MEDPOR composite titanium mesh implant surgery with titanium screw fixation promotes wound healing without implant extrusion or rejection and no vision loss. The implant was also fixed correctly as confirmed by CT, which suggests that MEDPOR composite titanium mesh can be applied in treating orbital blowout fractures.



In addition, enophthalmos improved. Analysis of visual acuity and eye position through intra-operative and postoperative visual acuity monitoring was done. Surgery should be done carefully to avoid brain plate traction and pressure on the eye, and to avoid irritation and damage to the optic nerve so that sudden loss of vision is prevented. Visual acuity showed no significant change postoperatively, which corresponds to other reports [10, 17]. However, postoperative eye position was improved after removing embedded tissue and correcting orbital volume [18]. If computer navigation guidance is used with real-time CT image display, repair of the orbital structure can be more accurate [19]. The results suggest that MEDPOR composite titanium mesh used in orbital blowout fractures can significantly improve clinical symptoms. Therefore, its clinical application can be recommended.

## Disclosure of conflict of interest

None.

**Address correspondence to:** Wangqiang Feng, Department of Ophthalmology, The Second Affiliated Hospital of Wenzhou Medical University, No. 109 Xueyuan West Road, Wenzhou 325000, China. Tel: +86 577 88002816; Fax: +86 577 88009100; E-mail: wangqiangfengcn@163.com

## References

- [1] Cağatay HH, Ekinci M, Pamukcu C, Oba ME, Akçal Özcan A and Karşıdağ S. Retrospective analysis of 132 patients with orbital fracture. *Ulus Travma Acil Cerrahi Derg* 2013; 19: 449-455.
- [2] Xiao W, Chen Y, Luo Q, Liu H and Zhang L. Clinical application of transconjunctival approach to treat orbitozygomatic complex fractures. *Hua Xi Kou Qiang Yi Xue Za Zhi* 2013; 31: 169-171.
- [3] Shin JW, Lim JS, Yoo G and Byeon JH. An analysis of pure blowout fractures and associated ocular symptoms. *J Craniofac Surg* 2013; 24: 703-707.
- [4] Shah HA, Shipchandler TZ, Sufyan AS, Nunery WR and Lee HB. Use of fracture size and soft tissue herniation on computed tomography to predict diplopia in isolated orbital floor fractures. *Am J Otolaryngol* 2013; 34: 695-698.
- [5] Wang Z, Yin Z, Wei S, Gong Y and Chen X. Application of preformed orbital titanium mesh in reconstruction of orbital fracture. *Nan Fang Yi Ke Da Xue Xue Bao* 2013; 33: 1071-1074.
- [6] Winters R, Chastant R and Graham HD 3rd. When is immediate surgical intervention required for isolated orbital blowout fractures? *Laryngoscope* 2014; 124: 585-586.
- [7] Jacono AA and Moskowitz B. A lloplastic implants for orbital wall reconstruction. *Facial Plast Surg* 2000; 16: 63-68.
- [8] Zhang Z, Zhang Y, He Y, An J and Zwahlen RA. Correlation between volume of herniated orbital contents and the amount of enophthalmos in orbital floor and wall fractures. *J Oral Maxillofac Surg* 2012; 70: 68-73.
- [9] Kyung H, Song SH, Kang N and Oh SH. Medpor implant fixation using fibrin glue in blowout fracture surgery. *J Craniofac Surg* 2013; 24: 1781-1784.
- [10] Banica B, Ene P, Vranceanu D and Ene R. Titanium preformed implants in orbital floor reconstruction - case presentation, review of literature. *Maedica (Buchar)* 2013; 8: 34-39.
- [11] Strong EB, Fuller SC, Wiley DF, Zumbansen J, Wilson MD and Metzger MC. Preformed vs intraoperative bending of titanium mesh for orbital reconstruction. *Otolaryngol Head Neck Surg* 2013; 149: 60-66.
- [12] Sakamoto Y, Shimizu Y, Nagasao T and Kishi K. Combined use of resorbable poly-L-lactic acid-polyglycolic acid implant and bone cement for treating large orbital floor fractures. *J Plast Reconstr Aesthet Surg* 2014; 67: e88-90.
- [13] Pereira Rdos S, Jorge-Boos FB, Hochuli-Vieira E, da Rocha HV Jr, Homsy N and de Melo WM. Management of pure medial orbital wall fracture with autogenous bone graft. *J Craniofac Surg* 2013; 24: 475-477.
- [14] Insull EA, Hart RH, Sloan BH, Ben-Simon GJ and McNab AA. Use of x-ray film implant for the repair of orbital fractures. *Ophthal Plast Reconstr Surg* 2013; 29: 393-395.
- [15] Tabrizi R, Ozkan TB, Mohammadinejad C and Minaee N. Orbital floor reconstruction. *J Craniofac Surg* 2010; 21: 1142-1146.
- [16] Mihora LD and Holck DE. Hematic cyst in a barrier-covered porous polyethylene/titanium mesh orbital floor implant. *Ophthal Plast Reconstr Surg* 2011; 27: 117-118.
- [17] Gunarajah DR and Samman N. Biomaterials for repair of orbital floor blowout fractures: a systematic review. *J Oral Maxillofac Surg* 2013; 71: 550-570.
- [18] Kersey TL, Ng SG, Rosser P, Sloan B and Hart R. Orbital adherence with titanium mesh floor implants: a review of 10 cases. *Orbit* 2013; 32: 8-11.
- [19] Bly RA, Chang SH, Cudejkova M, Liu JJ and Moe KS. Computer-guided orbital reconstruction to improve outcomes. *JAMA Facial Plast Surg* 2013; 15: 113-120.