

## Original Article

# Transconjunctival fat reposition with septal reset for the treatment of tear trough

Chiaoyun Chiu, Yichen Shen, Qingfang Zhao, Yijia Yu, Yang Wang, Jinghong Xu

Department of Plastic Surgery, The First Affiliated Hospital, Zhejiang University, No. 79, Qingchun Rd., Hangzhou 310003, Zhejiang Province, China

Received November 10, 2015; Accepted April 23, 2016; Epub June 15, 2016; Published June 30, 2016

**Abstract:** To offer an alternative operation as a method of fat repositioning via a transconjunctival approach. This is a safe and effective alternative surgical approach to Hamra's transcutaneous approach when obvious external scars are not acceptable. This approach should be limited to patients who do not have any obvious excessive lower eyelid skin or muscle laxity. The method of fat reposition with septal reset in transconjunctival lower blepharoplasty was used to correct tear trough deformity. Lower eyelid fat repositioning with septal reset during transconjunctival lower blepharoplasty was used to correct tear trough deformities on young Asian patients who did not want external scars. In the 34 patients of Barton's grade I, with 30 cases (88.2%) improving to grade 0, and 4 cases (11.8%) having no improvement. In the 38 patients of Barton's grade II, with 29 cases (76.3%) improving to grade 0, 9 cases (23.7%) improving to grade I. In the 12 patients of Barton's grade III, with 3 patients (25%) improving to grade 0, 8 cases (66.6%) improving to grade I, 1 cases (8.4%) improving to grade II. The case study demonstrated that the method of fat reposition with septal reset in transconjunctival lower blepharoplasty is optimal. However, it is important to notice that the indication is narrow.

**Keywords:** Lower blepharoplasty, orbital fat reposition, septal reset, tear trough, transconjunctival route

## Introduction

Intensive studies indicated that the periorbital aging is resulted from combined action of various factors like inherited anatomic differences and aging. As concave deformity in infraorbital region has become a noticeable sign of periorbital aging, more and more people have become concerned about the lower eyelid rejuvenation, especially tear trough deformity correction.

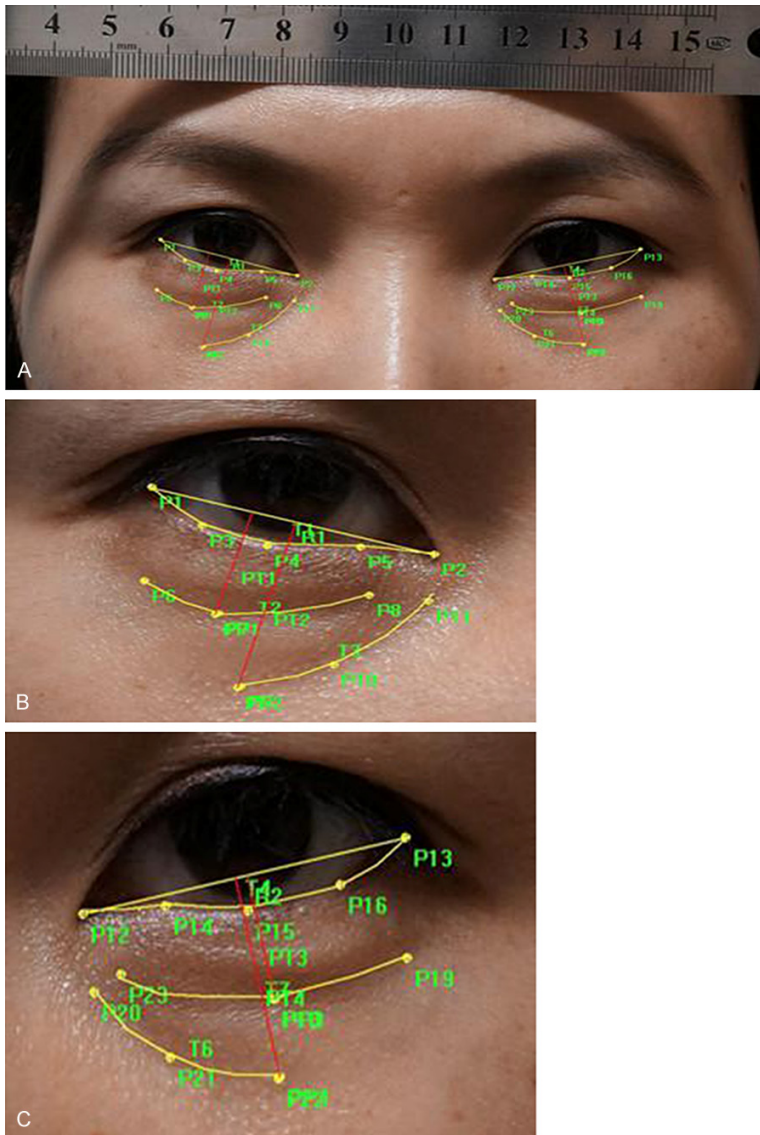
The surgical treatment for tear trough deformity is developed based on lower blepharoplasty. Although conventional lower blepharoplasty by removal of lower eyelid fat could significantly improves the protruded symptom, in the cases of lower eyelid with tear trough deformity, the techniques can create a concave contour, which makes the depression below the lower eyelid more obvious [1]. Loeb first proposed the fat pad sliding technique where orbital fat was transferred and filled to the depressed area [2]. Based on Loeb deformity, the techniques can create a concave contour, which makes the

depression below the lower eyelid more obvious periorbital concave contour. Repositioning the lower eyelid fat over or behind the orbital rim more specifically addresses changes in eyelid contour to create a more youthful, pleasing appearance [3]. This technique is performed in a subciliary skin incision and with suspension of orbicularis oculi. Barton improved the method to "Fat Extrusion and Septal Reset" [4]. And Goldberg successfully adopted approach by the conjunctival incision [5]. The forming fat flap arbitrary shape formed by retained fat was used to fill the tears groove. Mohadjer described a surgical technique of lower eyelid blepharoplasty with fat repositioning in an intrasuborbicularis oculi fat (intra-SOOF) dissection plane via a transconjunctival incision [3].

Hamra was used for patients with good results. However, there was still insufficient tear trough deformity defect in some patients found in the clinical follow-up. Hamra surgical was not suitable for younger patients since Asians were more prone to have postoperative obvious scar.

**Table 1.** Barton's grading system

|           |  |
|-----------|--|
| Grade 0   | Absence of medial or lateral lines demarcating the arcus marginalis or the orbital rim and a smooth, youthful contour without a transition zone at the orbit-cheek junction. |
| Grade I   | Mild, subtle presence of a medial line or shadow; smooth lateral transition of lid-cheek junction.   |
| Grade II  | Moderate prominence of a visible demarcation of the lid-cheek junction, extending from medial to lateral.  |
| Grade III | Severe demarcation of the orbit-cheek junction, with an obvious step between the orbit and the cheek.  |



**Figure 1.** A: Image-Pro Plus 6.0 photo measurement process diagram; B: Image-Pro Plus 6.0 photo measurement process diagram (right); C: Image-Pro Plus 6.0 photo measurement process diagram (left).

Therefore, we have used transconjunctival approach and performed orbital fat reposition with septal reset. Then improvement of surgical procedures was performed to correct tear trough deformity. In this study, we confirmed the effectiveness of this improved operation.

## Methods

This retrospective study was approved by Ethics Committee of the First Affiliated Hospital, College of Medicine, Zhejiang University and performed in Plastic Surgery of the First Affiliated Hospital of Zhejiang University “transconjunctival fat reposition with septal reset of lower blepharoplasty” treatment from October 2013 to January 2015. Patients had tear trough deformity with or without lower eyelid fat bulging met the inclusion criteria, marked skin or orbicularis oculi muscle laxity were excluded. There were a total number of 42 patients including 2 males and 40 females with age range of 20-41 years (mean age of 29.1 years old). Because of the asymmetry of the face, eyes of the same patient were evaluated independently and there were total 84 eyes in this study. All clinical follow-up was 3-12 months (mean follow-up of 6.5 months).

Preoperative and postoperative front, lateral and oblique photos were taken. Barton rating method was used for 2 orthopedic clinical physician to evaluate abnormalities tear trough and typing (Table 1) [4]. The eye, bags, tear trough and postoperative complications

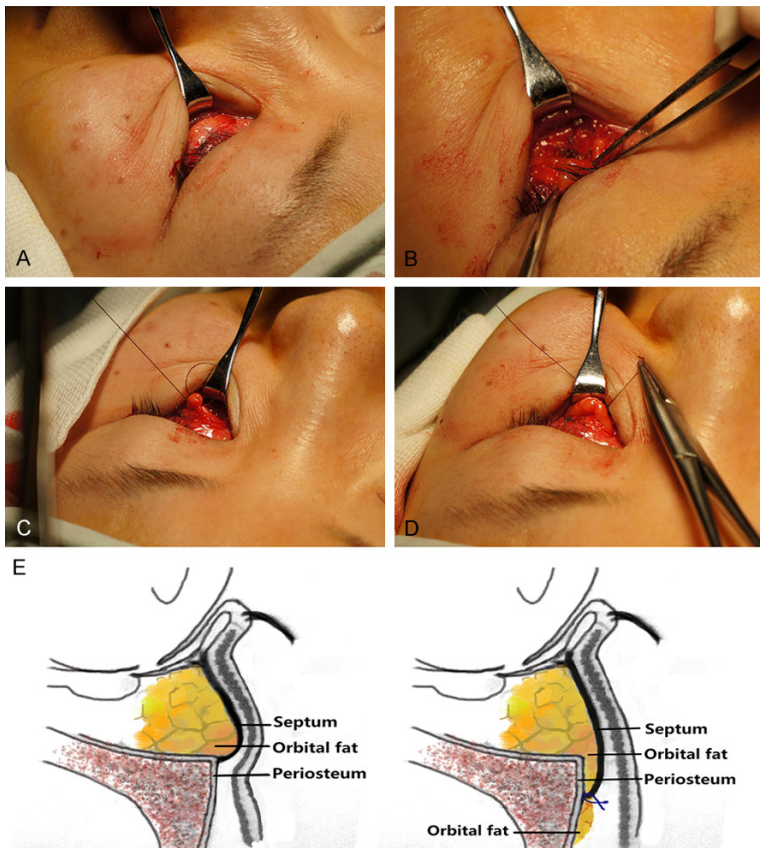
were observed to evaluate the effect of surgery, and patient satisfaction surveys were performed to obtain subjective evaluation.

The front photo was measured using Image-Pro Plus 6.0. The measuring line (Figure 1; Table 2)

## Transconjunctival fat for the tear trough

**Table 2.** Image-Pro Plus 6.0 photogrammetry

| Measuring item                        | Explanation   | Graphical representation  |
|---------------------------------------|---|---|
| Palpebral fissure width (mm)          | Distance between inner and external canthus                           | Right: R1 (P1, P2 ligature)<br>Left: R2 (P12, P13 ligature)   |
| Inferior palpebral margin length (mm) | The length of inferior palpebral margin                               | Right: T1 (P1, P3, P4, P5, P2 ligature)<br>Left: T4 (P12, P14, P15, P16, P13 ligature)                    |
| Under-eye puffiness length (mm)       | The length of under-eye puffiness margin                              | Right: T2 (P6, P7, P8 ligature)<br>Left: T7 (P23, P18, P19 ligature)                                      |
| Lacrimal sulcus length (mm)           | The tear groove depression length                                     | Right: T3 (P9, P10, P11 ligature)<br>Left: T6 (P20, P21, P22 ligature)                                    |
| Under-eye puffiness height (mm)       | The maximum distance between the pouch and palpebral fissure          | Right: PT1 (The maximum distance between T2 and R1)<br>Left: PT3 (The maximum distance between T7 and R2) |
| Lacrimal sulcus height (mm)           | The maximum distance between the orbital groove and palpebral fissure | Right: PT2 (The maximum distance between T3 and R1)<br>Left: PT4 (The maximum distance between T6 and R2) |



**Figure 2.** A, B: The separation was performed in the anterior orbital septum and posterior orbicularis oculi plane, and stripped down to the arcus marginalis. Blunt dissection was conducted with periosteal stripping in the periosteal surface and stripping to the bottom of the inferior orbital rim about 8-10 mm, forming a pouch-like gap; C, D: The 5-0 absorbable sutures were placed through the lower edge of the orbital septum and the middle of fat pedicle with fixation to the periosteal surface; E: Surgical schematic. The left figure was for the preoperative and right for postoperative.

was marking according to the background ruler scale with the smallest scale of 1 mm to make the calibration. Each indicator was measured three times.

### Surgical technique

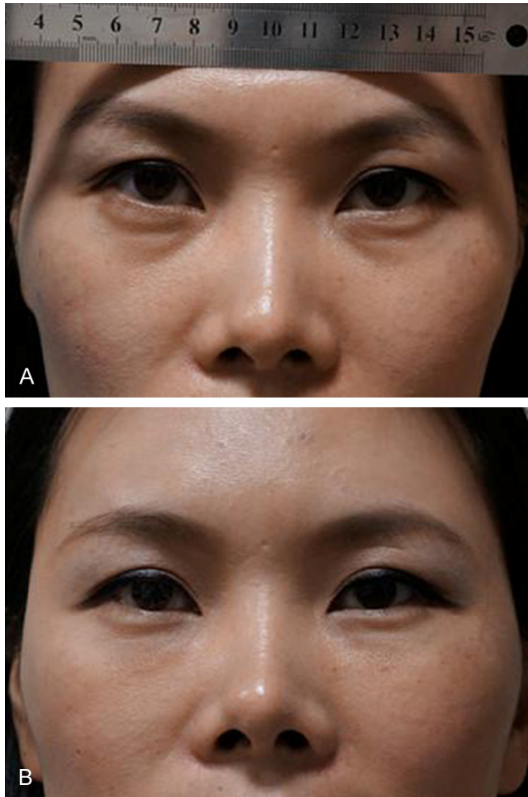Local anesthetic consisting 0.25% lidocaine with epinephrine is injected through the inferior fornix. A transconjunctival infraorbital nerve block is important to achieve adequate anesthesia. The transconjunctival incision approach followed by transection between the lower edge of tarsal plate and conjunctival fornix, to enter the anterior orbital septum and posterior orbicularis oculi plane. The separation was performed in this plane and stripped down to the arcus marginalis, and release the orbicularis retaining ligament. Make sure not to break the orbital septum in order to avoid affecting the operation field. Blunt dissection was conducted with periosteal stripping in the periosteal surface and stripping to the bottom of the inferior orbital rim about 8-10 mm, forming a pouch-like gap. Exposure to the orbital septum, release the medial and lateral fat pads to form fat pedicle flap and fully tiled the front gap. The 5-0 prolene suture was used to fix the

orbital septum and the fat pedicles. At about 3-5 mm in the bottom of the inferior orbital rim, the 5-0 absorbable suture were placed through the lower edge of the orbital septum and the



**Table 3.** Improvement in Patients (with a total of 84 eyes)

| Pre-operation |         | Post-operation |          |           |
|---------------|---------|----------------|----------|-----------|
| Grade I       | Grade 0 | Grade I        |          |           |
| 34            | 30      | 4              |          |           |
| Grade II      | Grade 0 | Grade I        | Grade II |           |
| 38            | 29      | 9              | 0        |           |
| Grade III     | Grade 0 | Grade I        | Grade II | Grade III |
| 12            | 3       | 8              | 1        | 0         |

**Figure 3.** A 27-year-old female patient with improvement of grade II to grade 0 after a fat reposition with septal reset via transconjunctival approach. A: Pre-operative view; B: Six-month postoperative view.

middle of fat pedicle with fixation to the periosteal surface, and then passed through the skin beyond the tear trough. The needle was again passed back through the same needle hole of skin, penetrated into the gap of the periosteum, through the middle of fat pedicle with the lower edge of covering orbital septum. Both ends of the suture were taut and knot. The two mutual tension sutures were knot. Usually 3-4 sewing needle was performed. Cold compress and antibiotic spongarion were used (**Figure 2**).

## Results

With all patients, no significant complication was found postoperatively. Though there were 6 patients worried about the edema in two weeks after the operation, and 3 patients felt lower eyelid skin saggy than before, all of the 42 patients finally felt satisfied with the result.

Preoperative evaluation showed 34 cases included in grade I with 30 cases (88.2%) improving grade I to grade 0, and 4 cases (11.8%) having no improvement. There were 38 cases preoperatively in grade II, with 29 cases (76.3%) improving to grade 0, 9 cases (23.7%) improving to grade I, and no cases without improvement. In preoperative grade III cases, there were 12 cases initially, with 3 patients (25%) improving to grade 0, 8 cases (66.6%) improving to grade I, 1 cases (8.4%) improving to grade II, and no cases without improvement. (**Table 3**) The method of fat reposition with septal reset in transconjunctival lower blepharoplasty had significant effect for both tear through with and without under-eye puffiness patients ( $P < 0.05$ ).

### Patient 1

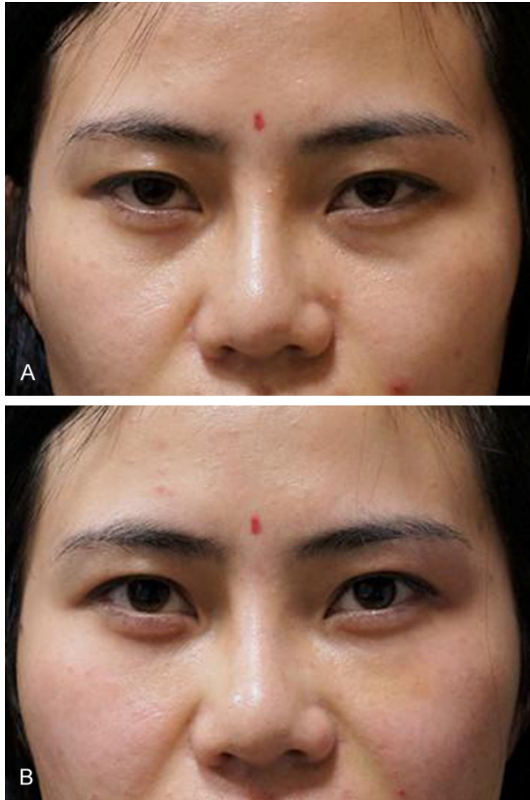A 33-year-old female patient has tear trough deformity with protrusion of orbit fat. We performed a transconjunctival lower blepharoplasty with fat reposition and septal reset. The asymmetric concave contour and infraorbital bulging were rectified. The deformity was improved from preoperative grade II to postoperative grade 0 (**Figure 3**).

### Patient 2

A 27-year-old female patient mainly complained of the appearance of tear trough deformity. We performed fat reposition with septal reset using the transconjunctival approach. Significant improvement was achieved postoperatively. The deformity was improved from preoperative grade II to postoperative grade 0 (**Figure 4**).

## Discussion

Inferior orbital rim groove deformity has become an important symbol of periorbital aging. Tear trough deformity was described as a "tear trough triad": 1. fat herniation, 2. prominent orbital rim depression, and 3. malar rim retrusion, producing a negative vector orbit [4].



**Figure 4.** A 27-year-old female patient with improvement of grade II to grade 0 after a fat reposition with septal reset via transconjunctival approach. A: Pre-operative view; B: Six-month postoperative view.

Learning the anatomy of tear trough deformity is crucial.

The support structure of lower eyelid includes skin, orbicularis muscle, orbital, etc. The occurrence of under-eye puffiness was related to the destruction of the equilibrium between the orbital fat and the lower eyelid support structures. Degeneration of the orbital septum is an important factor for under-eye puffiness formation [6]. Grown with ages, the gradual degeneration of the outer canthal ligament becomes laxity and the connection of Lockwood ligaments was weakened. When the eye decreases because of the loss of normal support force, reduce the space between the eye and the lower orbital wall, so that orbital fat hernia was forced forward. Growing with ages, the lower eyelid skin and orbicularis becomes muscle relaxation, orbital fat from the weaker section of orbital hernia, while adhering to the inferior orbital rim at the orbital septum with no significant slack, so the orbital rim, cheekbone edge revealed, tears appear recessed groove [7, 8].

Traditional blepharoplasty plastic surgery is mainly to remove excess orbital septum fat. After surgery, lower eyelid sag is apt to appear, and conditions of patients of tear groove deformity may be worse. The “fat pad sliding” procedure was firstly proposed by Loeb [2]. The orbital fat was shifted to filled ditch near the nose and cheeks sunken area. This method was improved by Hamra, fat was fixed at submuscular plane through the skin [2].

Hamra used the method of arcus marginalis release and fat preservation to elevate subseptal orbital fat to the level of the orbital rim [2]. This method was modified to septal reset technique [9]. By resetting the orbital septum, along with the fat, down to the anterior surface of the orbital rim, the integrity of the septal partition is restored. The vascularized fat volume is delivered to the malar depression. The release of the orbicularis-retaining ligament as part of redraping the ptotic orbicularis completes the correction [4]. By leaving the septum intact, the transconjunctival approach has reduced the spectrum of postoperative complications in lower eyelid retraction, ranging from rounding of the lateral canthal area to ectropion [10]. Camirand et al., made orbital fat along with eyelid bag fascia sutured to the orbital bone arcuate edge by transconjunctival approach [7]. Goldberg adopted the conjunctival incision to make retain the cellulite formed arbitrary shape of fat flap, and fixed in subperiosteal plane [5]. Kawamoto et al. adopted transconjunctival approach to replace the orbital fat flap under the muscle [11]. They think Asians retained orbital fat can obtain satisfactory results as well. Mohadjer performed lower eyelid blepharoplasty with fat repositioning in a intrasuborbicularis oculi fat (intra-SOOF) dissection plane via a transconjunctival incision [3].

We have young patients who want to improve congenital lower eyelid with tear trough. For our young cases, we believe their tear trough deformity is mainly caused by congenital orbital rim depression and fat herniation. For young patient whose skin and orbicularis muscle is still tight, there is no need to dissect orbicularis muscle flap via a transcutaneous approach. The method of fat reposition with septal reset in transconjunctival lower blepharoplasty is used in such cases.

Barton devised a graduated scale to describe the level of tear trough deformity [4]. According

to this scale, grade 0 was considered to be an ideal, youthful eyelid with an indistinct surface grooving over the arcus marginalis, and grade III is the most severe deformity. In the severe cases of grade III, fat extrusion and septal reset usually performed with skin-muscle flap elevation to achieve a good result. However, in grade I and grade II cases, we used a transconjunctival incision to remove lateral fat pad and reset medial and central fat pad.

Hamra proposed that the theory of orbital reset, the lower orbital fat flap edge together with the lower edge of the orbital septum were fixed to the periosteum sutured [12]. This will provide support force for the orbital septum and periosteum of adipose tissue and also make the inferior orbital rim deformity being corrected. Repositioning with septal reset via a transconjunctival approach showed a better improvement compared to the redraping of pedicled fat [13]. We had found in the clinical follow-up that retaining orbital fat pedicle drop-down filling in the inferior orbital rim area was certainly helpful to improve the eye and tear groove deformity. However it will also increase the pressure of the orbital septum, which is not conducive to the orbital balance of fat and lower eyelid support structures. Furthermore, since the small field of view through conjunctival incision surgery, the operation is relatively difficult and it is not easy to grasp orbital position reset. When the fat pedicle flap retraction occurs, the local filling is less effective and some patients may experience postoperative tears groove under correction situation. Based on the above analysis, was fixed on the periosteal flap at the same orbital position fixed on the basis of in the middle of the fat flap, and extends to the rest below 5 mm of tiled orbital rim.

By anatomy and histology, Chin-Ho Wong et al. confirmed the presence of osteocutaneous ligament, namely the tear trough ligament. The ligaments was the continuous section with the orbicularis retaining ligament found by Muzaffar et al., and it is a major factor in the formation of abnormal tear grooves. Research indicated that the ligaments were 4-8 mm away from the orbital rim, with an averaging of 5 mm [14, 15]. In order to effectively fill the tear groove, we believed that it was possible to extend the orbital fat tile to the inferior orbital rim at the

bottom of 8-10 mm. As long as the separation range was within 10 mm of the orbital rim, the risk of damage to surrounding nerves will be significantly reduced [16]. In order to fully extend orbital fat, orbital fat surgery will be stripped from the membrane formation of fat flap, so that the migration distance of fat increases, while fat contain fiber opened, reducing the likelihood of fat retraction. Since the periosteal is elastic and firm, the separation under the periosteum was easier and the tear grooves could be better filled [11]. In our study, the orbital fat was fixed at orbicularis muscle, periosteum plane to a better fat fixed at the exact position, and maximize the recovery of suborbital soft tissue volume. In addition, there was rich blood supply in this plane, which can provide a good blood supply to reset the fat, but the operation should avoid damaging the angular vessels and medial palpebral artery so as not to cause bleeding.

After follow-up, we found that our patients had no serious complications. In our experience, this method has strict indication. Patients must be told that this surgery could not improve even slight skin and muscle laxation. Grade III patients was significantly more associated with skin or orbicularis muscle relaxation and is not suitable for this method.

The result of the method of fat reposition with septal reset in transconjunctival lower blepharoplasty is pleasing. However, it is important to notice that the indication is narrow. And long-term result still requires following up.

### Disclosure of conflict of interest

None.

**Address correspondence to:** Jinghong Xu, Department of Plastic Surgery, The First Affiliated Hospital, Zhejiang University, No. 79, Qingchun Rd., Hangzhou 310003, Zhejiang Province, China. E-mail: jinghongxu201500@sina.com

### References

- [1] Hamra S. Arcus marginalis release and orbital fat preservation in midface rejuvenation. *Plast Reconstr Surg* 1995; 96: 354-362.
- [2] Loeb R. Fat pad sliding and fat grafting for leveling lid depressions. *Clin Plast Surg* 1981; 8: 757-776.

- [3] Mohadjer Y, Holds JB. Cosmetic lower eyelid blepharoplasty with fat repositioning via intra-SOOF dissection: Surgical technique and initial outcomes. *Ophthal Plast Reconstr Surg* 2006; 22: 409-413.
- [4] Barton FE, Ha R, Awada M. Fat extrusion and septal reset in patients with the tear trough triad: A critical appraisal. *Plast Reconstr Surg* 2004; 113: 2115-2121.
- [5] Goldberg RA. Transconjunctival orbital fat repositioning: transposition of orbital fat pedicles into a subperiosteal pocket. *Plast Reconstr Surg* 2000; 105: 743-748.
- [6] Hoffmann KT, Hosten N, Lemke AJ, Sander B, Zwicker C, Felix R. Septum orbitale: highresolution MR in orbital anatomy. *AJNR Am J Neuroradiol* 1998; 19: 91-94.
- [7] Camirand A, Doucet J, Harris J. Anatomy, pathophysiology, and prevention of senile enophthalmia and associated herniated lower eyelid fat pads. *Plast Reconstr Surg* 1997; 100: 1535-1546.
- [8] Putterman AM, Urist MJ. Surgical anatomy of the orbital septum. *Ann Ophthalmol* 1974; 6: 290-294.
- [9] Baker SR. Orbital fat preservation in lower-lid blepharoplasty. *Arch Facial Plast Surg* 1999; 1: 33-37.
- [10] Zarem HA, Resnick JL. Minimizing deformity in lower blepharoplasty: The transconjunctival approach. *Clin Plast Surg* 1993; 20: 317-321.
- [11] Kawamoto HK, Bradley JP. The tear "TROUF" procedure: transconjunctival repositioning of orbital unipedicled fat. *Plast Reconstr Surg* 2003; 112: 1903-1807.
- [12] Hamra ST. The role of the septal reset in creating a youthful eyelid-cheek complex in facial rejuvenation. *Plast Reconstr Surg* 2004; 113: 2124-2141.
- [13] Youn S, Shin JI, Kim JT, Kim YH. Transconjunctival subperiosteal fat reposition for tear trough deformity: pedicled fat redraping versus septal reset. *Ann Plast Surg* 2014; 73: 479-484.
- [14] Wong CH, Hsieh MK, Mendelson B. The tear trough ligament: anatomical basis for the tear trough deformity. *Plast Reconstr Surg* 2012; 129: 1392-1402.
- [15] Muzaffar AR, Mendelson BC, Adams WP Jr. Surgical anatomy of the ligamentous attachments of the lower lid and lateral canthus. *Plast Reconstr Surg* 2002; 110: 873-884.
- [16] Yoo DB, Peng GL, Massry GG. Transconjunctival lower blepharoplasty with fat repositioning: a retrospective comparison of transposing fat to the subperiosteal vs suprapariosteal planes. *JAMA Facial Plast Surg* 2013; 15: 176-181.