

Original Article

Occipitocervical fusion combining intra-operative skull traction with posterior instrumented reduction for the treatment of basilar invagination with atlantoaxial dislocation

Yongming Xi, Xu Zhang, Shilong Yuan, Jin Cao, Dechun Wang, Jinfeng Ma, Xianfeng Ren, Yougu Hu

Department of Spinal Surgery, The Affiliated Hospital of Qingdao University, Qingdao 266003, China

Received November 19, 2015; Accepted January 25, 2016; Epub June 15, 2016; Published June 30, 2016

Abstract: This study aims to evaluate the effects of combining intra-operative large magnitude skull traction with posterior instrumented reduction for treating basilar invagination with atlantoaxial dislocation. Eleven patients (7 men, 4 women) with basilar invagination, combined with irreducible atlantoaxial dislocation, underwent surgery from February 2009 to October 2013. All patients displayed neurological symptoms in the following degrees: American Spinal Injury Association (ASIA) C in 3 patients, ASIA D in 6, and the mean cervical medullary angle was 132.1° . Once the reduction index was more than 30%, whether by pre-operative or intra-operative skull traction, posterior instrumented reduction and fusion was performed. Mean surgery time was 150 minutes and mean blood loss was 150 ml. A satisfactory reduction was obtained immediately post-surgery. No other vertebral artery or spinal cord complications were seen, except unilateral numbness in the C2 nerve distribution in 1 patient. The follow-up period ranged from 10 to 66 months (average 32.5 months). All patients displayed significant neurological recovery with ASIA C in 2 patients recovered to ASIA D, ASIA C in 1 recovered to ASIA D, and ASIA D in 6 recovered to ASIA E. The post-operative mean cervical medullary angle was 156.2° . Solid fusion was achieved in 11 cases by final follow-up, with no internal fixation failures, and spinal cord signals had improved significantly. A combination of intra-operative heavy traction and instrumented reduction provides a safe and effective method for treating basilar invagination with irreducible dislocation.

Keywords: Basilar invagination, atlantoaxial dislocation, skull traction, reduction and fusion

Introduction

Basilar invagination (BI) is the most common anomaly of the craniocervical junction and can be associated with atlantoaxial instability, which in turn can compress the medulla oblongata or spinal cord, causing neck pain with local deformity and progressive neurological dysfunction [1, 2]. For symptomatic irreducible BI with atlantoaxial instability, surgery is indicated. Surgical treatment of BI consists of decompression and fusion. Various surgical methods have been described for treating basilar invagination, including direct anterior decompression with or without internal fixation [3-8], one-stage posterior instrumentation [9-11] and a combination of the anterior and posterior approaches [12]. Due to increased incidences of complications from the anterior

and combined approaches, posterior surgery is an option for the treatment of BI [11, 13]. In this study, we combined the methods recommended by Wang et al. [12] and Peng et al. [11], and present consecutive cases of BI treated by combining intra-operative skull traction with posterior pedicle screw/rod reduction. This procedure allowed easier and more powerful reduction. We show that this technique is a useful option for treating irreducible BI with atlantoaxial instability.

Materials and methods

Object

Between February 2009 and October 2013, 11 consecutive patients with occipitalization of the atlas underwent surgery combining intra-opera-

Treatment of basilar invagination with atlantoaxial dislocation

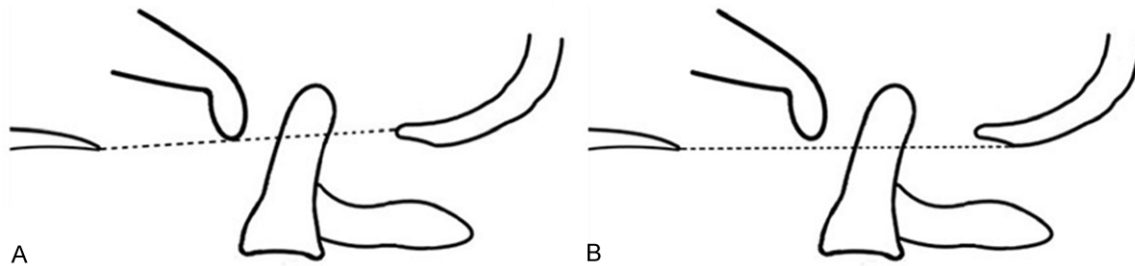


Figure 1. A: Chamberlain line (palatooccipital line), line between the posterior upper edge of hard palate and the posterior lip of foramen magnum; B: McGregor line (basal line), line between the posterior upper edge of hard palate and the lowest point of occipital bone (lowest edge of cortical plate of occipital squama).

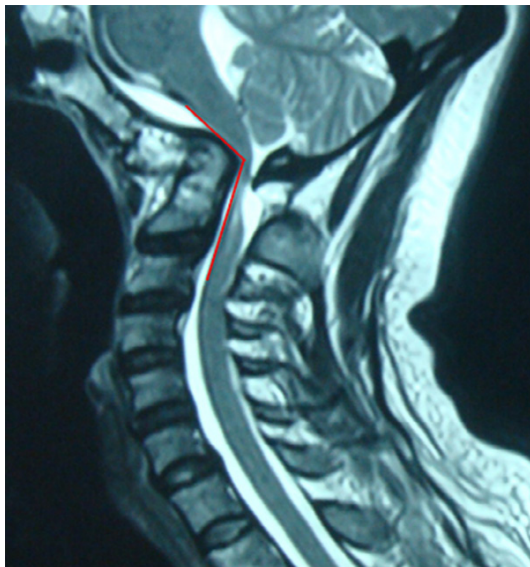

Figure 2. Spine-medulla angle: the angle formed by the sternopleural line of medulla and the sternopleural line of cervical spinal cord (normal spine-medulla angle: 145° - 170°).

tive large magnitude skull traction combined with posterior instrumented reduction. The average age was 50.3 years, (range 30-77 years), with 7 men and 4 women. All the patients manifested neurological symptoms to different degrees, including occipital neck pain and limited cervical motion. Nine patients had spinal cord compression symptoms in the upper and/or lower extremities, including numbness, weakness, and walking instability. According to the American Spinal Injury Association (ASIA) grade classification, 3 patients had ASIA C symptoms and 6 had ASIA D symptoms.

This study was conducted in accordance with the declaration of Helsinki. This study was con-

ducted with approval from the Ethics Committee of Qingdao University. Written informed consent was obtained from all participants.

Imaging

Conventional cervical radiographs (in lateral, dynamic, and open-mouth planes), 3-dimensional computed tomography (CT), and magnetic resonance imaging (MRI) were routinely performed. The basilar impression was diagnosed according to the McGregor line and Chamberlain line (**Figure 1**). The degree of irreducible dislocation could be determined by measuring the changes in the atlanto-odontoid interval (ADI) in the dynamic position. CT was then used to determine the hyperostotic degree of the atlantoaxial joint, and the degree of irreducible dislocation was determined according to the sagittal angle of the atlantoaxial joint. The channel and length of the pedicle screw were positioned by evaluating the morphologies of the vertebral body and pedicle. MRI was performed to understand spinal cord compression and scar hyperplasia (**Figure 2**).

Surgical methods

All patients underwent routine skull traction for 1-2 weeks pre-operatively with a traction weight of 3-5 kg. Lateral and open-mouth radiographs were performed during the traction period to observe the degree of reduction. Once the pre-operative traction had achieved a certain level of reduction (with the reduction index $\geq 30\%$) (**Figure 3**), the patient could be prepared for surgery. If the pre-operative traction index did not reach 30%, the traction method described by Wang et al. [12] was recommended with heavy weight skull traction under general anesthesia ($1/8$ - $1/6$ of body weight for more than

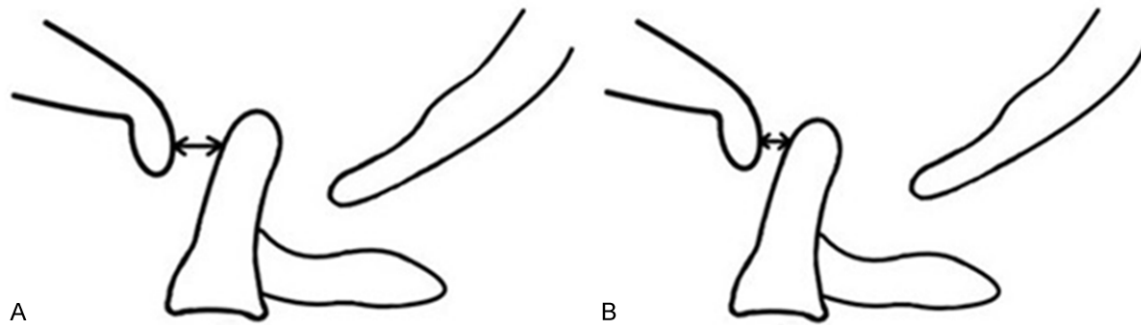


Figure 3. Before the skull traction, the atlanto-dens interval (ADI) = A; after the skull traction, the atlanto-dens interval (ADI) = B. Reduction index = $(A-B)/A \times 100\%$.

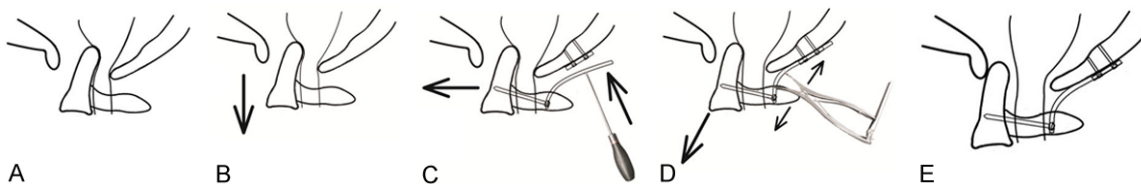

Figure 4. A: Situations of atlantoaxial dislocation before the surgery; B: After high-weight traction during the surgery, the axial dens process achieved partial longitudinal reduction; C: After implanted occipital plate and bilateral C2 cervical screws, the rod was pre-bended to certain angle (about 135°), then placed and locked C2 screw tightly, the turned-up head was then pushed into the occipital plate to force the axis reduced forwards; D: Distracted the space between the occipital plate and C2 cervical screw, making the axis reduced forwards and downwards; E: Locked tightly when achieved the full reduction.

10 min). Once the required reduction was obtained (index $\geq 30\%$), the posterior fixation surgery could then be performed. All patients in this study reached the above reduction standards.

All patients in this study were treated with the Summit fixation system (Depuy Spine, USA). The length of the atlantal pedicle screw was 24-28 mm, and its diameter was 3.5 mm; the axial pedicle screw was 24-28 mm, with a diameter of 3.5 or 4.0 mm; and the length of the lateral screw was 14-16 mm.

The patients underwent the intubation procedure under general anesthesia, with somatosensory and motor-evoked potential being monitored to assess the spinal cord function. The patient was placed in the prone position, with the Mayfield head holder to fix the head, and conventional skull traction was performed (**Figure 4A**). According to the degree of reduction, the traction weight was set between 5-10 kg, and head fixation was maintained throughout (**Figure 4B**). Using a posterior midline incision, sub-periosteal dissection was used to

fully expose the posterior arch of the atlas and the lamina of the axis, and care was taken to protect the dilating venous plexus to avoid serious bleeding. The pedicle screws were positioned according to the method described by Harms [14]. One high-speed burr was used to grind the sub-occipital bone as flat as possible, then the occipital plate was placed, a hole drilled, and two flat-head bi-cortical screw fixations (the average length was 8 mm) attached. A rod (with a diameter of 4 mm) was contoured to an angle of approximately 135° , and the length was 1-2 cm longer than the measured dislocation status. The pre-contoured rod was first placed on the head of the multi-axial C2 screw, the nut was then tightened, and the distance between the head end rod and the occipital plate screw slots was about 1-2 cm, according to the degree of dislocation. Then, a combination of head hyperextension and a rod-pusher was used to push the rod into the screw slot, the screw nut was fixed but not tightened (**Figure 4C**), so that anterior partial reduction could be achieved. Then the distraction force was used to slide the rod backwards along the screw slot of the occipital plate, while the dens

Table 1. Clinical characteristics and surgical outcomes

Case No.	Sex	Age (yr)	Neck pain*		Hypoesthesia		Bilateral Babinski		ASIA grade		Atlantodental distance (mm)		Cervico-Medullary Angle (°)	
			Preop	Postop	Preop	Postop	Preop	Postop	Preop	Postop	Preop	Postop	Preop	Postop
1	F	48	3	0	Yes	No	+	-	D	E	7	2	125	158
2	M	77	6	1	Yes	Yes	+	+	C	D	13	4	117	149
3	M	30	9	3	No	No	-	-	E	E	10	0	136	145
4	M	35	8	0	No	No	-	-	E	E	11	1	142	157
5	F	36	3	0	Yes	No	-	-	D	E	6	0	148	165
6	M	48	2	0	Yes	No	+	-	D	E	6	0	136	159
7	M	46	6	0	Yes	No	+	-	D	E	12	2	139	162
8	F	59	1	0	Yes	No	+	-	D	E	7	0	128	161
9	F	63	7	2	Yes	Yes	+	-	C	D	12	3	115	146
10	M	60	3	0	Yes	No	+	-	C	E	11	1	128	150
11	M	51	3	0	Yes	No	+	-	D	E	9	1	139	166

*e Evaluated by Numeric Rating Scale (NRS).

moved in the opposite (anteroinferior) direction (**Figure 4D**). The screw could then be tightened when a full reduction was achieved (**Figure 4E**).

After completing the reduction, the sub-occipital bone and axial lamina were decorticated, after which material from the iliac bone was harvested and embedded into the space between the occipital bone and atlantoaxial lamina.

All the patients could sit or walk on the second post-operative day, and wore a neck collar continuously for three months. Radiographic examination was performed in the 1st, 3rd, and 6th month after surgery, and CT reconstruction was performed in the postoperative 3rd and 6th months to evaluate internal surgical fixations and bone fusion. MRI was performed to evaluate if the spinal oppression was still present. One patient was treated with the standard anti-osteoporosis therapy (teriparatide, Lilly Co, Indianapolis, US) because the pre-operative degree of severe osteoporosis had also caused other fractures.

Results

The mean operative time was 150 min (range 110-180 minutes) and the mean blood loss was 150 ml (range 100-300 ml). There were no vertebral artery or spinal cord injury complications. After surgery, 1 patient showed numbness in a unilateral C2 nerve distribution; however, neck pain symptoms were alleviated to varying degrees. All patients were followed up for a mean period of 32.5 months (range, 6-66

months). Nine patients with spinal compression exhibited significant reduction of numbness and restoration of limb muscle strength at the final follow-up. According to the ASIA classification, 2 cases recovered from grade C to grade D, 1 case recovered from grade C to grade E, and 6 cases recovered from grade D to grade E (**Table 1**). The dynamic lateral radiographs, CT, and MRI scans conducted in final follow-ups exhibited no loosening, fracture, displacement, or loss of reduction. Solid fusion was obtained in all patients. The CT reconstruction showed good reduction of the odontoid and the degree of spinal compression had improved (**Figure 5**).

Discussion

Occipitalization is the most common anomaly of the craniocervical junction with a prevalence of 0.08-2.76% in the population [15]. It can be associated with atlanto-axial instability or BI resulting in compression of the medullary cord. Most patients with occipitalization of the atlas are asymptomatic; onset of symptoms usually occurs in the third or fourth decade. Common complaints are neck pain, stiffness, varying degrees of neurological dysfunction, and cosmetic concerns [1, 2].

The basic principles in treating atlantooccipital occipitalization and atlantoaxial dislocation include reduction, decompression, and maintaining local long-term stability. Currently, there are various methods used in treating atlanto-occipital occipitalization and atlantoaxial dislocation, including anterior, posterior, and an

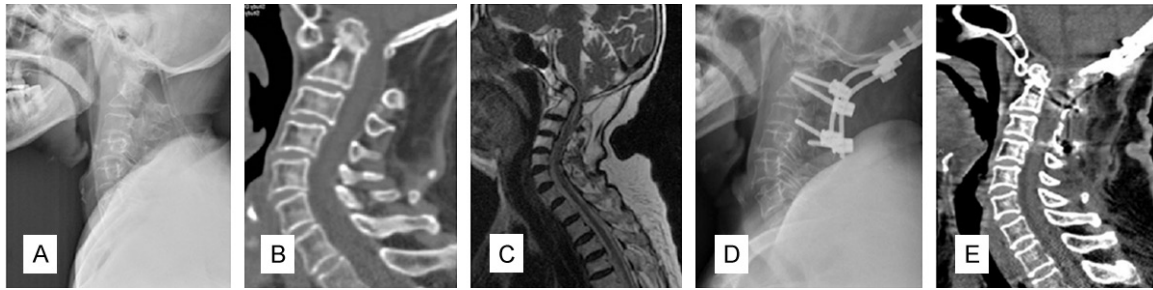


Figure 5. A: Preoperative X-ray; B: Preoperative CT reconstruction showed the dentate process obviously trapped upwards into the foramen magnum, and displaced backwards, and the spinal canal on the relative level was narrowed; C: Preoperative MRI showed that the cervical spine was significantly compressed; D: Postoperative X-ray: no loose or broken internal fixation; E: Postoperative CT reconstruction showed good reduction.

anteroposterior combined approach. Because the compression of the medullary spinal cord mainly originates anteriorly, transoral and transnasal odontoid resection could achieve the desired results [3, 4], but the anterior odontoid resection carries with it the possibilities of spinal cord injury, dural rupture, infection, and other serious complications. Yin completed the anterior release by a transoral approach [5], and completed the reduction and decompression by using a reduction plate, but the operation was technically demanding and more complications were possible, including the risk of infection, prolonged intubation, or tracheostomy, the need for nasogastric tube feeding, extended hospitalization, and possible effects on phonation [16].

Abumi et al. [10] reported occipitocervical reconstruction using pedicle screws and occipitocervical rod systems, with the aim of the reduction and fixation of atlantoaxial subluxation associated with BI [1]. Flexion deformity of the occipitoatlantoaxial complex was corrected by application of extension force, and superior migration of the odontoid process was reduced by the use of combined extension and distraction between the occiput and the cervical pedicle screws. However, the occipitocervical lesions were caused by rheumatoid arthritis and reduction is relatively easy in these cases.

Wang et al. [12] reported open reduction and stabilization of irreducible atlantoaxial dislocation by performing transoral anterior atlanto release and posterior internal fixation. Most of the presumed irreducible atlantoaxial dislocation (IAAD) could become reducible after anterior release without odontoid resection. Especially, cranial skeletal traction (6-10 kg, the maximum weight should not exceed one-

tenth of the patient's weight) and the plate screw instrumentation could achieve further reduction and provide immediate instrumentation data. Disadvantages are the possible occurrence of more complications than with the single approach.

Goel et al. [13, 17] describe a technique for treating BI by performing atlantoaxial joint distraction, reduction of the basilar invagination, and direct lateral mass atlantoaxial plate/screw fixation. He secured two titanium spacers within the bilateral atlantoaxial joints through the posterior approach. He then observed that the distraction and impaction of the titanium spacer within the joint cavity increased the height of the lateral masses, reduced the basilar invagination, and restored the craniovertebral alignment. Yoshizumi et al. [18] treated BI by performing occipitocervical fusion with atlantoaxial distraction using a cylindrical titanium cage packed with pieces of bone graft. C2 pedicle screws were inserted, and the atlantoaxial joint facet space was increased. Occipital-C2 fusion was completed by fastening the occipital bone plates with pedicle screws by using titanium rods. However, the above two methods need adequate space for the procedure by exposing the facets of the atlas and axis. Exposure of the local venous plexus and resection of the C2 nerve root are often necessary, both of which can result in serious bleeding and occipital numbness, and the procedure also demands high technical skill during insertion of the spacer.

Guo et al. [19] and Young et al. [20] reported using posterior screw and rod instruments for the reduction and fixation of atlantoaxial dislocation. Peng et al. [11] treated primary BI by cervical traction and posterior instrumented

reduction together with occipitocervical fusion, but the cervical traction before surgery required long-term bed rest, which increased the risk of deep venous thrombosis and pulmonary embolism, particularly in older patients. Our technique combined Peng and Wang's [11, 12] procedures by using intra-operative heavy traction and instrumented reduction, although the operating procedures are different from the original techniques.

The principle behind Wang's [12] reduction procedure was to use heavy traction to obtain odontoid longitudinal reduction and use the screw-plate system to help the forward reduction of odontoid process. Peng et al. [11] mainly used long-time traction for the partial reduction before surgery. The screw-rod fixation system was employed and precontoured rods would then produce an anterior-inferior reduction between the occipital fixation point and C2. Thus, the intra-cranial odontoid process would be pulled anterior-inferior, so as to achieve cervical medullary decompression.

In our study, we routinely used conventional pre-operative traction and, for patients whose traction index could not reach 30%, heavy skull traction under anesthesia was used to obtain reduction, then a contoured rod was used to create a reductive force downwards and forwards to obtain reduction of the odontoid process. Afterwards, a longitudinal distraction force was used for further longitudinal reduction. A combination of the three reduction forces outlined above could thus achieve good results for even the most irreducible dislocation. The advantages of this technique were that, in this one single approach, trauma was limited and there was no need for long-time traction before surgery which reduced pre-operative complications such as venous thrombosis. In addition, under anesthesia, the muscles and ligaments would be relaxed and could therefore truly show the irreducible dislocation; and the combination of the 3 reductive forces could achieve a more satisfactory reduction. The disadvantages were that for some patients who had more severe dislocations and for whom it was difficult to obtain a satisfactory reduction using traditional methods, the achievement of a reduction using the 3 combined forces might increase the stress acting on the rod and screws might cause breakage of the screw and dislocation of the rods, so post-

operative external fixation might become necessary.

Disclosure of conflict of interest

None.

Address correspondence to: Xu Zhang and Yongming Xi, Department of Spinal Surgery, The Affiliated Hospital of Qingdao University, No. 16 Jiangsu Road, Qingdao 266003, China. Tel: +86 532 82913565; E-mail: xunZhangcn@126.com (XZ); yongmingxi@yeah.net (YMX)

References

- [1] Grob D, Schütz U and Plötz G. Occipitocervical fusion in patients with rheumatoid arthritis. *Clin Orthop Relat Res* 1999; 46:53.
- [2] Nockels RP, Shaffrey CI, Kanter AS, Azeem S and York JE. Occipitocervical fusion with rigid internal fixation: long-term follow-up data in 69 patients. *J Neurosurg Spine* 2007; 7: 117-123.
- [3] Dasenbrock HH, Clarke MJ, Bydon A, Sciubba DM, Witham TF, Gokaslan ZL and Wolinsky JP. Endoscopic image-guided transcervical odontoidectomy: outcomes of 15 patients with basilar invagination. *Neurosurgery* 2012; 70: 351-359.
- [4] Wolinsky JP, Sciubba DM, Suk I and Gokaslan ZL. Endoscopic image-guided odontoidectomy for decompression of basilar invagination via a standard anterior cervical approach. *J Neurosurg Spine* 2007; 6: 184-191.
- [5] Ai FZ, Yin QS, Xu DC, Xia H, Wu ZH and Mai XH. Transoral atlantoaxial reduction plate internal fixation with transoral transpedicular or articular mass screw of C2 for the treatment of irreducible atlantoaxial dislocation: two case reports. *Spine (Phila Pa 1976)* 2011; 36: E556-E562.
- [6] Iacoangeli M, Gladi M, Alvaro L, Di Rienzo A, Specchia N and Scerrati M. Endoscopic endonasal odontoidectomy with anterior C1 arch preservation in elderly patients affected by rheumatoid arthritis. *Spine J* 2013; 13: 542-548.
- [7] Choi D and Crockard HA. Evolution of transoral surgery: three decades of change in patients, pathologies, and indications. *Neurosurgery* 2013; 73: 296-303.
- [8] Xia H, Yin Q, Ai F, Ma X, Wang J, Wu Z, Zhang K, Liu J and Xu J. Treatment of basilar invagination with atlantoaxial dislocation: atlantoaxial joint dislocation and fixation with transoral atlantoaxial reduction plate (TARP) without odontoidectomy. *Eur Spine J* 2014; 23: 1648-1655.
- [9] Klekamp J. Treatment of basilar invagination. *Eur Spine J* 2014; 23: 1656-1665.

- [10] Abumi K, Takada T, Shono Y, Kaneda K and Fujiya M. Posterior occipitocervical reconstruction using cervical pedicle screws and plate-rod systems. *Spine (Phila Pa 1976)* 1999; 24: 1425-1434.
- [11] Peng X, Chen L, Wan Y and Zou X. Treatment of primary basilar invagination by cervical traction and posterior instrumented reduction together with occipitocervical fusion. *Spine (Phila Pa 1976)* 2011; 36: 1528-1531.
- [12] Wang C, Yan M, Zhou HT, Wang SL and Dang GT. Open reduction of irreducible atlantoaxial dislocation by transoral anterior atlantoaxial release and posterior internal fixation. *Spine (Phila Pa 1976)* 2006; 31: E306-313.
- [13] Goel A and Shah A. Atlantoaxial joint distraction as a treatment for basilar invagination: a report of an experience with 11 cases. *Neurol India* 2008; 56: 144-150.
- [14] Goel A and Laheri V. Re: Harms J and Melcher P. Posterior C1-C2 fusion with polyaxial screw and rod fixation. (*Spine* 2001; 26: 2467-71). *Spine (Phila Pa 1976)* 2002; 27: 1589-1590.
- [15] Wang S, Wang C, Liu Y, Yan M and Zhou H. Anomalous vertebral artery in craniovertebral junction with occipitalization of the atlas. *Spine (Phila Pa 1976)* 2009; 34: 2838-2842.
- [16] Patel AJ, Boatey J, Muns J, Bollo RJ, Whitehead WE, Giannoni CM and Jea A. A Endoscopic endonasal odontoidectomy in a child with chronic type 3 atlantoaxial rotatory fixation: case report and literature review. *Childs Nerv Syst* 2012; 28: 1971-1975.
- [17] Goel A. Treatment of basilar invagination by atlantoaxial joint distraction and direct lateral mass fixation. *J Neurosurg Spine* 2004; 1: 281-286.
- [18] Yoshizumi T, Murata H, Ikenishi Y, Sato M, Takase H, Tateishi K, Nakanowatari S, Suenaga J and Kawahara N. Occipitocervical fusion with relief of odontoid invagination: atlantoaxial distraction method using cylindrical titanium cage for basilar invagination-case report. *Neurosurg Rev* 2014; 37: 519-524.
- [19] Guo SL, Zhou DB, Yu XG, Yin YH and Qiao GY. Posterior C1-2 screw and rod instrument for reduction and fixation of basilar invagination with atlantoaxial dislocation. *Eur Spine J* 2014; 23: 1666-1672.
- [20] Young RM, Sherman JH, Wind JJ, Litvack Z and O'Brien J. Treatment of craniocervical instability using a posterior-only approach: report of 3 cases. *J Neurosurg Spine* 2014; 21: 239-248.