

Case Report

Correction of migrated peritoneal dialysis catheter using processed gastroscopic brush: report of six cases and method description

Wenpeng Cui, Hongbin Zou, Guangdong Sun, Jing Sun, Xiaohua Zhuang, Ping Luo, Lining Miao, Wenhua Zhou

Department of Nephrology, Second Hospital of Jilin University, 218 Ziqiang Street, Changchun 130041, Jilin, China

Received September 7, 2015; Accepted April 9, 2016; Epub June 15, 2016; Published June 30, 2016

Abstract: Catheter malfunction caused by migration of the catheter tip is an ongoing challenge in patients on continuous ambulatory peritoneal dialysis. Reimplantation of a new catheter by open operation exposes the patient to additional hazards and costs. Non-operative treatment such as manual reduction, appropriate exercises and purgative enema tend to have a poor success rate. In this study, we report our experience with six patients on continuous ambulatory peritoneal dialysis in whom the migrated catheter tip was restored to the pelvic cavity with use of a processed gastroscopic brush.

Keywords: Catheter migration, gastroscopic brush, peritoneal dialysis

Introduction

Peritoneal dialysis (PD) catheter migration refers to its displacement from the site of its original insertion in the pelvis to upper abdomen. Migration of the catheter tip, which occurs in about 10-20% of all patients on peritoneal dialysis, is a common complication of continuous ambulatory peritoneal dialysis (CAPD) [1-3]. The catheter tip migration-induced catheter malfunction inevitably compromises fluid drainage. A number of reports have described techniques for prevention of catheter dislocation [1, 4, 5], however, remedial measures in the event of this complication are not well documented. Apart from reimplantation of a new catheter by open operation, non-operative treatment modalities include manual reduction, appropriate exercises, and purgative enema. Use of guide wire under x-ray fluoroscopic guidance has recently been described [6, 7]. However, the lack of sturdiness in the guide wire limits its ability to change the position of the catheter tip. In this study, we present our experience with a new technique that involves use of gastroscopic brush instead of the guide wire for catheter reduction.

Materials and methods

From April 2014 to July 2015, a total of six (two men and four women; age range: 24 to 59 years) patients with end-stage renal disease on CAPD presented with catheter tip migration at the Second Hospital of Jilin University. All patients had been implanted with a double-cuff, straight Tenckhoff catheter for an average duration of 108 days (range, 9-417 days). Gastroscopic brush obtained from Olympus Company was cut into four 50-cm segments. Single or both ends of the segment were transformed into blunt heads by electric welding (**Figure 1A-C**). All processed gastroscopic brushes (PGBs) were sterilized by ethylene oxide prior to their use.

All patients underwent abdominal radiograph examination to confirm catheter displacement, as well as to determine the specific location of the catheter tip (**Figure 2A**). Patients were made to lie on the operating table and standard disinfection performed. The external tube was removed and the PGB was inserted into the Tenckhoff catheter for 25 cm (the front blunt tip of the PGB should enter the peritoneal cavity at

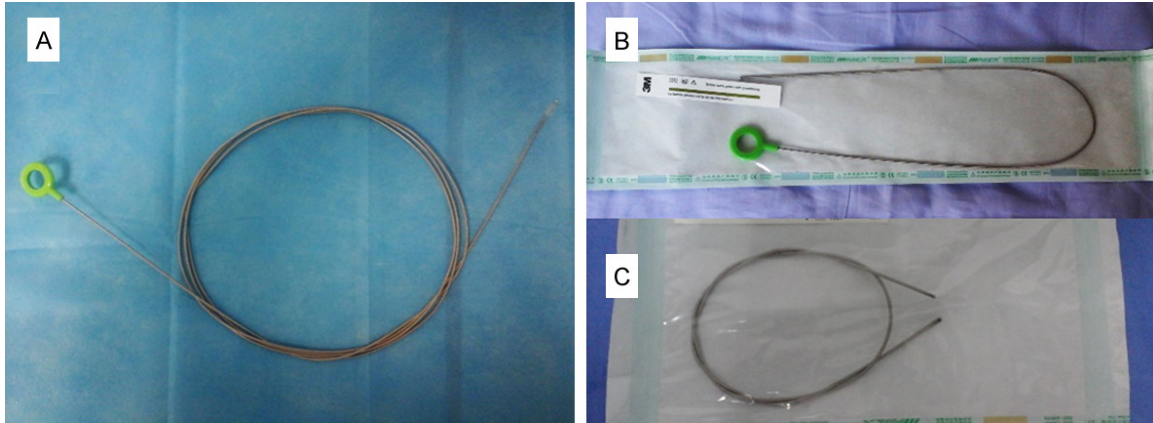


Figure 1. A. Gastroscopic brush obtained from Olympus Company. B. 50-centimeter long of processed gastroscopic brush with single blunt head. C. 50-centimeter long of processed gastroscopic brush with double blunt heads.

this time). The PGB was inserted slowly until a resistance was encountered (the front blunt tip of the PGB should meet the angle of the catheter, **Figure 2B**). Repeated drawing and insertion of the PGB was performed, until the shifted catheter tip was relocated to the vesicorectal pouch or Douglas nest or to the true pelvic cavity (**Figure 2C**). After pulling out the PGB, 200 mL physiological saline was injected through the catheter and the catheter function tested by observing the outflow. The final radiograph was taken to ascertain the correct location of the catheter tip (**Figure 2D**).

Discussion

Peritoneal dialysis catheter was first introduced by Tenckhoff in 1968. Although several different alternatives have since been introduced in an effort to replace the Tenckhoff catheter, the straight Tenckhoff catheter continues to be the most widely used catheter currently [8]. However, catheter malfunction caused by migration of the catheter tip is a recurrent challenge, both to the patients as well as to the nephrologists [1, 4].

Reasons for catheter tip migration may be broadly divided into surgery-related causes and non-surgery-related causes. The former includes improper placement of peritoneal catheter and improper placement of the subcutaneous tunnel at the time of insertion of the peritoneal catheter. In all our patients, peritoneal access surgery was performed as recommended by the International Society for Peritoneal Dialysis (ISPD) [9]. In none of the cases was the cath-

eter tip migration attributable to surgery related causes. Non surgery-related cause of catheter tip migration included abnormal intestinal peristalsis which stretched the peritoneal catheter, leading to catheter displacement in the early post-operative period, and omental wrapping. Other related or aggravating factors included: four patients developed constipation with consequent straining, and in one case the catheter was accidentally pulled out during the first week after operation. One patient always slept on his right side. Therefore, it is important to educate the patients to maintain the correct posture, sleep preferably in the supine position, and avoid abnormal intestinal pressure that may stretch the catheter.

Reimplantation of a new catheter by open operation exposes the patient to additional hazards and costs. Non-operative treatment such as manual reduction, appropriate exercises and purgative enema, tend to be associated with a poor success rate. Therefore, development of alternative safe techniques is a key imperative. Jwo et al. manipulated the migrated catheter with Lunderquist guidewire (Cook Medical) in eleven patients [6]. They demonstrated successful correction in all five cases of simple migration but failed in patients that had other difficulties, such as incorrect catheter placement at initial implantation and presence of severe catheter adhesions [6]. In consideration of the abdominal discomfort and pain during the procedure, as well as the potential for bowel injury caused by “stiff” guidewire, a “double guidewire” technique using “soft” guidewires was reported by Lee et al. [7]. In the event of

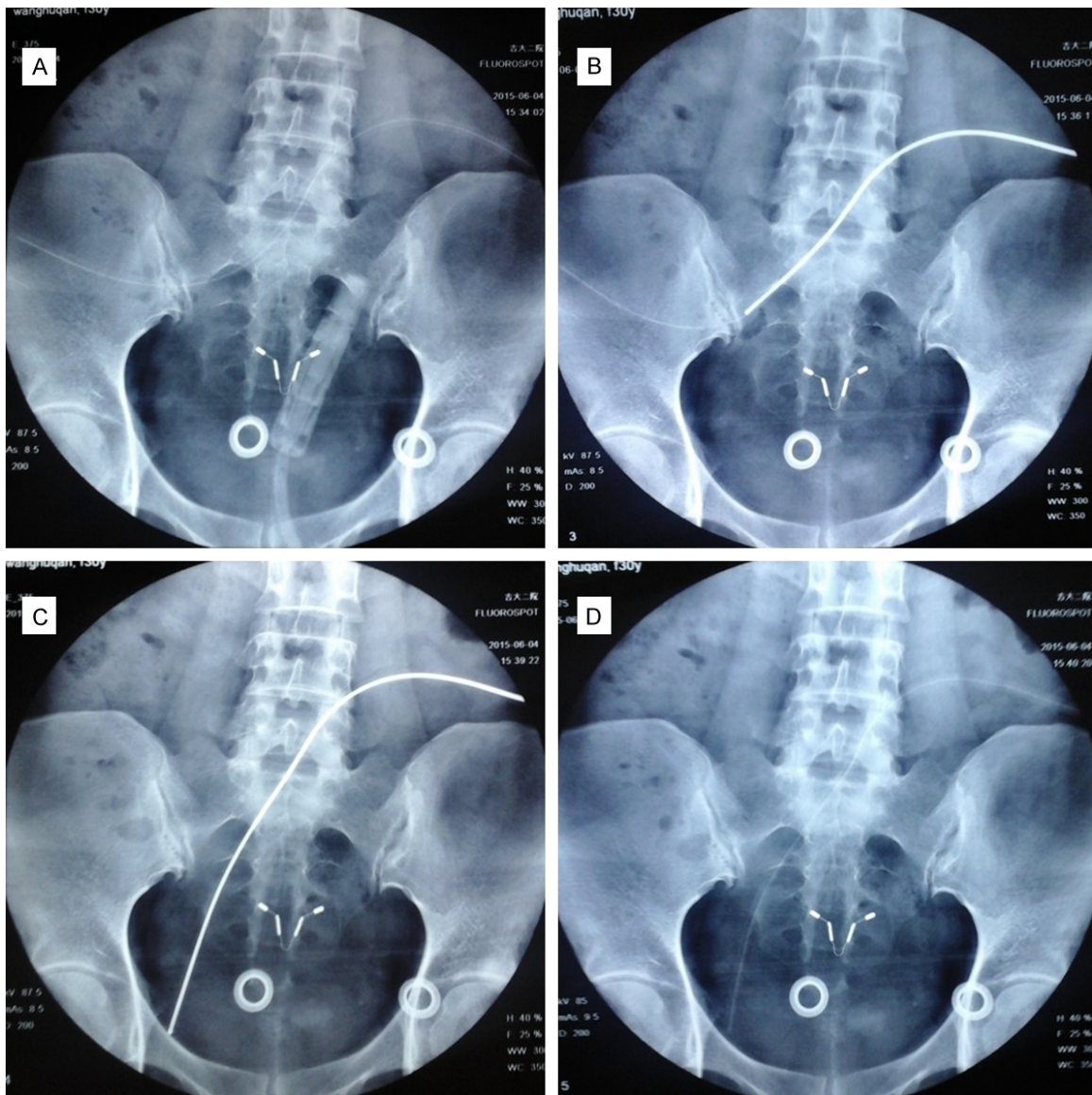


Figure 2. A. The catheter tip migrates to the right-lower abdomen. B. The front blunt tip of the processed gastroscopic brush meets the angle of the catheter. C. The processed gastroscopic brush relocates the shifted catheter tip in the true pelvic cavity. D. The processed gastroscopic brush is pulled out and the catheter tip located in the true pelvic cavity.

failure to restore the migrated catheter back into the pelvic cavity with the first guidewire, a second guidewire was introduced to reinforce and to prevent back flipping of the catheter tip at the time of withdrawal of the first guidewire. As the guidewire was too soft, another guidewire was needed, which increased the complexity of the procedure.

Here, we report a new technique which employs the use of moderately stiff PGBs; all six migrated catheters were successfully replaced. This technique has the following advantages: (1)

Simplicity, as only one PGB is needed; (2) Effectiveness, PGB has appropriate elasticity (not too soft, nor too stiff); (3) Safety, the ends of PGB are blunt and the whole procedure is performed under x-ray guidance. A limitation of this method is its inability to deal with omental wrapping or severe adhesions.

In conclusion, in the event of peritoneal dialysis catheter tip migration, we recommend use of PGB for its repositioning. Based on the encouraging results obtained in our first six patients, we believe this is a simple, safe, and effective

method for treating peritoneal dialysis catheter tip migration. The technique can be performed by any experienced nephrologists.

Acknowledgements

We would like to express our gratitude to all the physicians participating in this work.

Disclosure of conflict of interest

None.

Address correspondence to: Dr. Wenhua Zhou, Department of Nephrology, Second Hospital of Jilin University, 218 Ziqiang Street, Changchun 130041, Jilin, China. Tel: 0431-88796819; Fax: 0431-88796527; E-mail: 153762368@qq.com

References

- [1] Lan L, Jiang J, Wang P, Ren W, Hu Z. Peritoneal dialysis catheter placement in the right lower quadrant is associated with a lower risk of catheter tip migration: a retrospective single-center study. *Int Urol Nephrol* 2015; 47: 557-562.
- [2] Bergamin B, Senn O, Corsenca A, Dutkowski P, Weber M, Wuthrich RP, Segerer S, Thut MP. Finding the right position: a three-year, single-center experience with the "self-locating" catheter. *Perit Dial Int* 2010; 30: 519-523.
- [3] Liu WJ, Hooi LS. Complications after tenckhoff catheter insertion: a single-centre experience using multiple operators over four years. *Perit Dial Int* 2010; 30: 509-512.
- [4] Crabtree JH. Peritoneal dialysis catheter implantation: avoiding problems and optimizing outcomes. *Semin Dial* 2015; 28: 12-15.
- [5] Radhakrishna K, Sandeep P, Chakarpani U, Venkata Rami Reddy V, Ram R, Siva Kumar V. Insertion technique for prevention of peritoneal dialysis catheter tip migration. *Int Urol Nephrol* 2014; 46: 1867-1868.
- [6] Jwo SC, Chen KS, Lee CM, Huang CY. Correction of migrated peritoneal dialysis catheters using lunderquist guidewire: a preliminary report. *Perit Dial Int* 2001; 21: 619-621.
- [7] Lee CM, Ko SF, Chen HC, Leung TK. Double guidewire method: a novel technique for correction of migrated Tenckhoff peritoneal dialysis catheter. *Perit Dial Int* 2003; 23: 587-590.
- [8] Ouyang CJ, Huang FX, Yang QQ, Jiang ZP, Chen W, Qiu Y, Yu XQ. Comparing the Incidence of Catheter-Related Complications with Straight and Coiled Tenckhoff Catheters in Peritoneal Dialysis Patients-A Single-Center Prospective Randomized Trial. *Perit Dial Int* 2015; 35: 443-449.
- [9] Figueiredo A, Goh BL, Jenkins S, Johnson DW, Mactier R, Ramalakshmi S, Shrestha B, Struijk D, Wilkie M; International Society for Peritoneal Dialysis. Clinical practice guidelines for peritoneal access. *Perit Dial Int* 2010; 30: 424-429.