

Original Article

Herapeutic effect of wet compress of magnesium sulfate combined with vitamin B12 on chemotherapy-induced phlebitis in rabbits

Yuan Chi¹, Dan Wang², Hong-Yu Li²

¹Department of Human Resource, Liaoning Medical University, Jinzhou 121001, China; ²Institute of Medical Education, Liaoning Medical University, Jinzhou 121001, China

Received December 10, 2015; Accepted March 19, 2016; Epub June 15, 2016; Published June 30, 2016

Abstract: Objective: This study aimed to observe the therapeutic effect of wet compress of magnesium sulfate combined with vitamin B12 on doxorubicin hydrochloride-induced phlebitis in rabbits. Methods: Doxorubicin hydrochloride (0.2%, each side with 5 ml) was injected within 6 min through bilateral auricular veins to build phlebotic models in 48 rabbits. Forty eight hours later, the 48 rabbits were randomly divided into 4 groups (each group with 12 rabbits). 50% magnesium sulfate (Group A), vitamin B12 dissolved in 50% glucose (Group B), 50% magnesium sulfate combined with vitamin B12 dissolved in 50% glucose (Group C) were respectively applied to the bilateral auricular veins twice a day for a week. Rabbits in group D did not receive any treatments. Therapeutic effects were observed in all rabbits a week after treatment. Results: The effective rate was 75% in Group A, 83.33% in Group B, 91.67% in Group C and 16.67% in Group D, respectively. The effective rate was significantly higher in Group C than in Groups A, B and D (all $P < 0.05$). Conclusion: Vitamin B12 dissolved in 50% glucose combined with 50% magnesium sulfate can significantly improve the therapeutic effect on doxorubicin hydrochloride-induced phlebitis.

Keywords: Doxorubicin hydrochloride, chemotherapy-induced phlebitis, nursing care, animal experiment, rabbit

Introduction

As tumor incidence is increasing in China year by year, infusion of chemotherapeutics through peripheral vein has become one of the major means for treatment of tumors. However, most anti-cancer drugs have stimulative effect on local tissues and blood vessels, consequently readily leading to phlebitis [1]. Catheter-related complications may occur in most patients, even catheter-related bloodstream infection (CRBSI) may also appear in severe cases [2, 3]. In this study, we built chemotherapy-induced rabbit-auricular phlebitis models, and then applied different liquid drugs to the skin around the bilateral auricular phlebitis. A week later, we compared the therapeutic effect among these groups to find the optimal scheme for treatment of phlebitis.

Materials and methods

All study methods were approved by ethics committee of Liaoning Medical University.

Animals

Forty eight healthy Japanese big-ear rabbits of either sexes weighing between 2.5 kg and 3.0 kg were provided by the Animal Experiment Center of Liaoning Medical University. The 48 rabbits had no auricular vein variation with normal vascular course. Diet and movement were normal in the 48 rabbits within a week before experiment.

Reagents and apparatus

Weighing scale, paraffin section machine, optical microscope, 10 ml and 5 ml-disposable sterile syringes, disposable venous infusion needles, surgical knife and scissors, disposable skin preparation bag, iodophors, gossypium absorbens, disposable sterile latex gloves, disposable adhesive stickers, fixed box for rabbit's head, doxorubicin hydrochloride from Dalian Meilun Biological Technology Co. Ltd (Dalian, China), 0.9% sodium chloride injection, 10% formaldehyde solution, 10% chloral hyd-

Chemotherapy-induced phlebitis

Table 1. Incidence of phlebitis in each group 48 hours after injection of doxorubicin hydrochloride (before treatment)

Groups	Phlebitis [auricular vein (n) = 24]				Incidence of phlebitis (%)
	Grade 0	Grade I	Grade II	Grade III	
Group A	4	14	4	2	83.33
Group B	0	12	8	4	100.00
Group C	2	12	10	0	91.67
Group D	2	10	6	6	91.67

Notes: Group A: 50% magnesium sulfate; Group B: vitamin B12 dissolved in 50% glucose; Group C: 50% magnesium sulfate combined with vitamin B12 dissolved in 50% glucose; Group D: control group. $\chi^2 = 2.182, P = 0.536$.

Table 2. Therapeutic effects for rabbit's auricular veins in each group [auricular vein (n) = 24]

Groups	Marked effect	Effective-ness	No response	Effective rate (%)
Group A	8	10	6	75.00
Group B	6	14	4	83.33
Group C	20	2	2	91.67
Group D	2	2	20	16.67

Notes: Group A: 50% magnesium sulfate; Group B: vitamin B12 dissolved in 50% glucose; Group C: 50% magnesium sulfate combined with vitamin B12 dissolved in 50% glucose; Group D: control group. Comparisons among the four groups: $P = 0.000$; comparison between Group C and Group A: $P = 0.045$; comparison between Group C and Group B: $P = 0.020$; comparison between Group C and Group D: $P = 0.000$.

rate, 50% glucose solution, 50% adlerika and parenteral solution of vitamin B12 were used in this study.

Grouping

The 48 rabbits were randomly divided into 4 groups including Groups A, B, C and D. In Group A, 20 ml of 50% magnesium sulfate was used; in Group B, vitamin B12 (500 µg) dissolved in 20 ml of 50% glucose was used and in Group C, 20 ml of 50% magnesium sulfate combined with vitamin B12 (500 µg) dissolved in 20 ml of 50% glucose was used. Rabbits in group D did not receive any treatments as a control group.

Establishment of chemotherapy-induced rabbit-auricular phlebitis models

Rabbits were fixed, but their heads and both ears were exposed. After hairs around the location of bilateral auricular veins were shaved and injection site sterilized, centripetal punc-

ture was performed on the bilateral auricular veins. When 5 cm of pinhead entered the auricular vein, 2 ml of 0.9% sodium chloride injection was given to confirm success of puncture. Next, doxorubicin hydrochloride solution (0.2%, each side with 5 ml) was injected within 6 min followed by washing using 2 ml of 0.9% sodium chloride injection. Finally, the puncture point was marked.

Interventions

Forty eight hours later, the 48 rabbits were randomly divided into Groups A, B, C and D (each group with 12 rabbits). Gauze was immersed in liquid medicine, and then applied to the skin around bilateral auricular veins within an area of 15 cm² (length of 5 cm × width of 3 cm) twice a day for a week. Each intervention lasted for 20 min.

Samples

A week after intervention, each auricular vein was observed with the naked eye followed by taking auricular vein of 1.5 cm × 0.4 cm from rabbits after they were anesthetized by intraperitoneal injection of 10% chloral hydrate per 5 ml/kg. Samples were fixed with 10% of formal, embedded in paraffin, stained with hematoxylin and eosin (HE) followed by observation under optical microscope.

Evaluation

Based on clinical grading standards of the American Venous Transfusion Nursing Institute and excluding pain factor, rabbit's auricular vein was graded as follows: Grade 0: no phlebitis; Grade I: erythema or edema on the puncture point, but no venous cord-like changes including swelling and rubescence, and no palpable induration; Grade II: erythema or edema on the puncture point and venous cord-like changes including swelling and rubescence, but no palpable induration; Grade III: erythema or edema on the puncture point, venous cord-like changes including swelling and rubescence, and palpable induration or ulceration [4].

Therapeutic effect was evaluated as follows: no response: Phlebitis failed to improve within 7 days after intervention; effectiveness: Local skin color became light without rubefaction in 5 days after intervention; marked effect: Local

Chemotherapy-induced phlebitis

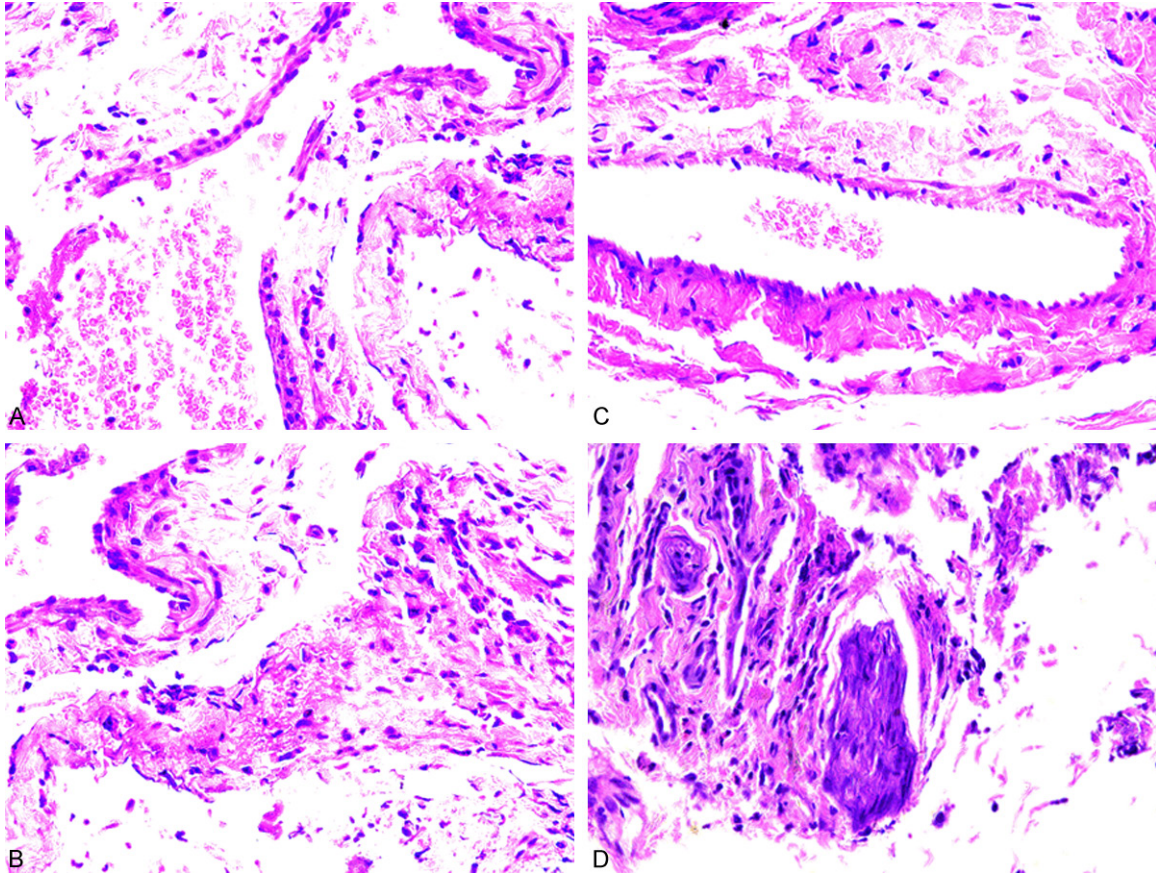


Figure 1. Inflammation cell infiltration in auricular veins in the four groups $\times 400$. Notes: Group A: 50% magnesium sulfate; Group B: Vitamin B12 dissolved in 50% glucose; Group C: 50% magnesium sulfate combined with vitamin B12 dissolved in 50% glucose; group D: Control group.

skin color became light without rubefaction in 3 days after intervention [5].

Statistical analysis

Statistical treatment was performed with SPSS17.0 software. X^2 test was used in numeration data. Kruskal-wallis H test and Mann-Whitney rank sum test were used in ranked data. Statistical significance was established at $P < 0.05$.

Results

Status of auricular phlebitis in the four groups

Varying degrees of rubescence, swelling and cord-like induration occurred around auricular vein in 48 h after injection of doxorubicin hydrochloride. Auricular phlebitis was graded in each group. X^2 test indicated that there were statistical differences in incidence of phlebitis among the four groups before treatment ($P > 0.05$, **Table 1**).

Therapeutic effects

Phlebitis got relieved in most auricular veins a week after intervention, particularly in Group C. Kruskal-wallis H test indicated a statistical significance in effective rate among the four groups ($P < 0.05$). Further comparison between two groups (Mann-Whitney rank sum test) displayed that effective rate was significantly higher in Group C than in Groups A, B and D, respectively (all $P < 0.05$, **Table 2**).

HE staining

There was a marked inflammatory cell infiltration and severe vascular endothelium injury in Group D. Vascular endothelium injury and inflammatory cell infiltration were the slightest in Group C. There were varying degrees of inflammatory cell infiltration and vascular endothelium injury in both Group A and Group B (**Figure 1**).

Discussion

Chemotherapy-induced phlebitis, a kind of aseptic inflammatory reaction, mainly manifests rubescence, calor mordicans, swelling and cord-like induration along local vein [6] with an incidence of more than 57.6% [7]. Chemotherapeutic phlebitis is related to properties and concentration of chemotherapeutics, osmotic pressure and pH value [8]. Doxorubicin hydrochloride, an antitumor antibiotic of anthracyclines, is one of the most effective drugs for treatment of breast cancer. Doxorubicin hydrochloride can destroy structures and functions of cell membrane, and can strongly stimulate local blood vessels and skin due to its characteristic of being highly-efficient foaming agent; so nearly all patients receiving doxorubicin hydrochloride will have different degrees of phlebitis [9]. In addition, the incidence of phlebitis is higher in patients with tumor than in patients with other diseases, and malignant tumor is regarded as an independent risk factor for upper limb-deep venous thrombosis [10]. This is associated with secondary hypercoagulable state in patients with tumor [11] and chemotherapeutics-induced release of tissue factors when blood vessels are injured by venepuncture [12]. It is reported that the incidence of peripherally inserted central catheter (PICC)-related thrombus is high in senile patients and a history of phlebothrombosis is a major risk factor of PICC-related thrombus [13]. Therefore, chemotherapy-induced phlebitis may be also associated with type of disease, age, a history of phlebitis and infusion method [14].

In clinical practice, magnesium sulfate wet compress is usually used for treatment of phlebitis, because magnesium sulfate possesses the characteristics of high permeability and can quickly eliminate inflammatory edema of local tissue [15]. Magnesium ions can penetrate skin effectively to relax vascular smooth muscle and to relieve vascular inflammatory reaction. It is reported that wet compress may allow magnesium ions directly to act on superficial veins, greatly enhancing anti-inflammatory effect [16, 17]. This study displays that the therapeutic effect of magnesium sulfate alone is not better. Bao et al [18] have confirmed that magnesium sulfate combined with lidocaine can effectively treat phlebitis, but lidocaine, a local anesthetic, may lead to anaphylaxis and

other adverse reactions. Vitamin B12, which is extracted from liver and contains cobalt, is involved in many metabolic reactions and can promote repair and regeneration of damaged mucocutaneous epithelial cells and vascular endothelial cells. Liquid glucose can provide energy necessary for repair of damaged blood vessels [19]. Therefore, vitamin B12 combined with 50% liquid glucose can relieve inflammatory reaction of local tissue. In this study, after 50% magnesium sulfate combined with vitamin B12 dissolved in 50% glucose were applied to rabbits' phlebitic veins, repair of vascular endothelial cells and therapeutic effect were all better than that in other groups, and no adverse reactions occurred.

In summary, 50% magnesium sulfate combined with vitamin B12 dissolved in 50% glucose has better therapeutic effect on phlebitis with high safeness. It is worth widely using in clinical practice.

Disclosure of conflict of interest

None.

Address correspondence to: Hong-Yu Li, Institute of Medical Education, Liaoning Medical University, No. 40, Section 3, Songpo Road, Jinzhou 121001, China. Tel: +86-024-31085195; Fax: +86-024-31085195; E-mail: reda4673@sina.com

References

- [1] Yu L, Jiang GC, Su LR. Progress in pathogenesis of chemotherapy-induced peripheral phlebitis. *China Medical Herald* 2014; 11: 147-149.
- [2] Maki DG, Kluger DM, Crnich CJ. The risk of bloodstream infection in adults with different intravascular devices: a systematic review of 200 published prospective studies. *Mayo Clin Proc* 2006; 81: 1159-1171.
- [3] Ho KH, Cheung DS. Guidelines on timing in replacing peripheral intravenous catheters. *J Clin Nurs* 2012; 21: 1499-1506.
- [4] Yang XH, Wang YN, Meng JN, Xue GH, Bian YC, Zhao CL. Study on effect of arnebia enchroma ointment on prevention and treatment of chemotherapy-induced phlebitis. *Chinese Journal of Experimental Traditional Medical Formulae* 2010; 16: 197-199.
- [5] Lin H, Xiao LX, Sun WR, Shi MZ, Xiang X. Therapeutic effect of magnesium sulfate combined with plastic wrap on chemotherapy-induced phlebitis. *Nursing and Rehabilitation Journal* 2008; 16: 197-199.

Chemotherapy-induced phlebitis

- [6] Shi JJ, Liu LJ. Progress in the cause of chemotherapy-induced peripheral phlebitis. *Chinese Nursing Research* 2012; 26: 3361-3363
- [7] Yoh K, Niho S, Goto K, Ohmatsu H, Kubota K, Kakinuma R, Saijo N, Nishiwaki Y. Randomized trial of drip infusion versus bolus injection of vinorelbine for the control of local venous toxicity. *Lung Cancer* 2007; 55: 337-341.
- [8] Sun SM. Present condition of prevention and nursing care for chemotherapy-induced phlebitis. *Chinese General Practice Nursing* 2012; 10: 2092-2094.
- [9] Guan MM, Liu YH, Guan HY, Liu GL, He PY. Prevention of chemotherapy-induced phlebitis by Didangtang wet compress. *Guangdong Medical Journal* 2010; 31: 2307-2308.
- [10] Zhao XN, Wang YT. Progress in diagnosis and treatment of deep venous thrombosis in upper limb. *Academic Journal of Chinese PLA Medical School* 2014; 35: 92-95
- [11] Yuan SQ, Yang YF, Xu MM, Li YP, Zhang LW. Clinical significance of degradation products of serous D-Dimer and fibrinogen. *Academic Journal of Chinese PLA Medical School* 2014; 35: 896-898.
- [12] Feng JH, Zhao YJ. Prevention and nursing care of adriamycin-induced phlebitis in 43 cases. *Journal of Qilu Nursing* 2010; 16: 123-124.
- [13] Liu G, Li D, Ma Y, Xu Y, Xie X, Wang BB, Yang JH, Huo X, Li SJ. Analysis of peripherally inserted central venous catheter-related thrombus in elderly patients. *Academic Journal of Chinese PLA Medical School* 2014; 35: 1130-1132.
- [14] Qiu YJ, Wang CF. Analysis of related factors of infusion-induced phlebitis. *Journal of Shanghai Jiaotong University (Medical Science)* 2011; 31: 696-700.
- [15] Duan YL, Xiao J, Xu XL. Therapeutic effect of heparin sodium wet compress on remaining needle-induced phlebitis. *Chinese Nursing Research* 2010; 24: 215.
- [16] Ikeda S, Douchi T, Nagata Y. Use of heparin to lower the incidence of phlebitis induced by antineoplastic agents used in ovarian cancer. *J Obstet Gynaecol Res* 2004; 30: 427-429.
- [17] Du CM, Wang H, Maimaiti A. Therapeutic effect of magnesium sulfate combined with lidocaine on epirubicin-induced phlebitis. *Health Abstract* 2014; 4: 65-66.
- [18] Bao MR, Nan GL, Guan H, Zhang MX, Yang ZC, Wu KY. Therapeutic effects of magnesium sulfate of different concentrations on chemotherapy-induced phlebitis. *Chinese Nursing Research* 2013; 27: 1018-1019.
- [19] Luo YQ, Chen YX, Hu F, Huang YC, Chen MY. Therapeutic effect of high glucose combined with vitamin B12 on epirubicin-induced phlebitis. *Modern Hospital* 2011; 11: 91-92.