

## Original Article

# Expression of FAP is correlated with clinical prognosis in ovarian cancer patients

Zhiwang Song, Yun Lin, Xia Zhang, Xiaojuan Ye, Guang Yang, Chan Feng, Yonglin Lu, Chunyan Dong

Breast Cancer Center, Shanghai East Hospital, Tongji University, Shanghai 200120, People's Republic of China

Received December 21, 2015; Accepted May 4, 2016; Epub June 15, 2016; Published June 30, 2016

**Abstract:** Background: Ovarian cancer is the second most common cancer in women and the leading cause of cancer-related death from gynecological cancer. Fibroblast activation protein (FAP) is best known for its presence in stromal cancer-associated fibroblasts (CAFs). The aim of this study was to investigate the expression of FAP in ovarian cancer and its significance in clinical prognosis. Material and methods: The expression of FAP in 102 formalin-fixed and paraffin-embedded ovarian cancer tissues and the adjacent tissues were examined by immunohistochemistry (IHC). The results were semi-quantitatively scored and analyzed by chi-square test. The overall survival time (OS) were collected by follow-up and analyzed by Kaplan-Meier analysis. Results: The expression level of FAP in ovarian cancer were higher than that in the adjacent tissues ( $P<0.05$ ). FAP expression was shown to be correlated with lymph node metastasis ( $P<0.05$ ), latent distant metastasis status ( $P<0.05$ ) and FIGO histology grade ( $P<0.05$ ). In addition, we found that patients with a higher expression of FAP tended to have much shorter survival time than patients with lower FAP expression. Conclusion: High FAP expression is associated with poor prognosis in ovarian cancer and may serve as a novel prognostic marker in ovarian cancer.

**Keywords:** Ovarian cancer, fibroblast activation protein (FAP), prognosis, biomarker, immunohistochemistry

## Introduction

Ovarian cancer is the second most common cancer in women and the leading cause of cancer-related death from gynecological cancer [1]. There are 225,000 new cases diagnosed and 140,000 deaths from ovarian carcinoma annually worldwide [2]. Even though substantial advances have been already made in early detection, treatment, and basic research, it is still less than 30% for the overall 5-year survival rate [3]. The poor prognosis for ovarian cancer largely remains undetectable in early stage and lack of reliable biomarkers to evaluate its prognostic progression [4-6]. Thus, further research to identify the specific molecular and/or genetic variations in ovarian cancer could translate into improved prognosis and insight into molecular mechanisms of ovarian cancer development and progression [7].

Fibroblast activation protein (FAP) (also called seprase) is a type II integral membrane protein belonging to the family of plasma membrane-bound serine proteases [8, 9]. FAP is characterized by its ability to cleave after a proline residue. Its crystal structure has confirmed that the

enzyme exists as a homodimer and that dimerization is necessary for enzymatic function [10]. Functionally, FAP can enhance stromal cell proliferation and invasiveness, and affect cell apoptosis. The expression of FAP is highly restricted to cancer-associated fibroblasts but it is not expressed in resting fibroblasts in normal tissue, although it can be induced to express in nontransformed, activated stromal fibroblasts [11]. Especially in human malignancies, FAP expression was found on the surface of fibroblasts in many epithelial cancers, including breast cancer [12], colon cancer [13], prostate cancer [14], pancreatic cancer [15], and skin cancer [16], as well as in some soft tissue and bone sarcomas [17]. The cancer-specific distribution of FAP makes it as a potential novel prognostic marker and therapeutic target in cancer.

However, the expression of the FAP in ovarian cancer and its significance has not been examined in detail yet. In the present study, we aimed to detect the expression of FAP in ovarian cancer and analyze its correlation with the clinicopathological features of ovarian cancer via immunohistochemical method.

**Table 1.** Expression of FAP in relation to pathologic and clinical variables

Clinicopathological parameters	N <sup>2</sup>	FAP expression		$\chi^2$	P value
		+	-		
All	102	61	41		
Age (years)				0.326	0.568
<60	68	42	26		
≥60	34	19	15		
Tumor size				0.774	0.379
<10 cm	67	38	29		
≥10 cm	35	23	12		
Lymph node metastasis				25.697	<0.001
Absence	56	21	35		
Presence	46	40	6		
Latent distant metastasis				17.560	<0.001
Absence	74	35	39		
Presence	28	26	2		
Grade				26.286	<0.001
Low	64	26	38		
High	38	35	3		
Bilaterality				0.035	0.851
Unilateral	83	50	33		
Bilateral	19	11	8		

## Material and methods

### Tumor specimens and study patients

A total of 102 formalin-fixed, paraffin-embedded ovarian cancer tissues and the adjacent tissues to perform immunohistochemical staining, which were collected from January 2002 to November 2012 at East Hospital, Tongji University. Important clinical data, such as age, tumor size, lymphatic metastasis, latent metastasis, TNM stage, were collected from each patient's medical records. The follow-up time was calculated from the date of surgery to the date of death, or the last known follow-up. Before surgical therapy, none of the patients had received neoadjuvant chemotherapy, radiation therapy, or other related anti-tumor therapies. All ovarian cancer tissue samples in this study were obtained with patients' written informed consent and all experiments have been approved by the ethics committee at local Hospital. Patient characteristics were detailed in **Table 1**.

### Immunohistochemistry staining

The two-step EnVision method has been conducted to perform immunohistochemical experiments. Three magnification visions ran-

domly observed under optical microscope, the number of positive cells in no less than  $3 \times 100$  cells was record, and then calculate the positive rate of positive cells to all cells. The dyeing positive rate was included for the statistical analysis: the positive rate equal or less than 95% was treated as low expression group, otherwise, it was included in high expression group.

### Statistical analysis

The expression of FAP in ovarian cancer and adjacent cancer tissues were compared with paired Wilcoxon test. The association between clinical characteristics of ovarian cancer patients and FAP expression were using Pearson and Spearman's correlation test. The prognostic of ovarian cancer and FAP protein expression were using Kaplan-Meier survival analysis and log-rank test for univariate analysis; the significant variables resulted from univariate

test were included in the Cox multivariate regression analysis. The *P*-value less than 0.05 is considered statistically significant.

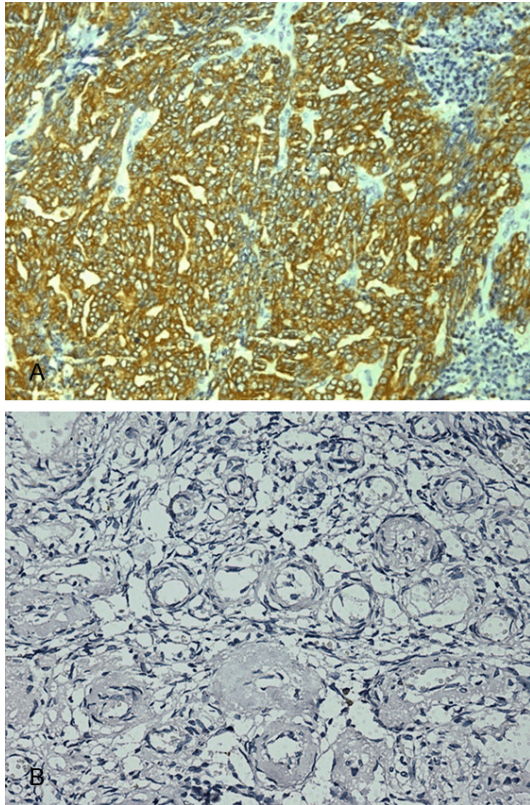
## Results

### Expression of FAP significantly increased in ovarian cancer tissues

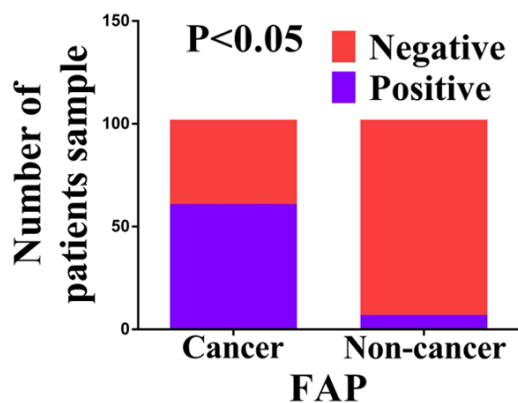
In order to determine whether FAP expression is changed in human ovarian cancer, Immunohistochemistry staining was exerted in TMA slides to evaluate the FAP expression in ovarian cancer tissues and paired adjacent non-tumor tissues (**Figure 1**). In training cohort TMA slides containing 102 cases ovarian cancer tissues with paired adjacent non-cancerous tissues, the positive percentage of FAP expression in ovarian cancer and adjacent non-tumor tissues were 59.8% (61/102) and 6.9% (7/102), respectively. There is significantly higher positive expression of FAP in ovarian cancer compared with the adjacent non-tumor tissues ( $P < 0.05$ ) (**Figure 2**).

### Increased FAP expression correlates with clinicopathological parameters

The correlation between patients' clinical parameters and the expression of FAP is shown in

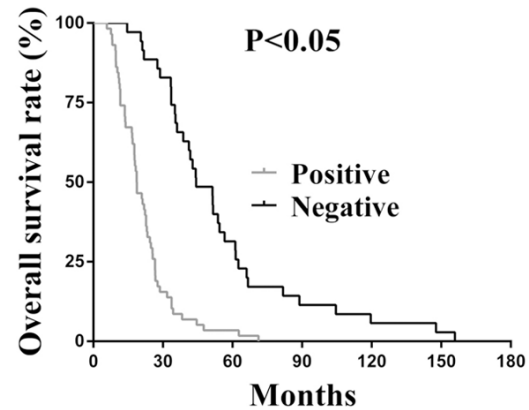


**Figure 1.** Expression of PDGF-BB of ovarian cancer tissues (A) and tissues adjacent to ovarian cancer (B) studied by immunohistochemistry in tissue microarrays [Original magnification,  $\times 200$ ].



**Figure 2.** Expression of PDGF-BB in ovarian cancer tissues compared to its adjacent tissues. Results show that there was significant difference between the groups which were statistically evaluated by chi-square test.

**Table 1.** It reveals that FAP expression in the ovarian cancer tissues is significantly correlated with lymph node metastasis (LNM) status



**Figure 3.** Kaplan-Meier survival analysis for a univariate survival analysis.

( $\chi^2 = 25.679$ ,  $P < 0.05$ ), latent distant metastasis status ( $\chi^2 = 17.560$ ,  $P < 0.05$ ) and FIGO histology grade ( $\chi^2 = 26.286$ ,  $P < 0.05$ ). However, we did not find significant correlation between FAP expression with other clinicopathologic features, including patient's age, tumor size, tumor location ( $P > 0.05$  for all). Therefore, our data demonstrates that higher FAP expression in ovarian cancer tissues is positively correlated with tumor metastasis and cancer progression, suggesting that FAP expression is involved in the progression of human ovarian cancer.

#### *Increased FAP correlates with poor patient survival*

In order to further investigate the prognostic significance of FAP expression in human ovarian cancer, we performed the log-rank survival analysis according to the FAP expression level in cancer tissues and collected survival data. The survival analysis demonstrates that the overall survival rate of the subgroup with negative expression is significantly better than that the subgroup with positive FAP expression ( $P < 0.05$ , **Figure 3**).

#### *FAP serves as an independent molecular prognostic indicator for ovarian cancer*

Moreover, multivariate analyses were conducted to confirm the possibility of FAP used as an independent risk factor for poor prognosis in the 102 cases of ovarian cancer. Multivariate Cox regression analysis confirmed FAP expression as independent predictor of the OS in ovarian cancer patients (**Table 2**).

**Table 2.** Analysis of independent correlation factors of colorectal cancer prognosis with OS by Cox multivariate regression analysis

Factors	B	S.E.	Wald	Sig.	Exp (B)	95% CI for Exp (B)	
						Lower	Upper
FAP expression	-1.327	0.288	21.185	<0.001	0.265	0.151	0.467
Age	-0.250	0.248	1.991	0.158	0.705	0.433	1.146
Tumor size	-0.320	0.233	0.019	0.889	0.968	0.613	1.528
Lymph node metastasis	-0.614	0.362	2.875	0.090	0.541	0.266	1.100
Latent distant metastasis	-0.689	0.392	3.049	0.079	0.502	0.233	1.082
Grade	-0.694	0.457	2.300	0.129	0.500	0.204	1.225

## Discussion

Ovarian cancer remains the most lethal gynecologic malignancy worldwide, and the survival rates remain low in spite of great medical advancements. Clinicopathological parameters such as tumor grade of differentiation and clinical stage have been used to evaluate the progression of ovarian cancer but their sensitivity is relatively low [18]. Due to lack of specific symptoms and early reliable biomarkers, the majority of patients present at an advanced stage (60%-70% present at stage III or stage IV) [19]. Therefore, better defining the pathogenesis, looking for useful biomarkers, and exploring novel therapeutic targets of ovarian cancer are demanding tasks [20].

A number of studies have demonstrated the expression of FAP in many tumors. It was reported that FAP was significantly overexpressed in osteosarcoma and was correlated with high histological grade, positive metastatic status and shorter overall survival [21]. It was also found that FAP was overexpressed in colon cancer and was associated with poor prognosis [22]. The expression of FAP was elevated in pancreatic ductal adenocarcinoma tissue microarrays, overexpression of FAP was relevant to the distant metastasis and poor prognosis of pancreatic adenocarcinoma [23, 24]. Our findings regarding FAP expression in ovarian cancer are consistent with the above results.

FAP, as a member of the S9B family of serine proteases, has attracted increasingly attention in recent years because it is a selective biomarker of cancer-associated fibroblasts and activated fibroblasts in tissues undergoing remodeling of their extracellular matrix due to wound healing or chronic inflammation [25]. FAP consists of 760 amino acids; an intracellular domain of six amino acids, followed by a

20-residue single pass transmembrane domain, and a 734 residue-long extracellular domain comprised of a  $\beta$ -propeller domain and a catalytic domain [26]. FAP exhibits both dipeptidyl peptidase and collagenase proteolytic activity [27]. Thus, FAP can cleave NH2-terminal dipeptides from polypeptides with L-proline or L-alanine in the penultimate position. Meanwhile, it can degrade both gelatin and native type I collagen, and thereby promote cancer cell invasion and migration [28].

Accumulating experimental evidence has demonstrated that cancer-associated fibroblasts (CAFs), can promote tumorigenesis and progression through many kinds of mechanisms, including invasion, proliferation, angiogenesis [29, 30]. FAP, as an essential component of the tumor microenvironment, is an important marker of activated CAFs. It can increase stromal cell proliferation and invasiveness, reduce cell apoptosis, and is involved in tumorigenesis and cancer progression.

Obviously, investigating the association between FAP expression and the prognosis of patients with ovarian cancer may be beneficial to understanding the underlying molecular mechanisms involved in the cancer progression and enabling the identification of novel targets for ovarian cancer treatment. In the present study, FAP expression is shown to be correlated with lymph node metastasis, latent distant metastasis status and FIGO histology grade, suggesting that FAP may be involved in the carcinogenesis and metastasis of ovarian cancer. In addition, we found that patients with a higher expression of FAP tended to have much shorter survival time than patients with lower FAP expression, indicating that high FAP expression is a potential biomarker for predicting the poor prognosis of ovarian cancer.



## Conclusions

In conclusion, the expression of FAP is increased in ovarian cancer tissues and it is correlated with lymph node metastasis, latent distant metastasis status and FIGO histology grade. In addition, high expression of FAP was associated with poorer survival and served as an independent prognostic factor in patients with ovarian cancer; suggesting that FAP may be a promising prognostic biomarker for ovarian cancer. However, the relatively small sample of this study is a limitation; a larger sample size would definitely be desirable with longer follow-up to firmly establish the diagnostic value of FAP in ovarian cancer. In addition, further studies are needed to elucidate the role of FAP in ovarian cancer at the cellular level.

## Acknowledgements

This research was supported in part by the National Nature Science Foundation of China (81573008), National Nature Science Foundation of China (81201798), the Fund of Pudong Health Bureau of Shanghai (PWRd2014-01) and the Project of Key Disciplines Group Construction of Pudong Health Bureau of Shanghai (PWZxq2014-04).

## Disclosure of conflict of interest

None.

**Address correspondence to:** Chunyan Dong, Shanghai East International Medical Center, 150 Jimo Road, Shanghai 200120, People's Republic of China. Tel: +86-13370029736; E-mail: 18662076641@163.com

## References

- [1] Eskander RN and Tewari KS. Incorporation of anti-angiogenesis therapy in the management of advanced ovarian carcinoma—mechanistics, review of phase III randomized clinical trials, and regulatory implications. *Gynecol Oncol* 2014; 132: 496-505.
- [2] Zhang B, Cai FF and Zhong XY. An overview of biomarkers for the ovarian cancer diagnosis. *Eur J Obstet Gynecol Reprod Biol* 2011; 158: 119-123.
- [3] Bast RC Jr, Hennessy B and Mills GB. The biology of ovarian cancer: new opportunities for translation. *Nat Rev Cancer* 2009; 9: 415-428.
- [4] Simon AE, Wardle J, Grimmett C, Power E, Corker E, Menon U, Matheson L and Waller J. Ovarian and cervical cancer awareness: development of two validated measurement tools. *J Fam Plann Reprod Health Care* 2012; 38: 167-174.
- [5] Su Z, Graybill WS and Zhu Y. Detection and monitoring of ovarian cancer. *Clin Chim Acta* 2013; 415: 341-345.
- [6] Tognon G, Carnazza M, Ragnoli M, Calza S, Ferrari F, Gambino A, Zizioli V, Notaro S, Sostegni B and Sartori E. Prognostic factors in early-stage ovarian cancer. *Ecancermedical-science* 2013; 7: 325.
- [7] Lv Q, Sun H, Cao C, Gao B and Qi Y. Overexpression of tumor necrosis factor receptor-associated protein 1 (TRAP1) are associated with poor prognosis of epithelial ovarian cancer. *Tumour Biol* 2016; 37: 2721-7.
- [8] Wikberg ML, Edin S, Lundberg IV, Van Guelpen B, Dahlin AM, Rutegard J, Stenling R, Oberg A and Palmqvist R. High intratumoral expression of fibroblast activation protein (FAP) in colon cancer is associated with poorer patient prognosis. *Tumour Biol* 2013; 34: 1013-1020.
- [9] Yuan D, Liu B, Liu K, Zhu G, Dai Z and Xie Y. Overexpression of fibroblast activation protein and its clinical implications in patients with osteosarcoma. *J Surg Oncol* 2013; 108: 157-162.
- [10] Aertgeerts K, Levin I, Shi L, Snell GP, Jennings A, Prasad GS, Zhang Y, Kraus ML, Salakian S, Sridhar V, Wijnands R and Tennant MG. Structural and kinetic analysis of the substrate specificity of human fibroblast activation protein alpha. *J Biol Chem* 2005; 280: 19441-19444.
- [11] Zhang J, Valianou M, Simmons H, Robinson MK, Lee HO, Mullins SR, Marasco WA, Adams GP, Weiner LM and Cheng JD. Identification of inhibitory scFv antibodies targeting fibroblast activation protein utilizing phage display functional screens. *FASEB J* 2013; 27: 581-589.
- [12] Huang Y, Simms AE, Mazur A, Wang S, Leon NR, Jones B, Aziz N and Kelly T. Fibroblast activation protein-alpha promotes tumor growth and invasion of breast cancer cells through non-enzymatic functions. *Clin Exp Metastasis* 2011; 28: 567-579.
- [13] Wang ZH, Ding KF, Yu JK, Zhai XH, Ruan SQ, Wang SW, Zhu YL, Zheng S and Zhang SZ. Proteomic analysis of primary colon cancer-associated fibroblasts using the SELDI-ProteinChip platform. *J Zhejiang Univ Sci B* 2012; 13: 159-167.
- [14] LeBeau AM, Brennen WN, Aggarwal S and Denmeade SR. Targeting the cancer stroma with a fibroblast activation protein-activated

- promelittin protoxin. *Mol Cancer Ther* 2009; 8: 1378-1386.
- [15] Lee HO, Mullins SR, Franco-Barraza J, Valianou M, Cukierman E and Cheng JD. FAP-overexpressing fibroblasts produce an extracellular matrix that enhances invasive velocity and directionality of pancreatic cancer cells. *BMC Cancer* 2011; 11: 245.
- [16] Canady J, Arndt S, Karrer S and Bosserhoff AK. Increased KGF expression promotes fibroblast activation in a double paracrine manner resulting in cutaneous fibrosis. *J Invest Dermatol* 2013; 133: 647-657.
- [17] Dohi O, Ohtani H, Hatori M, Sato E, Hosaka M, Nagura H, Itoi E and Kokubun S. Histogenesis-specific expression of fibroblast activation protein and dipeptidylpeptidase-IV in human bone and soft tissue tumours. *Histopathology* 2009; 55: 432-440.
- [18] Liao L, Wang J, Ouyang S, Zhang P, Wang J and Zhang M. Expression and clinical significance of microRNA-1246 in human oral squamous cell carcinoma. *Med Sci Monit* 2015; 21: 776-781.
- [19] Ozols RF, Bundy BN, Greer BE, Fowler JM, Clarke-Pearson D, Burger RA, Mannel RS, DeGeest K, Hartenbach EM, Baergen R and Gynecologic Oncology G. Phase III trial of carboplatin and paclitaxel compared with cisplatin and paclitaxel in patients with optimally resected stage III ovarian cancer: a Gynecologic Oncology Group study. *J Clin Oncol* 2003; 21: 3194-3200.
- [20] Jiang G, Yang D, Wang L, Zhang X, Xu H, Miao Y, Wang E and Zhang Y. A novel biomarker ARMc8 promotes the malignant progression of ovarian cancer. *Hum Pathol* 2015; 46: 1471-1479.
- [21] Yuan DT, Liu BB, Liu KX, Zhu GT, Dai ZT and Xie Y. Overexpression of fibroblast activation protein and its clinical implications in patients with osteosarcoma. *J Surg Oncol* 2013; 108: 157-162.
- [22] Wikberg ML, Edin S, Lundberg IV, Van Guelpen B, Dahlin AM, Rutegard J, Stenling R, Oberg A and Palmqvist R. High intratumoral expression of fibroblast activation protein (FAP) in colon cancer is associated with poorer patient prognosis. *Tumor Biology* 2013; 34: 1013-1020.
- [23] Kawase T, Yasui Y, Nishina S, Hara Y, Yanatori I, Tomiyama Y, Nakashima Y, Yoshida K, Kishi F, Nakamura M and Hino K. Fibroblast activation protein-alpha-expressing fibroblasts promote the progression of pancreatic ductal adenocarcinoma. *BMC Gastroenterol* 2015; 15: 109.
- [24] Shi M, Yu DH, Chen Y, Zhao CY, Zhang J, Liu QH, Ni CR and Zhu MH. Expression of fibroblast activation protein in human pancreatic adenocarcinoma and its clinicopathological significance. *World J Gastroenterol* 2012; 18: 840-846.
- [25] Wolf BB, Quan C, Tran T, Wiesmann C and Sutherlin D. On the edge of validation-cancer protease fibroblast activation protein. *Mini-Rev Med Chem* 2008; 8: 719-727.
- [26] Kelly T. Fibroblast activation protein-alpha and dipeptidyl peptidase IV (CD26): cell-surface proteases that activate cell signaling and are potential targets for cancer therapy. *Drug Resist Updat* 2005; 8: 51-58.
- [27] Torihashi S, Ho M, Kawakubo Y, Komatsu K, Nagai M, Hirayama Y, Kawabata Y, Takenaka-Ninagawa N, Wanachewin O, Zhuo L and Kimata K. Acute and temporal expression of tumor necrosis factor (TNF)-alpha-stimulated gene 6 product, TSG6, in mesenchymal stem cells creates microenvironments required for their successful transplantation into muscle tissue. *J Biol Chem* 2015; 290: 22771-22781.
- [28] Watson DI, Ellis T, Leeder PC, Neuhaus SJ, Dodd T and Jamieson GG. Excision of laparoscopic port sites increases the likelihood of wound metastases in an experimental model. *Surg Endosc* 2003; 17: 83-85.
- [29] Kidd S, Spaeth E, Watson K, Burks J, Lu H, Klopp A, Andreeff M and Marini FC. Origins of the tumor microenvironment: quantitative assessment of adipose-derived and bone marrow-derived stroma. *PLoS One* 2012; 7: e30563.
- [30] Shimoda M, Mellody KT and Orimo A. Carcinoma-associated fibroblasts are a rate-limiting determinant for tumour progression. *Semin Cell Dev Biol* 2010; 21: 19-25.