

## Original Article

# Sildenafil ameliorated meconium-induced acute lung injury in a neonatal rat model

Jia Song<sup>1</sup>, Yang-Yang Wang<sup>2</sup>, Ping Song<sup>2</sup>, Lu-Peng Li<sup>2</sup>, You-Fei Fan<sup>1</sup>, Yu-Lin Wang<sup>1</sup>

<sup>1</sup>Department of Pediatrics, Shandong Provincial Hospital Affiliated to Shandong University, Jinan 250021, China;

<sup>2</sup>Department of Pharmacology, Shandong University School of Medicine, Jinan 250012, China

Received December 23, 2015; Accepted April 3, 2016; Epub June 15, 2016; Published June 30, 2016

**Abstract:** Background: Meconium aspiration syndrome (MAS) remains one of the principle causes of neonatal death. Inflammation, oxidation and apoptosis play a crucial role in the pathophysiology of MAS. This study aimed to evaluate the effect of phosphodiesterase-5 inhibitor sildenafil in meconium-induced lung injury. Methods: Twenty-four neonatal Wistar rats were randomly divided into M (meconium), S (sildenafil), D (dexamethasone) and C (control) groups. Acute lung injury was induced by endotracheal instillation of human meconium (60 mg/ml, 2 ml/kg). After meconium instillation, rats in the S and D groups received sildenafil (25 mg/kg, ig.) and dexamethasone (1 mg/kg, ig.), respectively; while rats in the C and M groups both received saline (2 ml/kg, ig.). Rats were sacrificed at six hours for histopathological, biochemical, immunohistochemical and TUNEL analyses of lung damage indicators. Results: We found that sildenafil treatment attenuated meconium-induced acute lung injury as evaluated by histopathological changes and lung injury score. Sildenafil administration reduced meconium-induced inflammation as measured by myeloperoxidase (MPO) activity in lungs and tumor necrosis factor- $\alpha$  (TNF- $\alpha$ ) levels in serum, suppressed oxidative stress as assessed by nitric oxide (NO) levels, superoxide dismutase (SOD) activity and malondialdehyde (MDA) levels in lung tissues, and attenuated apoptosis as assayed by pro-apoptotic (Bax) and anti-apoptotic (Bcl-2) products in lung tissues. In addition, sildenafil increased cAMP and cGMP levels in serum. Conclusion: These results indicate that sildenafil could protect meconium-induced lung injury through the inhibition of inflammation, oxidative stress and apoptosis.

**Keywords:** Meconium aspiration, lung injury, sildenafil, inflammation, oxidative stress, apoptosis

## Introduction

Meconium aspiration syndrome (MAS) is a serious respiratory disorder in term and post-term neonates. Its incidence is 1.2~2.0% in liveborn infants, while its mortality reaches 3-12% [1]. Aspirated meconium obstructs peripheral airways and induces diffuse lung injury characterized by increases in pro-inflammatory cytokines, reactive oxygen species and apoptosis. All these aforementioned substances subsequently participated in pulmonary surfactant impairment, parenchymal disruption, edema and alveolar hemorrhage.

Based on its pathogenesis, the pharmacological treatment of meconium-induced lung injury has relied on various anti-inflammatory drugs such as glucocorticoids, inhibitors of angiotensin-converting enzyme, inhibitors of cyclooxy-

genase, antioxidants, etc. [2] However, the application of these drugs has been refuted due to the incidence of long-term adverse events, unideal effects or financial burden. Due to less incidence in side effects, selective phosphodiesterase (PDE) inhibitors (particularly PDE 3, 4, 5 and 7) have been introduced in the treatment of inflammation and bronchoconstriction-related respiratory disorders [3-5]. In pulmonary arterial hypertension (PAH) secondary to MAS, sildenafil, as a selective PDE5 inhibitor, blunted the meconium-induced increase in pulmonary vascular resistance via inhibiting the breakdown of cGMP to GMP and increasing cGMP levels [6, 7]. Therefore, this has been approved for the treatment of PAH [8]. In previous studies, sildenafil has been claimed to attenuate inflammation, improve oxidative damage and reverse apoptosis [9-11]. The protective effects of sildenafil have been demon-

## Sildenafil in acute lung injury

strated in acute lung injury, acute respiratory distress syndrome and lung ischemia-reperfusion injury [12-14].

In the present study, we hypothesize that sildenafil, alongside its modulatory effects on inflammation, may reduce oxidative damage and apoptosis in a neonatal rat model of meconium-induced lung injury. In addition, we hypothesize that the effect of sildenafil is comparable with dexamethasone, which has been proven to be effective in meconium-induced early lung injury.

### Material and methods

#### *Animals and reagents*

A total of 24 male newborn Wistar rats (age: 14-21 days, weight:  $28 \pm 4.7$  g) were obtained from the Experimental Animal Centre of Shandong University School of Medicine. Animal experiments and procedures were conducted in accordance with national guidelines for the use and care of laboratory animals, and were approved by Shandong University's local animal care committee. Sildenafil (brand name: viagra, 100 mg/per pill) was purchased from Pfizer Inc. (Lot: J50452). Dexamethasone was purchased from Chenxin Pharmaceutical Co. Ltd (Lot: 1411212121).

#### *Meconium preparation*

Meconium was collected from the first stools of healthy term human neonates. Samples were initially frozen, and later pooled and lyophilized. Due to the preliminary finding of lung injury caused by different meconium concentrations (30, 60 and 90 mg/ml; diluted with sterile saline), a concentration of 60 mg/ml has been proven to induce diffuse lung injury at six hours without sacrifice.

#### *Experimental protocol*

Animals were anesthetized with pentobarbital (40 mg/kg) intraperitoneally. A 24 G venous indwelling needle catheter (without core) was inserted into the trachea. All rats were randomly divided into four groups as follows. (1) M group ( $n=6$ ): A bolus of meconium (60 mg/ml, 2 ml/kg) was instilled into the lung, and normal saline (2 ml/kg) was administered by lavage 30 minutes later. (2) S group ( $n=6$ ): Meconium was intracheally instilled, and sildenafil (25 mg/kg) was injected by lavage 30 minutes later

[15]. (3) D group ( $n=6$ ): Each rat was fed by dexamethasone (1 mg/kg) 30 minutes after meconium was instilled. (4) C group ( $n=6$ ): Identical volume of normal saline was injected into the lung and administered by lavage. An injection of 1 ml of air was administered intracheally after meconium or saline to facilitate diffusion. The catheter was removed quickly after the intervention.

#### *Sample collection*

All rats were sacrificed with pentobarbital after six hours of follow-up. Blood samples were collected and centrifuged at 3,000 g for 10 minutes. Serum layers were stored at  $-20^{\circ}\text{C}$  for analysis. Lungs were extracted. Left lung tissues were washed, minced, and homogenized using a homogenizer at  $0-4^{\circ}\text{C}$ . Right anterior and middle lobes of the lung were stored in liquid nitrogen for real-time PCR analysis. Right posterior and accessory lobes of the lung were fixed with 4% paraformaldehyde, dehydrated, cleared and embedded in paraffin, according to the routine process for histological, immunohistochemical and TUNEL analyses.

#### *Lung injury assessment*

Five- $\mu\text{m}$  sections were stained with hematoxylin and eosin for light microscopic analysis. In order to determine the extent and severity of lung tissue injury, a pathologist blinded to the grouping of the piglets examined the samples and assigned a score from zero to four for three different characteristics: (1) extension of leukocyte infiltration (0=0%, 1=0-25%, 2=25-50%, 3=50-75%, and 4=75-100%), (2) amount of intra-alveolar leukocytes (0=none, 1=occasional, 2=several leukocytes in the alveoli, 3=alveoli almost full of leukocytes, 4=alveoli distended by tightly packed leukocytes), and (3) the amount of exudative debris (0=alveoli open, 1=exudate scarcely seen, 2=exudate clearly visible, 3=alveoli almost full of exudate, and 4=alveoli distended by exudate). Histologic lung injury score is defined as the sum of all these scores. Five high-power fields from hematoxylin-eosin stained sections were viewed (magnification  $\times 200$ ).

#### *Biochemical investigation of lung tissues and serum*

TNF- $\alpha$ , cAMP and cGMP levels in serum were determined using Elisa kits (R&D, USA). Lung

## Sildenafil in acute lung injury

superoxide dismutase (SOD) activity, myeloperoxidase (MPO) activity, NO and MDA concentrations were assayed using assay kits (Nanjing Jiancheng Corp., Nanjing, China). Analyses were performed according to manufacturer's instructions.

### *Real-time PCR for mRNA analysis of TNF- $\alpha$ , Bax and Bcl-2*

Total RNA was extracted using Trizol reagent (Takara, Japan), according to manufacturer's instructions. One microgram of total RNA was reverse transcribed using a Prime Script cDNA Synthesis kit (Takara, Japan). Real-time PCR was performed using the SYBR Premix Ex (Takara, Japan) on Applied Biosystems 9300, according to manufacturer's protocol. The following primers (Sangong, Shanghai, China) were used for mRNA amplification: Bcl-2 sense: 5'-CCAGAATCAAGTGTTCGCATA-3', Bcl-2 antisense: 5'-GCGTTCGGTTGCTCTCA-3'; Bax sense: 5'-CAGGCGAATTGGCGATGAA-3', Bax antisense: 5'-TGGTGAGTGAGGCAGTGAG-3'; TNF- $\alpha$  sense: 5'-TGGCGTGTTCATCCGTTCT-3', TNF- $\alpha$  antisense: 5'-CTGAGCATCGTAGTTGTTGGAA-3';  $\beta$ -actin sense: 5'-CATCTCTTGCTCGAAGTCCA-3',  $\beta$ -actin antisense: 5'-ATCATGTTTGAGACCTTCAACA-3'. The geometric mean of housekeeping gene  $\beta$ -actin was used as an internal control to normalize variability in expression levels. Expression data were normalized to the geometric mean of housekeeping gene  $\beta$ -actin to control the variability in expression levels, which were analyzed using the  $2^{-\Delta\Delta CT}$  method.

### *Western blot analysis of Bax and Bcl-2*

Total proteins were extracted and protein concentration was measured using the BCA method. Protein was separated by 10% SDS-PAGE electrophoresis and transferred onto a PVDF membrane. The membrane was blocked with 5% milk for one hour and incubated at 4°C overnight with rabbit anti-rat Bcl-2 or anti-Bax (Boster Inc., Wuhan, China) at a 1:500 dilution. The membrane was washed three times with Tris-buffer saline Tween-20 (TBST) and incubated with horseradish peroxidase-conjugated anti-rabbit IgG antibody at a concentration of 1:2,000 for one hour. After washing three times with TBST, immunoreactive bands were visualized using the enhanced chemiluminescence (ECL) system (Thermo Fisher Scientific, USA) and quantified by densitometric analysis using

Image Lab Software. Results were calculated as a relative ratio of a specific band to  $\beta$ -actin.

### *Immunohistochemical analysis of Bax and Bcl-2*

Briefly, deparaffinized thin sections were treated by microwave irradiation (high fire for three minutes and low heat for 15 minutes) with 10 mmol/L of citrate buffer (pH 6.0). Intrinsic peroxidase activity was inhibited by 0.3% hydrogen peroxide in methanol for 30 minutes, and non-specific binding was blocked with normal goat serum. Tissues were incubated with rabbit anti-rat Bax and Bcl-2 antibodies (Boster Inc., Wuhan, China) at 4°C overnight. The working titer of both Bcl-2 and Bax was 1:200. Samples were washed with PBS and incubated at room temperature with biotinylated secondary antibody for 40 minutes. After being soaked in 0.5% Triton X-100/PBS and washed in PBS, sections were stained with fresh DAB and counterstained with hematoxylin.

### *TUNEL analysis*

Cell apoptosis was detected according to the instructions of the TUNEL assay kit (Boster Inc., Wuhan, China). The apoptotic index (%) was calculated as the ratio of TUNEL-positive cells to total lung cells. The average overall index from five views (magnification,  $\times 400$ ) of each specimen was calculated.

### *Statistical analysis*

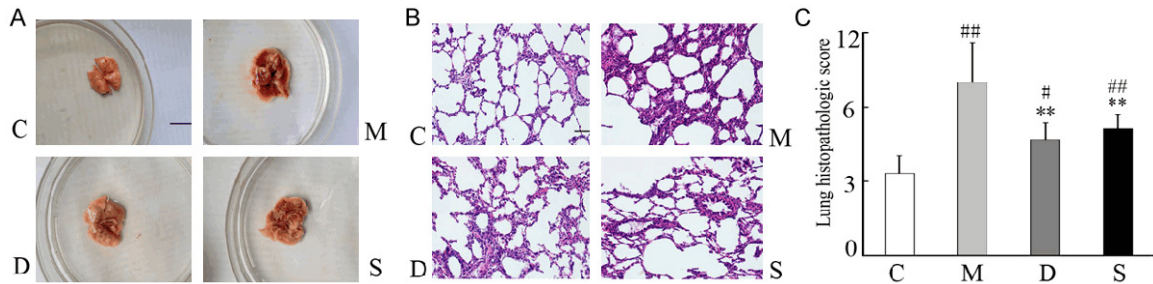
Data were expressed as mean  $\pm$  standard deviation (SD). All parameters were evaluated by one-way analysis of variance (ANOVA) test. A *P*-value  $< 0.05$  was considered statistically significant.

## Results

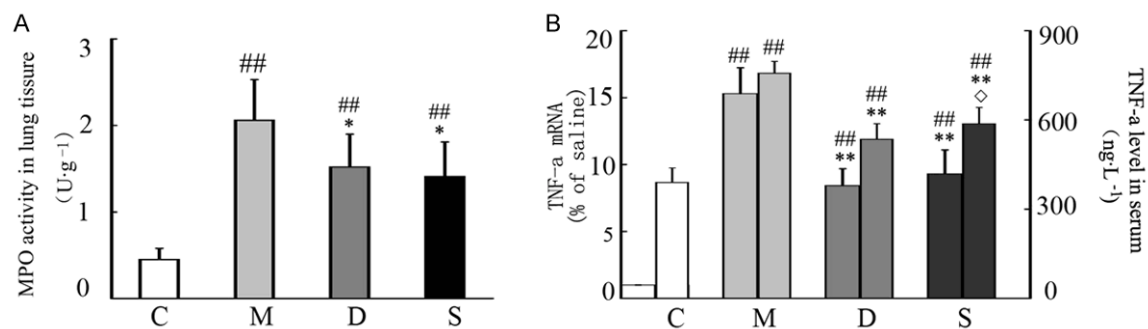
### *Sildenafil attenuates meconium-induced pathological damage*

Lung tissues in the M, D and S groups were grossly edematous and hemorrhagic at different extents, compared with the C group; which showed normal appearance. Histological analysis revealed diffuse alveolar damage including alveolar wall disruption, alveolar hemorrhage, edema and severe inflammatory cell infiltration in the M group, compared to the C group. By contrast, less severe alveolitis was observed in the D and S groups. Lung injury score signifi-

## Sildenafil in acute lung injury



**Figure 1.** Histopathological changes in lung tissues among groups. A. Gross lung changes, Scale bar=1 cm; B. Pathological changes, H&E stain, 200× magnification, Scale bar=50 μm; C. Lung histopathological scores, data were presented as mean ± SD, n=6. C: control; D: dexamethasone; M: Meconium; S: Sildenafil; <sup>#</sup>*P*<0.05 vs. the C group, <sup>##</sup>*P*<0.01 vs. the C group; <sup>\*</sup>*P*<0.05 vs. the M group, <sup>\*\*</sup>*P*<0.01 vs. the M group.



**Figure 2.** A. MPO activity in lung tissues among groups; B. Serum TNF-α mRNA and protein levels among groups. Data were presented as mean ± SD, n=6. C: control; D: dexamethasone; M: Meconium; S: Sildenafil; <sup>#</sup>*P*<0.05 vs. the C group, <sup>##</sup>*P*<0.01 vs. the C group; <sup>\*</sup>*P*<0.05 vs. the M group, <sup>\*\*</sup>*P*<0.01 vs. the M group; <sup>◇</sup>*P*<0.05 vs. D group.

cantly increased in the M group compared with the C group (*P*<0.05). However, these scores statistically decreased after sildenafil and dexamethasone treatment (both, *P*<0.01). There was no significant difference between the S and D groups (**Figure 1**).

### *Sildenafil suppresses meconium-induced inflammatory cytokine levels in lung tissues*

MPO activity increased to a great extent in the M group, compared with the C group. Lungs from rats treated with sildenafil exhibited markedly decreased MPO activity compared with the M group. Sildenafil could also significantly downregulate the mRNA and protein expression of TNF-α in a similar way (**Figure 2**).

### *Sildenafil reduces meconium-induced oxidative and nitrative injuries*

MDA levels significantly increased in the M group compared with the C group. However, reduced MDA activities were reversed after

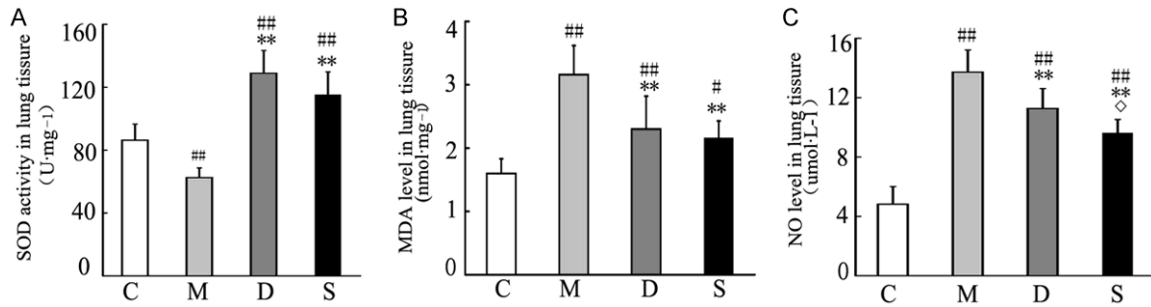
administration of sildenafil and dexamethasone. There were no significant differences were observed between the M and D groups. Lung tissue SOD activity was found to be significantly decreased in rats subjected to meconium. This decrease was eliminated by treatment of sildenafil and dexamethasone. The M group exhibited an elevated NO concentration compared with the C group. Elevated NO levels were significantly lower in the S and D groups, compared with the M group (**Figure 3**).

### *Sildenafil inhibits meconium-induced apoptosis*

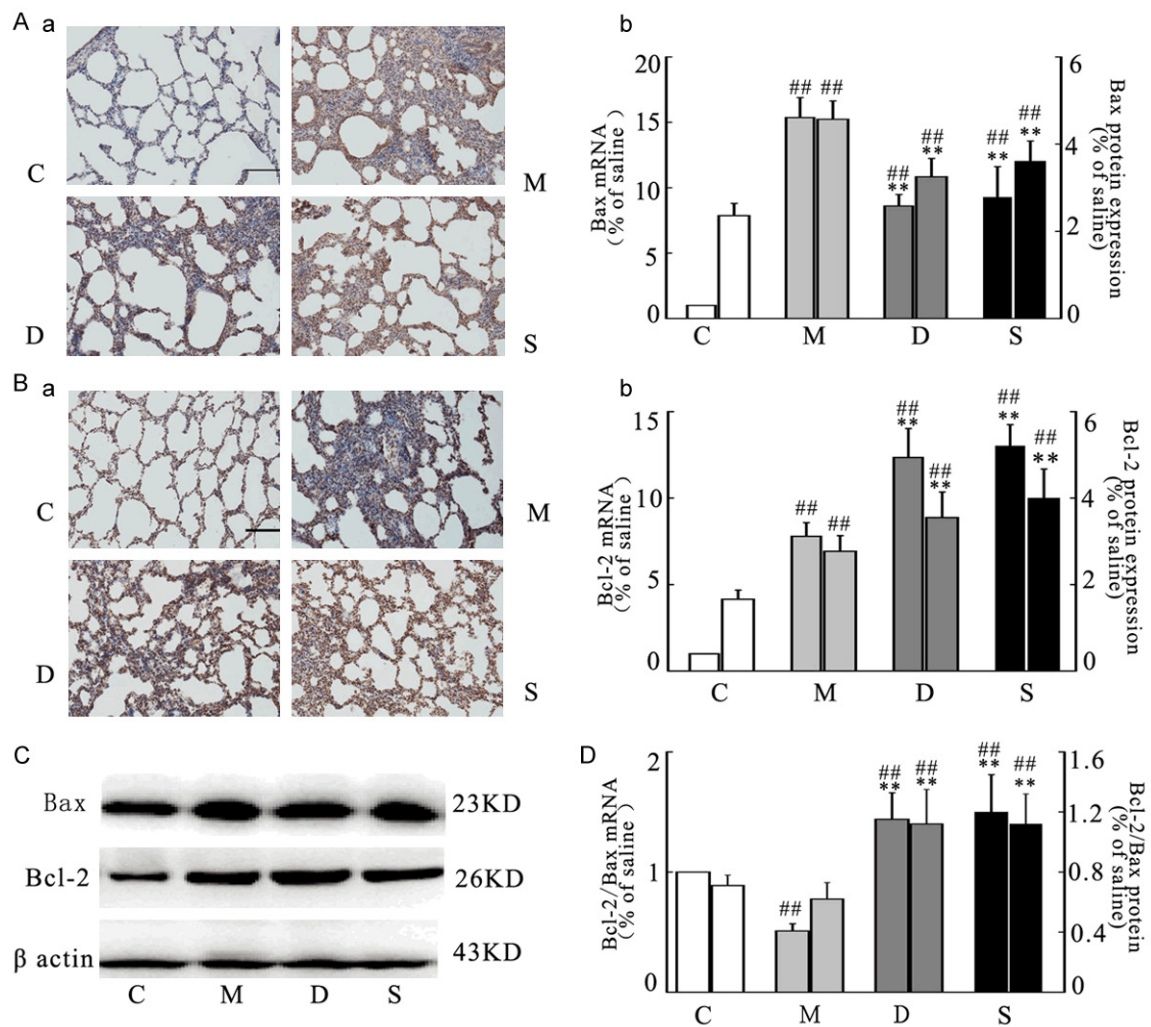
Bax and Bcl-2 proteins were normally expressed by polymorphonuclear cells, pneumocytes, bronchial epithelial cells and endothelial cells. Meconium resulted in the increased expression of pro-apoptotic Bax (protein and mRNA) and decreased level of anti-apoptotic Bcl-2 (protein and mRNA). However, elevated Bax protein and mRNA expression was significantly inhibited following sildenafil and dexamethasone treatment



## Sildenafil in acute lung injury

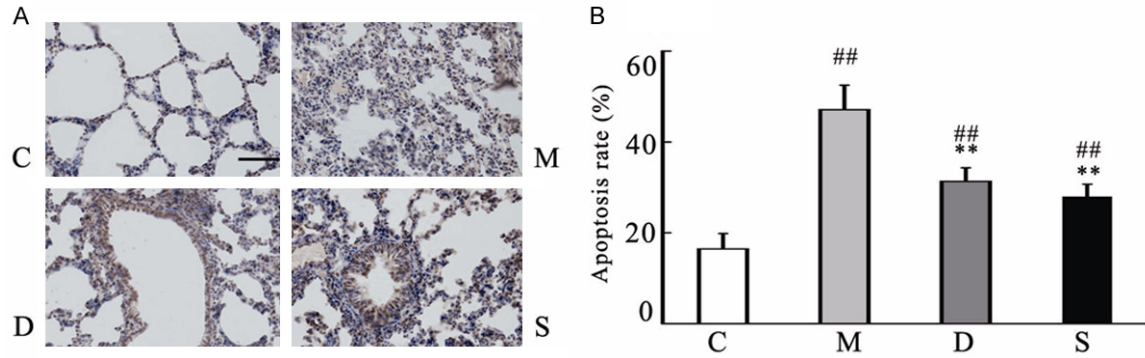


**Figure 3.** A. SOD activity in lung tissues; B. MDA levels in lung tissues; C. NO levels in lung tissues. Data were presented as mean  $\pm$  SD,  $n=6$ . C: control; D: dexamethasone; M: Meconium; S: Sildenafil; <sup>#</sup> $P<0.05$  vs. the C group, <sup>##</sup> $P<0.01$  vs. the C group; <sup>\*</sup> $P<0.05$  vs. the M group, <sup>\*\*</sup> $P<0.01$  vs. the M group; <sup>◇</sup> $P<0.05$  vs. the D group.

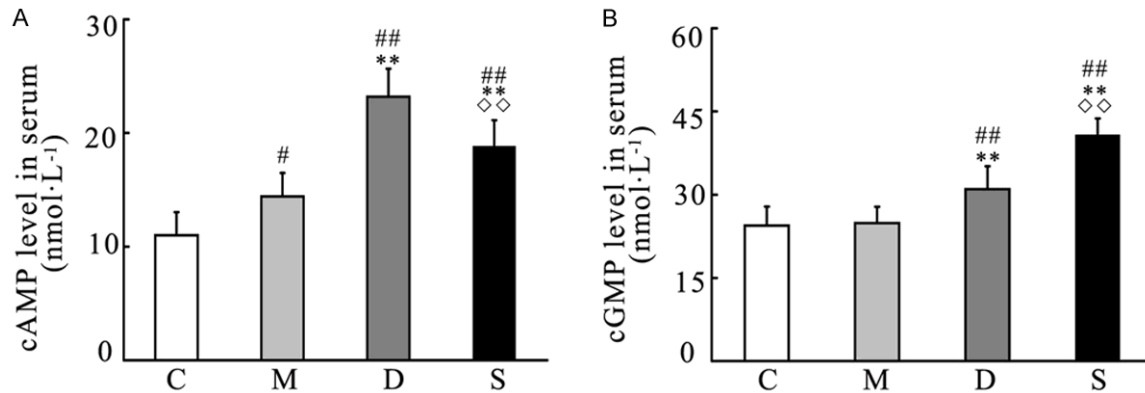


**Figure 4.** Aa. Immunohistochemical analysis of Bax in lung tissues, 200 $\times$  magnification, Scale bar=50  $\mu$ m; Ab. Relative mRNA expressions of Bax and semiquantitative analysis of Bax protein levels in lung tissues; Ba. Immunohistochemical analysis of Bcl-2 in lung tissues, 200 $\times$  magnification, Scale bar=50  $\mu$ m; Bb. Relative mRNA expressions of Bcl-2 and semiquantitative analysis of Bcl-2 protein levels in lung tissues; C. Western blot analysis of Bax and Bcl-2; D. Bcl-2/Bax mRNA and protein expression ratios. Data were presented as mean  $\pm$  SD,  $n=6$ . C: control; D: dexamethasone; M: Meconium; S: Sildenafil; <sup>#</sup> $P<0.05$  vs. the C group, <sup>##</sup> $P<0.01$  vs. the C group; <sup>\*</sup> $P<0.05$  vs. the M group, <sup>\*\*</sup> $P<0.01$  vs. the M group.

## Sildenafil in acute lung injury



**Figure 5.** A. TUNNEL assay in lung tissues, 400 $\times$  magnification, Scale bar=25  $\mu$ m; B. Apoptotic index. Data were presented as mean  $\pm$  SD,  $n=6$ . C: control; D: dexamethasone; M: Meconium; S: Sildenafil; \* $P<0.05$  vs. the C group, <sup>##</sup> $P<0.01$  vs. the C group; \* $P<0.05$  vs. the M group, \*\* $P<0.01$  vs. the M group.



**Figure 6.** A. Serum cAMP levels; B. Serum cGMP levels. Data were presented as mean  $\pm$  SD,  $n=6$ . C: control; D: dexamethasone; M: Meconium; S: Sildenafil; \* $P<0.05$  vs. the C group, <sup>##</sup> $P<0.01$  vs. the C group; \* $P<0.05$  vs. the M group, <sup>##</sup> $P<0.01$  vs. the M group;  $\diamond\diamond P<0.01$  vs. the D group.

(both  $P<0.05$ , compared with the M group). Concurrently, enhanced Bcl-2 to Bax protein and mRNA ratios in the S and D groups were observed in lung tissues (Figure 4).

In TUNEL assay, apoptosis was found in alveolar and airway epithelial layers, endothelial cells and neutrophils. Apoptotic cells were featured by prominent cell shrinkage and a brown condensed nucleus. The M group revealed the greatest apoptotic index among all groups, while the S and D groups exhibited a significant decrease in apoptotic index, compared with the M group (Figure 5).

### Effect of sildenafil on cAMP and cGMP

Both sildenafil and dexamethasone increased cAMP and cGMP levels in lung tissues, compared with the M and C groups. Noticeably, sildenafil triggered cGMP to the greatest extent,

while dexamethasone induced cAMP the most (Figure 6).

### Discussion

Inflammation, oxidation and apoptosis are important in the process that participates in meconium-induced lung injury. In the present study, sildenafil significantly improved lung histopathology in neonatal rats exposed to meconium, a suitable *in vivo* model for MAS, by inhibiting the infiltration of inflammatory cells, decreasing the release of inflammatory cytokines, reducing the formation of oxidation markers, and suppressing apoptotic markers evaluated in lung tissues. The protective effect of sildenafil may partly be explained by elevated cGMP and cAMP levels in lung tissues.

Meconium acts as a potent chemo-attractant. The accumulation of PMNs, particularly neutro-

phils, in lungs may be observed within several hours after meconium instillation [16, 17]. In this study, we observed an increase of infiltrated cells in alveolar spaces and in the lung interstitium after meconium instillation, compared to saline controls. In addition, MPO activity, which reflects the infiltration, was elevated in meconium-exposed lungs. Proinflammatory cytokines (TNF- $\alpha$ ) were simultaneously elevated. These findings were consistent with previous animal studies that revealed that meconium stimulated the production of proinflammatory cytokines such as IL-1 $\beta$ , IL-6, IL-8 and TNF- $\alpha$  [18]. These proinflammatory cytokines and the influx of PMNs may contribute to local pulmonary inflammation, which lead to parenchymal injury and remodeling of the lung tissue. The anti-inflammatory actions of sildenafil in our study confirms, in part, the findings of Toward TJ *et al.*, who proved that sildenafil pretreatment significantly reduced LPS-induced leukocyte influx and NO generation [19].

Enhanced inflammation is associated with the production of a wide range of ROS, which subsequently activate oxidative stress [20]. Meconium-induced alveolar collapse is partly due to the imbalance between the formation and scavenging of ROS. ROS overproduction injures cell membranes, resulting in lipid peroxide; which was reflected by MDA levels. SOD protects against oxidative injury by scavenging excess O<sub>2</sub>. It also indirectly reflects lipid peroxidation levels. In this study, meconium instillation significantly increased MDA level, but reduced SOD activity in the lung homogenate and serum; which was consistent with a previous study [21]. This phenomenon implies that meconium simultaneously stimulates oxidative stress injury and anti-oxidative defense. In accordance with previous reports, sildenafil potently inhibited lipid peroxidation [12].

Accumulating evidence has demonstrated that reactive nitrogen species (RNS) are also involved in acute lung injury [22, 23]. NO levels followed a similar pattern with MDA levels in the current study. The finding that sildenafil significantly suppressed NO levels in meconium-exposed rats confirms that sildenafil effectively inhibited nitrative injury. Notably, sildenafil's effect via reducing inflammation and oxidative/nitrative stress was not only confirmed in lung injury, but in heart, brain and testicles suffering ischemia-reperfusion injury [24-28].

Meconium induced direct cell death and caspase-dependant apoptosis in lung cells. The balance between Bcl-2 and Bax determines cell survival or death [29, 30]. We found that the ratio of Bcl-2/Bax expression decreased after meconium instillation. The treatment of sildenafil increased Bcl-2 expression and Bcl-2/Bax ratio, but decreased Bax expression. Similar results have been demonstrated by other studies on lung ischemia-reperfusion injury and ischemic cardiomyopathy, in which sildenafil elicited anti-apoptotic effects via an increase in Bcl-2/Bax ratio [14, 31].

Cyclic AMP and GMP are important second messengers in cells, and cAMP- and cGMP-elevating agents may provide a wide range of anti-inflammatory effects. Elevated intracellular cAMP inhibits the production of cell adhesion molecules and proinflammatory cytokines (such as TNF- $\alpha$  and IL-1), reduces chemotaxis, and decreases the generation of ROS [3, 32]. The beneficial effects of sildenafil on meconium-induced lung injury may, at least in part, be due to higher intracellular cAMP and cGMP levels, as demonstrated in the current study.

Sildenafil has been approved for the treatment of persistent pulmonary hypertension of the newborn (PPHN) secondary to MAS. Manifestations of PPHN appeared in two hours after meconium aspiration [6]. Critical condition can be deteriorated due to the delayed identification of PPHN. Our findings support an early application of sildenafil in the treatment of meconium-related acute lung injury. To our knowledge, this study is the first that validated the anti-inflammatory and anti-apoptotic effects of sildenafil in meconium-induced lung injury.

### Conclusion

Sildenafil administration reduced inflammation, suppressed oxidative/nitrative stress, attenuated apoptosis, and increased cAMP and cGMP levels in meconium-induced lung injury. The aforementioned beneficial effects emphasize the potential of sildenafil for the treatment of acute lung injury caused by meconium aspiration in infants. However, further animal and clinical studies are warranted.

### Disclosure of conflict of interest

None.

## Sildenafil in acute lung injury

**Address correspondence to:** Yu-Lin Wang, Department of Pediatrics, Shandong Provincial Hospital Affiliated to Shandong University, 324 Jingwu Road, Jinan 250021, China. Tel: +86 531 68776365; Fax: +86 531 68777003; E-mail: yulinwang777@sina.com

### References

- [1] Dargaville PA and Copnell B. The epidemiology of meconium aspiration syndrome: incidence, risk factors, therapies, and outcome. *Pediatrics* 2006; 117: 1712-1721.
- [2] Mokra D, Mokry J and Tonhajzerova I. Anti-inflammatory treatment of meconium aspiration syndrome: benefits and risks. *Respir Physiol Neurobiol* 2013; 187: 52-57.
- [3] Koike T, Nadeen Qutab M, Tsuchida M, Takekubo M, Saito M and Hayashi J. Pretreatment with olprinone hydrochloride, a phosphodiesterase III inhibitor, attenuates lipopolysaccharide-induced lung injury via an anti-inflammatory effect. *Pulm Pharmacol Ther* 2008; 21: 166-171.
- [4] Currie GP, Butler CA, Anderson WJ and Skinner C. Phosphodiesterase 4 inhibitors in chronic obstructive pulmonary disease: a new approach to oral treatment. *Br J Clin Pharmacol* 2008; 65: 803-810.
- [5] de Visser YP, Walther FJ, Laghmani EH, van Wijngaarden S, Nieuwland K and Wagenaar GT. Phosphodiesterase-4 inhibition attenuates pulmonary inflammation in neonatal lung injury. *Eur Respir J* 2008; 31: 633-644.
- [6] Shekerdemian LS, Ravn HB and Penny DJ. Intravenous sildenafil lowers pulmonary vascular resistance in a model of neonatal pulmonary hypertension. *Am J Respir Crit Care Med* 2002; 165: 1098-1102.
- [7] Malik M and Nagpal R. Emerging role of sildenafil in neonatology. *Indian Pediatr* 2011; 48: 11-13.
- [8] Nair J and Lakshminrusimha S. Update on PPHN: mechanisms and treatment. *Semin Perinatol* 2014; 38: 78-91.
- [9] Fan Chung K. Phosphodiesterase inhibitors in airways disease. *Eur J Pharmacol* 2006; 533: 110-117.
- [10] Das A, Xi L and Kukreja RC. Phosphodiesterase-5 inhibitor sildenafil preconditions adult cardiac myocytes against necrosis and apoptosis. Essential role of nitric oxide signaling. *J Biol Chem* 2005; 280: 12944-12955.
- [11] Zahran MH, Hussein AM, Barakat N, Awadalla A, Khater S, Harraz A and Shokeir AA. Sildenafil activates antioxidant and antiapoptotic genes and inhibits proinflammatory cytokine genes in a rat model of renal ischemia/reperfusion injury. *Int Urol Nephrol* 2015; 47: 1907-1915.
- [12] Gokakin AK, Deveci K, Kurt A, Karakus BC, Duger C, Tuzcu M and Topcu O. The protective effects of sildenafil in acute lung injury in a rat model of severe scald burn: A biochemical and histopathological study. *Burns* 2013; 39: 1193-1199.
- [13] Cornet AD, Hofstra JJ, Swart EL, Girbes AR and Juffermans NP. Sildenafil attenuates pulmonary arterial pressure but does not improve oxygenation during ARDS. *Intensive Care Med* 2010; 36: 758-764.
- [14] Shih PK, Cheng CM, Li HP, Huang MF, Chiu CW, Chen JX, Chen NW and Chou SH. Pretreatment with sildenafil alleviates early lung ischemia-reperfusion injury in a rat model. *J Surg Res* 2013; 185: e77-83.
- [15] Charriaut-Marlangue C, Nguyen T, Bonnin P, Duy AP, Leger PL, Csaba Z, Pansiot J, Bourgeois T, Renolleau S and Baud O. Sildenafil mediates blood-flow redistribution and neuroprotection after neonatal hypoxia-ischemia. *Stroke* 2014; 45: 850-856.
- [16] Mokry J, Mokra D, Antosova M, Bulikova J, Calkovska A and Nosalova G. Dexamethasone alleviates meconium-induced airway hyperresponsiveness and lung inflammation in rabbits. *Pediatr Pulmonol* 2006; 41: 55-60.
- [17] Mokra D, Mokry J, Tatarkova Z, Redfors B, Petraskova M and Calkovska A. Aminophylline treatment in meconium-induced acute lung injury in a rabbit model. *J Physiol Pharmacol* 2007; 58 Suppl 5: 399-407.
- [18] Zagariya A, Bhat R, Uhal B, Navale S, Freidine M and Vidyasagar D. Cell death and lung cell histology in meconium aspirated newborn rabbit lung. *Eur J Pediatr* 2000; 159: 819-826.
- [19] Toward TJ, Smith N and Broadley KJ. Effect of phosphodiesterase-5 inhibitor, sildenafil (Viagra), in animal models of airways disease. *Am J Respir Crit Care Med* 2004; 169: 227-234.
- [20] Mokra D, Drgova A, Pullmann R Sr and Calkovska A. Selective phosphodiesterase 3 inhibitor olprinone attenuates meconium-induced oxidative lung injury. *Pulm Pharmacol Ther* 2012; 25: 216-222.
- [21] Lu MP, Du LZ, Gu WZ and Chen XX. Nitric oxide inhalation inhibits inducible nitric oxide synthase but not nitrotyrosine formation and cell apoptosis in rat lungs with meconium-induced injury. *Acta Pharmacol Sin* 2005; 26: 1123-1129.
- [22] Gross CM, Rafikov R, Kumar S, Aggarwal S, Ham PB 3rd, Meadows ML, Cherian-Shaw M, Kangath A, Sridhar S, Lucas R and Black SM. Endothelial nitric oxide synthase deficient mice are protected from lipopolysaccharide induced acute lung injury. *PLoS One* 2015; 10: e0119918.



## Sildenafil in acute lung injury

- [23] Nys M, Deby-Dupont G, Habraken Y, Legrand-Poels S, Kohnen S, Ledoux D, Canivet JL, Damas P and Lamy M. Bronchoalveolar lavage fluids of ventilated patients with acute lung injury activate NF-kappaB in alveolar epithelial cell line: role of reactive oxygen/nitrogen species and cytokines. *Nitric Oxide* 2003; 9: 33-43.
- [24] Beheshtian A, Salmasi AH, Payabvash S, Kiumehr S, Ghazinezami B, Rahimpour S, Tavangar SM and Dehpour AR. Protective effects of sildenafil administration on testicular torsion/detorsion damage in rats. *World J Urol* 2008; 26: 197-202.
- [25] Bremer YA, Salloum F, Ockaili R, Chou E, Moskowitz WB and Kukreja RC. Sildenafil citrate (viagra) induces cardioprotective effects after ischemia/reperfusion injury in infant rabbits. *Pediatr Res* 2005; 57: 22-27.
- [26] Ozdegirmenci O, Kucukozkan T, Akdag E, Topal T, Haberal A, Kayir H, Oter S, Akyol M and Uzbay T. Effects of sildenafil and tadalafil on ischemia/reperfusion injury in fetal rat brain. *J Matern Fetal Neonatal Med* 2011; 24: 317-323.
- [27] Dias-Junior CA, Souza-Costa DC, Zerbini T, da Rocha JB, Gerlach RF and Tanus-Santos JE. The effect of sildenafil on pulmonary embolism-induced oxidative stress and pulmonary hypertension. *Anesth Analg* 2005; 101: 115-120, table of contents.
- [28] Korom S, Hillinger S, Cardell M, Zhai W, Tan Q, Dutly A, Leskosek B and Weder W. Sildenafil extends survival and graft function in a large animal lung transplantation model. *Eur J Cardiothorac Surg* 2006; 29: 288-293.
- [29] Jeng MJ, Soong WJ, Lee YS, Tsao PC, Yang CF, Chiu SY and Tang RB. Meconium exposure dependent cell death and apoptosis in human alveolar epithelial cells. *Pediatr Pulmonol* 2010; 45: 816-823.
- [30] Zagariya A, Sierzputovska M, Navale S and Vidyasagar D. Role of meconium and hypoxia in meconium aspiration-induced lung injury in neonatal rabbits. *Mediators Inflamm* 2010; 2010: 204831.
- [31] Salloum FN, Abbate A, Das A, Houser JE, Mudrick CA, Qureshi IZ, Hoke NN, Roy SK, Brown WR, Prabhakar S and Kukreja RC. Sildenafil (Viagra) attenuates ischemic cardiomyopathy and improves left ventricular function in mice. *Am J Physiol Heart Circ Physiol* 2008; 294: H1398-1406.
- [32] Essayan DM. Cyclic nucleotide phosphodiesterases. *J Allergy Clin Immunol* 2001; 108: 671-680.