

Case Report

Management of vulvar Paget's disease: a case report and review of the literature

Huiping Jiang, Congshun Ma, Suiqun Guo

Department of Obstetrics and Gynecology, The Third Affiliated Hospital of Southern Medical University, Guangzhou 510630, Guangdong, China

Received September 7, 2015; Accepted March 22, 2016; Epub June 15, 2016; Published June 30, 2016

Abstract: Extra-mammary Paget disease is one of the rare neoplastic conditions of the skin. The most common site of involvement is the vulva and presents itself with erythematous plaques. Although surgery is the most common treatment, removing the disease completely is challenging. We reviewed the reports of other patients with vulvar Paget disease and reported one new case. A 64-year-old woman presented to department of gynaecology with complaints of vulvar pruritus, painful vulvar lesion for 10 years. Physical examination revealed an erythematous plaque with a size of 15 cm*18 cm*20 cm extending over the pubic area to crissum. Pathological result was reported as Paget disease. The radical vulvectomy was performed with a safety margin of 2 cm. The patient was followed up for 2 years. No evidences of recurrence were observed throughout this period.

Keywords: Vulva, Paget disease, surgery, vulvar Paget disease

Introduction

Paget's disease was first described in 1874 by Sir James Paget as a rare intraepithelial neoplasm of the areola skin [1]. In 1901, Dubreuil described the characteristic 'cake-icing appearance' of vulvar Paget's disease [2]. Vulvar Paget's disease is an extremely rare clinical entity, accounting for only 1% of vulvar malignancies. Our understanding of this disease is limited [3]. Paget's disease of the vulva (PDV) commonly develops in postmenopausal Caucasian females. Symptoms include pruritus, tenderness or identification of a vulvar lesion [4]. The patients always suffer from these symptoms for several years before seeking medical advice. The typical clinical manifestations presents as a well-demarcated, thickened, pruritic, erythematous, or white scaly plaque with irregular borders.

Wilkinson and Brown has proposed a classification system for extramammary vulvar Paget's disease based on the origin of neoplastic paget cells: -primary and secondary disease. Primary cutaneous Paget's disease, an intraepithelial adenocarcinoma, arises within the epidermis or underlying skin appendages. Secondary or noncutaneous Paget's disease originates from

an underlying noncutaneous adenocarcinoma, most commonly anorectal adenocarcinoma, urothelial carcinoma of the bladder or urethra, carcinoma of the cervix, ovary or endometrium [5, 6]. A biopsy can be used to establish the diagnostic, and immunohistochemical studies may be of great use in distinguishing primary and secondary lesions [7].

Standard treatment of vulvar Paget's disease is surgical excision [8]. Surgical evaluation of these lesions is important, because 20-30% of cases have an underlying malignancy [9]. Histological disease may exceed far beyond the visible lesion and lead to recurrence. Repeated operations may destroy the anatomy. So it is challenging to excise the disease adequately.

We reported a postmenopausal woman with noninvasive PDV. She was treated by only surgery and followed up for two years. No evidences of recurrence were observed throughout this period. We will show and discuss the treatment of this disease.

Case report

Sixty-four years old female was in natural menopause for 14 years. She visited the gynecologi-

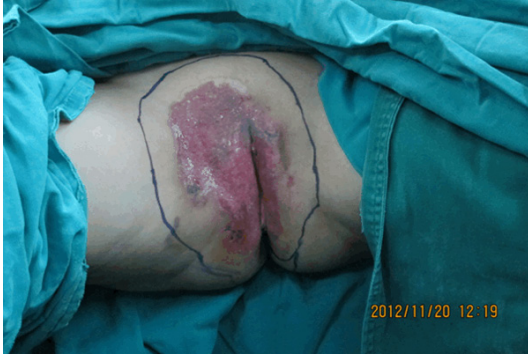

Figure 1. Macroscopic appearance of Paget's disease of the vulva. Pink plaque extended through the pubic area and left great labia.

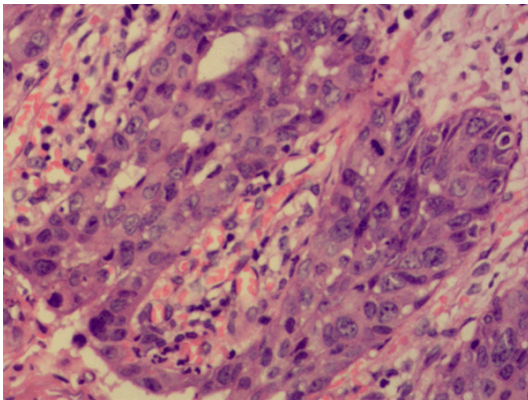


Figure 2. Primary Paget's disease of vulvar. Paget's cells with large nuclei, prominent nucleoli and large amount pale cytoplasm, extended in the basal and parabasal areas of the epithelium.

cal oncology clinic in November 2012 with an itchy lesion in her vulva for 10 years. The symptom began about 10 years prior to admission with the appearance of a small pimple on the right labia majora. The marked pruritus was associated with the lesion. The patient received cortisone and ACTH, both locally and parenterally, and got temporary improvement. The vulvar pruritus and painful vulvar lesion was worse during three months.

Pelvic examination showed that the mons pubis and labium were markedly reddened and edematous. The involved area extended posteriorly over the perineum and almost to the anal margin and laterally to the right thigh for a distance of about 4-5 cm from the labium. It also extended up to the clitoris but did not approach the external urethral meatus (**Figure 1**).

Biopsy from the lesion was performed. The result of the biopsy was Paget's disease (**Figure 2**). Upon the result of Paget disease from the pathology, other systems were examined. Breast examination, mammography results, skin examination and lymph node palpation results were normal. Colonoscopy, cystoscopy and pelvic and abdominal ultrasonography were performed and no abnormality could be found. Physical examination revealed an elderly female in good general physical condition. Heart and lungs were clear. There was no adenopathy.

The proposed treatment was surgery with radical vulvectomy and reconstruction via skin flap transplantation. The gross lesion was outlined with a 2 cm border, and strips of tissue beyond this border were excised. This was done in a systematic fashion with proper labeling by quadrants. These strips of tissue were sent directly to the pathology laboratory and processed by frozen section analysis to determine whether invasive disease is present. The routine fashion for vulvar malignancies and no special stains, molecular or receptor analyses were routinely performed.

The patient was followed up for 2 years. No evidences of recurrence were observed throughout this period. The pain disappeared and the quality of life was improved greatly.

Discussion

Paget's disease was originally described as a breast lesion associated with underlying invasive ductal adenocarcinoma. It was divided into mammary or extramammary disease. According to the location on the body. The most common site of involvement is the vulva, which accounts for up to 60% of primary extramammary. Paget's disease of the vulva cases account for less than 2% of vulvar malignancies [10]. Erythematous and/or eczematoid area are always accompanied by pruritus in 70% of patients [11]. The lesions in PDV are non-specific. There is a significant delay between the onset of symptoms and diagnosis [12]. The median interval from the onset of symptoms to a histological diagnosis was approximately 20 months [13]. This delay did not correlate with the size or extent of disease, which suggests that this disease is slowly progressive.

Concerning the pathogenesis, it is still a subject of great debate. Paget's cells are malignant keratinocytes and are transformed in situ. Ellis et al. demonstrated that it was possible that in PDV, cells can migrate and progress to invasive disease by utilizing the existing vasculature, but not in formation of new blood vessels [14]. Paget's cells are larger than keratinocytes, have clear chromatin, and have a nucleolus. The cell cytoplasm is gray-blue, and it appears vacuolated with hematoxylin and eosin staining. On the basis of pathologic diagnosis, the patients were then divided into four groups: Intraepithelial Paget's disease, invasive Paget's disease, intraepithelial Paget's disease with underlying adenocarcinoma and intraepithelial Paget's disease with a coexisting cancer [15]. The intraepithelial type accounts for the majority of primary cases and has a better clinical course and outcomes.

Underlying adenocarcinoma is found in 10% to 20% of cases [16]. Helwig and Graham reported a higher rate of underlying adenocarcinoma in patients with perianal involvement [17]. Stephen Tebes et al. reported 26% of the women had underlying adenocarcinoma, and twenty-two percent of cases had additional malignancies at other sites, which is consistent with other reports [18]. Commonly associated malignancies mentioned in previous studies are breast, basal cell, rectal, genitourinary, and cervical carcinoma. Women with Paget's disease should undergo a search for other malignancies, including at least colonoscopy, mammography, and Papanicolaou smear. Any suspicious symptoms of other malignancies should be evaluated additionally.

Paget's disease of the vulva is a rare locally recurrent chronic disease. The recurrence rate is high, up to 21% to 61% [19]. It may correlate with a patchy tape of distribution with multiple islands of abnormal epithelium, which are not connected and have microscopic extension beyond the gross lesion. The risk factors associated with local recurrence remain controversial, such as a positive surgical margin, dermal invasion, and adnexal involvement.

Standard treatment of vulvar Paget's disease is surgical excision, depending on the lesion size, lesion location, the presence of invasion, and underlying adenocarcinomas or adjacent skin abnormalities. Surgical procedures include

wide local excision, radical hemivulvectomy, and simple or radical vulvectomy. The treatment of noninvasive extramammary Paget's disease is wide surgical excision with a gross margin of 2-3 cm and resection to the fascia, because the disease usually extends well beyond the gross lesion. Radical vulvectomy may be considered for invasive lesions and adnexal adenocarcinomas. To reduce the width of the margin, mapping biopsies were performed at several selected points where the margin remained clinically ill-defined after infection control. The lesion can then be excised for frozen section analysis to determine whether invasive disease is present and whether radical resection will be necessary. Limiting resection in favor of the preservation of the clitoris, urethra, and anus is recommended.

Recurrences happened in 20% to 60% cases after surgical treatment [20], and microscopic positive margins have been frequently found in 40%-70% cases [21]. So margin status gained interest with intraoperative frozen section analysis. However, the controversy of influence of surgical margins status on the recurrence rate also exists. Some studies found that positive margins correlate with increased recurrence rate, and negative margins tend to have longer disease-free periods and lower recurrence rates. However, other studies have found no correlation between margin status and local recurrence [22]. Gunn et al. showed that microscopic disease extended beyond the visible lesion with multifocal islands of microscopic disease [23]. Adamsons et al. also reported that Paget's cells existed along the basement membrane beyond the apparent border of the lesion [24]. So the high frequency of recurrence and the high rate of positive surgical margins are thought to be a result of the multicentric nature of vulvar Paget's disease. Because it is unfeasible to freeze all margins and intraoperatively identify sporadic cells. And there was no significant difference in recurrence rate between positive and negative surgical margins. We would recommend selective use of intraoperative frozen section analysis of the vulvectomy specimen, not for margin status, but to determine whether invasive disease is present.

Mohs micrographic surgery (MMS) is performed under microscopic control to remove tumor lesions and conserve tissue loss and function.

Report of vulvar Paget's disease

Mohs micrographic technique is used by the dermatologists as a standard surgical technique for the cutaneous lesions of extra-mammary Paget disease. A lower recurrence rate in those patients with Mohs surgery than that in the patients who were treated with conventional resection has been documented [25]. Hendi et al. reported a recurrence rate of 16% for the primary disease and 50% in recurrent cases [26]. However, additional clinical trials are warranted to determine whether MMS could be used as a standard surgical technique for EMPDV.

Alternative nonsurgical or combined treatments have been proposed, including radiotherapy, topical chemotherapy, laser, photodynamic treatment with aminolevulinic acid, topical fluorouracil (5-Fu), and imiquimod 5% cream [27]. Systemic chemotherapy may be considered in advanced cases of disease and in cases of metastatic disease although the standard regimens have not been validated. Radiotherapy is an alternative treatment for patients with a medical contradiction for surgery and for patients with recurrent disease. In addition, it could be considered as an adjuvant therapy for patients with a positive margin after surgical. Over the years, many therapeutic modalities have been attempted on patients with PDV in an effort to reduce the significant morbidity associated with the after-radical surgical treatments performed.

The high frequency of recurrence remains the most challenging feature in the management of vulvar intraepithelial Paget's disease. Long-term monitoring of patients is recommended, and repeat surgical excision is often necessary. The optimum treatment regimen needs to be defined in prospective studies and long-term follow-up data are needed.

Acknowledgements

This study was supported by the Medical Research Foundation of Guangdong Province (WSTJJ20131218432929197808190026).

Disclosure of conflict of interest

None.

Address correspondence to: Suqun Guo, Department of Obstetrics and Gynecology, The Third Affi-

liated Hospital of Southern Medical University, Guangzhou 510630, Guangdong, China. Tel: +86 20-62784511; Fax: +86 20-62784511; E-mail: suiqunguo@sina.com

References

- [1] Abell DA. Simple vulvectomy-A 10-years. *Aust N Z J Obstet Gynaecol* 1973; 12: 8-14.
- [2] Dubreuilh W. Paget's disease of the vulva. *Br J Dermatol* 1901; 13: 403-413.
- [3] Jones SC, Crandon A and Sanday K. Paget's disease of the vulva: diagnosis and follow up key to management; a retrospective study of 50 cases from Queensland. *Gynecol Oncol* 2011; 122: 42-44.
- [4] Shaco-Levy R, Bean SM, Vollmer RT, Papalas JA, Bentley RC, Selim MA and Robboy SJ. Paget disease of the vulva: a histologic study of 56 cases correlating pathologic features and disease course. *Int J Gynecol Pathol* 2010; 29: 69-78.
- [5] Wilkinson EJ and Brown HM. Vulvar Paget disease of urothelial origin: a report of three cases and a proposed classification of vulvar Paget disease. *Hum Pathol* 2002; 33: 549-554.
- [6] Lopes Filho LL, Lopes IM, Lopes LR, Enokihara MM, Michalany AO and Matsunaga N. Mammary and extramammary Paget's disease. *An Bras Dermatol* 2015; 90: 225-231.
- [7] Nowak MA, Guerriere-Kovach P, Pathan A, Campbell TE and Deppisch LM. Perianal Paget's disease: distinguishing primary and secondary lesions using immunohistochemical studies including gross cystic disease fluid protein-15 and cytokeratin 20 expression." *Archives of Pathology and Laboratory Medicine* 1998; 122: 1077-1081.
- [8] Wong SM, Freedman RA, Stamell E, Sagara Y, Brock JE, Desantis SD and Golshan M. Modern Trends in the Surgical Management of Paget's Disease. *Ann Surg Oncol* 2015; 22: 3308-16.
- [9] Feuer G, Shevchuk M and Calanog A. Vulvar Paget's disease: the need to exclude an invasive lesion. *Gynecol Oncol* 1990; 38: 81-89.
- [10] Lam C and Funaro D. Extramammary Paget's disease: summary of current knowledge. *Dermatol Clin* 2010; 28: 807-826.
- [11] Shepherd V, Davidson EJ and Davies-Humphreys J. Extramammary Paget's disease. *BJOG* 2005; 112: 273-279.
- [12] Hatta N, Yamada M, Hirano T, Fujimoto A and Mortia R. Extramammary Paget's disease: treatment, prognostic factors and outcome in 76 patients. *Br J Dermatol* 2008; 158: 313-318.
- [13] Cai YP, Sheng WQ, Xiang LB, Wu XH and Yang HJ. Primary extramammary Paget's disease of

Report of vulvar Paget's disease

- the vulva: The clinicopathological features and treatment outcomes in a series of 43 patients. *Gynecol Oncol* 2013; 129: 412-416.
- [14] Ellis PE, Maclean AB, Wong LF, Fong T, Crow JC and Perrett CW. Angiogenesis in Paget's disease of the vulva and the breast: correlation with microvessel density. *J Oncol* 2012; 2012: 651507.
 - [15] Kodama S, Kaneko T, Saito M, Yoshiya N, Honma S and Tanaka K. A clinicopathologic study of 30 patients with Paget's disease of the vulva. *Gynecol Oncol* 1995; 56: 63-70.
 - [16] Curtin JP, Rubin SC, Jones WB, Hoskins WJ and Lewis JL. Paget's disease of the vulva. *Gynecol Oncol* 1990; 39: 374-377.
 - [17] Helwig EB and Graham JH. Paget's disease. *Cancer* 1963; 16: 387-403.
 - [18] Tebes S, Cardosi R and Hoffman M. Paget's disease of the vulva. *Am J Obstet Gynecol* 2002; 187: 281-284.
 - [19] Black D, Tornos C, Soslow RA, Awtrey CS, Barakat RR and Chi DS. The outcomes of patients with positive margins after excision for intraepithelial Paget's disease of the vulva. *Gynecol Oncol* 2007; 104: 547-550.
 - [20] Gunn RA and Gallagher HS. Vulvar Paget's disease: a topographic study. *Cancer* 1980; 46: 590-594.
 - [21] Shaco-Levy R, Bean SM, Vollmer RT, Jewell E, Jones EL, Valdes CL, Bentley RC, Selim MA and Robboy SJ. Paget's disease of the vulva: a study of 56 patients. *Eur J Obstet Gynecol Reprod Biol* 2010; 149: 86-91.
 - [22] Parker LP, Parker JR, Bodurka-Bervers D, Deavers M, Bervers MW, Shen-Gunther J, Gershenson DM. Paget's disease of the vulva: pathology, pattern of involvement, and prognosis. *Gynecol Oncol* 2000; 77: 183-189.
 - [23] Gunn RA and Gallagher HS. Vulvar Paget's disease: a topographic study. *Cancer* 1980; 46: 590-594.
 - [24] Adamsons K Jr, Reisfield D. Observations on intradermal migration of paget cells. *Am J Obstet Gynecol* 1964; 90: 1274-1280.
 - [25] O'Conner WJ, Lim KK, Zalla MJ, Gagnot M, Otley CC, Nguyen TH and Roenigk RK. Comparison of Moh's micrographic surgery and wide excision for extramammary Paget's disease. *Dermatol Surg* 2003; 29: 723-727.
 - [26] Hendi A, Brodland DG and Zitelli JA. Extramammary Paget's disease: surgical treatment with Mohs micrographic surgery. *J Am Acad Dermatol* 2004; 51: 767-773.
 - [27] Anton C, Luiz AV, Carvalho FM, Barakat EC, Carvalho JP. Clinical treatment of vulvar paget's disease: a case report. *Clinics* 2011; 66: 1109-1111.