

Case Report

Metastatic renal pelvis carcinoma to the testis: a case report and review of the literature

Liwei Xu, Zhigen Zhang, Gonghui Li

Department of Urology, Sir Run Run Shaw Hospital, College of Medical Sciences, Zhejiang University, Hangzhou, China

Received January 5, 2016; Accepted April 1, 2016; Epub June 15, 2016; Published June 30, 2016

Abstract: Metastasis from urothelial carcinoma to the testis is rare. This case report presented an extremely rare case of testicular metastasis from renal pelvis carcinoma in a 69 year old man who had experienced painless left testicular swelling, after he underwent radical nephroureterectomy and bladder cuff excision for the urothelial carcinoma of left renal pelvis ten years ago. Physical examination found a 2- to 3-cm mass in the left testicle and he was slightly tender on palpation. A scrotal ultrasound demonstrated a soft tissue mass, measuring 3.0×2.5×2.0 cm, within the left testicle. Left radical orchiectomy was performed. The pathologic diagnosis was metastatic urothelial carcinoma of the left testicle. We reviewed 12 cases of testicular metastasis from urothelial carcinoma in the existing literature in English. To our knowledge, our case is the first individual case report of testicular metastasis from renal pelvis urothelial carcinoma. We hypothesized that the most possible pathway for testicular metastasis from urothelial carcinoma is the lymphovascular system and transurethral surgery. Excision of local lesions in selected patients is suggested and may provide satisfactory management of the tumor.

Keywords: Renal pelvis carcinoma, urothelial carcinoma, metastasis, testicular neoplasm

Introduction

Urothelial carcinomas (UCs) are the fourth most common tumors [1]. Bladder tumors account for 90-95% of UCs and are the most common malignancy of the urinary tract. However, Upper tract urothelial carcinomas (UTUCs) are uncommon and account for only 5-10% of UCs [1]. The most common metastasis of UC is to the regional lymph nodes, although metastasis to the bone, lung, and liver is not rare [2]. A multitude of tumor types metastasizes to the testes, including some sarcomas, but most studies have found tumors from prostate, lung, skin (melanoma), colon and kidney in descending order of frequency, to be the more common ones [3]. Metastasis from UC to the testis is very rare. We searched the English medical literature using the MEDLINE/PUBMED database. Our search yielded 12 cases of testicular metastasis from UCs (**Table 1**) [4-15]. Only two case reports are available in the literature regarding UTUCs metastasizing to the testicle [6, 15]. This report presented an extremely rare

case of metastatic renal pelvis carcinoma to the testis. To our knowledge, this is the first individual case report of testicular metastasis from renal pelvis urothelial carcinoma.

Case report

A 69-year-old man initially presented to a local hospital in October of 2005 with a symptomatic visible hematuria. His preoperative investigations revealed a left renal pelvis tumor. A cystoscopy at the time was normal. Open radical nephroureterectomy with bladder cuff excision was performed and the histology showed a moderately differentiated papillary urothelial carcinoma of the left renal pelvis with invasion to the muscularis. He presented again in November 2009 with gross, painless hematuria. Cystoscopy showed a small papillary tumor arising from the prostatic urethra and a 2-cm tumor to the left bladder wall. Transurethral resection of the tumor (TURBT) showed G3pT1 UCs of the bladder and prostatic urethra. After surgery, he was scheduled to start instillations

Metastatic renal pelvis carcinoma to the testis

Table 1. Clinical characteristics of reported cases of testicular metastasis from urothelial carcinoma: a review of the literature

Case no.	Author	Age, years	Clinical presentation of primary tumors	Treatment of primary tumors	Pathology of primary tumors	Time of testicular metastasis	Laterality and symptom of testicular metastasis	Other sites of metastasis presentation
1	Turo R et al	61	5-cm tumor from the base of the bladder	TURBT + radical cystoprostatectomy	G3pT4	2 years	Right, painless swelling	Not noted
2	Mahmalji W et al	72	A large left-sided tumor of bladder	TURBT + BCG, cystoprostate-urethrectomy (recurrence)	G2 pT1, Tis, with prostatic invasion	10 years	Left, testicular pain	Para-aortic lymphadenopathy
3	Manav AN et al	56	Left hydronephrosis, an 8.5 × 7.5 cm lymph node surrounding the left proximal ureter	Systemic gemcitabine-cisplatin chemotherapy	NA	The same time	Left, painless swelling	Left para-aortic lymph nodes, pelvic bone, left sixth rib
4	Oppong FC et al	67	Flat tumor on the anterior bladder wall with extension to the lateral walls	Intracavity doxorubicin and subsequent radiotherapy	Poorly differentiated, T1	2 years	Bilateral, painful swollen testis with hydrocele	Not noted
5	Watkin NA et al	68	NA	Cystodiathermy and radical radiotherapy	Poorly differentiated, T2	6 years	NA, a painful, hard testicular swelling	Not noted
6	Kozak GN et al	84	A small tumor below the bladder neck and a larger tumor to the left of the original tumor	TURBT + BCG	Poorly differentiated, T1	15 months	Right, bilateral hydroceles	Paratesticular lymph node
7	Binkley WF et al	69	A mass in the bladder trigone region	TURBT + local radiation	Transitional cell carcinoma (TCC) of urinary bladder and adenocarcinoma of the prostate	8 months	Left, tender and slightly enlarged	Lungs, scalene lymph nodes, liver, vertebra
8	Morgan K et al	74	A 2-cm papillary tumor	TURBT, cystoprostatectomy (recurrence)	G2, noninvasive (TURBT), high-grade TCC invading the trigone, prostate, and seminal vesicles (recurrence)	9 months	Right, firm and tender testis	Not noted
9	Thwaini A et al	74	NA	TURBT + radical cystoprostatectomy	G2 pT3 with involvement of the trigone	3 years	Left, painless swelling	Not noted
10	Kiely G et al	71	A large bladder mass	TURBT	G3T2, with squamous differentiation	1 year	Left, painless swelling	Pulmonary and paratracheal tissue
11	Doherty AP et al	64	NA	Radical radiotherapy	Moderately differentiated, T3	6 years	Bilateral, enlarged	Not noted
12	Wang CN et al	64	Complete obstruction in the mid-third ureter	Radical nephroureterectomy with bladder cuff excision + radiotherapy + systemic chemotherapy	G2,T2	5 months	Left, painful swelling	Not noted
13	Present case	69	Left renal pelvis mass	Radical nephroureterectomy with bladder cuff excision	Moderately differentiated, with invasion to the muscularis	10 years	Left, painless swelling	Not noted

NA: not available.

Metastatic renal pelvis carcinoma to the testis

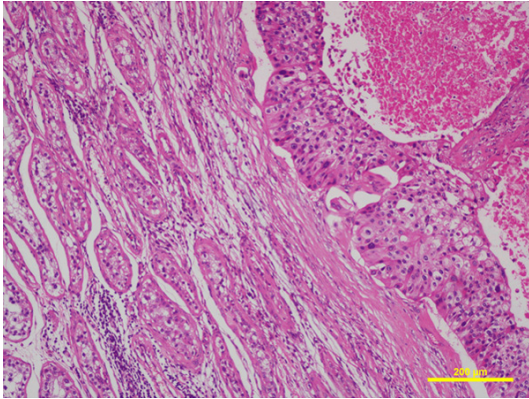


Figure 1. Microscopic section of the left testicle shows a nested and infiltrated growth pattern of urothelial carcinoma. The heteromorphism of the tumor cells was obvious and nuclear mitosis was common (hematoxylin and eosin 100 \times).

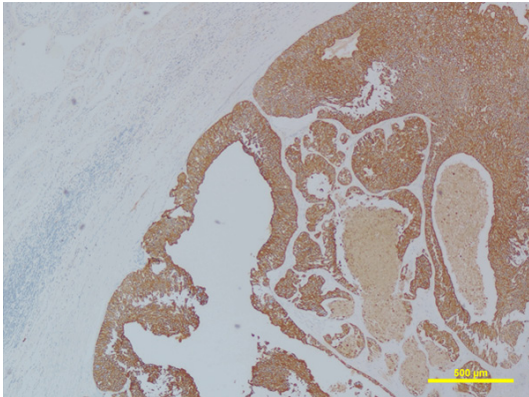


Figure 2. The neoplastic cells exhibited marked positivity for cytokeratin (CK) 20 (CK20 immunostain; 40 \times).

of intravesical Epirubicin. Regular follow up and cystoscopic surveillance lasted two years after TURBT and showed no evidence of tumor recurrence. In July 2015, he presented to our urology department complaining of a one-month history of gross hematuria and painless left testicular swelling. Physical examination found a 2- to 3-cm mass in the left testicle and he was slightly tender on palpation. A scrotal ultrasound demonstrated a hypoechoic and hypervascular soft tissue mass, measuring 3.0 \times 2.5 \times 2.0 cm, within the left testicle and a normal right testicle. Cystoscopy revealed a flat cauliflower-like mass on the posterior wall of the bladder. Computed tomography (CT) showed thickening of the bladder wall and a possible mass in the posterior aspect of the bladder. No other hy-

permetabolic activity was observed anywhere else.

On July 22, 2015, he underwent TURBT and left radical orchiectomy. The resected left testicle with intact tunica albuginea measured 6.0 \times 4.0 \times 3.0 cm. On cut section, the testicle contained a well-circumscribed grayish-yellow mass about 2.6 \times 2.1 cm. The lesion was confined to the testicle with no involvement of the tunicas, epididymis, paratesticular soft tissue, or spermatic cord. Microscopically, the tumor had a nested and infiltrated growth pattern. The heteromorphism of the tumor cells was obvious and nuclear mitosis was common (**Figure 1**). There were multiple intratubular tumor thrombus. The neoplastic cells exhibited marked positivity for cytokeratin (CK) 20 (**Figure 2**) and were negative for cluster of differentiation (CD) 117, placental alkaline phosphatase (PLAP), vimentin (VM), inhibin α . The spermatic cord and resection margins were negative. The pathologic diagnosis was metastatic UC of the left testicle.

The patient had an uneventful recovery and received adjuvant chemotherapy of cisplatin and gemcitabine.

Discussion

When radical nephroureterectomy with bladder cuff excision is performed, local recurrence of UTUC is rare and the risk of distant metastases is directly related to the risk factors such as tumor location, surgical waiting time, tumor stage and grade, lymphovascular invasion, surgical margins, pathological factors. The distant metastasis of UC to the bone, lung, and liver is not rare. By contrast, testicular metastasis from UC is exceptionally rare. Metastases to the testis are most commonly incidental findings at autopsy or in therapeutic orchiectomy specimens performed for the treatment of prostate cancer [16]. Prostate and lung together account for over 50% of the primary sites [10]. Clinically, there are no specific features that differentiate primary from secondary testicular tumors, as both may present with local pain, tenderness, painless swelling. Also, serum tumor markers such as alpha-feto protein (AFP) and human chorionic gonadotropin (hCG) are not helpful in distinguishing primary from secondary testicular tumors. Thus in older patients presenting a solitary testicular mass, the differential diagno-

Metastatic renal pelvis carcinoma to the testis

sis must include metastatic carcinoma. A personal history of cancer should first be investigated. The mean age of 13 patients with secondary testicular neoplasms in this series was 69 years with an age range from 56 to 84 years. In contrast, patients with primary testicular neoplasms are generally younger. According to the reviewed cases, 3/13 (23%) were in right side, 7/13 (54%) in left side, and 2/13 (15%) in bilateral testis. Four patients 4/13 (31%) felt testicular pain, 2 patients 2/13 (15%) first presented as hydrocele. Two patients were initially diagnosed as epididymitis and treated with antibiotics which turned out to be no effect. Most of the patients 10/13 (77%) had their primary tumor in the bladder and only 2/13 (15%) in the ureter. Only the case in our report found the primary tumor was from the renal pelvis. The length of time from the diagnosis of primary tumor to testicular metastasis ranged from 5 months to 10 years. Except in one case, the primary tumor and multiple metastasis were found at the same time [6].

The rarity of metastatic involvement of testis remains unexplained. The low incidence of secondary tumors to the testis is apparently due to the lower temperature of the scrotum, which could impair the metastatic ability of tumor cells from solid organs. It may also be due to blood-testis and blood-epididymis barrier. The tight junctions between Sertoli cells and epididymis epithelial cells respectively, build a functional barrier of utmost competence [17]. Various routes of spread of metastatic tumors to the testes have been suggested, including arterial embolization from the tumor, retrograde venous spread, retrograde lymphatic spread, direct spread along the vas deferens to the epididymis, and transperitoneal seeding through a patent tunica vaginalis. The dissemination mechanism seems to vary with type and location of the primary tumor, and one does not exclude the other [18]. Metastatic pathways from UCs to the testis remain speculative. There were only three UTUC cases in this series and one case was not confirmed by pathologic diagnosis [6]. Wang CN, et al [15] thought that the mechanism of ureteral cancer metastasis to the testis may be reflux from vas deferens. Tumor cells invaded into the vas deferens through cross of the ureter and the vas deferens. However, we don't agree with them. Only metastasis in the condition that the ureteral

tumor located near the vas deferens can be explained by their hypothesis. We think that lymphatic spread is a very important route and past transurethral surgery may promote the metastasis. In the present case, multiple intratubular tumor thrombus were found in the testicle specimen, suggesting lymphatic metastasis. In the reviewed cases, we find eight patients 8/13 (62%) accepted transurethral surgery before testicular metastasis. In our case, the patient underwent transurethral surgery for recurrent tumors of bladder and prostatic urethra. The bladder recurrence and transurethral operation may cause the tumor cells spread to the testicle. Another possible mechanism is through retrograde descent whereby tumor cells can directly seed via descent through the testicular veins. This theory may potentially explain the ipsilateral deposit of metastasis in our case.

Testicular metastases usually are a manifestation of widely disseminated tumors. Five patients 5/13 (38%) had other synchronous sites of metastasis in the reviewed cases. Therapeutic strategies used for any metastatic tumor include palliative chemotherapy, radiation, and sometimes surgery. Because there are no randomized clinical trials on resection of testicular metastasis from UCs, the benefit for resection of testicular metastasis is not clear. We suggest that surgery be done if the patient could endure. First, it can clarify the diagnosis. Then surgery can palliate symptoms and control tumor growth. And most importantly, resection of testicular metastasis from UCs may improve survival for these patients. There were two patients doing well at 1.5 years [11] and 21 months [15] after orchiectomy. Post-operative platinum-based chemotherapy remains of clear benefit in improving survival and should be considered.

In conclusion, we present an extremely rare case of testicular metastasis from renal pelvis carcinoma. We hypothesized that the most possible pathway for testicular metastasis from UC is the lymphovascular system and transurethral surgery may promote the metastasis. Excision of local lesions is suggested and may provide satisfactory management for such patients.

Disclosure of conflict of interest

None.

Metastatic renal pelvis carcinoma to the testis

Address correspondence to: Gong-Hui Li, Department of Urology, Sir Run Run Shaw Hospital, College of Medical Sciences, Zhejiang University, Hangzhou 310016, China. E-mail: ligonghui1970@hotmail.com

References

- [1] Munoz JJ and Ellison LM. Upper tract urothelial neoplasms: incidence and survival during the last 2 decades. *J Urol* 2000; 164: 1523-1525.
- [2] Shinagare AB, Ramaiya NH, Jagannathan JP, Fennessy FM, Taplin ME and Van den Abbeele AD. Metastatic pattern of bladder cancer: correlation with the characteristics of the primary tumor. *AJR Am J Roentgenol* 2011; 196: 117-122.
- [3] Morichetti D, Mazzucchelli R, Lopez-Beltran A, Cheng L, Scarpelli M, Kirkali Z, Montorsi F and Montironi R. Secondary neoplasms of the urinary system and male genital organs. *BJU Int* 2009; 104: 770-776.
- [4] Turo R, Smolski M, Hatimy U, Bromage SJ, Brown SC, Brough R and Collins GN. A rare case of testicular metastasis of bladder transitional cell carcinoma. *Can Urol Assoc J* 2014; 8: E181-183.
- [5] Mahmalji W, Jain S and Stower M. A rare cause of scrotal swelling: transitional cell carcinoma of the bladder presenting as a testicular metastasis. *Adv Urol* 2011; 2011: 284121.
- [6] Manav AN, Kazan E, Ertek MS, Amasyali AS, Culhaci N and Erol H. A rare cause of testicular metastasis: upper tract urothelial carcinoma. *Case Rep Urol* 2014; 2014: 759858.
- [7] Oppong FC and Rundle JH. Bilateral testicular secondaries from transitional cell carcinoma of the bladder. *Br J Urol* 1991; 68: 430.
- [8] Watkin NA, Gallegos CR, Moisey CU and Charlton CA. Metastatic bladder cancer involving the testis. *Br J Urol* 1994; 74: 380.
- [9] Kozak GN and Field NC. Metastatic transitional cell carcinoma of the bladder to the testis: a case report. *Case Rep Urol* 2012; 2012: 486245.
- [10] Binkley WF and Seo IS. Metastatic transitional cell carcinoma of the testis. A case report. *Cancer* 1984; 54: 575-578.
- [11] Morgan K, Srinivas S and Freiha F. Synchronous solitary metastasis of transitional cell carcinoma of the bladder to the testis. *Urology* 2004; 64: 808-809.
- [12] Thwaini A, Kaluba J, Shergill I, Kumar R and Lewi H. Testicular metastasis of transitional cell carcinoma of the urinary bladder: an unusual site. *Int J Urol* 2006; 13: 1136-1137.
- [13] Kiely G, Kavanagh L, Bolton D and Lawrentschuk N. Urothelial carcinoma of the bladder with asynchronous metastases to both testes. *Urol Ann* 2013; 5: 218-219.
- [14] Doherty AP, Smith R, Paradinis FJ, Bower MD and Ramsay JW. A case of metastatic transitional cell carcinoma in the testis histologically mimicking intratubular germ cell neoplasia. *Br J Urol* 1996; 78: 137-138.
- [15] Wang CN, Huang CN, Hsiao PH, Chou YH and Huang CH. An unusual testicular metastasis from transitional cell carcinoma of the ureter: a case report. *Gaoxiong Yi Xue Ke Xue Za Zhi* 1995; 11: 578-581.
- [16] Ulbright TM and Young RH. Metastatic carcinoma to the testis: a clinicopathologic analysis of 26 nonincidental cases with emphasis on deceptive features. *Am J Surg Pathol* 2008; 32: 1683-1693.
- [17] Mital P, Hinton BT and Dufour JM. The blood-testis and blood-epididymis barriers are more than just their tight junctions. *Biol Reprod* 2011; 84: 851-858.
- [18] Dutt N, Bates AW and Baithun SI. Secondary neoplasms of the male genital tract with different patterns of involvement in adults and children. *Histopathology* 2000; 37: 323-331.