

## Case Report

# Pseudo-progression in a patient with lung adenocarcinoma and ALK fusion who responded to crizotinib

Chunxia Su<sup>1\*</sup>, Shengxiang Ren<sup>1\*</sup>, Xuefei Li<sup>2</sup>, Likun Hou<sup>3</sup>, Caicun Zhou<sup>1\*</sup>

<sup>1</sup>Departments of Medical Oncology, <sup>2</sup>Lung Cancer and Immunology, <sup>3</sup>Pathology, Shanghai Pulmonary Hospital, Tongji University School of Medicine, Tongji University Medical School Cancer Institute, No. 507 Zheng Min Road, Shanghai 200433, People's Republic of China. \*Equal contributors.

Received May 27, 2015; Accepted March 21, 2016; Epub June 15, 2016; Published June 30, 2016

**Abstract:** The dramatic responses to small molecule inhibitors such as EGFR-TKI and ALK inhibitor observed in advanced NSCLC patients harboring relevant oncogenic mutations have made personalized therapy into reality. We here report the first case of a patient with lung adenocarcinoma and EML4-ALK fusion who got pseudo oligo-metastatic progression after 6 months treatment of crizotinib. Re-biopsy revealed pulmonary cryptococcosis and thereafter the patient received continuous crizotinib plus antifungal therapy and benefited another 12.1 months from ALK inhibitor. Hence, re-biopsy for patient with advanced NSCLC who might progress from the targeted drugs such as ALK inhibitor to exclude the possibility of pseudo-progression is of clinical significance.

**Keywords:** Pseudo-progression, lung adenocarcinoma, ALK fusion, crizotinib

### Case report

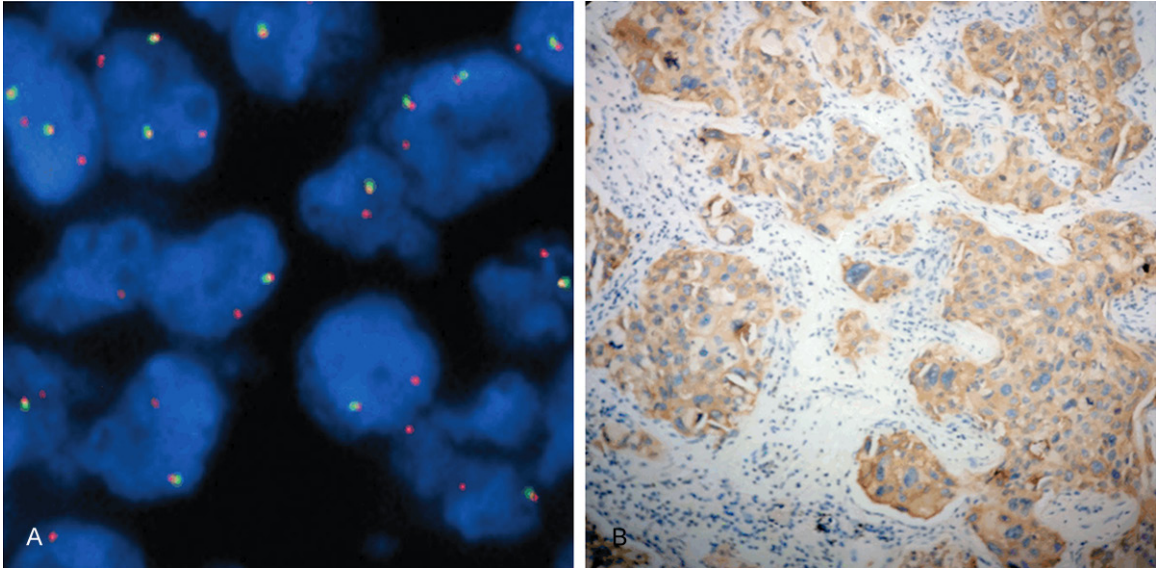
A 46 year-old Chinese male, none-smoker, was referred to Shanghai Pulmonary Hospital in May 2013 for a left upper lobe nodule and cervical, mediastinum 4R/5 and hilar 10 L lymph nodal enlargement. He had no medical, family, and psychosocial history. Bone scan showed multiple metastases. His left cervical lymph nodes with 2 cm of diameter were found upon physical examination. Cervical lymph node biopsy revealed acinar adenocarcinoma and Scorpion Amplification Refractory Mutation system (AmoyDx Co., Xiamen, China) showed no detectable epidermal growth factor receptor mutation, while ALK break-apart FISH (Fluorescence in situ hybridization) test showed loss of the ALK 5 (centromeric) probe (**Figure 1A**) using the commercially available break-apart probe set (Abbott Molecular, Des Plaines, IL). ALK immunohistochemistry (clone ALK1, Dako UKLtd, DM828) test result was also positive (**Figure 1B**).

He commenced chemotherapy initially with pemetrexed plus cisplatin. However, after two

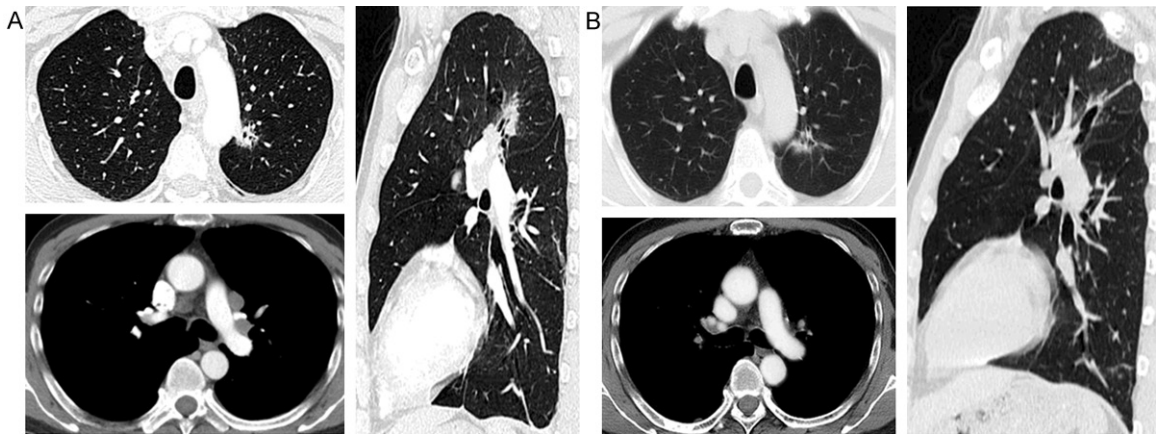
cycles of treatment, his symptom worsened and CT scan confirmed progressive disease of the lung. Then, the patient received crizotinib orally 250 mg twice daily as a surrogate regimen and reached partial response (**Figure 2A, 2B**), side effect was mild, only with grade 1 of visual impairment and grade 1 diarrhea. However, six months later in Jan 2014, his symptoms worsened with productive cough and CT scan showed a new nodule in left lower lobe (**Figure 3A**).

Then the re-biopsy on the new nodule was performed to elucidate the possible resistant mechanism. However, no malignant cells but necrosis were found on the pathological examination. Immunohistochemistry test of the re-biopsy sample showed six ammonia silver and PAS both were positive. Cryptococcosis latex agglutination test was undergone using the re-biopsy sample and serum sample and both revealed positive with a titer of 1:128. The patient then received continuous crizotinib with a reduced dose of 200 mg twice daily and anti-fungal drug of fluconazole, 400 mg/day orally.

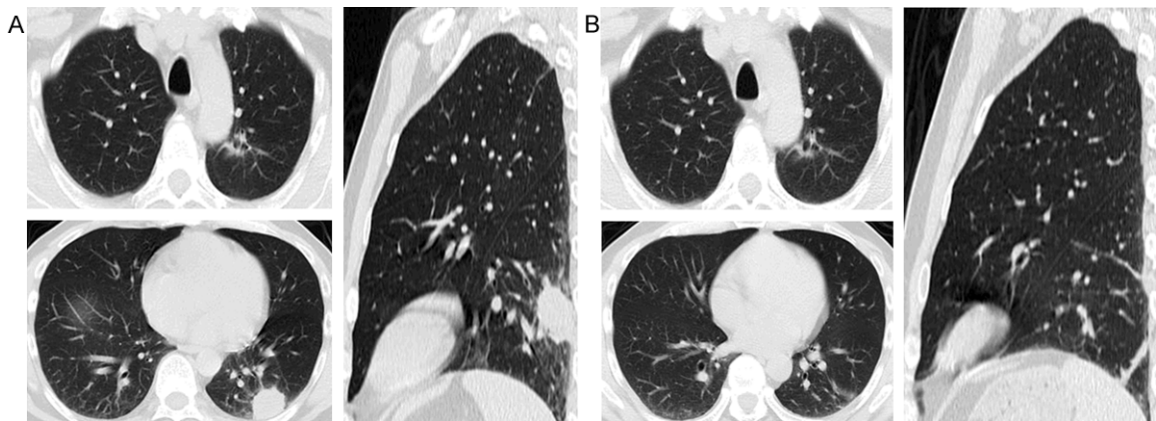
## Pseudo-progression after crizotinib treatment in lung cancer



**Figure 1.** Oncogene detection- biopsy sample from cervical lymph node. (A: ALK Fish; B: ALK IHC).



**Figure 2.** Computed tomography (CT)-scan before (A: Baseline) and after (B: Three months later) second-line crizotinib treatment.



**Figure 3.** Six months treatment after ALK-inhibitor when anti-fungal treatment started (A) vs. six months after anti-fungal treatment combined with reduced dose of crizotinib treatment (B).

## Pseudo-progression after crizotinib treatment in lung cancer

Two months later, the new nodule was resolved. Six months later, it disappeared and fluconazole was stopped (**Figure 3B**). Then he continued to receive crizotinib alone until progressive disease with multiple pleural effusion and pericardial effusion in Jan 7th 2015. The patient died 2 months later for uncontrolled lung cancer disease.

### Discussion

We here report the first case of a patient with lung adenocarcinoma and EML4-ALK fusion who got pseudo oligometastatic progression after 6 months treatment of crizotinib. Re-biopsy revealed pulmonary cryptococcosis and thereafter the patient received continuous crizotinib plus antifungal therapy and benefited another 12.1 months from ALK inhibitor.

The dramatic responses to small molecule inhibitors such as EGFR-TKI and ALK inhibitor observed in advanced NSCLC patients harboring relevant oncogenic mutations have made personalized therapy into reality [1-3]. However, acquired resistance to the initial kinase inhibitor will eventually develop, thus drugs that can overcome resistance are warranted [4-6]. Accordingly, several next-generation inhibitors of EGFR and ALK have been developed, with impressive early signs of clinical activity [7, 8]. Thus, in addition to the initial genomic diagnosis, precise determination of the actual mechanism of resistance through re-biopsy is a key requirement to provide optimal clinical care to patients. Besides that, the present case revealed that re-biopsy could found alternative possibilities such as pseudo-progression.

Recently, pseudo-progression has attracted the attention of oncologist with the understanding of immunotherapy therapy such as PD1/PDL1 antibody. Initial progression from the treatment of PD1 antibody such as nivolumab according to RECIST criteria has showed tumor shrinkage thereafter [9]. Here we showed the first case of pseudo-progression after treatment of crizotinib. A new nodule was found after 6 months of crizotinib treatment and a re-biopsy revealed fungus infection. With the therapy of antifungal treatment together with a reduction dose of crizotinib, the new nodule finally disappeared.

In conclusion, in addition to clarify the mechanism of acquired resistance, this case emphasizes the importance of re-biopsy in patient with advanced NSCLC who might progress from the targeted drugs such as ALK inhibitor to exclude the possibility of pseudo-progression.

### Acknowledgements

This study was supported by grants from National Natural Science Fund (No. 81201707 & 81402486 & 81401890), Science and Technology Commission of Shanghai Municipality (No. 12ZR1426000 & 132R1434600) and Shanghai City Health Bureau (Grant numbers: 20124259).

### Disclosure of conflict of interest

None.

**Address correspondence to:** Dr. Caicun Zhou, Department of Medical Oncology, Shanghai Pulmonary Hospital, Tongji University School of Medicine, No. 507 Zheng Min Road, Shanghai 200433, People's Republic of China. Fax: 86-21-55660346; E-mail: caicunzhou@163.com

### References

- [1] Shaw AT, Kim DW, Nakagawa K, Seto T, Crinó L, Ahn MJ, De Pas T, Besse B, Solomon BJ, Blackhall F, Wu YL, Thomas M, O'Byrne KJ, Morosibilot D, Camidge DR, Mok T, Hirsh V, Riely GJ, Iyer S, Tassell V, Polli A, Wilner KD, Jänne PA. Crizotinib versus chemotherapy in advanced ALK-positive lung cancer. *N Engl J Med* 2013; 368: 2385-94.
- [2] Antoniu SA. Crizotinib for EML4-ALK positive lung adenocarcinoma: a hope for the advanced disease? Evaluation of Kwak EL, Bang YJ, Camidge DR, et al. Anaplastic lymphoma kinase inhibition in non-small-cell lung cancer. Erratum in: *N Engl J Med* 2010; 363: 1693-703. *Expert Opin Ther Targets* 2011; 15: 351-3.
- [3] Zhou C, Wu YL, Chen G, Feng J, Liu XQ, Wang C, Zhang S, Wang J, Zhou S, Ren S, Lu S, Zhang L, Hu C, Hu C, Luo Y, Chen L, Ye M, Huang J, Zhi X, Zhang Y, Xiu Q, Ma J, Zhang L, You C. Erlotinib versus chemotherapy as first-line treatment for patients with advanced EGFR mutation-positive non-small cell lung cancer (OPTIMAL, CTONG-0802): a multicentre, open-label, randomized, phase 3 study. *Lancet Oncol* 2011; 12: 735-42.

## Pseudo-progression after crizotinib treatment in lung cancer

- [4] Qi X, Ma W, Li S, Zhou C. Overcoming crizotinib resistance in ALK-rearranged non-small cell lung cancer. *Lung Cancer* 2014; 85: 335-6.
- [5] Li W, Ren S, Li J, Li A, Fan L, Li X, Zhao C, He Y, Gao G, Chen X, Li S, Shi J, Zhou C, Fei K, Schmid-Bindert G. T790M mutation is associated with better efficacy of treatment beyond progression with EGFR-TKI in advanced NSCLC patients. *Lung Cancer* 2014; 84: 295-300.
- [6] Yu HA, Arcila ME, Rekhtman N, Sima CS, Zakowski MF, Pao W, Kris MG, Miller VA, Ladanyi M, Riely GJ. Analysis of tumor specimens at the time of acquired resistance to EGFR-TKI therapy in 155 patients with EGFR-mutant lung cancers. *Clin Cancer Res* 2013; 19: 2240-7.
- [7] Ranson M, Pao W, Kim DW. AZD9291: an irreversible, potent and selective tyrosine kinase inhibitor (TKI) of activating (EGFRm+) and resistance (T790M) mutations in advanced NSCLC (ID 2289). *J Thorac Oncol* 2013; 8 Suppl 2: S389.
- [8] Shaw AT, Kim DW, Mehra R, Tan DS, Felip E, Chow LQ, Camidge DR, Vansteenkiste J, Sharma S, De Pas T, Riely GJ, Solomon BJ, Wolf J, Thomas M, Schuler M, Liu G, Santoro A, Lau YY, Goldwasser M, Boral AL, Engelman JA. Ceritinib in ALK-rearranged non-small-cell lung cancer. *N Engl J Med* 2014; 370: 1189-97.
- [9] Rizvi NA, Mazières J, Planchard D, Stinchcombe TE, Dy GK, Antonia SJ, Horn L, Lena H, Minenza E, Mennecier B, Otterson GA, Campos LT, Gandara DR, Levy BP, Nair SG, Zalcman G, Wolf J, Souquet PJ, Baldini E, Cappuzzo F, Chouaid C, Dowlati A, Sanborn R, Lopez-Chavez A, Grohe C, Huber RM, Harbison CT, Baudelet C, Lestini BJ, Ramalingam SS. Activity and safety of nivolumab, an anti-PD-1 immune checkpoint inhibitor, for patients with advanced, refractory squamous non-small-cell lung cancer (CheckMate 063): a phase 2, single-arm trial. *Lancet Oncol* 2015; 16: 257-65.