

Original Article

Clinical outcomes and cost analysis for unilateral versus bilateral pedicle screw fixation in two levels during minimally invasive transforaminal lumbar interbody fusion (MIS-TLIF): a comparative analysis

Kang Han^{1,2*}, Quanyou Gao^{2*}, Haoran Gao², Yao Lu³, Na Bian¹, Qingxi Meng¹, Xiang Chen⁴, Changsheng Yang¹, Zengkun Yang¹, Jixian Qian², Tingbao Zhao¹

¹Department of Spinal Cord Injury, General Hospital of Jinan Military Area Command of Chinese PLA, Jinan, Shandong, P. R. China; ²Department of Orthopedic Surgery, Orthopedics Oncology Institute of Chinese PLA, Tangdu Hospital, Fourth Military Medical University, Xi'an, Shaanxi, P. R. China; ³Department of Orthopedic Surgery, Xi'an Honghui Hospital, Medical College of Xi'an Jiaotong University, No. 76, Nanguo Road, Beilin District, Xi'an, Shanxi, P. R. China; ⁴Department of Baylor College of Medicine, 1709 Dryden Road, Houston, Texas, United States. *Equal contributors.

Received January 6, 2016; Accepted May 4, 2016; Epub June 15, 2016; Published June 30, 2016

Abstract: Study Design: Retrospective clinical study of 116 patients who underwent either a bilateral or unilateral TLIF procedure for the treatment of degenerative lumbar diseases. Objectives: We design this retrospective clinical study to compare the clinical, radiological outcomes and complication of unilateral pedicle screw (UPS) versus bilateral pedicle screw (BPS) in degenerative lumbar diseases after MIS-TLIF. Summary of Background Data. Studies have shown that minimally invasive transforaminal lumbar interbody fusion (MIS-TLIF) was used in a large number of lumbar degenerative disorders. However, unilateral or bilateral pedicle screw fixation after MITLIF remains controversial, especially in two-level surgery. Methods: We retrospectively analyzed 116 consecutive patients who had two-level MIS-TLIF at L4/L5 and L5/S1 from January 2010 to January 2014 and the clinical and radiological outcome and the complication were compared. Of the 116 patients for analysis, 52 patients underwent unilateral fixation, and 64 patients underwent bilateral fixation. Results: There was no statistically significant difference in baseline demographic characteristics and in hospital-stay period between the two groups ($P>0.05$). There was a significantly longer operating time, more blood loss and X-ray exposure times in BPS comparing with UPS ($P<0.05$). Clinical outcomes in two groups such as the pain (VAS) and Oswestry Disability Index (ODI) improved significantly after surgery and no difference was found between them ($P<0.05$). The number of patients who have good or excellent outcomes in UPS was 84.6% which in BPS was 82.3%. No significant difference was found in fusion rate and total complication rate between the two groups ($P>0.05$). Conclusion: There was no significant difference between the two fixation methods of MIS-TLIF in clinical outcomes and complications. However, unilateral pedicle screw has some superiorities such as shorter operating time, lower cost, less blood loss and X-ray exposure. Unilateral pedicle screw might be more suitable in performing two-level pedicle screw fixation after MIS-TLIF.

Keywords: Minimally invasive, transforaminal lumbar interbody fusion (tlif), unilatera, bilateral, pedicle screw fixation, degenerative spondylolisthesis, clinical outcomes, radiographic analysis

Introduction

For a long time, posterior lumbar interbody fusion (PLIF) was regarded as the major decompressive surgery to treat the lumbar degenerative diseases [1, 2]. However, more and more shortage were found such as dural tear, epidural bleeding, neural injury, damage of cauda equina as well as adjacent soft tissue sever-

ance [3]. In 1982, TLIF was first introduced by Harms and Rolinger [4] as a alternate technique which could reduce the risk of nerve injury, particularly when it was not the first surgery. A number of studies [5, 6] have found TLIF is equivalent or even superior to PLIF regarding the outcome, fusion rate and complications of the patient. With the development of Medicine, especially the development of minimally inva-

sive spine, minimally invasive transforaminal lumbar interbody fusion (MIS-TLIF) which could have the less invasive variant has grown significantly in popularity and has been studied in detail [7, 8]. Through a small, paramedian muscle-splitting exposure, the objective of the spinal decompression, interbody arthrodesis and pedicle screw fixation can be realized and the blood loss and hospital stay were obviously reduced [9].

Generally, bilateral pedicle screw fixation after MIS-TLIF is the standard of instrumentation to provide spinal stability and it seems that bilateral pedicle screw fixation could have a better rigid fixation and fusion rate [10]. However, unlike open-TLIF, BPS need a second incision and exposure which will inevitably lead to longer operative time, more expensive instrumentation use, bigger tissue damage and more times of X-ray exposure [11]. In fact, the necessity and choice of BPS after the MIS-TLIF has been questioned a lot recently especially when surgical trends have emphasized the minimization of exposure and tissue destruction [12]. In a 87-patients study, Suk et al. found that there was no difference in clinical outcomes and fusion rates between UPS and BPS [13, 14]. In addition, some studies demonstrated UPS was better than BPS [15]. On the contrary, an in vivo animal model study considered that UPS were consistently less rigid [16] and a finite element analysis were not favored for UPS used in contralateral axial rotation [17]. A recent biomechanical study in vitro founded that the UPS after TLIF operation have significantly increased segmental range of motion, off-axis movement and reduced stiffness. In all, the appropriateness of the ways of fixation is still unclear and controversial. What is more, these studies mainly focused on one-level lumbar fusion and few studies involved two-level degenerative lumbar diseases.

In this study, we try to compare the hospital cost and clinical outcome of the patients who have the MIS-TLIF with unilateral or bilateral pedicle screw fixation. We selected the patients whose lesion at L4/L5 and L5/S1 because this levels are the most common location of lumbar disc disease, spinal stenosis and spondylolisthesis. We hope to we could provide the theoretical basis for the clinical treatment of MIS-TLIF through our experiment.

Materials and methods

Ethics statement

The research was approved by the Ethics Review Committee of General Hospital of Jinan Military Area Command of Chinese PLA, Jinan, Shandong, China (approval ID: 2014103) and written informed consent was obtained from all participating patients.

Cohort selection

A total of 116 patients who underwent MIS-TLIF at the General Hospital of Jinan Military Area Command of Chinese PLA between 2010 and 2014 were retrospectively reviewed. Patients included were between the ages of 28 and 76 at the time of operation. All 116 patients were diagnosed with plain radiographs, CT scans, and MRI and had either a unilateral (52 patients) or a bilateral (64 patients) MIS-TLIF for L4/L5 and L5/S1 spinal stenosis and were studied in a follow-up (**Figures 1, 2**). The median follow-up was 31.3 months (range 12-58 months). No patient died during the follow-up period. Indications for the surgery of MIS-TLIF included lumbar disc disease, spinal stenosis and spondylolisthesis. The patients who had previous lumbar surgery were excluded.

Surgical technique

All operations were performed by the same surgeon. When the general anesthesia had the satisfactory result, the patient was placed at the prone position. Then the operative level and incision was marked by using G-arm fluoroscopy. After the disinfection and surgical draping, a 4.5 cm paramedian incision was made over the plane between the longissimus and multifidus components of the sacrospinalis muscle. Then a tubular retractor (Care-Fusion, San Diego, CA) was placed and maintained exposure. A complete facetectomy and the decompression including the central stenosis, the ligamentum flavum and its bony attachment, the deep cortical surface of the contralateral lamina, lateral recess and foramen was performed. The removed bone was handled to granular for later use as the locally harvested autograft. Then, discectomy and intervertebral disc were performed, and the cage was placed. With the help of the SpheRx pedicle screw system (NuVasive, San Diego, CA), percutaneous lumbar pedicle screws were inserted unilaterally or bilaterally under fluoroscopic. Finally, the

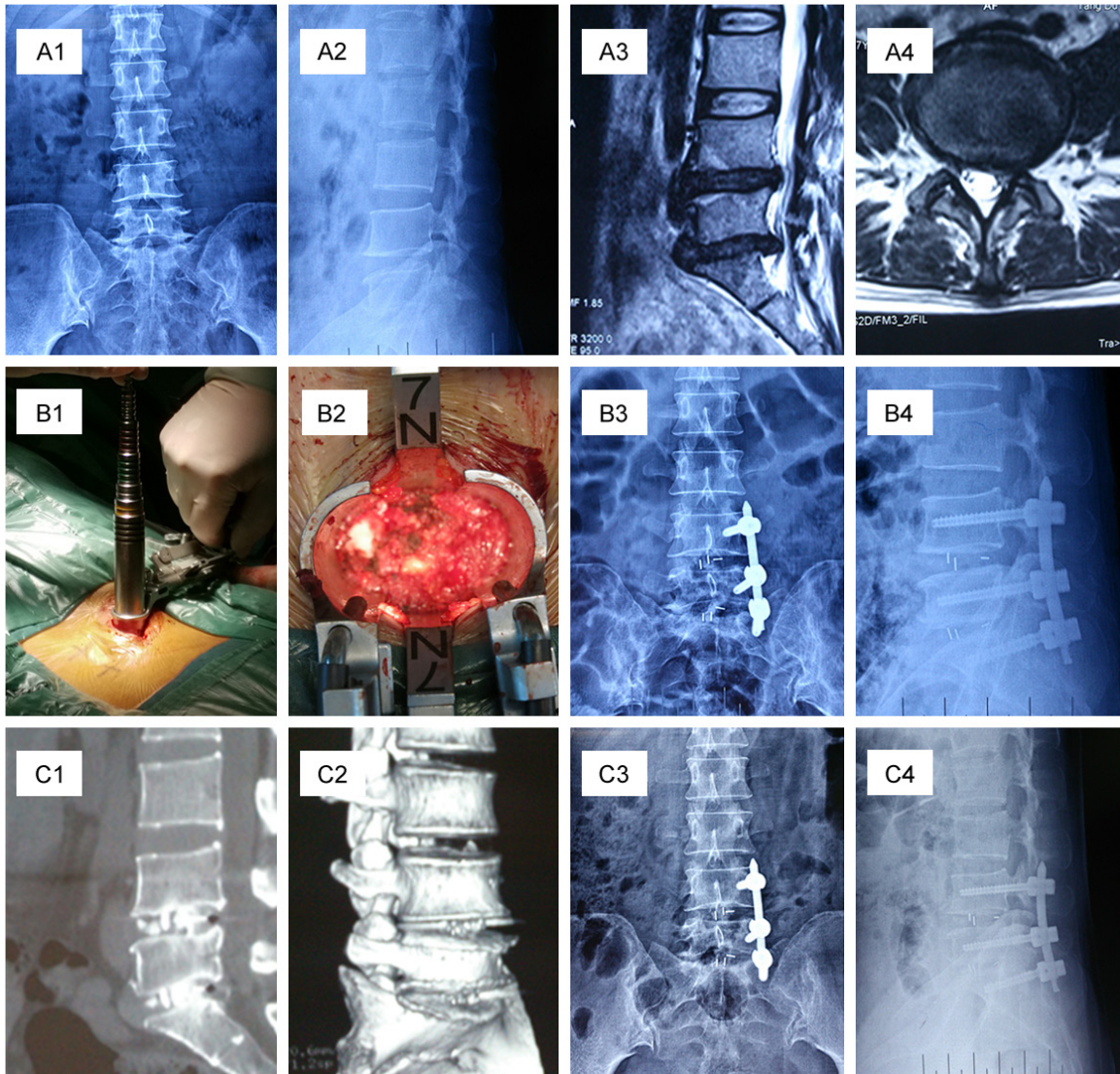


Figure 1. A patient with L4/5 and L5/S1 two-level degenerative lumbar diseases combined with lumbar instability treated with two-level MITLIF and unilateral pedicle screw fixation. (A1-A4) The preoperative images of the patient showing the lumbar disc disease of L4/L5, L5/S1, (A1, A2) are X-ray, (A3, A4) are MRI; (B1, B2) The pictures in the surgery, the establishment of work road; (B3, B4) Radiographs 3 days after MIS-TLIF, X-ray showing the good position of internal fixation; (C1-C4) Lumbar radiographs (C1, C2) and CT imaging reconstruction (C3, C4) 6 months after surgery.

surgical site was copiously irrigated and closed in consecutive layers. When the bilateral instrumentation was performed, a second paramedian incision was performed on the contralateral side and an additional pedicle screw fixation was percutaneous performed.

Post-surgery rehabilitation

All patients were given antibiotics to prevent infection in 48 hours after the operation and they performed the exercises on the bed in the first 5 days. Then they were permitted to begin ambulation while wearing the lumbus sacrum

orthosis. The patients were request not to do the impetuous exercise and protect their lumbus in the first 3 months after the operation, especially in the first 3 weeks. Generally, the patients were allowed to have the discharge from hospital 5 days after the surgery.

Clinical outcome

Clinical outcomes were assessed by the review, clinic notes, phone questionnaire and Email. The date including age, sex, diagnosis, inpatient length of stay, operative time, blood loss and X-ray exposure were accessed and sorting.

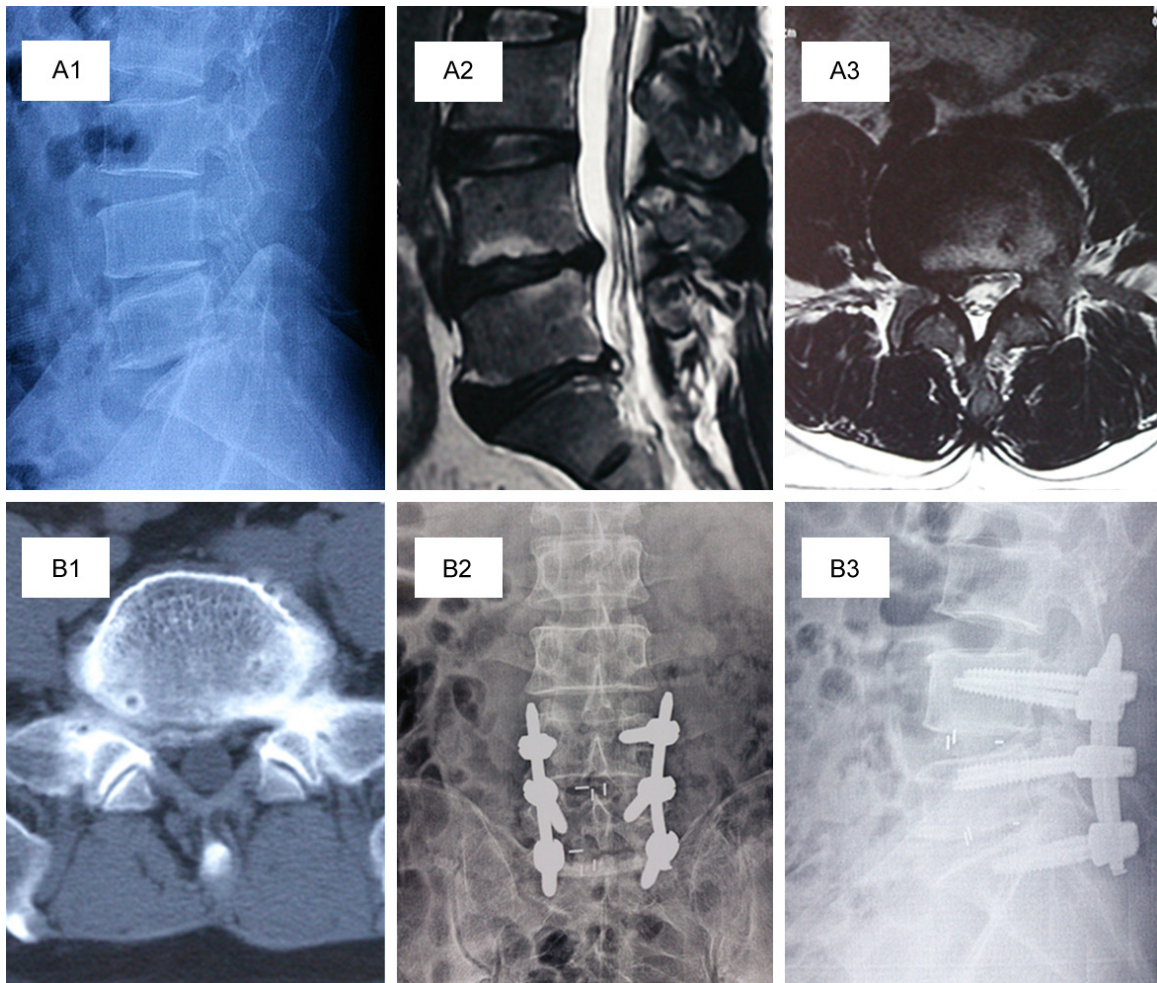


Figure 2. A patient with L4/5 and L5/S1 two-level degenerative lumbar diseases combined with lumbar instability treated with two-level MIS-TLIF and bilateral pedicle screw fixation. A1-B1: The preoperative images of the patient showing the lumbar disc disease of L4/L5, L5/S1, A1 is X-ray, A2, A3 are MRI, A4 is CT; B2, B3: Radiographs of X-ray 3 days after MIS-TLIF showing the good position of internal fixation.

The clinical outcome were determined by visual analog scale (VAS) [18] and Oswestry Disability Index (ODI) [19]. Briefly, according to the Odom's criteria [20], the outcome can be rated either excellent, good, fair, or poor. Fusion and instrumentation status was assessed by radiographic follow-up like CT and radiography and were determined by the Bridwell grading system [21] which could be rated for 4 levels.

Statistical analysis

All values in the paper were expressed as the means \pm SD, and all error bars represent the standard deviation of the mean. Student's *t* test, chi-square test and fisher exact tests were used to determine significance. All statistical tests were two-sided and *P* value of <0.05 was

considered statistically significant. Statistical analyses were performed using SPSS 17.0 software (SPSS Inc, USA).

Results

Of all 116 patients, 52 patients have the unilateralpedicle screw (**Figure 1**) and 64 patients have the bilateralpedicle screw (**Figure 2**). The patient demographics and descriptive statistics are provided in **Table 1**. Mean age was 54.8 ± 12.8 years for UPS group and 51.7 ± 14.4 for the BPS group. The median follow-up was 31.3 months (range 12-58 months). There were no statistically significant differences between the two groups regarding the age or gender, so the patients in the two groups were comparable.

UPS Fixation versus BPS for MIS-TLIF

Table 1. Comparison of the demographic data of the patients in the BPS and the UPS groups

	UPS	BPS	P value
NO.	52	64	
Age (y)	54.8±12.8	51.7±14.4	0.70>0.05
Gender			0.78>0.05
Male	29	34	
Female	23	30	
Disease			0.84>0.05
Lumbar disc disease	28	31	
Spinal stenosis	17	24	
Spondylolisthesis	7	9	
Follow-up (mo)	33.2±14.1	30.0±12.7	0.79>0.05

Table 2. Comparison of the clinical results observed in the patients of the BPS and the UPS groups

	UPS	BPS	P value
Length of stay (d)	9.5±1.0	9.0±1.9	0.585
Operative time (min)	65.3±15.7	100.2±26.5	0.020
Blood loss (mL)	90.8±19.9	129.3±27.2	0.019
X-ray exposure times	7.67±1.75	11.83±2.48	0.007
Complications	1 (1.9%)	1 (1.6%)	0.88
Fusion 6 months 12 months	44 (84.6%) 52 (100%)	54 (84.3%) 64 (100%)	0.97 1
Clinical outcome			0.937
Excellent	20	27	
Good	27	31	
Fair	4	4	
Poor	1	2	

According to perioperative assessments (**Table 2**), the average length of stay in the unilateral group (9.5±1.0 days) was not significantly different from that in the bilateral group (9.0±1.9 days). The operative time of the unilateral group were significantly shorter than that of bilateral group (65.3±15.7 minutes versus 100.2±26.5 minutes, P = 0.020) and the blood loss were significantly lower in the unilateral group (90.8±19.9 ml versus 129.3±27.2 ml, P = 0.019). The X-ray exposure times of unilateral group were significantly lower than that of bilateral group (7.67±1.75 times versus 11.83±2.48 times, P = 0.007). No statistically significant difference was found for complications. One patient had the superficial layer skin infection in bilateral group and one patient had the slight cage moving in UPS group. No reoperation was performed as the purpose to handle the complications.

Radiographic outcome were obtained at 5days, 6 and 12 months after the surgery by using of X-rays, and CTs (**Table 2**). Though there were 8 patients of unilateral group and 10 patients of bilateral group who were defined as unfused 6 months after the surgery, All people had solid fusion 12 months after the surgery.

Regarding clinical outcomes (**Table 3**), the VAS and ODI scores were lower in the UPS group than that in the BPS group at 5 days after the surgery, but there was no significant difference (P>0.05). There were no significant difference between 2 groups at 6 and 12 months after the surgery. 90.4% (47/52) of the patients of the UPS group had good or excellent outcomes and the date was 90.6% (58/64) in the BPS group. This was not statistically significant (P = 0.937) (**Table 2**).

The hospital cost was significantly lower in UPS than BPS as a result of different implant cost (P<0.05). The cost of implants for the UPS group was 32.3% less than those for the bilateral group.

Discussion

Now, lumbar fusion is a very common surgical procedure in the treating for degenerative lumbar diseases and there are a variety of ways to achieve the aim of fusion [22]. With the surgery technological advancements and a better understanding of the morbidity of prolonged muscle retraction, the minimization of exposure and tissue destruction are needed. MIS-TLIF including decompression and instrumentation placement is very popular in clinic at present. One reason may be that the percutaneous screws could reduce the trauma, blood loss and the risk of neurologic injury [23].

King et al. [24] first reported the facet screws for lumbosacral fixation in 1948 which have a high risk of failure. The technique was modified by Boucher in 1959 in using of more longer screws [25]. In 1984, the screw was first thought to be “strong screw” by being inserted

UPS Fixation versus BPS for MIS-TLIF

Table 3. Comparison of the VAS and ODI score between two groups

	VAS			ODI (%)		
	UPS	BPS	<i>P</i> value	UPS	BPS	<i>P</i> value
Preoperative	8.28±0.49	8.30±0.72	0.96	65.0±11.8	70.1±15.2	0.53
5 days	3.36±0.48	3.48±0.84	0.78	49.7±11.1	57.7±12.8	0.27
6 months	1.75±0.38	1.58±0.56	0.56	19.2±3.49	21.8±6.30	0.39
12 months	1.42±0.70	1.32±0.53	0.79	12.0±2.00	13.1±3.03	0.49

from the contralateral lamina into the ipsilateral facet joint [26]. However, this technique seems to be associated with a high incidence of neurologic injuries. In the Montesano's report [27], the incidence of transient neurologic deficits was 11%, and the data in another report [28] was 7%.

Unlike the open procedure, MIS-TLIF could significantly minimize tissue injury, cause less blood loss, raise the speed of recovery and decrease postoperative pain [29] which are more welcome by patients. Because the total facetectomy are needed in the surgery which results in instability, pedicle screw fixation is essential [23]. However, to date there were constant controversy over the unilateral or bilateral pedicle screw fixation. Schleicher et al. reported that bilateral pedicle screw augmentation offered significantly more stability than UPS in 8 fresh frozen human cadaveric study [30]. Slucky found it was not enough stiff if using unilateral pedicle screw construction alone [23]. A biomechanical experiment was also reported by Yucesoy that UPS was not fit for a double-level unilateral lesion [31]. However, Ferrara [32] et al. found there was no significant difference between UPS and BPS in a human cadavers study. Xue [33] reported a 80 patients study of UPS and BPS in TLIF which showed that there was no difference in postoperative outcomes while UPS group could significantly shorter operative time, less blood loss, and lower implant cost. Moreover, McAfee PC [34] reported that BPS fixation can not only lead to device-related osteoporosis but also the adjacent segment degeneration.

For the question of stability of UPS in TLIF, a series of studies were performed. In a biomechanics study Chen [17] found that UPS fixation was good enough to maintain the stability. Moreover, it was reported that UPS fixation had a lower risk of adjacent-segment degeneration [35] and reduced the stress shielding [16]. Using of UPS has been advocated in many reports [33, 36]. Conversely, Aoki et al. observed that the risk of cage migration is

much high in UPS group [35]. Slucky AV reported that UPS could cause significant offaxis rotational motions, which would hurt the stability and fusion [23].

Unlike open-TLIF, MISS-TLIF has its own features.

Bilateral pedicle screw augmentation means an additional incision, trauma and more cost. So whether there are significant difference of clinical outcomes between UPS and BPS is very important for the instrument choose. In the present study, we present a retrospective clinical study of 116 patients of at least 12 months follow-up. As far as we know, this is the biggest sample size retrospective study of MIS-TLIF on unilateral versus bilateral pedicle screw fixation. The results indicated that there was no statistically significant difference in clinical outcomes between two groups such as the pain and ODI. No significant difference was also found in fusion rate and total complication rate between the two groups. However, UPS involves shorter surgical time, less blood loss, X-ray exposure and decreasing cost. Thus, UPS might be more suitable for performing the two-level pedicle screw fixation and lumbar interbody fusion in MIS-TLIF.

The present study has several limitations. First, the study is a retrospective analysis which means a insufficiency for the conclusion. Second, the follow-up period is relatively shorter comparing with other studies for long-term outcomes. In addition, our study size was still smaller and we narrowed our criteria to two level disease. Last but not least, not all the patients were given the postoperative CT scans which may result in deviations in the fusion status. Multicenter studies with larger participants and long-term follow-up periods are necessary to further determine the benefits of unilateral versus bilateral fixation in MIS-TLIF.

Conclusion

In conclusion, in the patients with L4/L5 and L5/S1 level selected in the present study, unilateral instrumentation provides similar clinical and radiological outcomes to bilateral fixation while the cost and the perioperative data including blood loss, surgical time and X-ray exposure in UPS are better than that in BPS. Although additional larger and longer prospec-

tive analyses are needed to further confirm the outcomes of the UPS and BPS, the results in this study indicate that a clear advantage to the use of the UPS for performing two-level pedicle screw fixation after MIS-TLIF.

Acknowledgements

The reported work was supported in part by research grants from the president funding of General Hospital of Jinan Military Area Command of Chinese PLA (Grant# 2015ZX01 to KH). We would like to thank Shoufeng Jiao, Qunqun Shan, Quanyou Gao, Weigao Xue, Jian Qi, Zhaohu Mao, Shusen Tan, Baolong Wang and Zengkun Yang for their excellent technical assistance and helpful discussions. The research was approved by the Ethics Review Committee of General Hospital of Jinan Military Area Command of Chinese PLA, Jinan, Shandong, China (approval ID: 2014103) and written informed consent was obtained from all participating patients.

Disclosure of conflict of interest

None.

Address correspondence to: Tingbao Zhao, Department of Spinal Cord Injury, General Hospital of Jinan Military Area Command of Chinese PLA, Jinan, Shandong, P. R. China. E-mail: gan_7758525@163.com; Jixian Qian, Department of Orthopedic Surgery, Orthopedics Oncology Institute of Chinese PLA, Tangdu Hospital, Fourth Military Medical University, Xi'an, Shaanxi, P. R. China. E-mail: gan_7758525@sina.com

References

[1] Kuslich SD, Danielson G, Dowdle JD, Sherman J, Fredrickson B, Yuan H and Griffith SL. Four-year follow-up results of lumbar spine arthrodesis using the Bagby and Kuslich lumbar fusion cage. *Spine (Phila Pa 1976)* 2000; 25: 2656-2662.

[2] Tsantrizos A, Baramki HG, Zeidman S and Steffen T. Segmental stability and compressive strength of posterior lumbar interbody fusion implants. *Spine (Phila Pa 1976)* 2000; 25: 1899-1907.

[3] Brantigan JW, Steffee AD, Lewis ML, Quinn LM and Persenaire JM. Lumbar interbody fusion using the Brantigan I/F cage for posterior lumbar interbody fusion and the variable pedicle screw placement system: two-year results from

a Food and Drug Administration investigational device exemption clinical trial. *Spine (Phila Pa 1976)* 2000; 25: 1437-1446.

[4] Harms J and Rolinger H. [A one-stager procedure in operative treatment of spondylolistheses: dorsal traction-reposition and anterior fusion (author's transl)]. *Z Orthop Ihre Grenzgeb* 1982; 120: 343-347.

[5] Cole CD, McCall TD, Schmidt MH and Dailey AT. Comparison of low back fusion techniques: transforaminal lumbar interbody fusion (TLIF) or posterior lumbar interbody fusion (PLIF) approaches. *Curr Rev Musculoskelet Med* 2009; 2: 118-126.

[6] Whitecloud TS 3rd, Roesch WW and Ricciardi JE. Transforaminal interbody fusion versus anterior-posterior interbody fusion of the lumbar spine: a financial analysis. *J Spinal Disord* 2001; 14: 100-103.

[7] Park Y, Ha JW, Lee YT and Sung NY. The effect of a radiographic solid fusion on clinical outcomes after minimally invasive transforaminal lumbar interbody fusion. *Spine J* 2011; 11: 205-212.

[8] Park P and Foley KT. Minimally invasive transforaminal lumbar interbody fusion with reduction of spondylolisthesis: technique and outcomes after a minimum of 2 years' follow-up. *Neurosurg Focus* 2008; 25: E16.

[9] Karikari IO and Isaacs RE. Minimally invasive transforaminal lumbar interbody fusion: a review of techniques and outcomes. *Spine (Phila Pa 1976)* 2010; 35: S294-301.

[10] Aoki Y, Yamagata M, Ikeda Y, Nakajima F, Ohtori S, Nakagawa K, Nakajima A, Toyone T, Orita S and Takahashi K. A prospective randomized controlled study comparing transforaminal lumbar interbody fusion techniques for degenerative spondylolisthesis: unilateral pedicle screw and 1 cage versus bilateral pedicle screws and 2 cages. *J Neurosurg Spine* 2012; 17: 153-159.

[11] Duncan JW and Bailey RA. An analysis of fusion cage migration in unilateral and bilateral fixation with transforaminal lumbar interbody fusion. *Eur Spine J* 2013; 22: 439-445.

[12] Kawaguchi Y, Matsui H and Tsuji H. Back muscle injury after posterior lumbar spine surgery. A histologic and enzymatic analysis. *Spine (Phila Pa 1976)* 1996; 21: 941-944.

[13] Molinari RW, Saleh A, Molinari R Jr, Hermsmeyer J and Dettori JR. Unilateral versus Bilateral Instrumentation in Spinal Surgery: A Systematic Review. *Global Spine J* 2015; 5: 185-194.

[14] Awad BI, Lubelski D, Shin JH, Carmody MA, Hoh DJ, Mroz TE and Steinmetz MP. Bilateral Pedicle Screw Fixation versus Unilateral Pedicle and Contralateral Facet Screws for

UPS Fixation versus BPS for MIS-TLIF

- Minimally Invasive Transforaminal Lumbar Interbody Fusion: Clinical Outcomes and Cost Analysis. *Global Spine J* 2013; 3: 225-230.
- [15] Eliades P, Rahal JP, Herrick DB, Corliss BM, Riesenburger R, Hwang S and Kryzanski JT. Unilateral Pedicle Screw Fixation is Associated with Reduced Cost and Similar Outcomes in Selected Patients Undergoing Minimally Invasive Transforaminal Lumbar Interbody Fusion for L4-5 Degenerative Spondylolisthesis. *Cureus* 2015; 7: e249.
- [16] Goel VK, Lim TH, Gwon J, Chen JY, Winterbottom JM, Park JB, Weinstein JN and Ahn JY. Effects of rigidity of an internal fixation device. A comprehensive biomechanical investigation. *Spine (Phila Pa 1976)* 1991; 16: S155-161.
- [17] Chen SH, Lin SC, Tsai WC, Wang CW and Chao SH. Biomechanical comparison of unilateral and bilateral pedicle screws fixation for transforaminal lumbar interbody fusion after decompressive surgery—a finite element analysis. *BMC Musculoskelet Disord* 2012; 13: 72.
- [18] Hawker GA, Mian S, Kendzerska T and French M. Measures of adult pain: Visual Analog Scale for Pain (VAS Pain), Numeric Rating Scale for Pain (NRS Pain), McGill Pain Questionnaire (MPQ), Short-Form McGill Pain Questionnaire (SF-MPQ), Chronic Pain Grade Scale (CPGS), Short Form-36 Bodily Pain Scale (SF-36 BPS), and Measure of Intermittent and Constant Osteoarthritis Pain (ICOAP). *Arthritis Care Res (Hoboken)* 2011; 63 Suppl 11: S240-252.
- [19] Kong YS, Jang GU and Park S. The effects of prone bridge exercise on the Oswestry disability index and proprioception of patients with chronic low back pain. *J Phys Ther Sci* 2015; 27: 2749-2752.
- [20] Odom GL, Finney W and Woodhall B. Cervical disk lesions. *J Am Med Assoc* 1958; 166: 23-28.
- [21] Bridwell KH, Lenke LG, McEnery KW, Baldus C and Blanke K. Anterior fresh frozen structural allografts in the thoracic and lumbar spine. Do they work if combined with posterior fusion and instrumentation in adult patients with kyphosis or anterior column defects? *Spine (Phila Pa 1976)* 1995; 20: 1410-1418.
- [22] Lee KH, Yue WM, Yeo W, Soeharno H and Tan SB. Clinical and radiological outcomes of open versus minimally invasive transforaminal lumbar interbody fusion. *Eur Spine J* 2012; 21: 2265-2270.
- [23] Slucky AV, Brodke DS, Bachus KN, Droge JA and Braun JT. Less invasive posterior fixation method following transforaminal lumbar interbody fusion: a biomechanical analysis. *Spine J* 2006; 6: 78-85.
- [24] King D. Internal fixation for lumbosacral fusion. *J Bone Joint Surg Am* 1948; 30A: 560-565.
- [25] Boucher HH. A method of spinal fusion. *J Bone Joint Surg Br* 1959; 41-B: 248-259.
- [26] Magerl FP. Stabilization of the lower thoracic and lumbar spine with external skeletal fixation. *Clin Orthop Relat Res* 1984; 125-141.
- [27] Montesano PX, Magerl F, Jacobs RR, Jackson RP and Rauschnig W. Translaminar facet joint screws. *Orthopedics* 1988; 11: 1393-1397.
- [28] Jacobs RR, Montesano PX and Jackson RP. Enhancement of lumbar spine fusion by use of translaminar facet joint screws. *Spine (Phila Pa 1976)* 1989; 14: 12-15.
- [29] Peng CW, Yue WM, Poh SY, Yeo W and Tan SB. Clinical and radiological outcomes of minimally invasive versus open transforaminal lumbar interbody fusion. *Spine (Phila Pa 1976)* 2009; 34: 1385-1389.
- [30] Schleicher P, Beth P, Ottenbacher A, Pflugmacher R, Scholz M, Schnake KJ, Haas NP and Kandziora F. Biomechanical evaluation of different asymmetrical posterior stabilization methods for minimally invasive transforaminal lumbar interbody fusion. *J Neurosurg Spine* 2008; 9: 363-371.
- [31] Yucesoy K, Yuksel KZ, Baek S, Sonntag VK and Crawford NR. Biomechanics of unilateral compared with bilateral lumbar pedicle screw fixation for stabilization of unilateral vertebral disease. *J Neurosurg Spine* 2008; 8: 44-51.
- [32] Ferrara LA, Secor JL, Jin BH, Wakefield A, Inceoglu S and Benzel EC. A biomechanical comparison of facet screw fixation and pedicle screw fixation: effects of short-term and long-term repetitive cycling. *Spine (Phila Pa 1976)* 2003; 28: 1226-1234.
- [33] Xue H, Tu Y and Cai M. Comparison of unilateral versus bilateral instrumented transforaminal lumbar interbody fusion in degenerative lumbar diseases. *Spine J* 2012; 12: 209-215.
- [34] McAfee PC, Farey ID, Sutterlin CE, Gurr KR, Warden KE and Cunningham BW. The effect of spinal implant rigidity on vertebral bone density. A canine model. *Spine (Phila Pa 1976)* 1991; 16: S190-197.
- [35] Aoki Y, Yamagata M, Nakajima F, Ikeda Y, Shimizu K, Yoshihara M, Iwasaki J, Toyone T, Nakagawa K, Nakajima A, Takahashi K and Ohtori S. Examining risk factors for posterior migration of fusion cages following transforaminal lumbar interbody fusion: a possible limitation of unilateral pedicle screw fixation. *J Neurosurg Spine* 2010; 13: 381-387.
- [36] Korovessis P, Papazisis Z, Koureas G and Lambiris E. Rigid, semirigid versus dynamic instrumentation for degenerative lumbar spinal stenosis: a correlative radiological and clinical analysis of short-term results. *Spine (Phila Pa 1976)* 2004; 29: 735-742.