

Case Report

Surgical planning by three dimensional printing for huge chondrosarcoma of chest wall resection

Bo Yang^{1,2*}, Lin Zhou^{1*}, Jia-Kuan Chen¹, Jian Wang¹, Xiao-Ping Li², Tao Jiang¹

¹Department of Thoracic Surgery, Tangdu Hospital, Fourth Military Medical University, Xi'an 710038, PR China;

²Department of Thoracic Surgery, Tianjin First Central Hospital, Tianjin 300192, PR China. *Equal contributors.

Received January 21, 2016; Accepted May 12, 2016; Epub June 15, 2016; Published June 30, 2016

Abstract: Chondrosarcoma is a slow-growing malignant tumour characterised by the formation of cartilage. It seldom occurs in the ribs region. Most patients present with painful progressive swelling in the anterior chest wall arising from the costochondrosternal junction. CT scan with intravenous contrast is the investigation of choice. Herein, by using three dimensional (3D) printing model, we describe a rare case of a huge chondrosarcoma originating from the cartilaginous part of the ribs which has never been reported previously. The tumour was completely resected, and the patient's postoperative recovery was uneventful. We believe that 3D printing models are valuable tools for perioperative planning and might be more excellent than other imaging techniques in some cases.

Keywords: Three dimensional, tumor, thoracotomy

Introduction

Chondrosarcoma is a slow-growing malignant tumour characterised by the formation of cartilage, but not bone, by tumour cells [1]. Chondrosarcoma arises from embryogenic cartilaginous rests [2]. It represents 11% of all malignant primary bone tumours, and the pelvis, femur, tibia and humerus are most frequently involved [1]. It seldom occurs in the ribs region [3]. The clinical behaviour of chondrosarcoma is greatly variable and is linked to histologic grading. The majority of these tumors metastasizes rarely and has an excellent prognosis after adequate surgery. The following report describes a rare case of huge chondrosarcoma of chest wall resection. For surgical planning, we used 3D printing and a 3D thorax model.

Patients

A 78 years old woman was admitted to our hospital because of the intermittent chest discomfort, shortness of breath and deformity in the anterior chest wall for 3 years (**Figure 1A**). A computed tomography (CT) scan of the chest and abdomen revealed a huge mass $21.9 \times 17.9 \times 20.5$ cm, anomaly, in the anterior mediastinum with close relation to the ribs, pericar-

dium, heart, pulmonary vascular, and diaphragm (**Figure 1B** and **1C**). Osteolytic bone destruction was observed when the soft tissue mass invaded the adjacent sternum. To facilitate surgical planning, we used 3D printing. After converting the CT image into a 3D image, the model of thorax and mass was printed. Based on an examination of the printed thorax model, the resection of the huge mass was made (**Figure 2A** and **2B**). A biopsy was also performed, which showed chondrosarcoma (**Figure 2C**). The patient is still alive and is currently receiving follow-up.

Discussion

Chondrosarcoma accounts for about 30% of all skeletal cancers. The disease usually affects older people. Unlike most other forms of skeletal system cancer, it affects the axial skeleton more than the appendicular skeleton [4].

It was really rare that it was developed in the rib, as in this case. The tumor's close relation to cartilage, the irregular form, and the compression on the ribs, pericardium, heart, pulmonary vascular, and diaphragm could indicate that the tumor was very complicated. However, after examining the 3D printed model, we decided

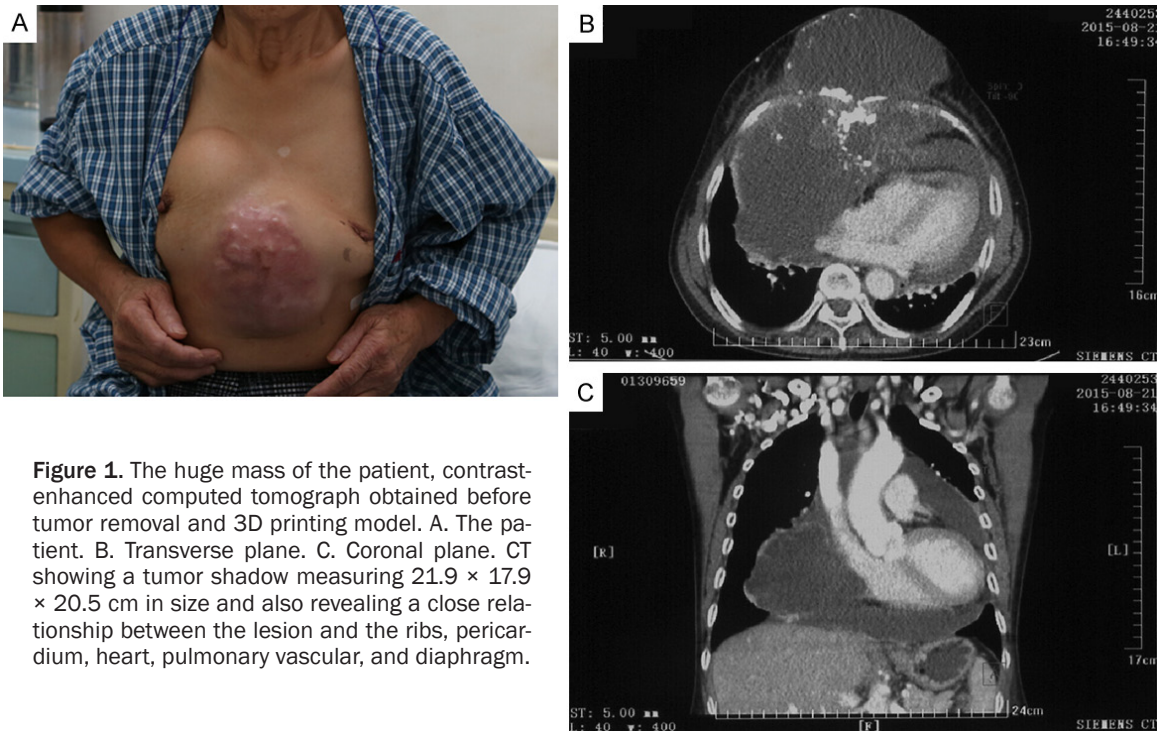


Figure 1. The huge mass of the patient, contrast-enhanced computed tomograph obtained before tumor removal and 3D printing model. A. The patient. B. Transverse plane. C. Coronal plane. CT showing a tumor shadow measuring 21.9 × 17.9 × 20.5 cm in size and also revealing a close relationship between the lesion and the ribs, pericardium, heart, pulmonary vascular, and diaphragm.

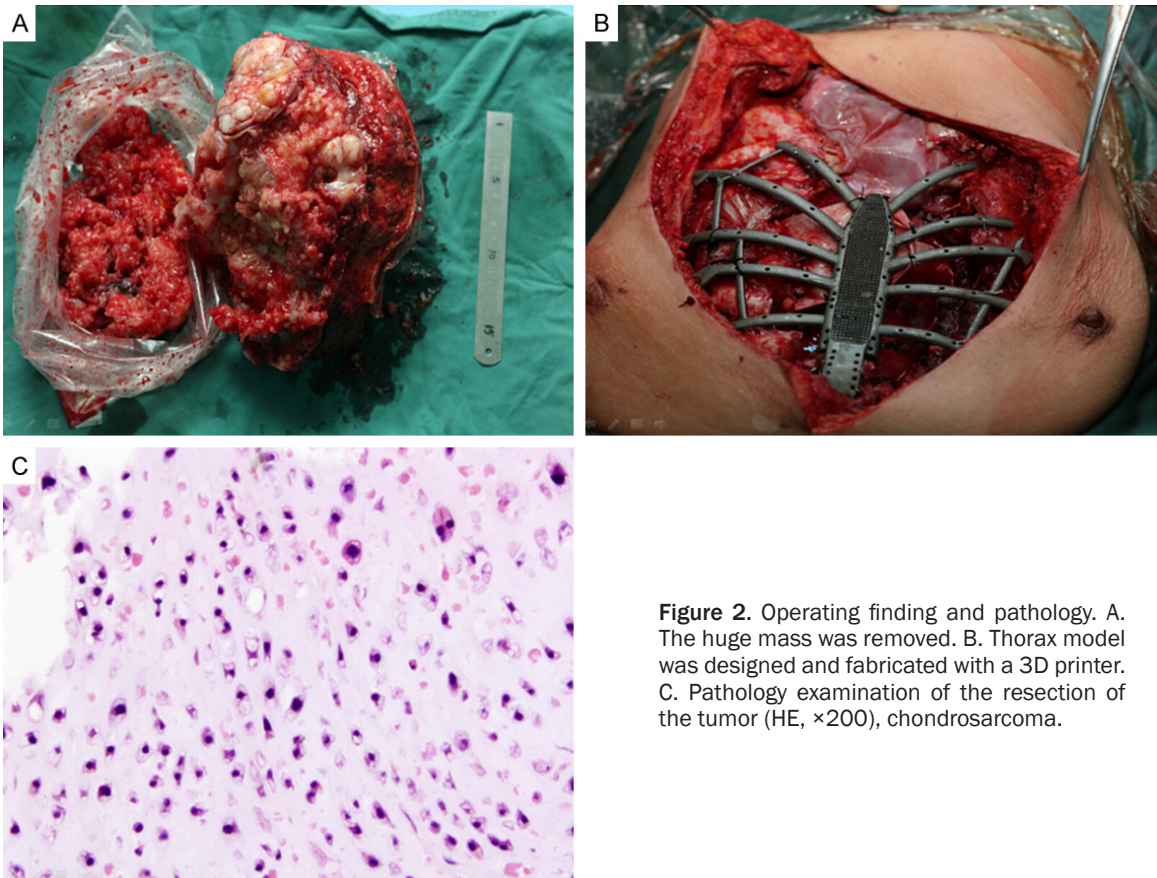


Figure 2. Operating finding and pathology. A. The huge mass was removed. B. Thorax model was designed and fabricated with a 3D printer. C. Pathology examination of the resection of the tumor (HE, ×200), chondrosarcoma.

that sternotomy approach and tumor removal was the more appropriate option. These mod-

els simplify surgical procedures, because they improve preoperative planning and knowledge

of the intraoperative dispositions of structures at risk and target tissues, and thus, might improve surgical outcomes.

We believe that this is the first case of huge chondrosarcoma removed by 3D printing. In our case, 3D printing was found to be helpful when deciding the approach used, although the CT data set used was obtained using a slice thickness of 5.0 mm, and thus, segmentation result was rather coarse as was the margin between the heart, diaphragm and tumor.

Because CT image is used for 3D printing model, it is not easy to get more exact anatomical information such as the tumor infiltration, or tumor stalk which is not conclusively shown on the CT by 3D printing model. In the present case, we could not get the information about exact origin of tumor by the 3D printing, nevertheless, the model was helpful for clearly identifying the tumor position and relationship with the great vessels. We believe that 3D printing models are valuable tools for perioperative planning and might be more excellent than other imaging techniques in some cases.

Acknowledgements

We thank other colleagues in the Thoracic Surgery Department and the operating room for their enthusiastic help, and the leaders of our hospital for their kind support.

Disclosure of conflict of interest

None.

Address correspondence to: Tao Jiang, Department of Thoracic Surgery, Tangdu Hospital, Fourth Military Medical University, No. 569 Xinsi Road, Xi'an 710038, PR China. Tel: +862984777556; Fax: +862984777556; E-mail: jiangtaochest@163.com

References

- [1] Giorgione C, Passali FM, Varakliotis T, Sibilia M, Ottaviani F. Temporo-mandibular joint chondrosarcoma: Case report and review of the literature. *Acta Otorhinolaryngol Ital* 2015; 35: 208-211.
- [2] Olivera RC, Marques KD, Mendoca AR, Mendonça EF, Silva MR, Batista AC, Ribeiro-Rotta RF. Chondrosarcoma of the temporo-mandibular joint: a case report in child. *J Orofac Pain* 2009; 23: 275-281.
- [3] Lin JR, Zhang WM, Wang ZC. Primary malignant bone neoplasm: a case report of dedifferentiated chondrosarcoma in the riband review of the literature. *Chin J Cancer* 2010; 29: 964-968.
- [4] Singhal A, Mahajan C, Hadi R, Awasthi NP. Chondrosarcoma of chest wall metastasising to the larynx: Case report and review of literature. *J Cancer Res Ther* 2015; 11: 658.