

## Original Article

# Bedside prediction of peripherally inserted central catheter length: based on patient height combined with surface landmark

Xiaoxia Zhang<sup>1</sup>, Nengwen Ke<sup>2</sup>, Chang Liu<sup>3</sup>, Xiuying Hu<sup>4</sup>, Huaqin Yu<sup>1</sup>, Yi Jia<sup>1</sup>

<sup>1</sup>Tumor Center, West China Hospital, Sichuan University, Chengdu 610041, Sichuan Province, P. R. China; Departments of <sup>2</sup>Pancreatic Surgery, <sup>3</sup>Radiology, West China Hospital, Sichuan University, Chengdu 610041, Sichuan Province, P. R. China; <sup>4</sup>West China Nursing School, Sichuan University, Chengdu 610041, Sichuan Province, P. R. China

Received December 28, 2015; Accepted May 24, 2016; Epub August 15, 2016; Published August 30, 2016

**Abstract:** Background and objective: The placement of a central venous catheter in the superior vena cava and cavoatrial junction helps reduce catheter tip-related complications. While several approaches have been used to estimate the optimum length of centrally inserted central catheter, predicting the length of a peripherally inserted central catheter (PICC) for insertion into the superior vena cava and cavoatrial junction still remains a challenge and needs an improvement. This study explored the viability of calculating, at bedside, the length of a PICC according to the patient height and using the clavicular notch as a surface landmark. Methods: Adult cancer patients were divided into 3 groups (< 155, 155-170, and > 170 cm) based on height. At bedside, the catheter was placed blindly, to a depth equal to the distance between the insertion site and the ipsilateral clavicular notch plus 4, 5, or 6 cm (right arm) or 7, 8, or 9 cm (left arm) based on patient height group (< 155, 155-170, and > 170 cm, respectively). Central vein insertion was defined as placement of the catheter tip from 3 cm above to 4 cm below the tracheal carina, measured vertically. Results: Of the 247 catheters, 73, 142, and 32 were located above, below, and at the level of the tracheal carina, respectively. The distance between the catheter tip and tracheal carina was  $1.68 \pm 1.25$  cm (95% CI: 1.52-1.84), and 93.12% (230/247) of the catheter tips located in the desired position. Conclusion: Combination of the height and surface land mark can be used to predict catheter length and improve the accuracy of the catheter tip. The catheter tip can be reliably placed near the tracheal carina level when a catheter is inserted at an arm using patient height and the clavicular notch as a surface landmark.

**Keywords:** Tracheal carina, central vein, clavicular notch, patient height, peripherally inserted central catheter

## Introduction

The peripherally inserted central catheter (PICC) is important for cancer patients in a variety of disease states and for different purposes. Routinely, the proper length of a PICC is estimated by measuring the catheter from the insertion site to the sternal notch, and then down to the third intercostal space. However, compared with other venous access devices, this method is more likely to generate malposition of PICC [1]. For example, when PICCs were placed at bedside blindly, more than 1/3 of the catheter tips were located in a suboptimal position, that is, the innominate vein and right atrium [2, 3]. Misplaced catheters may lead to their malfunction and increase rates of compli-

cations such as thrombus, vascular perforation, arrhythmia, and cardiac tamponade [4].

There are technologies available for the accurate placement of catheter tips. Examples of these include intracavitary electrocardiography-guided catheterization, Sherlock tip location systems, and electromagnetic detection systems [5-7]. However, because of the additional equipment required, the complexities of the procedures, and high costs, they are not used routinely. Thus, non-image-guided catheterization is still common in many medical centers in various countries.

While physical parameters, such as patient height, bone and soft tissue landmarks, have

been used for estimating the optimal centrally inserted central catheter length [4, 7-11], the prediction of the PICC length has not been studied adequately. There have been reports that the proper PICC length correlates with or can be derived from the patient height [12-14]. Two studies have developed equations for estimating PICC length on this basis [12, 14]. Although these conclusions may provide a reference for clinical practice, application is limited—they all relied on insertion at the cubital fossa, which is not appropriate for patients with poor veins at the cubital fossa, and are not relevant for catheterization in the forearm or upper arm.

We hypothesized that the insertion site, clavicular notch, and tracheal carina could be used to predict the PICC length. Furthermore, that the distance between the clavicular notch and tracheal carina varies according to patient height. And finally, that a reasonable combination of the insertion site, clavicular notch, and distance between the clavicular notch and tracheal carina could simply predict the PICC length and improve the accuracy of catheter tip during blind catheterization.

Therefore, to simplify PICC placement and ensure a more accurate central vein catheter tip position, we developed a method to estimate the appropriate PICC length during blind catheterization. This method is based on patient height and uses the clavicular notch as a surface landmark. The present study assessed the efficacy of this new method.

### Materials and methods

#### *Design and setting*

This was a prospective study conducted at West China Hospital, a 4500-bed university-affiliated medical center in China.

#### *Data acquisition*

The Institutional Review Board of the hospital approved this study, and signed informed consent was obtained from all the patients. We prospectively enrolled 300 consecutive adult cancer patients who had been hospitalized in West China Hospital for central venous catheterizations. All catheterizations were performed for clinical indications and adhered to standard

procedures. Patient information was anonymized and de-identified at the time of analysis. All catheterizations were conducted between December 2014 and April 2015 (a 5-month period).

Those catheters without tip pointing toward heart, e.g. coiling or looping within veins, or malpositioning in the axillary, subclavicular, or internal jugular veins, were excluded from the analysis. Data extracted for analysis included the patients' age, gender, and height; and catheter type, insertion arm, insertion site, vein, experience of the PICC nurses, and the catheter tip positions.

#### *Catheterization*

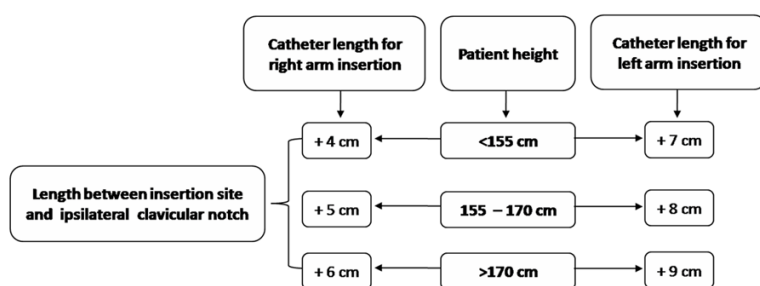
In this study, all catheters were scheduled to be used to administer fluids, such as chemotherapy, parenteral nutrition, antibiotics, dehydrants, or electrolytes. Two types of single lumen catheters were used: BD First PICC Catheter (Becton Dickinson Infusion Therapy Systems; Sandy, UT, USA) or Groshong (Bard Access Systems; Salt Lake City, UT, USA). The catheters were placed at bedside blindly, either by a senior PICC nurse with 7-year or by a junior PICC nurse with 2-year insertion experience. The choice of insertion arm, insertion site, and vein was based on patient condition, for the benefit of patients.

The patients were divided into 3 groups according to height: < 155 cm, 155-170 cm, or > 170 cm [15]. During the procedure, patients were lying supine, with the insertion arm abducted at 90°. The catheter was placed at a depth derived from adding the length between the insertion site and the ipsilateral clavicular notch plus an additional length of 4, 5, or 6 cm for right arm insertion or an additional length of 7, 8, or 9 cm for left arm insertion based on the patient height group (< 155 cm, 155-170 cm, or > 170 cm, respectively; **Figure 1**). Thereafter, a standard posteroanterior chest-X ray image was performed for catheter tip identification in all patients.

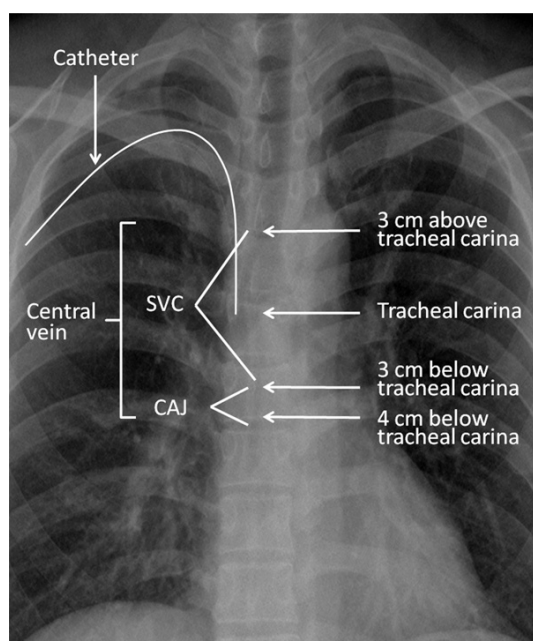
#### *Target location for catheter tip insertion and criteria for catheter tip assessment*

The target location for catheter tip insertion was determined based on guidelines and literature reviews [3, 9, 16, 17], and our own clinical

## Prediction of length of peripherally inserted central catheter



**Figure 1.** Protocol of catheter length measurement. Patients were divided into three groups based on their heights (< 155 cm, between 155-170 cm, and > 170 cm). The catheter was placed blindly, to a depth equal to the distance between the insertion site and the ipsilateral clavicular notch plus 4, 5, or 6 cm (right arm) or 7, 8, or 9 cm (left arm) based on patient height groups.



**Figure 2.** Target location for catheter tip insertion on the standard posteroanterior chest-X ray image. The central vein comprises the SVC and CAJ. The SVC is 6 cm and the CAJ is 1 cm in length. The catheter tip located in the region 3 cm above and 4 cm below the tracheal carina was considered to be in the central vein. SVC, superior vena cava; CAJ, cavoatrial junction.

experience. The tracheal carina was adopted as the landmark for assessing the catheter tip position. With regard to the tracheal carina, the target location-central vein, which comprises the superior vena cava and cavoatrial junction, was defined as a region 3 cm above and 4 cm below the tracheal carina (**Figure 2**). The catheter tip located within this region was considered to be in the central vein, whereas the cath-

eter tip located outside this region was considered to be in the non-central vein. A catheter tip located at the level of the tracheal carina was recorded as 0, and a catheter tip within 1 cm above or below the tracheal carina was regarded as being in the optimal position. The catheter tip on the post-procedural chest-X ray image was re-interpreted and the vertical length between the catheter tip and the tracheal carina was measured by an appointed radiol-

ogist with 15-year of radiography-reading experience, using a picture archiving and communication system.

### Statistical methods

Categorical variables were analyzed by count and percentage. The vertical length between the catheter tip and tracheal carina was expressed as the mean  $\pm$  standard deviation (SD) and a 95% confidence interval (CI). Analysis of variance (ANOVA) and *t*-tests were used to compare differences in the distances between the catheter tip and tracheal carina among groups. A *P*-value < 0.05 was considered statistically significant. Statistical analyses were performed using the statistical package SPSS version 19.0 (SPSS, Chicago, IL, USA).

### Results

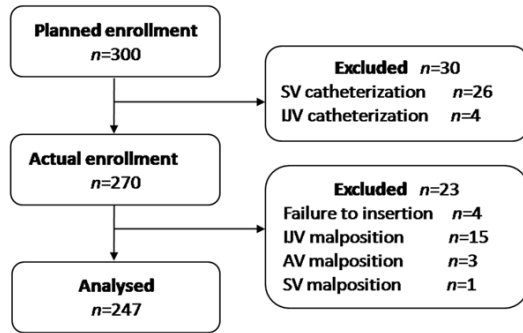
#### Enrollment and analysis

Three hundred patients were enrolled in the study. Thirty patients accepted subclavicular and internal jugular catheterization, and 270 patients accepted PICCs, of whom 247 were analyzed (**Figure 3**). All 247 PICCs were advanced the predicted distance into veins without any coiling or looping. In addition, all the catheter tips were pointed toward the heart, and the distances between the catheter tips and tracheal carinas could be measured.

#### Characteristics of the patients and catheters

The characteristics of the patients and catheters were detailed in **Table 1**. The mean age of

## Prediction of length of peripherally inserted central catheter



**Figure 3.** Study flow chart. The number of patients included/excluded after each indicated procedure is shown. SV, subclavicular vein; IJV, internal jugular vein; AV, axillary vein.

**Table 1.** Characteristics of the patients and catheters

Patient characteristics		n (%)
Total subjects, n		247
Age, y	< 40	37 (14.98)
	40-60	166 (67.21)
	> 60	44 (17.81)
Gender	Male	129 (52.23)
	Female	118 (47.77)
Height, cm	< 155	31 (12.55)
	155-170	193 (78.14)
	> 170	23 (9.31)
Insertion arm	Right	156 (63.16)
	Left	91 (36.84)
Catheter type	BD*	161 (65.18)
	Groshong	86 (34.82)
Vein	Basilic	204 (82.59)
	Cephalic	43 (17.41)
Insertion site	Forearm	51 (20.65)
	Cubital fossa	127 (51.42)
	Upper arm	69 (27.93)
Nurse	Senior	173 (70.04)
	Junior	74 (29.96)
Catheter tip position	Innominate vein	8 (3.24)
	Right atrium	9 (3.64)
	Central vein	230 (93.12)

\*BD First PICC Catheter.

the patients was  $49.6 \pm 10.6$  years (range, 19-76 years), and their mean height was  $162.0 \pm 6.9$  cm (range, 143-180 cm). The rate of the catheter tips located in the central vein was 93.12% (230/247).

### Distances between catheter tip and carina among groups

The mean length measured between the catheter tip and tracheal carina, and the comparison of lengths among groups is shown in **Table 2**. Of the 247 catheters, 73 were located above, 142 below, and 32 at the level of the tracheal carina (**Figure 4**). The catheter tip located highest was 4.35 cm above the tracheal carina, and lowest was 4.90 cm below the tracheal carina. The mean distance between the catheter tip and tracheal carina was  $1.68 \pm 1.25$  cm (95% CI: 1.52-1.84). The percentage of catheter tips located in the optimal position (i.e., 1 cm above or 1 cm below the tracheal carina) was 36.44% (90/247). The distances from catheter tips to tracheal carinas were statistically similar among all groups when stratified by age, gender, height, catheter type, insertion arm, insertion site, vein, or the experience of the PICC nurses.

### Discussion

This study demonstrates that the combination of the height and clavicular notch can be used to predict PICC length and improve the accuracy of the catheter tip.

To reduce or prevent the occurrence of potential catheter tip-related complications, the PICC tip should lie in the superior vena cava and outside the pericardial sac. It was reported that the combined overall accuracy for initial placement of PICC tips in the lower third of the superior vena cava or cavoatrial junction was only 45.9% (478/1042, ranged from 39% to 75%) [18]. Moreover, the rate was 33.7% (68/202) in adults and 34.3% (289/843) in children when the PICC tips were located in the innominate vein and right atrium [2, 3]. All these data demonstrates that the blind PICC placement into the central vein remains a challenge and needs an improvement.

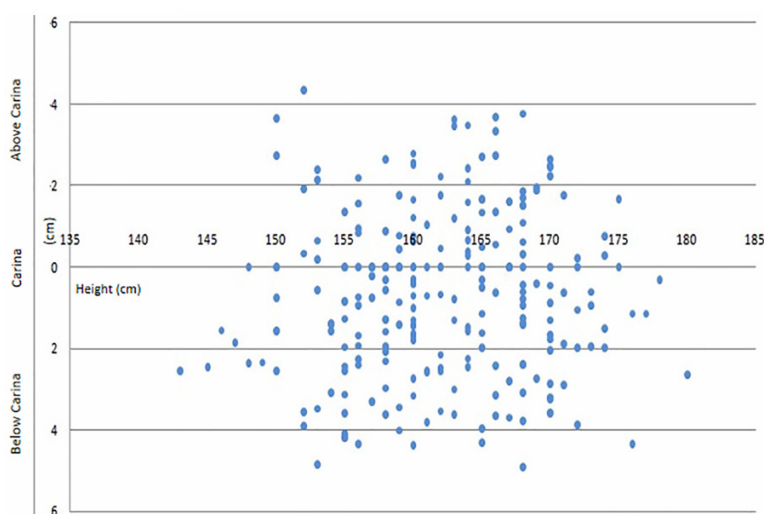
Different calculations and approaches that include patient height, landmarks, or both have been used for estimating PICC length in blind placement [12-14], but none has been generally accepted. Of these, two approaches achieved a central vein accuracy rate of 96.3% (129/134) and 65.7% (111/169), respectively [12, 13]. However, reliance on cubital fossa-

## Prediction of length of peripherally inserted central catheter

**Table 2.** Distance between catheter tip and tracheal carina among groups

		Distance*, cm	95% CI	t/F	P
All catheter tips		1.68 ± 1.25	1.52-1.84		
Age, y	< 40	1.77 ± 1.41	1.32-2.22	1.299	0.275
	40-60	1.73 ± 1.26	1.54-1.93		
	> 60	1.41 ± 1.05	1.10-1.72		
Gender	Male	1.59 ± 1.19	1.39-1.80	-1.173	0.242
	Female	1.78 ± 1.31	1.54-2.02		
Height, cm	< 155	1.99 ± 1.32	1.52-2.45	1.333	0.266
	155-170	1.66 ± 1.25	1.48-1.83		
	> 170	1.46 ± 1.16	0.98-1.93		
Insertion arm	Right	1.62 ± 1.26	1.42-1.81	-1.060	0.290
	Left	1.79 ± 1.24	1.54-2.05		
Catheter type	BD#	1.72 ± 1.24	1.53-1.91	0.669	0.504
	Groshong	1.61 ± 1.28	1.34-1.88		
Vein	Basilic	1.65 ± 1.25	1.48-1.82	-0.818	0.414
	Cephalic	1.82 ± 1.25	1.45-2.20		
Insertion site	Forearm	1.69 ± 1.17	1.37-2.01	0.051	0.951
	Cubital fossa	1.70 ± 1.24	1.48-1.91		
	Upper arm	1.64 ± 1.36	1.32-1.96		
Nurse	Senior	1.65 ± 1.24	1.46-1.83	-0.664	0.507
	Junior	1.76 ± 1.29	1.47-2.06		

\*Distance between catheter tip and tracheal carina. #BD First PICC Catheter.



**Figure 4.** Scatter graph of PICC tip positions. Each point represents an individual catheter tip. The abscissa represents patient height, the ordinate represents the catheter tip position, and 0 represents the level of the tracheal carina. The catheter tip located highest is 4.35 cm above the tracheal carina, and lowest is 4.90 cm below the tracheal carina. The mean length between the catheter tip and tracheal carina is 1.68 ± 1.25 cm (95% CI: 1.52-1.84). The rate of central vein accuracy is 93.12% (230/247).

sited insertion and the low rate of central vein accuracy has limited the clinical application of

these approaches. Catheters that are inserted too shallow or too deep, primarily due to misjudgment or miscalculation of the landmarks, are then located either in the innominate vein or the right atrium, respectively [12]. Therefore, a proper method to predict the PICC length, in our opinion, should meet the following requirements: a simple formula, a readily palpated landmark, and with consideration of the particular insertion site.

The results of the present study showed that our method had a central vein accuracy rate of 93.12% (230/247) based on 247 catheters, and the mean distance between the catheter tip and tracheal carina was 1.68 ± 1.25 cm (95% CI: 1.52-1.84). We acknowledged that the accuracy rate of the method demonstrated herein was slightly inferior to the best (to our knowledge) central vein accuracy rate of 96.3% reported previously [12]. However, our method is free of the limitations imposed by cubital fossa-sited insertion, and thus may benefit clinicians and patients with respect to the selection of insertion site.

Moreover, we believe that our method can be used reliably. It has been reported that rates of central vein accuracy and adverse complications are most influenced by the catheterization experience of the medical staff, the height of the patient, and the arm of insertion [3, 13, 19]. However, our present study showed that the calculated length between the catheter tip and

tracheal carina, by our method, were not influenced by the experience of the PICC nurses,



patient height, or insertion arm, nor by patient age, gender, insertion site, vein, or catheter type.

Because the distance between the right clavicular notch and tracheal carina is  $6.1 \pm 1.5$  cm on chest CT scan [16], we included an additional 5 cm at right arm insertion for patients of moderate height (155-170 cm), to prevent the catheter tip from migrating into the right atrium. For patients who were shorter (< 155 cm) or taller (> 170 cm), we subtracted 1 cm or added 1 cm, respectively, from the 5 cm. The left innominate vein is 3-5 cm longer than the right innominate vein [3], since it transverses through the mediastinum. The previous study suggested that left catheterization was 3-4 cm longer than right catheterization, both in the peripherally inserted and centrally inserted central catheter [8, 12]. In the present study we made left arm catheterizations 3 cm longer than right arm catheterizations, and hoped to place the catheter tip slightly below the tracheal carina, to ensure that the catheter was parallel to the longitudinal axis of the superior vena cava.

Our method has several advantages for determining the proper PICC length. Firstly, it is simple and reliable, and its accuracy was not affected by patient characteristics or the experiences of the PICC nurses. Secondly, only one surface landmark is used (i.e., the clavicular notch), which can be easily palpated in all patients, even those who are obese. And thirdly, the method broadens the choice of insertion sites, as it can be used not only for cubital fossa-sited insertion, but also in forearm- and upper arm-insertion.

Although abovementioned advantages, our method is limited in that it can be used only in adult patients. Secondly, most enrolled patients were of moderate height, and including shorter and taller patients in a future study will corroborate our findings and expand their applications. Finally, our technique does not include a calculation of the angle formed between the catheter and the superior vena cava.

### Conclusion

The insertion site, clavicular notch, and tracheal carina are three pivotal factors that should be used to predict the proper length of a PICC,

which will improve the accuracy of catheter tip position during blind catheterization. The catheter tip can be reliably placed near the tracheal carina level when a catheter is inserted at the arm, based on patient height and using the clavicular notch as a surface landmark. Because this method can be readily applied to patients with different medical conditions, it could have broad clinical application and expand the benefit of PICC to a larger group of patients.

### Disclosure of conflict of interest

None.

**Address correspondence to:** Chang Liu, Department of Radiology, West China Hospital, Sichuan University, # 37 Guo Xue Xiang, Chengdu 610041, Sichuan Province, P. R. China. Tel: +8628 85423360; Fax: +8628 85423360; E-mail: liuchang@scu.edu.cn; Xiuying Hu, West China Nursing School, Sichuan University, # 37 Guo Xue Xiang, Chengdu 610041, Sichuan Province, P. R. China. Tel: +8628 85422042; Fax: +8628 85422042; E-mail: xiuying.hu@163.com

### References

- [1] DeChicco R, Seidner DL, Brun C, Steiger E, Stafford J and Lopez R. Tip position of long-term central venous access devices used for parenteral nutrition. *JPEN J Parenter Enteral Nutr* 2007; 31: 382-387.
- [2] Fricke BL, Racadio JM, Duckworth T, Donnelly LF, Tamer RM and Johnson ND. Placement of peripherally inserted central catheters without fluoroscopy in children: initial catheter tip position. *Radiology* 2005; 234: 887-892.
- [3] Venkatesan T, Sen N, Korula PJ, Surendrababu NR, Raj JP, John P and Christopher S. Blind placements of peripherally inserted antecubital central catheters: initial catheter tip position in relation to carina. *Br J Anaesth* 2007; 98: 83-88.
- [4] Kim MC, Kim KS, Choi YK, Kim DS, Kwon MI, Sung JK, Moon JY and Kang JM. An estimation of right- and left-sided central venous catheter insertion depth using measurement of surface landmarks along the course of central veins. *Anesth Analg* 2011; 112: 1371-1374.
- [5] Baldinelli F, Capozzoli G, Pedrazzoli R and Marzano N. Evaluation of the correct position of peripherally inserted central catheters: anatomical landmark vs. electrocardiographic technique. *J Vasc Access* 2015; 16: 394-398.
- [6] Leikes V, Kumar A, Shukla PA, Contractor S and Rutan T. Analysis of the Sherlock II tip loca-

## Prediction of length of peripherally inserted central catheter

- tion system for inserting peripherally inserted central venous catheters. *Clin Imaging* 2013; 37: 917-921.
- [7] Svendsen MC, Birrer D, Jansen B, Teague SD, Combs B, Schears GJ and Kassab GS. Accurate nonfluoroscopic guidance and tip location of peripherally inserted central catheters using a conductance guidewire system. *J Vasc Surg Venous Lymphat Disord* 2013; 1: 202-208, e201.
  - [8] Kim WY, Lee CW, Sohn CH, Seo DW, Yoon JC, Koh JW, Kim W, Lim KS, Hong SB, Lim CM and Koh Y. Optimal insertion depth of central venous catheters—is a formula required? A prospective cohort study. *Injury* 2012; 43: 38-41.
  - [9] Lee JB and Lee YM. Pre-measured length using landmarks on posteroanterior chest radiographs for placement of the tip of a central venous catheter in the superior vena cava. *J Int Med Res* 2010; 38: 134-141.
  - [10] Ezri T, Weisenberg M, Sessler DI, Berkenstadt H, Elias S, Szmuk P, Serour F and Evron S. Correct depth of insertion of right internal jugular central venous catheters based on external landmarks: avoiding the right atrium. *J Cardiothorac Vasc Anesth* 2007; 21: 497-501.
  - [11] Shin HJ, Kim BG, Na HS, Oh AY, Park HP and Jeon YT. Estimation of catheter insertion depth during ultrasound-guided subclavian venous catheterization. *J Anesth* 2015; 29: 724-727.
  - [12] Lum P. A new formula-based measurement guide for optimal positioning of central venous catheters. *Journal of the Association for Vascular Access* 2004; 9: 80-85.
  - [13] Joshi S, Kulkarni A and Bhargava AK. Evaluation of length of central venous catheter inserted via cubital route in Indian patients. *Indian J Crit Care Med* 2010; 14: 180-184.
  - [14] Jeon EY, Koh SH, Lee IJ, Ha HI and Park BJ. Useful equation for proper estimate of left side peripherally inserted central venous catheter length in relation to the height. *J Vasc Access* 2015; 16: 42-46.
  - [15] General Administration of Sport of China: National Physique Monitoring Bulletin of 2010. 2011. Available: <http://www.sport.gov.cn/n16/n1077/n297454/2052709.html>.
  - [16] Pan KH, Gu DY, Zhou JC and Zhao HC. The carina is approximately 1-2 cm above the pericardial reflection among Chinese patients. *J Thorac Dis* 2014; 6: 845-849.
  - [17] Ridge CA, Litmanovich D, Molinari F, Bankier AA and Eisenberg RL. Radiographic evaluation of central venous catheter position: anatomic correlation using gated coronary computed tomographic angiography. *J Thorac Imaging* 2013; 28: 129-133.
  - [18] Hostetter R, Nakasawa N, Tompkins K and Hill B. Precision in central venous catheter tip placement: a review of the literature. *Journal of the Association for Vascular Access* 2010; 15: 112-125.
  - [19] Alexandrou E, Spencer TR, Frost SA, Mifflin N, Davidson PM and Hillman KM. Central venous catheter placement by advanced practice nurses demonstrates low procedural complication and infection rates—a report from 13 years of service. *Crit Care Med* 2014; 42: 536-543.