

Original Article

Side-to-end hypoglossal-facial nerve anastomosis for facial paralysis: a meta-analysis

Dong Wang¹, Hongjuan Deng¹, Hongquan Xiong¹, Siguo Qi¹, Wenlong Luo², Dan Xu¹, Pengju Yu³, Wendong Huang³

¹Department of Otolaryngology-Head and Neck Surgery, The Central Hospital of Dazhou, Dazhou 635000, Sicuan, China; ²Department of Otolaryngology-Head and Neck Surgery, The Second Affiliated Hospital of Chongqing Medical University, Chongqing 400010, China; ³Department of Otolaryngology-Head and Neck Surgery, The Sanming First Hospital, SanMing 365000, Fujian, China

Received February 5, 2016; Accepted July 11, 2016; Epub August 15, 2016; Published August 30, 2016

Abstract: To assess the efficacy and safety of side-to-end Hypoglossal-facial nerve anastomosis (HFA) in the treatment of facial paralysis. Methods: We searched MEDLINE, EMBASE, www.clinicaltrials.gov, the Cochrane Controlled Clinical Trials Register Database, Biosis Preview, and the Chinese Biomedical Database. Studies involving patients with facial paralysis undergoing scheduled side-to-end HFA used the House-Brackmann (HB) grading system or similar methods to evaluate facial nerve function postoperation. The influence of the severity of the lesion and duration of facial palsy on recovery rate, and adverse effects were analyzed. Meta-Analyst software was used for statistical analysis. Results: 10 trials of 87 patients were eligible for analysis. Good recovery rate of side-to-end HFA is 75.4% (95% CI: 56.6%-87.8%), with no significant heterogeneity ($P = 0.033$, $I^2 = 33.4\%$). The difference between different intervals in the "good recovery rate" is not significant. And different levels of severity of facial nerve dysfunction have no significant influence on the recovery rate. There were no significant adverse effects after side-to-end HFA. Conclusions: Hypoglossal-facial nerve side-to-end anastomosis is an effective and reliable technique with consistent and satisfying results. Neither the severity of the lesion nor duration of facial palsy has an adverse effect on prognosis. Major complications caused by the complete transection of the hypoglossal nerve can be avoided with the side-to-end technique.

Keywords: HFA, facial paralysis, transection meta-analysis

Introduction

Peripheral facial nerve injury is a common problem, with causes of facial nerve damage including malignant parotid tumor surgery, trauma, petrous bone surgery and so on. In addition to its serious functional deficits, it can cause psychological trauma owing to facial asymmetry which has been a focus and a difficult problem in the medical field. Various types of procedures have been proposed for established facial paralysis, including nerve anastomosis, free muscle transplantation and lengthening temporalis myoplasty [1-3]. In spite of the striking development in microsurgical techniques, rehabilitation of facial nerve remains challenging.

Theoretically, primary end-to-end facial nerve repair with or without an interposition graft offers the best result for recovery, both in in-

tracranial and extracranial facial nerve transections [4]. Nevertheless, when the proximal stump of the facial nerve at the brainstem is not available, because of destruction of the intrapontine facial nucleus and when the facial nerve is anatomically preserved but the patient has inadequate recovery of facial paresis due to internal axonotmesis and subsequent suboptimal regeneration [5]. In this situation, hetero-nervous anastomosis procedures are considered.

Direct end-to-end neurorrhaphy between the hypoglossal and facial nerves is a widely accepted technique that yields good results in the rehabilitation of facial function since 1903, Körte performed [6]. However, this procedure demands a total section of the hypoglossal nerve and results in an inevitable loss of hemiglossal function associated with speech, mastication and/or swallowing difficulties that

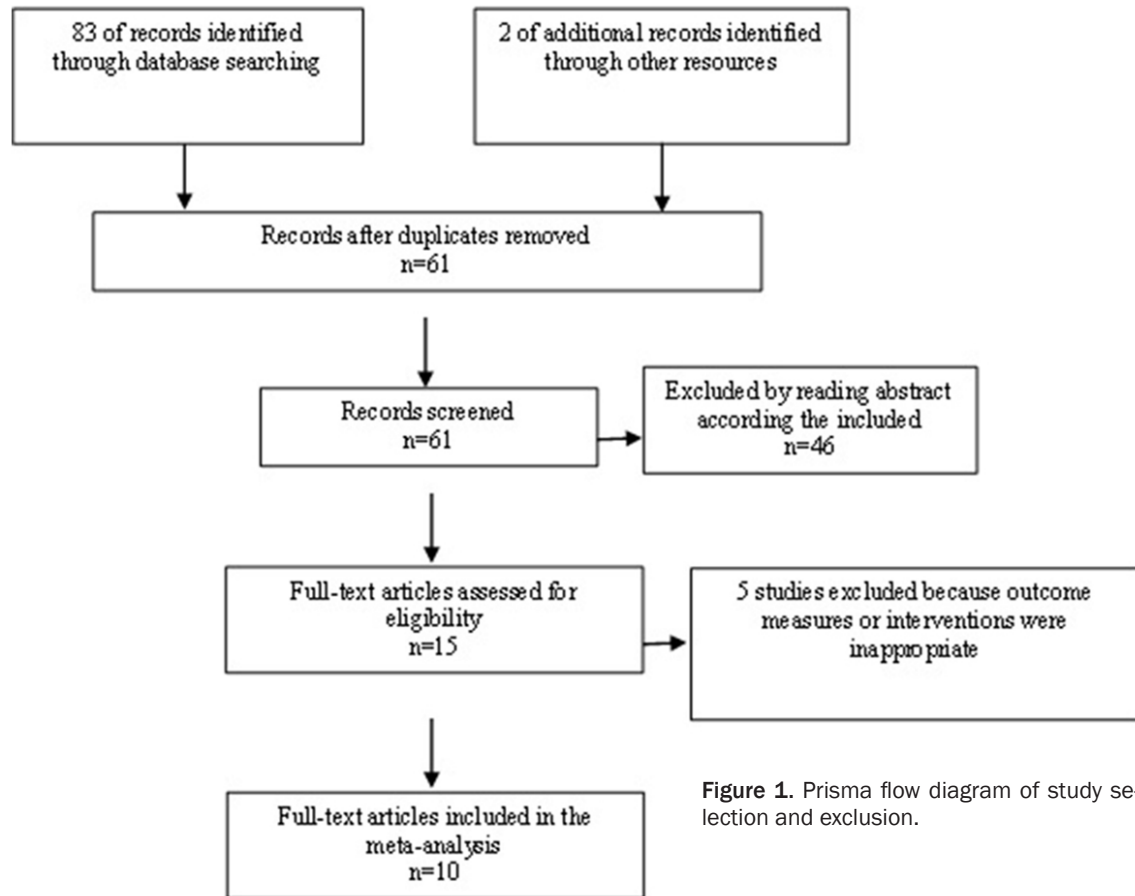


Figure 1. Prisma flow diagram of study selection and exclusion.

interfere with daily life [7, 8]. To prevent side effects of Hypoglossal-facial anastomosis (HFA), the procedure was modified. In 1991, May et al. reported favorable results when proposing the partial end-to-end anastomosis with interpositional jump grafting ("jump" procedure) [9], which requiring two anastomosis sites may influence the reinnervation quality and time. Theoretically, direct anastomosis has the advantage over interposition grafting of regaining more myelinated axons across the reconstruction site, which in turn, has the advantage of improved mimetic activity. All these issues can be summed up in one big dilemma.

In 1999, Atlas and Lowinger [10] described hemihypoglosso-facial anastomosis, and improved by Roland et al. [11]. This technique involved transmastoid rerouting of the long facial nerve and connection to a half-cut hypoglossal nerve, which was termed side-to-end anastomosis and gave a better preservation of glossal function and restoration official movement.

To date, only limited series of patients undergoing this procedure have been published. This meta-analysis aims to examine as many cases as possible from the available literature to determine the success rates of side-to-end hypoglossal-facial nerve anastomosis, the influence on the success rate induced by the timing of surgery and preoperative facial nerve dysfunction and the incidence of side effects.

Materials and methods

Literature search

We attempted to identify all relevant trials regardless of publication status (published, unpublished, in press, and in progress). The following databases were searched: MEDLINE (PubMed, 1966-2015), EMBASE (1974-2015), www.clinicaltrials.gov, the Cochrane Controlled Clinical Trials Register Database, Biosis Preview, Chinese Biomedical Database (1980-2015) by using text keywords: facial palsy OR facial paralysis, end-to-side hypoglossal-facial nerve OR side-to-end hypoglossal-facial nerve, anastomosis OR suture OR neurorrhaphy.

Table 1. Characteristics of studies

Study	Country	Design of parent study	N	Age (in years)	Time to paralysis (in months)	Preoperative HB	Postoperative HB or RFNRS	Side effect
Sammi 2015	Germany	Retrospective	17	38 (2-69)	NA	NA	II:1 III:13 IV:2 V:1	Mild lingual hypotrophy
Willam 2014	US	Retrospective	19	47.4±18.6	8.7±9.9	IV:18 V:1	III:7 IV:9 V:3	Weakness on tongue movement
Beutner 2013	Germany	Retrospective	5	36 (6-68)	25 (12-30)	V:4 VI:1	III:5	None
Jacobson 2010	US	Retrospective	21	42 (13-73)	10 (0-36)	IV:1 V:2 VI:18	B:14 C:4 D:3	None
Rebol 2006	Slovenia	Retrospective	5	51 (24-67)	10 (8-13)	V:5	III:2 IV:2 V:1	None
Ferraresi 2006	Italy	Retrospective	2	32.5 (31-34)	12	VI:2	II:2	None
Roland 2006	US	Retrospective	9	(13-38)	9 (0-36)	V:1 VI:8	B:6 C:3	Parasitic motion
Koh 2002	South Korea	Retrospective	2	26.5 (21-32)	11 (9-13)	IV:2	III:2	None
Atlas 1997	Australia	Retrospective	3	46 (46-72)	12 (1-18)	VI:3	III:3	None
Sawamura 1997	Japan	Retrospective	4	29.5 (9-63)	26.5 (20-37)	V:1 VI:3	III:3 IV:1	None

Inclusion and exclusion criteria

Studies considered for inclusion met the following criteria (i): patients enrolled with complete facial paralysis following the removal of a tumor, skull base fracture, Bell's Palsy and other etiologies; (ii): patients at term scheduled to receive planned side-to-end HFA; (iii): Facial nerve function were evaluated using the House-Brackmann (HB) grading system or similar methods. 1 study [12] with a different classification of the facial nerve function and 2 studies [11, 13] using repaired facial nerve recovery scale (RFNRS) were converted to the HB grading system [4].

Exclusion criteria included: 1) the indicators described in articles with less association or data being incomplete; 2) repeated articles.

Data collection

In order to avoid systematic error in this meta-analysis, two reviewers independently assessed all the studies to ensure conformity in the application of the inclusion and exclusion criteria. Disagreements were resolved by discussion with a third author until a consensus was reached.

Statistical analysis

The data were analyzed using Meta-Analyst for window (version 3.13). By heterogeneity test,

the random-effect model was applied to merging sets of data and data analysis. The final data were subdivided into several groups for statistical analysis and chart description. Publication bias was assessed by funnel plots, and evaluated by the method of Begg's and Mazumadar's rank correlation test (Begg's test) and Egger's linear regression tests (Egger's test) [32] with the StatsDirect (version 3.0).

Results

Study selection

We retrieved 85 potentially eligible studies and excluded 75 studies because of the following reasons: animal studies, review articles, meeting reports, other methods of hypoglossal-facial nerve anastomosis or there was a lack of proper data. Finally, 10 [5, 10-18] appropriate studies with 87 patients were selected for analysis (**Figure 1**). The basic information on the final articles is summarized in **Table 1**.

Recovery rate

The overall success rates of HFA in 87 patients from 10 studies were as follows: 21 patients (24.1%) grade II, 44 patients (50.6%) grade III, 17 patients (19.5%) grade IV, 5 patients (5.7%) grade V. HB grade II and III recovery after anastomosis were satisfied by patients with slight or

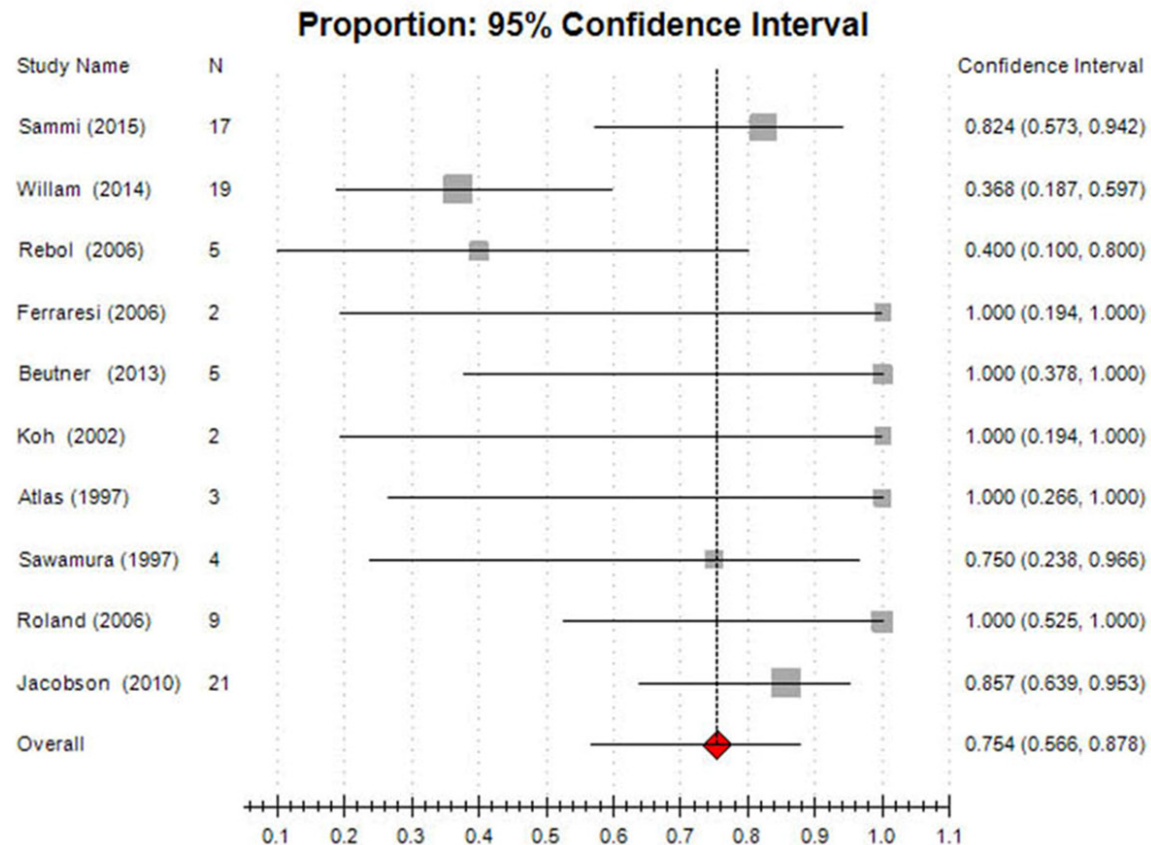


Figure 2. Forest plot of 95% confidence intervals showing good recovery rates of side-to-end HFA.

Table 2. The recovery rate after anastomosis at different time intervals

	Grade I		Grade II		Grade III		Grade IV		Grade V		Grade VI	
	N	%	N	%	N	%	N	%	N	%	N	%
≤ 12 months	0	0	15	57.7	7	26.9	2	7.7	1	3.8	1	3.8
12-24 months	0	0	4	28.6	9	64.3	1	7.1	0	0	0	0
> 24 months	0	0	1	11.1	6	66.7	2	22.2	0	0	0	0

obvious weakness but not disfiguring. So we defined HB grade II and III recovery as the successful recovery. Random-effect model was used for meta-analysis. As is shown by the forest plots (**Figure 2**), the results suggested that pooled good recovery rate of side-to-end HFA is 75.4% (95% CI: 56.6%-87.8%), with no significant heterogeneity ($P = 0.033$, $I^2 = 33.4\%$).

Timing of anastomosis

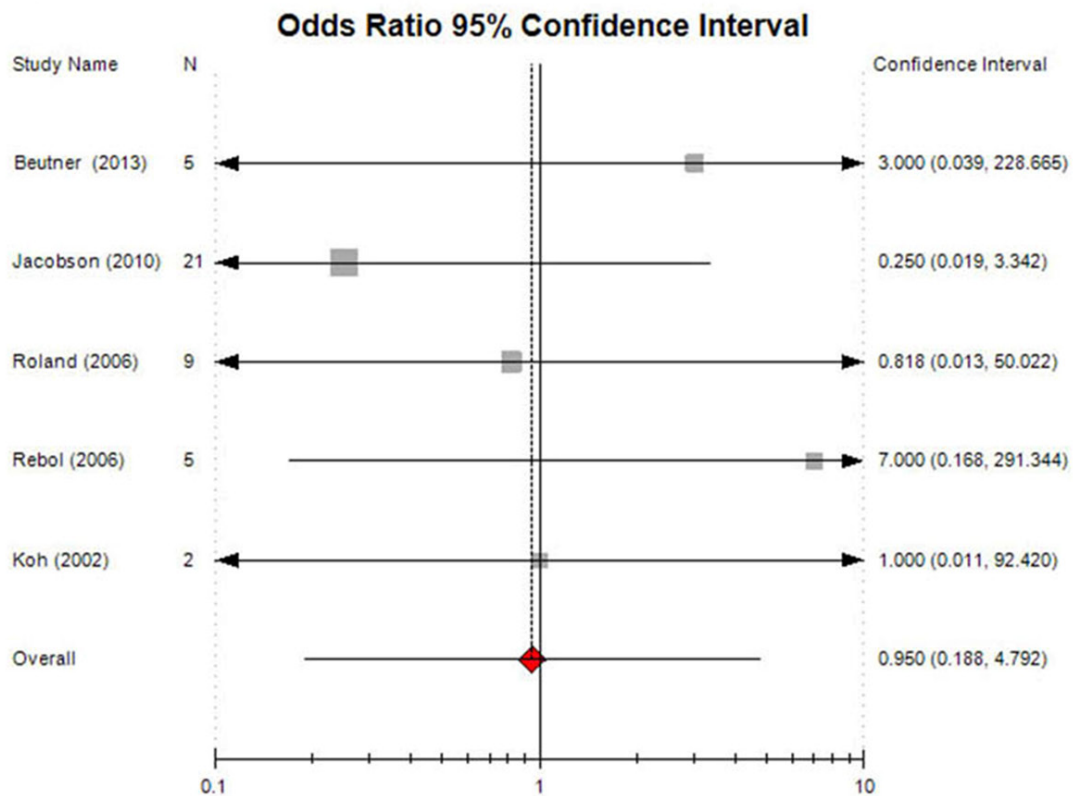
Recovery rates after anastomosis at different time intervals were showed in **Table 2**. Five studies [11, 13, 16-18] provided dichotomous data to compare recovery rate at less than and more than one year interval. Data pooled

from two studies [13, 18] compared the recovery rate more than 2 years and less than 2 years after the onset of paralysis. The difference between different intervals in the “good recovery rate” is not significant (**Figure 3**).

Degree of preoperative facial nerve dysfunction

There were 1 patient with grade IV, 18 patients with grade V, and 33 patients with grade VI facial paralysis before the anastomosis. On the other hand, there were 20 patients with grade II, 22 patients with grade III, 7 patients with grade IV, 2 patients with grade V and 1 patients with grade VI facial paralysis after the anas-

>1year interval vs. ≤1year interval



>2years interval vs. ≤2years interval

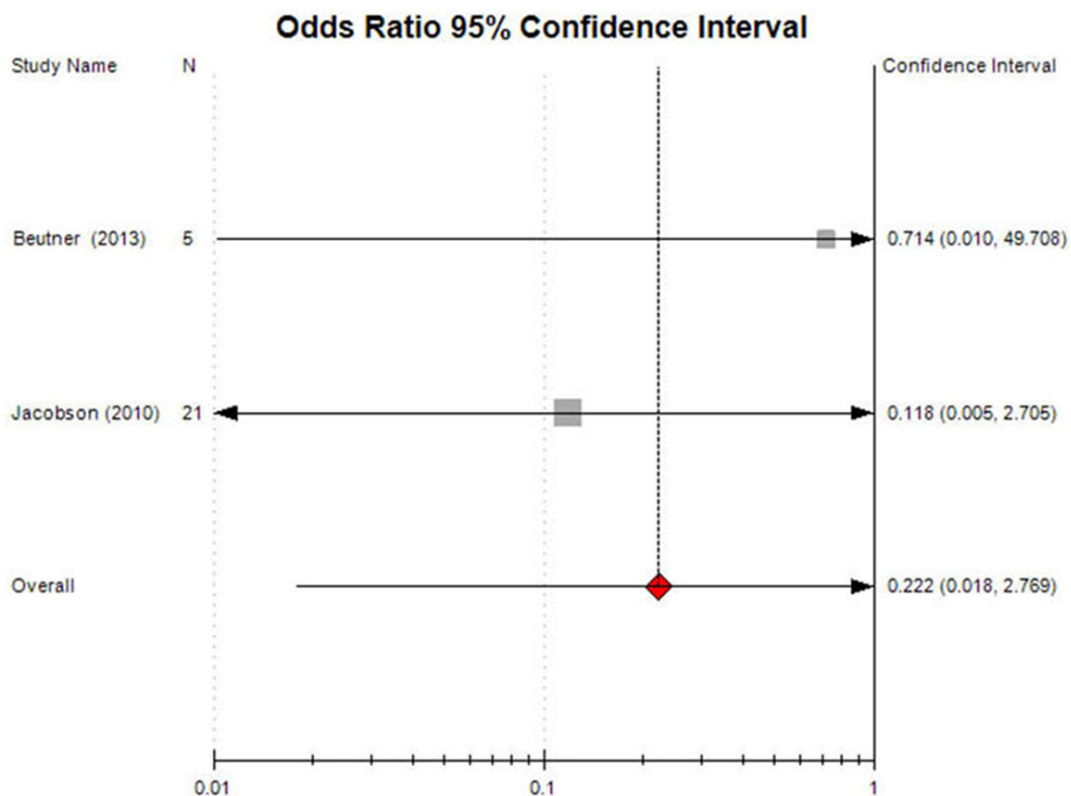


Figure 3. Forest plot of 95% confidence intervals for the recovery rates after anastomosis at different time intervals, for 5 studies comparing more than 1-year interval vs. less than 1-year interval, and 3 studies comparing more than 2-year interval vs. less than 2-year interval.

tomosis from 7 studies [10-13, 16-18]. Dichotomous data on recovery rates of preoperative grade V and VI to postoperative grade II or III were pooled from four studies [10, 11, 13, 17] (**Figure 4**). Different levels of severity of facial nerve dysfunction have no significant influence on the recovery rate.

Adverse effects

There were no significant adverse effects after side-to-end HFA as **Figure 5** showed. In seven articles [10, 12, 13, 15-18], there were no side effects or complications observed. However, one out of 17 patients developed lingual hypotrophy in the study by in Samii et al. [14]. And one patient with weakness on tongue movement [5] and another synkinetic movement [11] was reported.

Publication bias

The funnel plot regarding the good recovery rate of side-to-end HFA (**Figure 6A**) showed no potential publication bias among the included studies (*P*-values from Begg's test and Egger's test were 0.652 and 0.761, respectively). The funnel plot regarding the adverse effect after side-to-end HFA (**Figure 6B**) showed no potential publication bias among the included studies (*P*-values from Begg's test and Egger's test were 0.587 and 0.751, respectively).

Discussion

Facial reanimation with hypoglossal-to-facial nerve anastomosis has been used since early 20th century to address the debilitating morbidity of facial nerve paralysis. However, reanimation of the paralyzed face is still a great challenge despite the revolution of the technique. Besides the obvious cosmetic disfigurement, there are also deficits related to oral competence and mastication, multiple sensory deficits, and a considerable risk to the eye. It is necessary to find a more appropriate method to treat peripheral facial nerve injury.

In a meta-analysis of 293 patients with end-to-end HFA and 71 patients with side-to-end HFA (including 57 with interposition graft and only

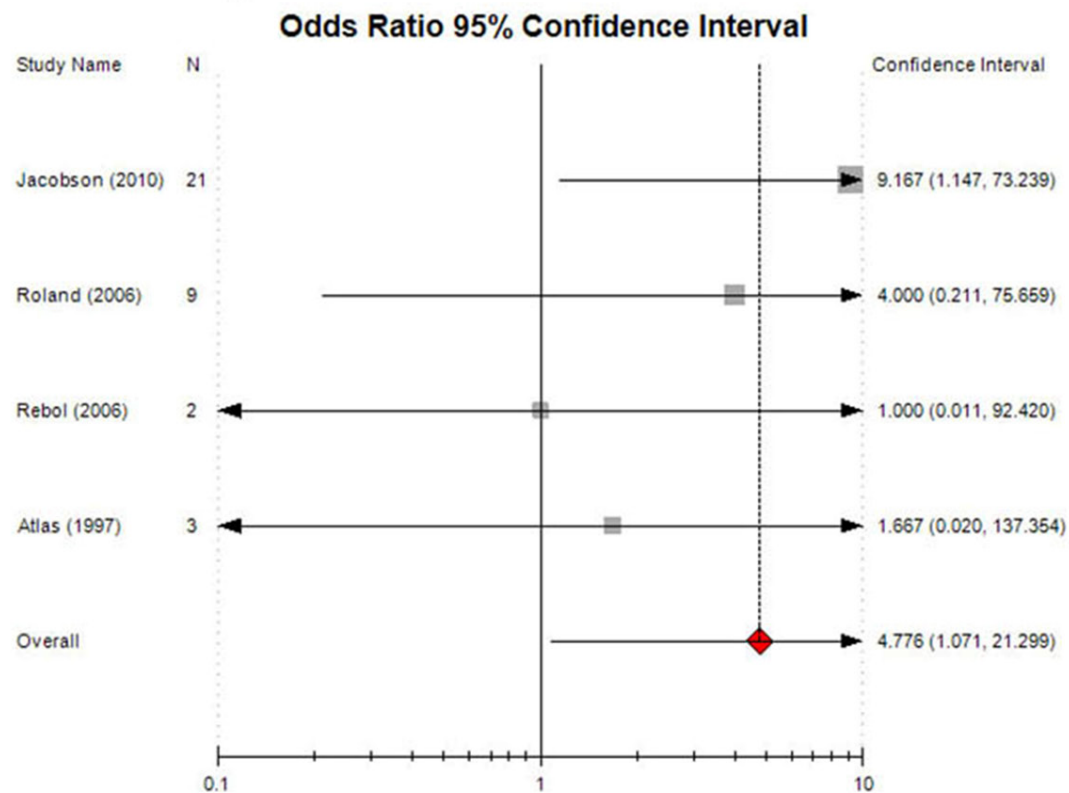
14 with direct HFA), a grade II HB was achieved in 12.6%, grade III in 50.8%, grade IV in 28.9%, grade V in 6.3% and grade VI in 1.4%. The grade II and III recovery rate was lower than that reported in our study. As a result, an important assumption is brought in in this paper that side-to-end HFA may have a better efficacy in regards to facial nerve recovery.

Anatomic evidence showed the hypoglossal and facial nerve anatomy to be ideal for side-to-end anastomosis [19]. Atrophic facial nerve diameter is to be nearly 50% of the diameter of the normal hypoglossal nerve diameter, which bodes well for end-to-side anastomosis. And the caliber of the myelinated axons of the hypoglossal and facial nerve are to be similar (8~11 and 7~10 μ m, respectively). The mobilizing the facial nerve from the second genu to the pes can free from 22 to 42 mm, which was sufficient to reach the closest point on the hypoglossal nerve. This was also the case with Campero and Socolovsky, who determined that on average 35 mm of mobilized nerve or graft is needed [20]. And additional facial nerve is released from the parotid for the extra length to reach beyond the ansa hypoglossi bifurcation [11, 13], which is not used in every study involved in our research. This allows for a tensionless anastomosis, optimizing the local tissue environment and host-bed neovascularization for improved clinical outcomes.

Besides the anatomic characteristics, surgical technique of side-to-end HFA is also conducive for facial nerve recovery. Suture anastomosis may result in fibrosis, foreign-body reactions, axonal mismatch, neuromas, and wound separation [21], which are associated with longer rehabilitation duration. Thus, a single anastomosis, unlike the jump graft technique, enhances neural regeneration and optimizes results. From the case series published, it clearly gives comparable results to the jump graft and HFA [8, 22]. However, because of slight variations in technique, different grading scales, and small series, it is difficult to directly compare results.

Since the introduction of the side-to-end HFA procedures, there has been a debate on the advantages compared to classic HFA. With the

Grade II recovery rate



Grade III recovery rate

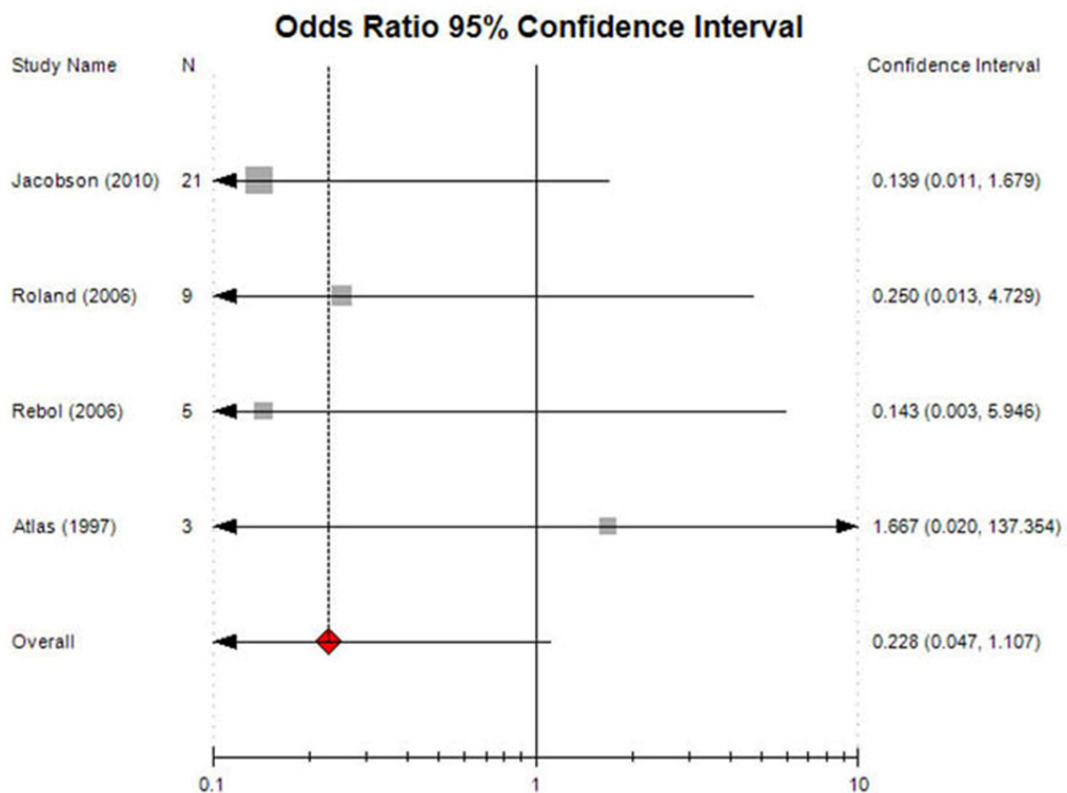


Figure 4. Forest plot of 95% confidence intervals for the recovery rates of preoperative facial nerve dysfunction (grade V and VI HB).

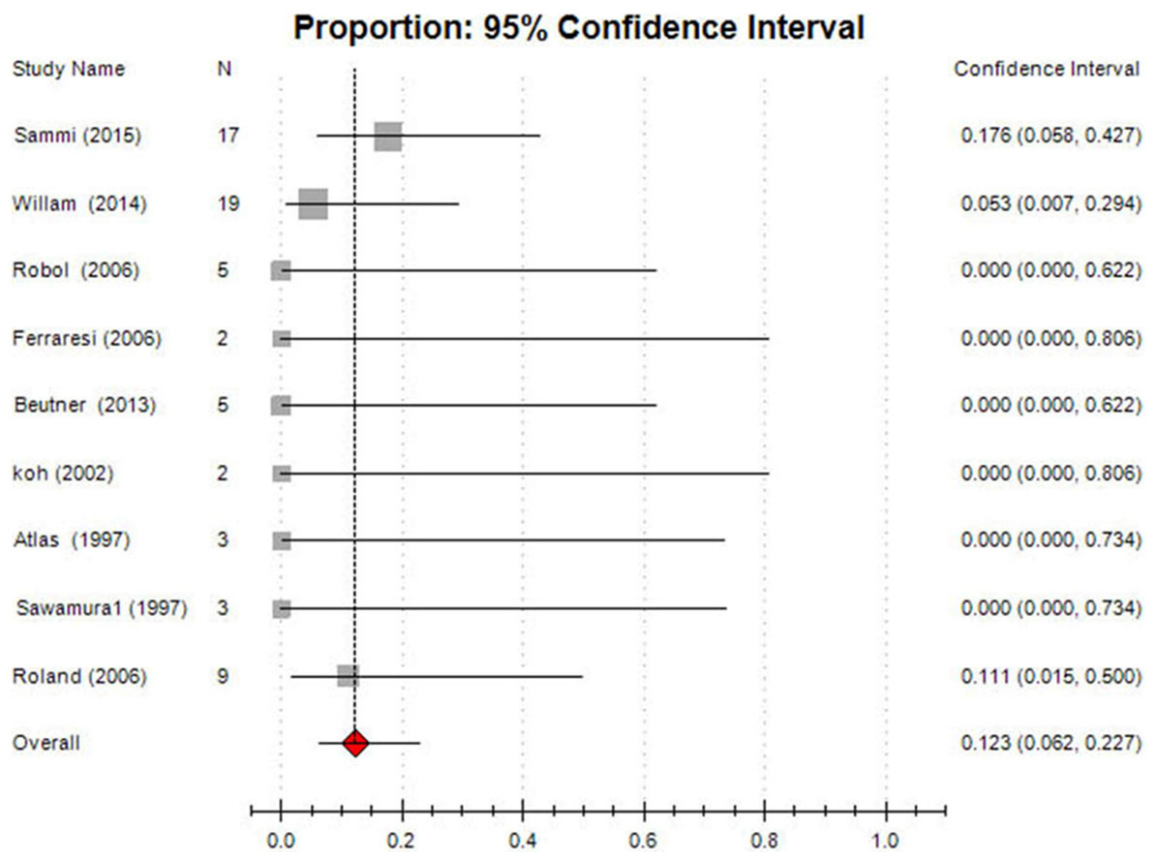


Figure 5. Forest plot of 95% confidence intervals for adverse effects after side-to-end HFA.

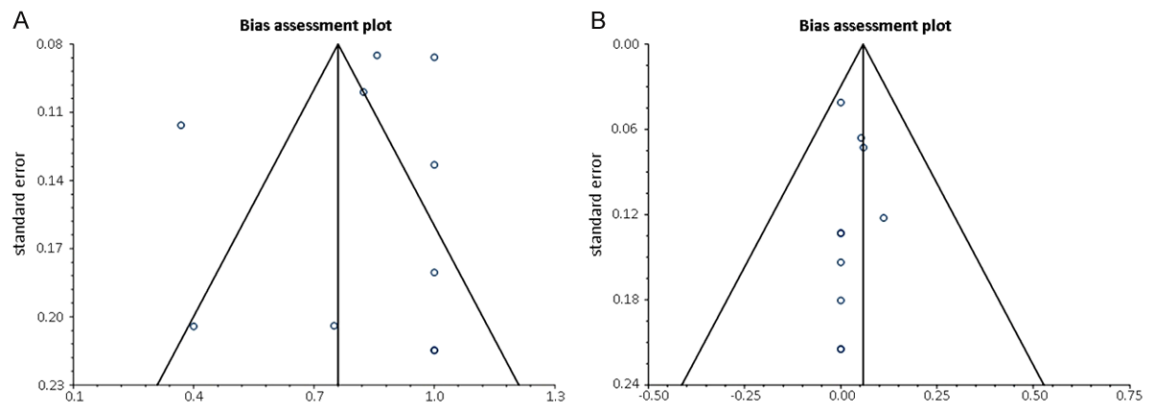


Figure 6. Funnel plot for studies on the good recovery rate (A) and adverse effect (B) of side-to-end HFA.

side-to-end HFA , hemiglossal atrophy and the dysfunction of swallowing and speech due to complete transection of hypoglossal were avoided. One patient developed lingual hypotro-

phy, one with weakness on tongue movement and one with synkinetic movement were reported in the ten studies involved in our analysis. The incidence is lower compared that induced

by classic HFA reported by Smaii [14]. Nevertheless, because of insufficient evidence, the conclusion that side-to-end HFA better than classic technique can not be drawn.

Recovery result was not statistically significantly associated with sex, side (right or left), tumor size in those with tumor surgery as cause of injury, or cause of paralysis [5]. Duration of paralysis has been implicated in the outcomes of reanimation, but has not been fully established [4]. It is widely accepted that better results are obtained with a shorter interval. And general guidelines have usually been developed based on personal clinical experience and should be conducted before fibrosis and permanent atrophy of the facial musculature [23]. Guntinas-Lichius et al. recommend the surgery within the first 2 years [24]. Yetiser et al. reported that reanimation procedures are generally carried out about 1 year after the onset of facial paralysis [4]. Kunihiro et al. indicated that HFA should be performed as early as 3 months after paralysis [25, 26]. As researches mentioned above, 2 years may be “dead line” to repair facial function.

However, contradictory results have clouded the decision-making for the timing of the repair. Toffola revealed no significant correlation between early surgery and outcome, and emphasize the importance of physical training [27]. From our result, with an interval of more than 2 years side-to-end HFA could also result in a good outcome.

Therefore, there is no definite period of delay beyond which side-to-end HFA becomes ineffective. Sawamura et al. also demonstrated that 2 of the 3 patients who benefited from side-to-end HFA more than 2 years after facial palsy, the facial nerve continuity was preserved. Interestingly, almost all the patients operated later in our research benefited from the reconstructive procedure, had an anatomically preserved but nonfunctioning facial nerve. There are some possible reasons, shorter distance between the facial nerve muscles, physiological differences between facial and limb musculature that explain the relative tolerance of facial muscles to longer denervation periods, axonal from the contralateral facial nerve [28] and clinically imperceptible trophic influence of the anatomically preserved facial nerve [8] that maintain integrity of myoneural junction during denervation. This underscores

the importance of preserving the continuity of the facial nerve during tumor resection.

As suggested by Catli et al. [29] and Wang et al. [30] function improvement can be strongly influenced by the rehabilitation process. So even if the period after the facial injury is more than 2 years, there is still a chance for functional. But the time for recuperation is longer in patients who had a longer delay period between facial injury and repair and in those who received radiation therapy before the HFA. A protracted course of recovery should be expected and discussed with these patients.

Another prognostic indicator for the success of sideHFA could be the grade of the previous facial nerve paralysis. But in our study, there was no significant influence induced by previous facial nerve function. Like our result, Malik et al. [31] indicated that injury of facial function before the reparative surgery was not associated with a worse outcome. The findings in that study strikingly indicate that neither the presence of facial paralysis before the anastomosis nor the severity of it had a negative effect on prognosis.

This study has several limitations. First, only 10 RCTs were included in this meta-analysis and the sample sizes were small. Second, the evaluating methods were not integrated among researchers, which may introduce heterogeneity. Third, we cannot avoid all biases such as publication bias, because research with negative results is not easy to publish. We are uncertain whether all the papers suitable for our research were included in our study. Finally, because of insufficient evidence, the comparison between side-to-end HFA better and other techniques cannot be carried out. We should minimize the likelihood of bias and draw objective conclusions as much as possible by developing a detailed protocol in advance, by performing a comprehensive search for published and unpublished trials, by applying explicit methods for study selection, data extraction, and data analysis, and by critically appraising study quality.

Conclusion

Hypoglossal-facial nerve side-to-end anastomosis is an effective and reliable technique with consistent and satisfying results. Neither the severity of the lesion nor duration of facial

palsy has an adverse effect on prognosis. Even with more than 2 years interval, there is still a chance for functional recovery. Major complications caused by the complete transection of the hypoglossal nerve, such as lingual atrophy and difficulty in swallowing and speech, can be avoided with the side-to-end technique.

Disclosure of conflict of interest

None.

Address correspondence to: Wenlong Luo, Department of Otolaryngology-Head and Neck Surgery, The Second Affiliated Hospital of Chongqing Medical University, Chongqing 400010, China. E-mail: wenlong_long22@sina.com

References

- [1] Terzis JK, Noah ME. Analysis of 100 cases of free-muscle transplantation for facial paralysis. *Plast Reconstr Surg* 1997; 99: 1905-1921.
- [2] Terzis JK, Tzafetta K. The "babysitter" procedure: minihypoglossal to facial nerve transfer and cross-facial nerve grafting. *Plast Reconstr Surg* 2009; 123: 865-876.
- [3] Moubayed SP, Labbe D, Rahal A. Lengthening temporalis myoplasty for facial paralysis reanimation: an objective analysis of each surgical step. *JAMA Facial Plast Surg* 2015; 17: 179-182.
- [4] Yetiser S, Karapinar U. Hypoglossal-facial nerve anastomosis: a meta-analytic study. *Ann Otol Rhinol Laryngol* 2007; 116: 542-549.
- [5] Slattery WH 3rd, Cassis AM, Wilkinson EP, Santos F, Berliner K. Side-to-end hypoglossal to facial anastomosis with transposition of the intratemporal facial nerve. *Otol Neurotol* 2014; 35: 509-513.
- [6] W K. Ein fall von nervenpfpfung des nervus facialis auf den nervus hypoglossus. 1903.
- [7] Magliulo G, D'Amico R, Forino M. Results and complications of facial reanimation following cerebellopontine angle surgery. *Eur Arch Otorhinolaryngol* 2001; 258: 45-48.
- [8] Martins RS, Socolovsky M, Siqueira MG, Campero A. Hemihypoglossal-facial neurotomy after mastoid dissection of the facial nerve: results in 24 patients and comparison with the classic technique. *Neurosurgery* 2008; 63: 310-316; discussion 7.
- [9] May M, Sobol SM, Mester SJ. Hypoglossal-facial nerve interpositional-jump graft for facial reanimation without tongue atrophy. *Otolaryngol Head Neck Surg* 1991; 104: 818-825.
- [10] Atlas MD, Lowinger DS. A new technique for hypoglossal-facial nerve repair. *Laryngoscope* 1997; 107: 984-991.
- [11] Roland JT Jr, Lin K, Klausner LM, Miller PJ. Direct Facial-to-Hypoglossal Neurotomy with Parotid Release. *Skull Base* 2006; 16: 101-108.
- [12] Sawamura Y, Abe H. Hypoglossal-facial nerve side-to-end anastomosis for preservation of hypoglossal function: results of delayed treatment with a new technique. *J Neurosurg* 1997; 86: 203-206.
- [13] Jacobson J, Rihani J, Lin K, Miller PJ, Roland JT Jr. Outcomes of Direct Facial-to-Hypoglossal Neurotomy with Parotid Release. *Skull Base* 2011; 21: 7-12.
- [14] Samii M, Alimohamadi M, Karimi Khouzani R, Rashid MR, Gerganov V. Comparison of direct side to end and end to end hypoglossal-facial anastomosis for facial nerve repair. *World Neurosurg* 2015; 84: 368-75.
- [15] Ferraresi S, Garozzo D, Migliorini V, Buffatti P. End-to-side intrapetrous hypoglossal-facial anastomosis for reanimation of the face. Technical note. *J Neurosurg* 2006; 104: 457-460.
- [16] Koh KS, Kim J, Kim CJ, Kwun BD, Kim SY. Hypoglossal-facial crossover in facial-nerve palsy: pure end-to-side anastomosis technique. *Br J Plast Surg* 2002; 55: 25-31.
- [17] Rebol J, Milojkovic V, Didanovic V. Side-to-end hypoglossal-facial anastomosis via transposition of the intratemporal facial nerve. *Acta Neurochir (Wien)* 2006; 148: 653-657; discussion 7.
- [18] Beutner D, Luers JC, Grosheva M. Hypoglossal-facial-jump-anastomosis without an interposition nerve graft. *Laryngoscope* 2013; 123: 2392-2396.
- [19] Asaoka K, Sawamura Y, Nagashima M, Fukushima T. Surgical anatomy for direct hypoglossal-facial nerve side-to-end "anastomosis". *J Neurosurg* 1999; 91: 268-275.
- [20] Campero A, Socolovsky M. Facial reanimation by means of the hypoglossal nerve: anatomic comparison of different techniques. *Neurosurgery* 2007; 61 Suppl: 41-9; discussion 9-50.
- [21] Gidley PW, Gantz BJ, Rubinstein JT. Facial nerve grafts: from cerebellopontine angle and beyond. *Am J Otol* 1999; 20: 781-788.
- [22] Godefroy WP, Malessy MJ, Tromp AA, van der Mey AG. Intratemporal facial nerve transfer with direct coaptation to the hypoglossal nerve. *Otol Neurotol* 2007; 28: 546-550.
- [23] Hammerschlag PE. Facial reanimation with jump interpositional graft hypoglossal facial anastomosis and hypoglossal facial anastomosis

Hypoglossal-facial nerve anastomosis

- sis: evolution in management of facial paralysis. *Laryngoscope* 1999; 109 Suppl 90: 1-23.
- [24] Guntinas-Lichius O, Irintchev A, Streppel M, Lenzen M, Grosheva M, Wewetzer K, Neiss WF, Angelov DN. Factors limiting motor recovery after facial nerve transection in the rat: combined structural and functional analyses. *Eur J Neurosci* 2005; 21: 391-402.
- [25] Kunihiro T, Higashino K, Kanzaki J. Classic hypoglossal-facial nerve anastomosis after acoustic neuroma resection. A review of 46 cases. *ORL J Otorhinolaryngol Relat Spec* 2003; 65: 1-6.
- [26] Celis-Aguilar E, Lassaletta L, Roda JM, Gavilan J. End-to-Side interposed donor grafting as a facial nerve reinforcement technique after vestibular schwannoma surgery. *Ann Otol Rhinol Laryngol* 2013; 122: 520-523.
- [27] Dalla Toffola E, Pavese C, Cecini M, Petrucci L, Ricotti S, Bejor M, Salimbeni G, Biglioli F, Klersy C. Hypoglossal-facial nerve anastomosis and rehabilitation in patients with complete facial palsy: cohort study of 30 patients followed up for three years. *Funct Neurol* 2014; 29: 183-187.
- [28] Tankere F, Bernat I, Vitte E, Lamas G, Bouche P, Fournier E, Soudant J, Willer JC. Hypoglossal-facial nerve anastomosis: dynamic insight into the cross-innervation phenomenon. *Neurology* 2003; 61: 693-695.
- [29] Catli T, Bayazit YA, Gokdogan O, Goksu N. Facial reanimation with end-to-end hypoglossofacial anastomosis: 20 years' experience. *J Laryngol Otol* 2010; 124: 23-25.
- [30] Wang Z, Zhang Z, Huang Q, Yang J, Wu H. Long-term facial nerve function following facial reanimation after translabyrinthine vestibular schwannoma surgery: A comparison between sural grafting and VII-XII anastomosis. *Exp Ther Med* 2013; 6: 101-104.
- [31] Malik TH, Kelly G, Ahmed A, Saeed SR, Ramsden RT. A comparison of surgical techniques used in dynamic reanimation of the paralyzed face. *Otol Neurotol* 2005; 26: 284-291.
- [32] Egger M, Davey Smith G, Schneider M, Minder C. Bias in meta-analysis detected by a simple, graphical test. *BMJ* 1997; 315: 629-34.