Int J Clin Exp Med 2016;9(8):16923-16926
www.ijcem.com /ISSN:1940-5901/IJCEM0025644

Case Report

Diagnosis of a pedigree with Fabry disease mimicking erythromelalgia: the utility of next-generation sequencing in a precision medicine perspective

Zhao Chen[1*], Wei Ye[1*], Shujun Jiao[1], Dongxue Ding[1], Zhe Long[1], Huirong Peng[1], Yun Peng[1], Chunrong Wang[1], Qian Pan[2], Kun Xia[2], Beisha Tang[1,2,3], Hong Jiang[1,2,3,4]

[1]Department of Neurology, Xiangya Hospital, Central South University, Changsha, Hunan, P.R. China; [2]State Key Laboratory of Medical Genetics, Central South University, Changsha, Hunan, P.R. China; [3]Key Laboratory of Hunan Province in Neurodegenerative Disorders, Central South University, Changsha, Hunan, P.R. China; [4]Xinjiang Medical University, Xinjiang, P.R. China. [*]Equal contributors.

Received February 5, 2016; Accepted May 10, 2016; Epub August 15, 2016; Published August 30, 2016

Abstract: Fabry disease (FD) is an X-linked inherited metabolic lysosomal storage disease caused by absence or deficiency activity of α-galactosidase A coded by *GLA* gene on Xq22. Here, a Chinese pedigree with FD presenting as primary erythromelalgia (PEM) was followed up for 6 years. Diagnosis was not confirmed until we found a known common variant in the causative gene *GLA* using whole-exome sequencing (WES), which further implies that next-generation sequencing (NGS) technology is a preferable tool for diagnosis on disorders characterized by genetic and clinical heterogeneity in a precision medicine perspective.

Keywords: Fabry disease, next-generation sequencing, *GLA*, precision medicine, genetic diagnosis

Introduction

Fabry disease (OMIM 301500; FD), or Anderson-Fabry's disease (AFD) is a rare X-linked inherited lysosomal storage disease caused by absence or deficiency activity of α-galactosidase A, which results in the accumulation of globotriaosylceramide (Gb3) within lysosomes in a variety of cell types, including vascular endothelium, dorsal root ganglion neuronal cells, renal glomerular and tubular epithelial cells, and cardiomyocytes [1, 2]. Lysosomal α-galactosidase A is coded by causative gene *GLA*, and currently, over 600 variants/mutations in *GLA* have been described (The Human Gene Mutation Database, 2014). Early diagnosisof FD in clinical practice may be challenging and it is often misdiagnosed as other disorders, such as PEM, rheumatic fever, multiple sclerosis, Raynaud syndrome, idiopathic polyneuropathy [3], *et al*.

Case report

This pedigree of six generations came from mainland of China with a total of 59 members including 17 patients (**Figure 1A**). The age at onset (AO) of these affected individuals ranged from 7 to 14 years (mean AO for the present series: 10 ± 2 years). These patients were characterized by recurrent episodes of burning pain associated with redness in the extremities usually evoked by long time standing, exercise and local exposure to warmth, and relieved by putting extremities into cold water. In 2007, we first examined the proband, a 28-year-old male with the age at onset at 7 years old, with complains of burning pain in his feet provoked or aggravated by fever, a long walk and exposure to warmth and the symptoms achieved remission with a local cooling of his feet. The result of neurological examination was normal. Laboratory exams including blood routine test, urinalysis and serum creatinase analysis, electrocardiogram (ECG) test and electromyography (EMG) test revealed were in normal range. In 2013, the proband returned for a reexamination. The severity of pain in his extremities was relieved during these years, and there was no noticeable sign found by physical examination. Blood count and urinalysis were normal. The ECG

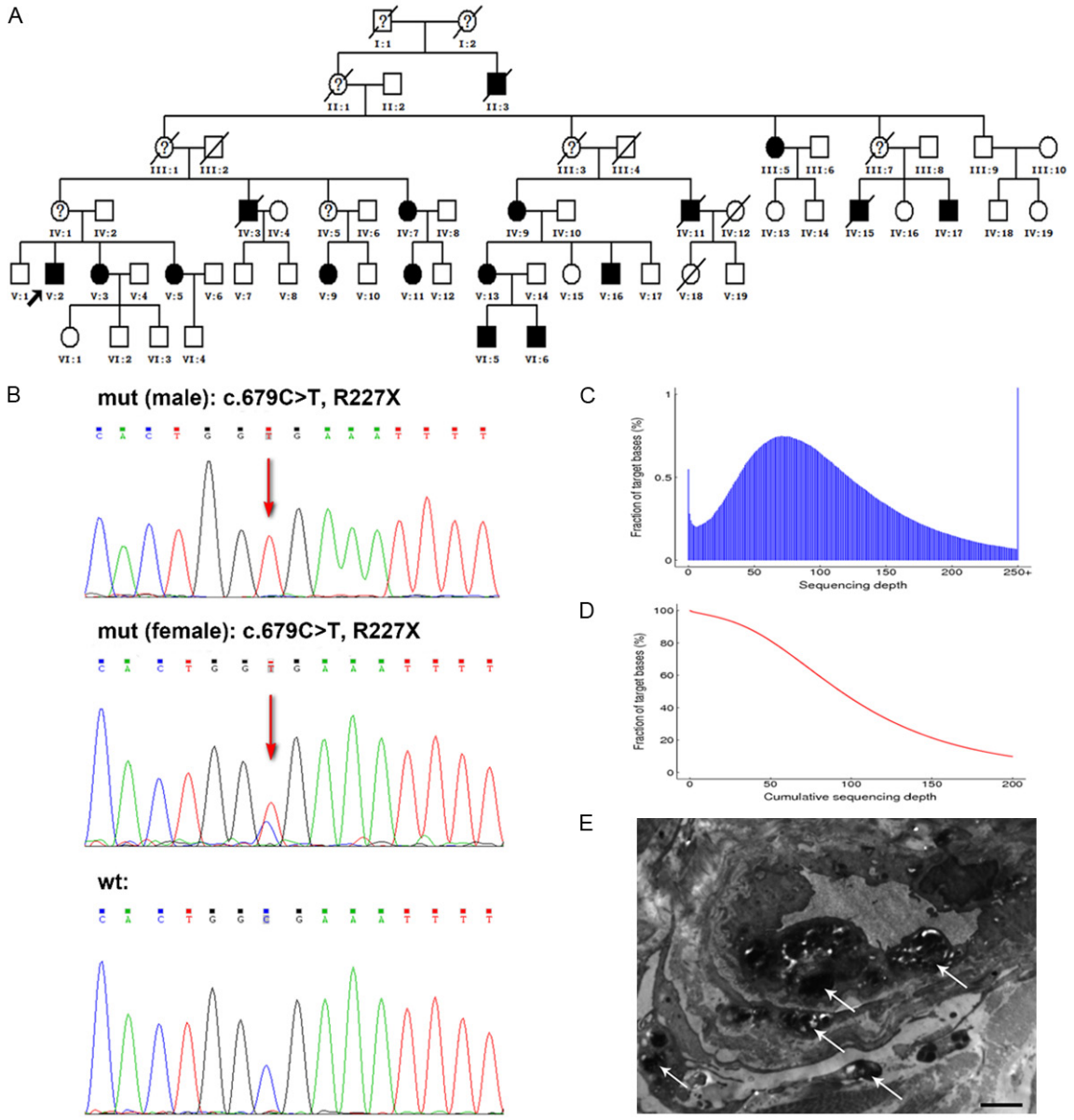

Figure 1. Pedigree, pathogenic mutation in the *GLA* gene and skin biopsy of the proband. A. Pedigree. B. Sanger sequencing of the *GLA* gene in the affected individuals and normal controls. C. The distribution of per-base sequencing depth in target regions for gDNA sample of the proband. D. Cumulative depth distribution in target regions for gDNA sample of the proband. E. Skin biopsy (transmission electron microscopy, scale bar = 20 μm) of the proband showing lysosomal inclusions consisting of tightly arranged, concentric lamellae, or called lamellar bodies (arrows).

showed left ventricular high voltage. The UCG study showed mild increase of the left atrium diameter (LAD) and mild regurgitation was detected in pulmonic, tricuspid and mitral valves. We recorded clinical data of the proband and several other affected members, which showed in **Table 1**.

With a presumptive diagnosis of PEM, we sequenced the candidate gene *SCN9A* but found no causative variant. Then, we employed the gDNA of the proband to exome sequencing with Illumina Genome Analyser II platform (Illumina). About 117 Mb raw base reads of the whole exons for the proband were captured and sequenced in this study with average depth for target region being above 109X (**Figure 1C**, **1D**), and on average 98% of base pairs were successfully detected indicated high capability for variants identification (**Table 2**).

Table 1. Overview of clinical features of the proband and some other individuals in Chinese family

Clinical features	Patient NO.											
	III:5	IV:1	IV:9	IV:17	V:2	V:3	V:5	V:9	V:11	V:13	V:16	VI:5
Gender	F	F	F	M	M	F	F	F	F	F	M	M
Age	71	56	65	54	34	32	31	29	28	44	37	25
Age at onset	10	N	13	10	7	11	10	7	11	12	10	8
Acroparesthesias	+	-	+	+	-	-	+	+	+	+	+	+
Angiokeratoma	-	-	-	-	-	-	-	-	-	-	-	-
Hypohidrosis	-	-	-	-	-	-	-	-	-	-	-	-
Headache	-	-	-	-	-	-	-	-	-	-	-	-
Vertigo	-	-	-	-	-	-	-	-	-	-	-	-
Corneal opacities	/	-	/	/	-	/	/	/	/	-	-	-
ECG abnormalities	/	-	/	/	+	/	/	/	/	-	-	-
UCG abnormalities	/	-	/	/	+	/	/	/	/	-	-	-
EMG abnormalities	/	-	/	/	-	/	/	/	/	-	-	-
Proteinuria	/	-	/	/	-	/	/	/	/	-	-	-
Uric acid	/	-	/	/	+	/	/	/	/	-	-	-
Anemia	/	-	/	/	+	/	/	/	/	-	-	-
Brain MRI	/	-	/	/	-	/	/	/	/	-	-	-
a-GLA activity in isolated leukocytes (nmol/h/mg)#	/	17.06	/	/	2.27	/	/	/	/	15.45	2.09	2.13

Notes: M, Male; F, Female; /, data not available; N, individual IV:1 is the proband's mother and she was not clinically affected. #GLA activity in isolated leukocytes in 100 normal individuals from China rang from 24.71~94.79 nmol/h/mg (mean, 51.97 ± 15.24 nmol/h/mg).

Table 2. Overview of data production

Raw reads yield (Mb)	Capture specificity (%)	Coverage of targeted region (%)	Mean depth of targeted region	Depth of targeted region ≥ 4 × (%)	Depth of targeted region ≥ 10 × (%)	Depth of targeted region ≥ 20 × (%)
10531	70.19	99.45	109.12	98.71	97.48	95.10

We analyzed the exome sequencing data and surprisingly found out a known mutation, c.679C>T of exon 5 (p.R227X), in *GLA* gene encoding α-galactosidase A, which is the causative gene of FD. Sanger sequencing of affected individuals and normal controls in this family was performed to confirm the variant (**Figure 1B**). Thus, a skin biopsy in electron microscopy of the proband showed lysosomal inclusions consisting of tightly arranged, concentric lamellae, or called lamellar bodies (**Figure 1E**). Activity of α-galactosidase A of isolated leukocytesfrom five individuals were measured following the methods described previously [4] and revealed a variety degree of decrease in enzyme activity showed in **Table 1**, which was consistent with FD.

Discussion

We here reported a Chinese pedigree with FD mimicking PEM on early stage. Diagnosis was delayed until six years later the finding of a known variant in the disease-causing gene GLA using WES as well as a decreased leukocytes α-GLA activity subsequently, indicating that it is likely to misdiagnose for atypical FD cases.

This variant was first reported by Christine M. Eng, et al. [5] in two FD families with the classical phenotype. However, this case we reported has atypical symptoms without typical acroparesthesia, angiokeratomas, cornea verticillata, *et al*. The proband was not recognized as FD until the finding of a known variant in the causative *GLA* gene, showing that a high possibility of clinical heterogeneity may exist in FD. In clinical practice, unfortunately, realizing the early signs of FD may be challenging and consequently considerable diagnostic delays occurred, due to a variety of reasons, including the rarity of the disease, heterogeneity of clinical features and a lack of awareness of this disease [6, 7].

The advent of precision medicine that aims togenerate individualized strategies of prevention, diagnosis and treatment would provide abroad insight into whole range of disease [8]. As for rare genetic disease, the utility of NGS as

an updated molecular diagnostic approach-could help to uncover the molecular etiology of diseases with high clinical and genetic heterogeneity [9]. This case illustrates that NGS technology is a powerful tool for diagnosis and differential diagnosis, which would facilitate the evolution of so-called "precision diagnosis" in patients with atypical presentations and equivocal diagnoses. Although there exist some debated results relevant to this method, the interpretation of data resulted from NGS technology can be reasonable and reliable based on the guideline proposed by ACMG [10]. As NGS becomes both affordable and accessible in the immediate future, the convenience and effectiveness of this genetic diagnostic strategy will be recognized by more clinicians, thus promoting the clinical application of NGS in the early diagnosis of atypical FD cases or other inherited metabolic diseases.

Acknowledgements

This study was supported by the Xinjiang Natural Science Foundation (No. 201318101-4 to Hong Jiang). The authors declare that they have no financial or other conflicts of interest in relation to this research and its publication. Informed consent was obtained from all individual participants included in the study.

Disclosure of conflict of interest

None.

Address correspondence to: Hong Jiang, Department of Neurology, Xiangya Hospital, Central South University, Changsha, Hunan, P.R. China. E-mail: jianghong73868@126.com

References

[1] Brady RO, Gal AE, Bradley RM, Martensson E, Warshaw AL, Laster L. Enzymatic defect in Fabry's disease. Ceramidetrihexosidase deficiency. N Engl J Med 1967; 276: 1163-1167.

[2] Peters FP, Vermeulen A, Kho TL. Anderson-Fabry's disease: alpha-galactosidase deficiency. Lancet 2001; 357: 138-140.

[3] Samuelsson K, Kostulas K, Vrethem M, Rolfs A, Press R. Idiopathic small fiber neuropathy: phenotype, etiologies, and the search for fabry disease. J Clin Neurol 2014; 10: 108-118.

[4] Desnick RJ, Allen KY, Desnick SJ, Raman MK, Bernlohr RW, Krivit W. Fabry's disease: enzymatic diagnosis of hemizygotes and heterozygotes. Alpha-galactosidase activities in plasma, serum, urine, and leukocytes. J Lab Clin Med 1973; 81: 157-171.

[5] Eng CM, Resnick-Silverman LA, Niehaus DJ, Astrin KH, Desnick RJ. Nature and frequency of mutations in the alpha-galactosidase A gene that cause Fabry disease. Am J Hum Genet 1993; 53: 1186-1197.

[6] Taylor I, Dennett X, Nicholls K, Tubridy N. Intermittent claudication -- atypical presentation, diagnosis and treatment. J Clin Neurosci 2004; 11: 783-785.

[7] Hoffmann B, Mayatepek E. Fabry disease-often seen, rarely diagnosed. Dtsch Arztebl Int 2009; 106: 440-447.

[8] Mirnezami R, Nicholson J, Darzi A. Preparing for precision medicine. N Engl J Med 2012; 366: 489-491.

[9] Bras J, Guerreiro R, Hardy J. Use of next-generation sequencing and other whole-genome strategies to dissect neurological disease. Nat Rev Neurosci 2012; 13: 453-464.

[10] Richards S, Aziz N, Bale S, Bick D, Das S, Gastier-Foster J, Grody WW, Hegde M, Lyon E, Spector E, Voelkerding K, Rehm HL. Standards and guidelines for the interpretation of sequence variants: a joint consensus recommendation of the American College of Medical Genetics and Genomics and the Association for Molecular Pathology. Genet Med 2015; 17: 405-424.