

Case Report

Simultaneous surgery of synchronous hilar cholangiocarcinoma and pyogenic liver abscess-a case report

Xin Zhu, Zhi-Hong Shen, Xing-Gui Yuan, Xun Tong, Guan-Fu Tian, Bao-Chun Lu

Department of Hepatopancreatobiliary Surgery, Shaoxing People's Hospital (Zhejiang University Shaoxing Hospital), Shaoxing, Zhejiang Province, China

Received February 29, 2016; Accepted June 2, 2016; Epub August 15, 2016; Published August 30, 2016

Abstract: Hilar cholangiocarcinoma (HC) is a complex and aggressive malignancy of the biliary tree. Radical resection offers chance of long-term survival. Pyogenic liver abscess (PLA) is a severe condition, often requiring adequate drainage when antibiotic therapy fails. Here we report a case of synchronous HC (Bismuth type I) and PLA. A 76 years old male patient was referred to our hospital for upper abdominal discomfort and abnormal liver function test. A typical pyogenic abscess in the right liver as well as an intraluminal filling defect at the confluence of common hepatic duct and cystic duct were identified by ultrasonography, computed tomography (CT) and magnetic resonance cholangio-pancreatography (MRCP). This patient received simultaneous radical resection of HC and surgical drainage of PLA, and recovered well. Pathological results revealed adenocarcinoma of the common hepatic duct with lymph node uninvolved. To our knowledge, coincidence of these two life-threatening diseases is never reported. The inner relationship between these two diseases is unknown. Some factors may contribute to this situation: confluence of cystic duct and hepatic duct being involved by tumor, diabetes mellitus, bacterial translocation and the history of gallbladder stones. Although optimal treatment is unknown, simultaneous surgery may be a feasible and effective method.

Keywords: Hilar cholangiocarcinoma, pyogenic liver abscess, image, simultaneous, surgery

Introduction

Hilar cholangiocarcinoma (HC) is rare with poor prognosis. Jaundice is the most common presenting symptom. The gallbladder is usually vacuous due to the obstruction at the bifurcation of the right and left hepatic bile ducts. However, when the tumor arises from the lower part of the common hepatic duct, the gallbladder may be obstructed at an early stage and further complications may occur. Although the history of malignancy is associated with higher risk for developing a pyogenic liver abscess (PLA), the relationship of HC and PLA was unknown. Here we present a case of a 76-year-old male with synchronous Bismuth type I HC and PLA. Simultaneous surgery, which included radical resection of HC and surgical drainage of PLA, was performed.

Case report

A 76 years old male patient was referred to our hospital for upper abdominal discomfort and abnormal liver function test. Before admission, MRCP showed an intraluminal filling defect in the confluence of common hepatic duct and cystic duct (**Figure 1**). The history was unremarkable except for hypertension and diabetes. At admission, his body temperature was 39.1°C and blood pressure was 141/110 mmHg. Physical exam showed tenderness in the right upper quadrant of the abdomen and intense fist percussion over the right liver. White blood cell was $11.2 \times 10^9/L$ and C-reactive protein was 69.29 mg/L. Liver test showed elevated glutamic-pyruvic transaminase (451.2 U/L), glutamic-oxalacetic transaminase (271.4 U/L), alkaline phosphatase (491.8 U/L) and gamma-

Synchronous hilar cholangiocarcinoma and pyogenic liver abscess

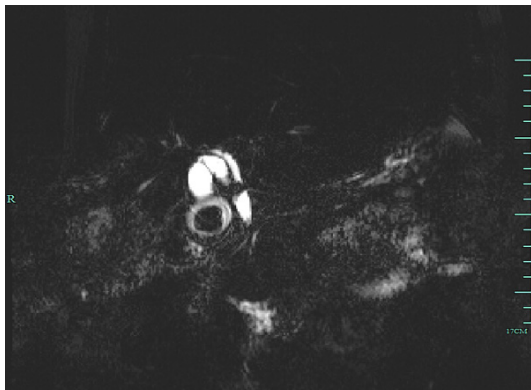


Figure 1. MRCP findings. Intraluminal filling defect in the confluence of common hepatic duct and cystic duct and calculi in the bottom of gallbladder.

glutamyltranspeptidase (543.1 U/L). Total bilirubin and direct bilirubin were 38.8 $\mu\text{mol/L}$ and 20.6 $\mu\text{mol/L}$. CA199, CA50 and CA242 were 2715.28 U/ml, 210.78 IU/ml and 142.9 IU/ml respectively. Ultrasonography showed a hypoechoic heterogeneous mass in the liver. The gallbladder was clear in border with unthickened wall (**Figure 2**). A hyperechoic lesion with acoustic shadow was visualized inside the gallbladder. CT scan showed a 32×48 mm hypodensity lesion with peripheral enhancement in the right lobe of the liver. A single intraluminal polypoidal soft tissue with contrast enhancement could be identified in the confluence of common hepatic duct and cystic duct (**Figure 3**). Intrahepatic bile ducts were dilated. According to the clinical manifestation and the results of various imaging modalities, we diagnosed the patients having synchronous HC and PLA.

After admission, intravenous antibiotics therapy was applied and ultrasonography-guided catheter drainage as well as liver biopsy was performed (**Figure 2**). However, the catheter was obstructed by pus and the state did not improve. Pathological examination did not show any evidence of malignancy of the liver lesion. After all these preparations, this patient underwent operation two weeks after admission.

During the operation, a mass with unclear borderline could be touched in segment V. 40 mL purulent fluid was extracted by an injector. Moreover, liver parenchyma on the surface of

the abscess was removed to make postoperative drainage accessible. The gallbladder was swollen and with a calculi at the bottom. A tumor was palpable at the confluence of common hepatic duct and the cystic duct with a tangible lymph node nearby. Common bile duct was transected close to the head of pancreas and the inferior margin was proved negative by frozen section analysis. Dissection was then conducted along the anterior wall of the portal vein. In this setting, the right hepatic artery was dissected carefully. The superior margin could only be proved negative until the bifurcation of the right and left hepatic ducts was reached. After removing the tumor along with the gallbladder, skeletonisation of the hepatoduodenal ligament was performed. Routine Rouen-Y choledochojejunostomy was performed to reconstruct the bile duct. One drainage tube was placed in the abscess cavity and another under the anastomose.

This patient did not suffer from fever or bile leakage after the surgery. Fluid food was feed 4 days after operation. The two drainage tubes were removed 5 and 6 days after operation respectively. Pathologic examination reported a cholangioadenocarcinoma with no lymph node metastasis. Both the inferior and superior margin was negative (**Figure 4**). CA-199 turned normal one week after operation. No chemotherapy was applied according to the will of the patient. During the 15 months follow-up, there was no evidence of recurrence of tumor or PLA.

Discussion

Hilar cholangiocarcinoma, also known as Klastkin tumor, accounts for over 60% of all cholangiocarcinomas [1]. For HC, radical resection, which includes R0 resection and extensive lymphadenectomy in the hepatoduodenal ligament can improve long-term survival [2, 3]. Partial hepatectomy was dependent on Bismuth-Corlette type of the tumor. Frozen section analysis was advocated by many researchers to confirm the suitability of the resection [4, 5]. In this case, frozen section played an important role in the choice during operation. The hepatoduodenal ligament was quite difficult to dissect due to inflammation caused by liver abscess, and it seemed to be a relatively late stage of HC. However, the tissues and lymph node around the common bile duct were proved

Synchronous hilar cholangiocarcinoma and pyogenic liver abscess

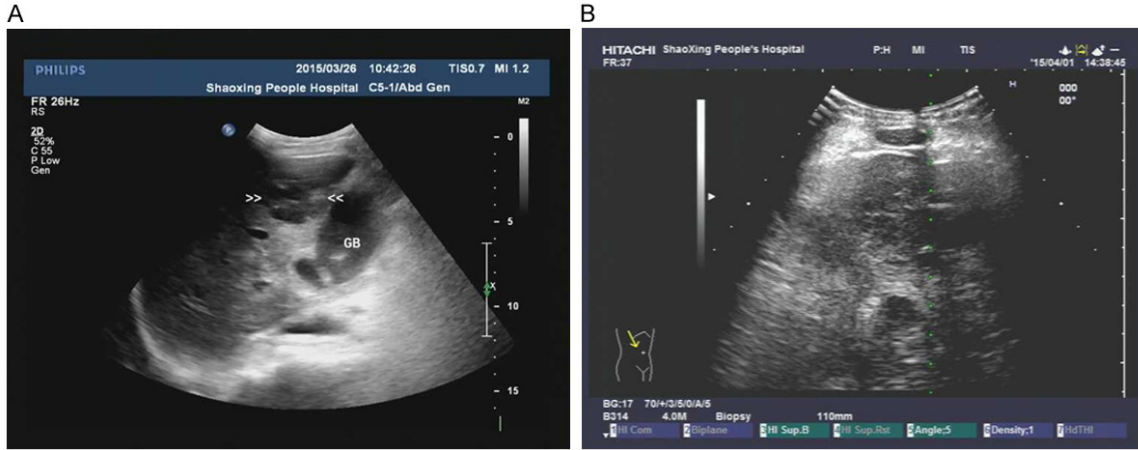


Figure 2. Ultrasonography findings. A: Hypoechoic heterogeneous mass in the liver and the image of gallbladder; B: Ultrasonography-guided catheter drainage and liver biopsy.

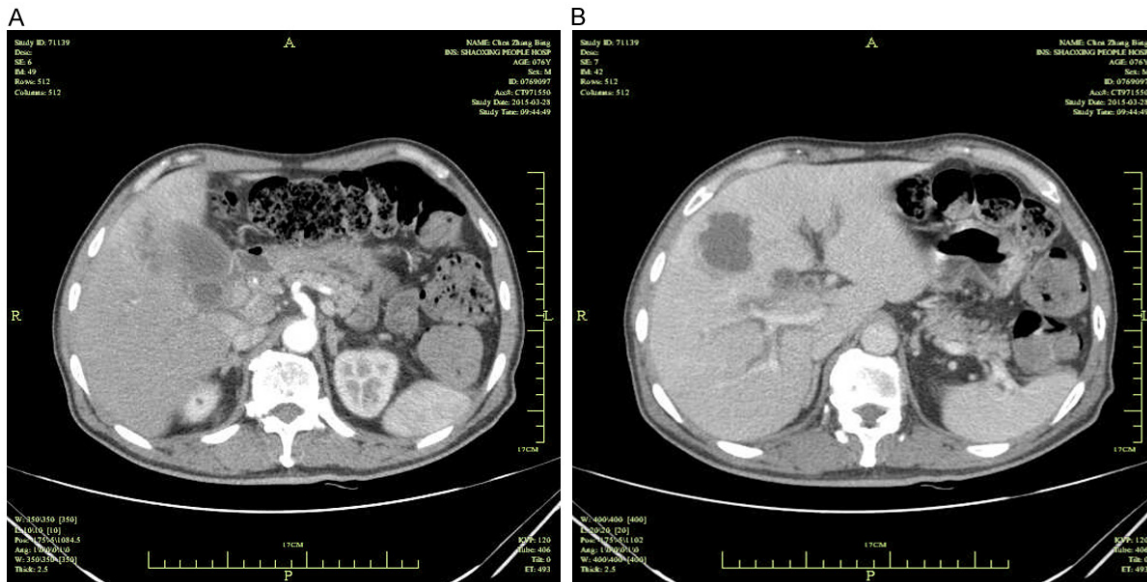


Figure 3. CT scan findings. A: Intraluminal polypoidal soft tissue with contrast enhancement in the confluence of common hepatic duct and cystic duct. B: Hypodense lesion with peripheral enhancement.

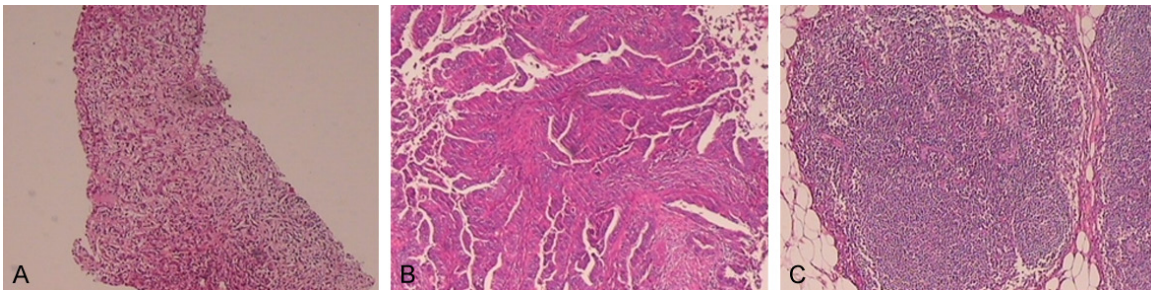


Figure 4. Pathologic results. A: Ultrasonography-guided liver biopsy. B: Adenocarcinoma of the common hepatic duct. C: Lymph node in the hepatoduodenal ligament.

Synchronous hilar cholangiocarcinoma and pyogenic liver abscess

to be uninvolved by frozen section. Hence, the radical resection came to be the dominant choice rather than palliative surgery. In addition, the bile ducts involved by tumor were far more extensive than CT or MRCP revealed. From these points, frozen section analysis was the key measure to ensure a R0 section.

Pyogenic liver abscess (PLA) is a severe condition with significant morbidity and mortality [6]. The history of diabetes and malignancy is associated with higher risk for developing a PLA [7]. However, the relation between HC and PLA was scarcely reported [8]. To our knowledge, this is the first case of synchronous HC and PLA that have ever been reported. Some factors may contribute to this situation: confluence of cystic duct and hepatic duct being involved by tumor, diabetes mellitus, bacterial translocation and the history of gallbladder stones.

In the last decade, percutaneous aspiration or catheter drainage guided by ultrasonography or CT were first-line treatments for PLA for their minimal invasive nature [9, 10]. However, laparoscopic or open drainage were still viable options when interventional radiology failed [11]. Once PLA is concurrent with other situations that need to be treated surgically, the optimal therapeutic strategy remains uncertain. In a study of 12 patients with acute cholecystitis and PLA, Renato Costi and his colleagues [12] recommended emergency cholecystostomy followed by delayed laparoscopic cholecystectomy should be a first-line treatment option for synchronous acute cholecystitis and PLA. For synchronous PLA and HC, the treatment would probably fall into an even dismal dilemma. The treatment of PLA is time-consuming, and the patient would probably lose the chance of R0 resection after recovery from PLA. At the other hand, it takes great risk carrying out radical resection for HC regardless of PLA. In this case, simultaneous surgery for both HC and PLA was performed. Some advantages of this strategy could be expected-resection of the cholangiocarcinoma at a relatively early stage, lower incidence of surgical site infection after operation and reduce of overall hospital stay. Our experiences of this patient imply simultaneous surgery be an accessible and effective option in this setting.

Acknowledgements

This research was supported by Medicine and Health Care Technology Project of Zhejiang Province, No. 2015KYA218 and The Platform of Medicine and Health Care Talents of Zhejiang Province, Type A, No 2014RCA031.

Disclosure of conflict of interest

None.

Address correspondence to: Dr. Bao-Chun Lu, Department of Hepatopancreatobiliary Surgery, Shaoxing People's Hospital (Zhejiang University Shaoxing Hospital), Zhongxing North Road 568#, Shaoxing 312000, Zhejiang Province, China. Tel: +86-0575-88229083; E-mail: lbc111@yeah.net

References

- [1] Nakeeb A, Pitt HA, Sohn TA, Coleman J, Abrams RA, Piantadosi S, Hruban RH, Lillemoe KD, Yeo CJ, Cameron JL. Cholangiocarcinoma. A spectrum of intrahepatic, perihilar, and distal tumors. *Ann Surg* 1996; 224: 463-473.
- [2] Cannon RM, Brock G, Buell JF. Surgical resection for hilar cholangiocarcinoma: experience improves resectability. *HPB (Oxford)* 2012; 14: 142-149.
- [3] Cho MS, Kim SH, Park SW, Lim JH, Choi GH, Park JS, Chung JB, Kim KS. Surgical outcomes and predicting factors of curative resection in patients with hilar cholangiocarcinoma: 10-year single-institution experience. *J Gastrointest Surg* 2012; 16: 1672-1679.
- [4] Hemming AW, Reed AI, Fujita S, Foley DP, Howard RJ. Surgical management of hilar cholangiocarcinoma. *Ann Surg* 2005; 241: 693-699.
- [5] Kawasaki S, Imamura H, Kobayashi A, Noike T, Miwa S, Miyagawa S. Results of surgical resection for patients with hilar bile duct cancer: application of extended hepatectomy after biliary drainage and hemihepatic portal vein embolization. *Ann Surg* 2003; 238: 84-92.
- [6] Meddings L, Myers RP, Hubbard J, Shaheen AA, Laupland KB, Dixon E, Coffin C, Kaplan GG. A population-based study of pyogenic liver abscesses in the United States: incidence, mortality, and temporal trends. *Am J Gastroenterol* 2010; 105: 117-124.
- [7] Kaplan GG, Gregson DB, Laupland KB. Population-based study of the epidemiology of and the risk factors for pyogenic liver abscess. *Clin Gastroenterol Hepatol* 2004; 2: 1032-1038.

Synchronous hilar cholangiocarcinoma and pyogenic liver abscess

- [8] Lai HC, Lin CC, Cheng KS, Kao JT, Chou JW, Peng CY, Lai SW, Chen PC, Sung FC. Increased incidence of gastrointestinal cancers among patients with pyogenic liver abscess: a population-based cohort study. *Gastroenterology* 2014; 146: 129-137.
- [9] Zerem E, Hadzic A. Sonographically guided percutaneous catheter drainage versus needle aspiration in the management of pyogenic liver abscess. *AJR Am J Roentgenol* 2007; 189: 138-142.
- [10] Dulku G, Mohan G, Samuelson S, Ferguson J, Tibballs J. Percutaneous aspiration versus catheter drainage of liver abscess: A retrospective review. *Australas Med J* 2015; 8: 7-18.
- [11] Wang W, Lee WJ, Wei PL, Chen TC, Huang MT. Laparoscopic drainage of pyogenic liver abscesses. *Surg Today* 2004; 34: 323-325.
- [12] Costi R, Le Bian A, Cauchy F, Diop PS, Carloni A, Catherine L, Smadja C. Synchronous pyogenic liver abscess and acute cholecystitis: how to recognize it and what to do (emergency cholecystostomy followed by delayed laparoscopic cholecystectomy). *Surg Endosc* 2012; 26: 205-213.