

Original Article

The effects of recombinant human bone morphogenic protein-2 and low-level laser irradiation on synthetic graft healing in a rat bony defect model

Mahmut Koparal¹, Ibrahim Kose¹, Yusuf Atalay², Omer Cakmak³, Hilal Alan⁴, Kamil Serkan Agacayak⁵, Ibrahim Halil Erdogan⁶, Belgin Gulsun⁵

¹Department of Oral and Maxillofacial Surgery, Faculty of Dentistry, Adiyaman University, Adiyaman, Turkey;

²Department of Oral and Maxillofacial Surgery, Faculty of Dentistry, Afyon Kocatepe University, Afyon, Turkey;

³Department of Periodontology, Faculty of Dentistry, Afyon Kocatepe University, Afyon, Turkey; ⁴Department of Oral and Maxillofacial Surgery, Faculty of Dentistry, Inonu University, Malatya, Turkey; ⁵Department of Oral and Maxillofacial Surgery, Faculty of Dentistry, Dicle University, Diyarbakir, Turkey; ⁶Department of Pathology, Faculty of Medicine, Adiyaman University, Adiyaman, Turkey

Received March 19, 2016; Accepted June 12, 2016; Epub August 15, 2016; Published August 30, 2016

Abstract: We assessed the benefit of bone morphogenic protein-2 (BMP-2) and low-level laser irradiation (LLLI) on the osseointegration of synthetic bone grafts. Synthetic bone grafts are safe alternatives to autografts. BMP-2 and LLLI have been shown separately to improve bone healing. However, their effects have not been evaluated together with synthetic materials. Here, we used a rat model to compare the efficacy of BMP-2 and LLLI on synthetic graft healing. Male Sprague-Dawley rats ($n = 35$) were divided equally into groups: control (defect only), graft only, graft and BMP-2, graft and LLLI, and a combination of graft, LLLI, and BMP-2. A 3×3 mm monocortical tibial defect was filled using a synthetic graft with or without 2 mg/mL BMP-2 pre-treatment. LLLI was performed using an optical fibre and an indium-gallium-arsenide-phosphate laser for 60 s daily for 7 days, delivering 6.0 J/day. Histopathology was performed 4 weeks post-graft using a standardised scoring system (1-5, based on the degree of healing observed). Groups were compared using the MannWhitney U test, with p values < 0.05 considered significant. Osteogenesis was poor in both the control and graft-only groups (1.4 ± 0.5 and 2.3 ± 0.5 , respectively). BMP-2- (4.3 ± 0.5), LLLI- (3.7 ± 0.5), and BMP-2/LLLI-treated (4.7 ± 0.5) grafts all displayed significantly more healing than the control or graft alone groups ($P < 0.001$). Both BMP-2 and LLLI significantly improved the osseointegration of synthetic bone grafts. However, no synergy was noted between the therapies.

Keywords: Bone healing, experimental surgery, low-level laser therapy, diode laser

Introduction

The repair of bony defects is a complex process in the human body. Various graft materials have been used to help bone repair. Among them, autografts have been considered the gold standard. Autografts are successful in osseointegration because they are the subject's own bone. However, other graft materials are also widely used due to such disadvantages as the need for a second operation to remove the autograft. Among these, synthetic grafts are biocompatible materials that are freed of organic materials, eliminating the risk of infection, and are compatible with human tis-

sues [1]. They generally have an osteoconduction effect mechanism. However, this characteristic of the graft material may not be sufficient for a good response in all cases. Thus, other methods have been used to increase the effectiveness of these materials, including low-level laser irradiation (LLLI).

Positive effects of LLLI on bone recovery have been shown in many clinical and experimental studies [2]. LLLI stimulated osteoblast precursor cells and increased osteoblastic cell proliferation, and thus, contributed to the formation of new cells [3]. Although the effects of LLLI in tissue repair are not fully understood, LLLI stim-

Effects of low-level laser on graft healing

Table 1. The irradiation parameters

Parameter	Value
Wavelength	940 nm (infrared)
Beam area	0.0707 cm ² (circle of diameter, 0.3 cm)
Output power	0.1 W
Irradiation time	60 s
Energy density	85 J/cm ²
Power density	1.414 W/cm ²
Energy delivered	6.0 J
Emission mode	Continuous
Application	In contact

ulates wound healing, collagen synthesis, and nerve damage repair [4-8]. A study by Tang and Chai showed that LLLI increased the effectiveness of red blood cells, macrophages, fibroblasts, chondrocytes, and osteoclasts in the fracture area [9]. Furthermore, LLLI promotes cell proliferation and protein synthesis by increasing the synthesis of DNA and RNA [10, 11]. LLLI reportedly triggers a low amount of reactive oxygen species and cell stimulation, and increases mitochondrial respiration and ATP synthesis [12].

Proteins such as recombinant human (rh) bone morphogenetic protein-2 (BMP-2) have a positive effect on bone formation. In 1965, Urist showed that placing decalcified bone matrix (DBM) outside skeletal areas led to the induction of bone formation [13]. The morphogenesis typically observed during embryogenic bone development is recapitulated following implantation of DBM outside the skeletal area, and natural bone formation ensues. Bone matrix proteins, especially bone morphogenetic proteins (BMPs), have osteoinductive potential [14]. In 1979, Urist first isolated proteins that caused bone induction, and observed that bone morphogenetic activity was higher than that of demineralised bone [15]. BMPs are members of the transforming growth factor-beta family. Currently, 15 BMPs are known. They are divided into subgroups according to their amino acid sequence similarities. Among them, BMP-2, BMP-4, and BMP-7 have the most effective osteoinductive properties; the BMP-2 protein possesses the greatest osteoinductive properties [14]. Currently, most rhBMP-2 is obtained using Chinese hamster ovary cells [16].

In this study, we sought to examine and compare the effectiveness of LLLI and BMP-2 appli-

cation, which have positive effects on bone regeneration and repair, on bone repair. With this aim, synthetic graft material, both treated and untreated, was applied to critical-dimension bony defects formed in rat tibia.

Materials and methods

Animals

The study included 35 male Sprague-Dawley rats (mean age, 12 weeks; weight, 290-350 g) and was conducted at the Health Institution Research Centre, Afyon Kocatepe University, Afyonkarahisar, Turkey. The animals were housed in groups of seven per plastic cage in a controlled environment (22°C, 12/12-h light/dark cycle) with free access to drinking water and a diet of standard laboratory rat food pellets. The experimental protocol was approved by the Animal Experimentation Ethics Committee of Kocatepe University (Decision number: 2014-49533702/120). The animals were maintained and used in accordance with the Animal Welfare Act and the Guide for the Care and Use of Laboratory Animals. The rats were divided randomly into five groups: Group A (control group), tibia defect model with no treatment ($n = 7$); Group B (graft group), tibia defect model treated with graft ($n = 7$); Group C (laser group), tibia defect model treated with graft and LLLI ($n = 7$); Group D (BMP-2 group), tibia defect model treated with graft and BMP-2 ($n = 7$); and Group E (BMP-2 and laser group), tibia defect model treated with graft, BMP-2, and LLLI ($n = 7$).

Preparation of BMP-2

We added 50 µg of distilled water to a vial that contained 10 µg of rhBMP-2 (R&D Systems, Minneapolis, MN, USA) to obtain a final concentration of 0.2 mg/mL. The biomaterial was soaked in 25 µg of rhBMP-2 solution for 15 min before it was placed in the defect.

Laser application

The low-level laser source used was an indium-gallium arsenide phosphate (InGaAsP) semiconductor diode device (Biolase Inc., Irvine, CA, USA), with the laser beam delivered via an optical fibre. The surgical hand piece directly contacted the area of interest without the fibre tip. The irradiation parameters are presented in **Table 1**.

Effects of low-level laser on graft healing

Table 2. Histological scoring table used for statistical analysis

Osteogenesis None 1 = 1 point = fibrous and cartilage tissue
Osteogenesis Weak 2 = 2 points = low trabecular bone with woven bone cells
Osteogenesis Medium 3 = 3 points = trabecular bone with woven bone cells (immature bone)
Osteogenesis Good 4 = good trabecular bone with lamellar bone cells and compact bone
Osteogenesis Perfect 5 = perfect trabecular bone with lamellar bone cells and compact bone (mature bone)

Holes (6-mm diameter) were created in the rat femur bones. The bones were directly irradiated with the laser immediately after surgery and every day after the surgery for a week. The parameters shown in **Table 1** were applied during each treatment session in the study.

Rat tibia defect model and surgical procedure

Surgical procedures were performed under general anaesthesia induced using a combination of ketamine chlorhydrate (Ketalar, 0.08 mL/100 g body weight; Pfizer Istanbul/Turkey) and 2% xylazine (Rompun, 0.04 mL/100 g body weight; Bayer Istanbul/Turkey). A monocortical bone defect was created on the left tibia in all animals. After moving the left leg into a flexion position, the overlying skin of the left tibia was shaved and disinfected with iodated alcohol. A 1.5 cm incision was then made in the skin and muscle to expose the bone surface of the middle third of the tibia, where a monocortical defect was created on the wider region. A 1 mm diameter rod and a size 12 stainless steel dental burr (Meisinger GmbH, Neuss, Germany) were used in a low-speed hand piece under constant sterile saline irrigation to create an oval bone defect measuring ~3 mm in width and 3 mm in length. The muscular layer was sutured with resorbable 5.0 catgut suture (Dogsan, Trabzon, Turkey), and the skin was sutured with an interrupted 3.0 silk suture (Dogsan, Trabzon, Turkey). Upon completion of the surgical procedure, each animal received a single 50 mg/kg dose of cefazolin sodium (Cefamezin; Zentiva/Turkey) via intramuscular injection.

Histopathological and biochemical evaluation

Following surgery, rats in each study group were sacrificed on day 28 using a high-dose combination of ketamine and xylazine. Bone regeneration and fibrotic healing were evaluated by histopathology. Histological samples were fixed in 10% formalin for 72 h and decalcified in a 10% ethylenediaminetetraacetic acid

solution for ~2 months. After decalcification was complete, dehydration was carried out in a graded alcohol series, and the samples were embedded in paraffin wax blocks. For each tibia defect, 4-5 µm-thick transverse sections were prepared. All slices were stained with haematoxylin and eosin and Masson's trichrome. Histological examination of the slides was carried out using a light microscope. An experienced pathologist evaluated all parameters using a histological scoring technique. The pathologist was blinded to the study groups to which each specimen belonged. Healed bone was observed at the repair stage of healing in all groups. Findings of fibrous tissue, cartilage tissue, immature ossification, and mature bone formation were observed in the groups. According to these findings, a semi-quantitative classification of bone healing was used as follows (**Table 2**).

Statistical analysis

We used SPSS software (v. 15.0 for Windows) for statistical analysis. Determinative statistics are shown as numbers and percentages for categorical variables, and medians and interquartile ranges. The categorical variable ratios were tested among the groups using χ^2 analyses. Multiple group comparisons of ordinal variables from two groups were carried out using Kruskal-Wallis H tests. Analyses of sub-groups were carried out with the Mann-Whitney U test and interpreted following Bonferroni correction. The statistical significance level was set at $P < 0.05$.

Results

Histopathological findings: haematoxylin and eosin staining (Figure 1)

Minimal fibrous tissue development and bone marrow areas were observed around the defect gap in Group 1 (control; **Figure 1A**). A low level of new bone formation, fibrous tissue forma-

Effects of low-level laser on graft healing

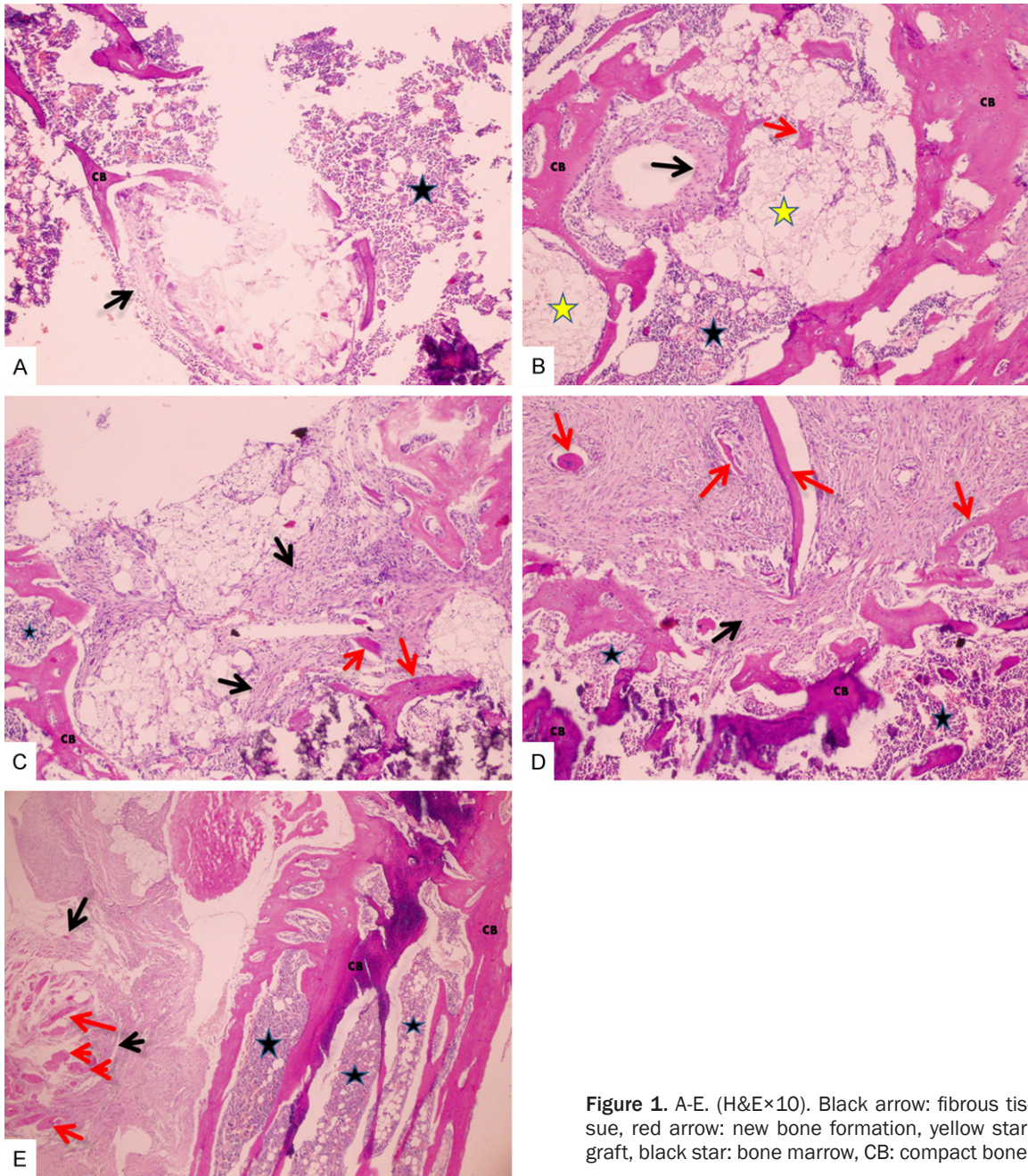


Figure 1. A-E. (H&E×10). Black arrow: fibrous tissue, red arrow: new bone formation, yellow star: graft, black star: bone marrow, CB: compact bone.

tion, and bone marrow elements was observed in Group 2 (graft group; **Figure 1B**).

Fibrous tissue formation and new bone formation were observed around the graft in Group 3 (laser group; **Figure 1C**). New lamellar bone formation was observed between the areas of recovery in Group 4 (BMP-2 group); the areas of recovery were covered by bone marrow (**Figure 1D**). In Group 5 (BMP-2/laser group), new bone formation was observed in the fibrous tissue

areas around the graft and trabecular bone marrow areas were observed (**Figure 1E**).

Histopathological findings: Masson's trichrome staining (Figure 2)

In Group 1 (control group), fibrous tissue areas were evident, with widespread collagen fibres observed; bleeding foci were observed between the bone marrow and fat tissue areas (**Figure 2A**). Recovery with fibrous tissue was observed

Effects of low-level laser on graft healing

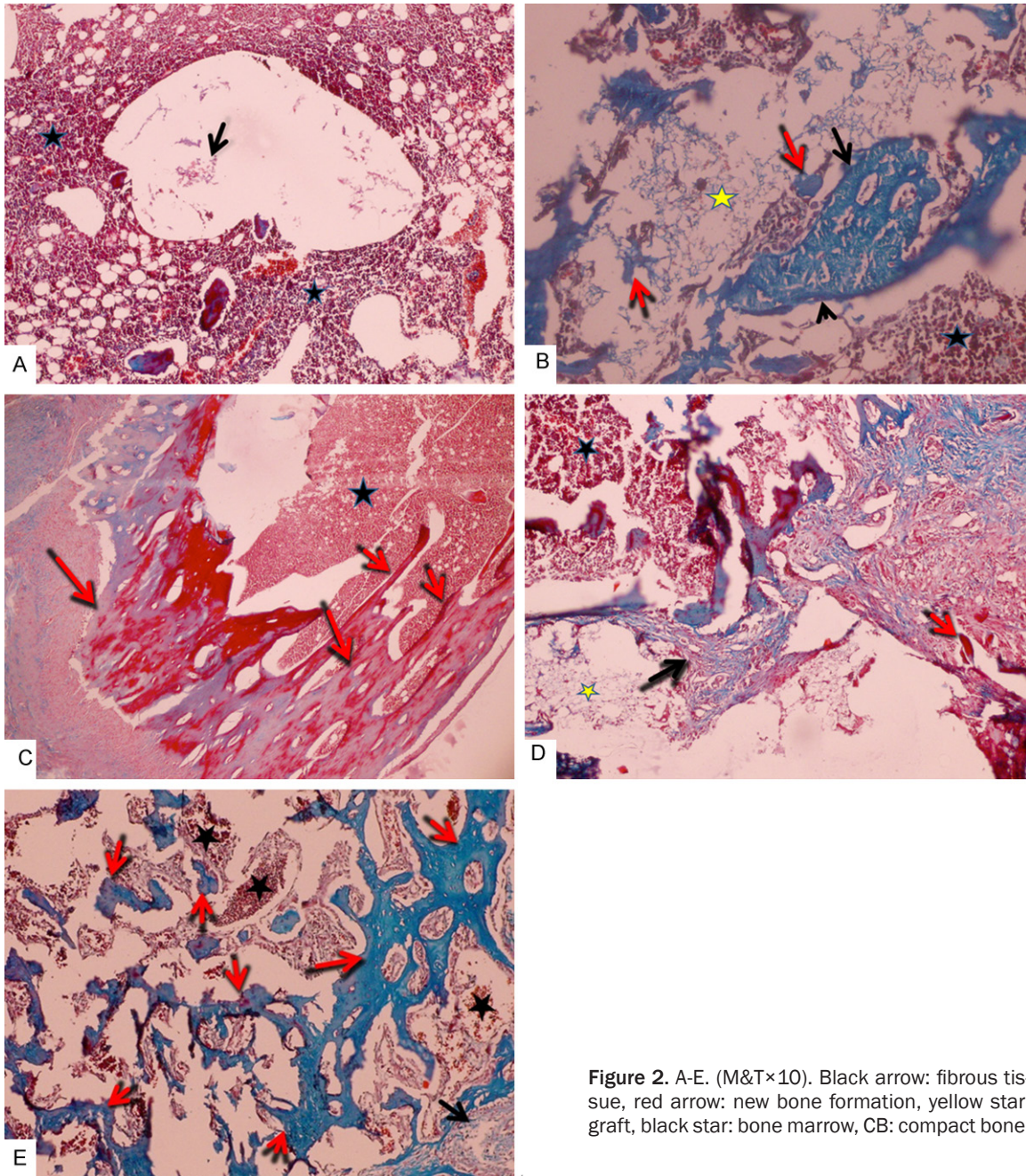


Figure 2. A-E. (M&T×10). Black arrow: fibrous tissue, red arrow: new bone formation, yellow star: graft, black star: bone marrow, CB: compact bone.

between the bone marrow areas around the graft, in addition to new bone formation, in Group 2 (graft Group; **Figure 2B**). In Group 3 (laser group), new bone formation of the lamellar structure, bone marrow, increased collagen fibres, and osteoblastic activity were observed (**Figure 2C**). Fibrous tissue development around graft areas and an increase in new bone formation were seen in Group 4 (BMP-2 group; **Figure 2D**). In Group 5 (BMP 2-laser group), ossification of the chondroid tissue around the defect

area, an evident increase in bone formation, and slight fibrous tissue were observed (**Figure 2E**).

Statistical findings

The prevalence of osteogenesis levels in all study groups is summarised in **Table 3**. A statistically significant difference in the prevalence of histopathological osteogenesis scores was found among all groups ($P < 0.001$; **Table 3**; **Figure 3**).

Effects of low-level laser on graft healing

Table 3. Prevalence of osteogenesis levels

		GROUP A		GROUP B		GROUP C		GROUP D		GROUP E		p
		n	%	n	%	n	%	n	%	n	%	
Osteogenesis	No	4	57.1	0	0.0	0	0.0	0	0.0	0	0.0	< 0.001
	Poor	3	42.9	5	71.4	0	0.0	0	0.0	0	0.0	
	Fair	0	0.0	2	28.6	0	0.0	2	28.6	0	0.0	
	Good	0	0.0	0	0.0	5	71.4	5	71.4	2	28.6	
	Excellent	0	0.0	0	0.0	2	28.6	0	0.0	5	71.4	

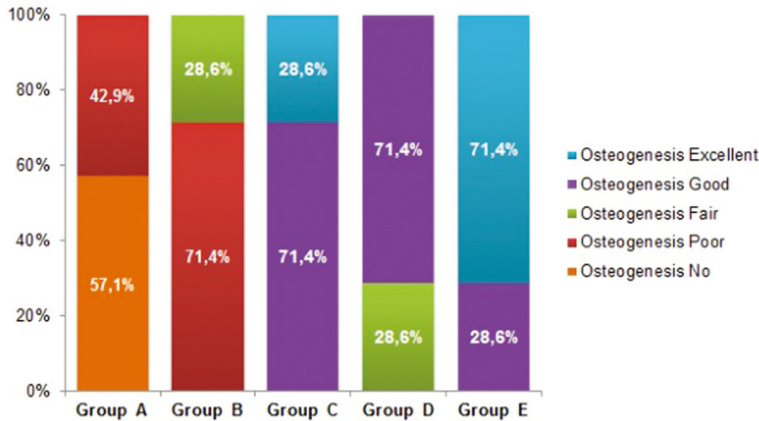


Figure 3. The prevalence of osteogenesis levels in all groups.

Table 4. Histopathological scoring of osteogenesis

	Mean ± SD	Median	IQR	p
GROUP A	1.4 ± 0.5	1	1-2	< 0.001
GROUP B	2.3 ± 0.5	2	2-3	
GROUP C	4.3 ± 0.5 ^{*β}	4	4-5	
GROUP D	3.7 ± 0.5 ^{*β}	4	3-4	
GROUP E	4.7 ± 0.5 ^{*β}	5	4-5	

^{*}Different from Group A and ^βdifferent from Group B (Mann-Whitney U test with Bonferroni correction, P < 0.005). (SD: Standard Deviation, IQR: Inter Quartile Range).

A statistically significant difference was found in the mean histopathological scores of the amount of osteogenesis in all groups (P < 0.001). While the mean score was not statistically significant between Group A and B (P > 0.005), a statistically significant increase was detected among the mean scores of Groups C, D, and E when compared with the mean scores of Groups A and B (P < 0.005). While Group E had the highest mean score, no statistically significant difference was detected between Group E and Groups C and D (P > 0.005; **Table 4; Figure 4**).

Discussion

In this study, we examined the effects of low-level laser and BMP-2 treatment, alone and in combination, on the recovery of a critical-dimension bone defect. Although autografts, xenografts, and synthetic materials have long been used for the repair of bony defects, they are not sufficient solutions to the problem. They have limited areas of use, high costs, difficulties in access, and they do not always yield the required result in osteointegration, leading to searches for other methods and materials [17].

These include the application of BMP-2 and lasers. Although many studies have examined the effects of BMP-2 and lasers on bone recovery, few studies have investigated their effects on graft materials applied to defect areas and their use in combination [18-20]. In this study, the effectiveness of BMP-2 and lasers on graft material applied in defect areas was examined.

In the literature, there are studies showing positive effects of BMPs on bone repair. Kuvat et al. performed a Le Fort 1 osteotomy in a patient with a class III defect, to whom they applied orthognathic surgery and 1 cc demineralised bone matrix + 20 mg ox collagen protein for rigidification between the segments to increase osteosynthesis. They then examined the recovery period of the patient. Ossification of a structure showing trabeculation with osteoblastic and osteocytic activity, mimicking intramembranous ossification, was observed via histopathology. Osteocytes were reportedly surrounded by osteoblasts and osteoclasts in the mesenchymal structure [21]. Harmut Feifel et al. reported that when they applied ProOsteon®

Effects of low-level laser on graft healing

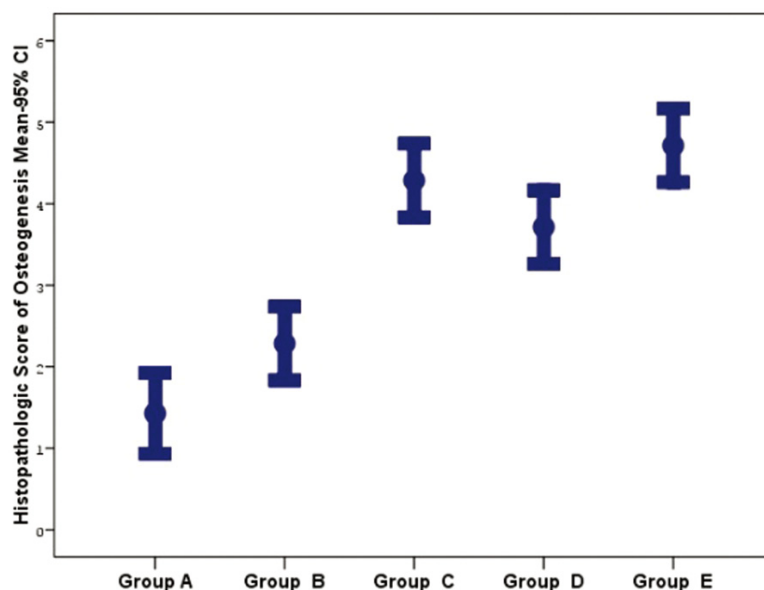


Figure 4. Histopathological scores of the amount of osteogenesis in all groups.

500 alone or in combination with Colloss® in a bony defect that they opened in rabbit femur and assessed bone recovery on days 28, 84, 168, and 365, the application increased ossification; however, this increase was not statistically significant [22].

It has been suggested that BMP-2 triggers the transformation of mesenchymal and root cells into osteoblasts and chondroblasts, and thus, increases new bone formation [23]. In this study, bone recovery in the BMP-2 group was higher than that in the control group and the group where only the graft was used. There is no clear measure of the BMP-2 dosage to be used for application, as different values have been reported in the literature [24-26]. Because we observed greater recovery in the groups that received BMP-2 alone and in combination with laser treatment than that in the control group suggests that the dosage of 0.2 mg/mL used in this study was sufficient.

There are various uses of LLLI in the clinic [27, 28]. Although its mechanism is not fully understood, there are many *in vivo* and *in vitro* studies indicating that it has positive effects on bony defect recovery [29-31]. Studies on the bone regeneration-stimulating effects of LLLI are ongoing. LLLI increases bone mineralisation and the population of osteoblast cells [32, 33]. It has been reported that the application of

LLLI increases the amount of ATP, accelerates mitosis, corrects tissue repair, stimulates bone repair, balances the production of fibroblasts by normalising the accumulation of collagen and elastic fibrils in tissue repair, increases peripheral blood circulation, and reduces anti-inflammatory activity [34, 35]. It was shown that LLLI played an important role in alveolar repair after tooth extraction and affected the processes of proliferation, differentiation, and calcification in osteoblast cultures [36].

The effects of LLLI on cells depend on the laser wavelength [37]. LLLI has been studied using the following wavelengths: 588 nm, [38, 39] 780 nm, [40] 830 nm, [33, 41-43] 735 nm, [44] 808 nm, [45] and 1064 nm [46, 47]. Use of the 'correct' wavelength is important for a specific indication; however, the 'best' wavelength for any particular indication has not yet been determined. Abo Elsaad et al. compared groups by applying bioactive glass and bioactive glass plus a laser together in the treatment of intra-bone defects. They applied LLLI on days 0, 3, 5, and 7 device. A basic rule in the determination of treatment ranges is that several applications (3-5) per week at medium dosages are better than fewer applications at higher dosages [42]. In their study in which they assessed the effectiveness of LLLI in intra-bone defects, Ozcelik et al. applied laser irradiation right after the operation and on days 1, 3, and 7 following the operation [38]. Further studies are needed to determine the most appropriate duration of irradiation. In our study, laser irradiation was applied right after the operation, and on days 1, 2, 3, 4, 5, 6, and 7 postoperation. The application of laser energy on these days demonstrated reliable results in tissue repair, and our results are consistent with others.

If laser irradiation is applied in the early period of recovery, it is more effective in the process by which the defect is filled. Brynes et al. examined the effects of LLLI on cutaneous wounds

in a type II diabetes animal model. They indicated that there was a significant level of development in the histology of wound closure and wound recovery following laser application at a dosage of 4 J/cm² [48]. In their study that examined wound healing after tooth extraction in a rat model, Takeda et al. applied LLLI with a GaAlAs laser in the area of extraction for 1 week. It was determined that LLLI both increased fibroblast proliferation and accelerated bone matrix formation [49]. In a clinical study by Amorim et al., in which they examined the recovery of the tooth gum after gingivectomy and LLLI, a 685-nm diode laser was applied immediately after the gingivectomy, 24 h later, and on Days 3 and 7, at an energy intensity of 4 J/cm². A biometric examination indicated that LLLI was an effective auxiliary treatment [50]. In a study in which they examined the effects of LLLI on mouse femurs, Merli et al. applied a GaAlAs laser at a wavelength of 670 nm, a power of 15 mW, and a dose of 16 J/cm² at 0, 24, 48, and 72 h, to the defects they created. Histological assessments of the subjects that were sacrificed on day 14 indicated that there was an increase in new bone formation in the group to which the laser was applied when compared with the control group [51].

Despite different treatment protocols, the aforementioned results were consistent with our study in terms of early bone recovery. The recovery was greater in both groups to which the laser was applied in our study versus the control group. In this study, as well as in other studies showing positive effects on bone recovery, the bone recovery in the group to which the laser was applied showed the 'best' recovery after the group to which the laser in combination with BMP-2 was applied [3, 19, 52]. A full trabecular recovery was observed in Group 5, where the laser in combination with BMP-2 was applied. These results were consistent with Renno et al. and Khodra et al. [53, 54].

Conclusion

In conclusion, we determined that the use of LLLI and BMP-2 had positive effects on the osteointegration of graft material applied to bony defects formed in rat tibia and the repair of the defect. Laser application alone had a better effect than BMP-2 application alone, and the use of BMP-2 in combination with the laser yielded a still better result.

Statement on the welfare of animals

All procedures performed in studies involving animals were in accordance with the ethical standards of the institution or practice at which the studies were conducted.

Disclosure of conflict of interest

None.

Address correspondence to: Dr. Mahmut Koparal, Department of Oral and Maxillofacial Surgery, Faculty of Dentistry, Adiyaman University, 02200, Adiyaman, Turkey. Tel: +90 4162251920; Fax: +90 4162251921; E-mail: koparalmahmut@gmail.com

References

- [1] Moore WR, Graves SE, Bain GI. Synthetic bone graft substitutes. *ANZ J Surg* 2001; 71: 354-61.
- [2] Stein A, Benayahu D, Maltz L, Oron U. Low-level laser irradiation promotes proliferation and differentiation of human osteoblasts in vitro. *Photomed Laser Surg* 2005; 23: 161-6.
- [3] Ozawa Y, Shimizu N, Kariya G, Abiko Y. Low-energy laser irradiation stimulates bone nodule formation at early stages of cell culture in rat calvarial cells. *Bone* 1998; 22: 347-54.
- [4] Mester E, Mester AF, Mester A. The biomedical effects of laser application. *Lasers Surg Med* 1985; 31-9.
- [5] Luger EJ, Rochkind S, Wollman Y, Kogan G, Dekel S. Effect of low-power laser irradiation on the mechanical properties of bone fracture healing in rats. *Lasers Surg Med* 1998; 22: 97-102.
- [6] Lam TS. Laser stimulation of collagen synthesis in human skin fibroblast cultures. *Lasers Life Sci* 1986; 61-77.
- [7] Bosatra M, Jucci A, Oliario P, Quacci D, Sacchi S. In vitro fibroblast and dermis fibroblast activation by laser irradiation at low energy. *Dermatology* 1984; 168: 157-62.
- [8] Anders JJ, Borke RC, Woolery SK, Van De Merwe WP. Low power laser irradiation alters the rate of regeneration of the rat facial nerve. *Lasers Surg Med* 1993; 13: 72-82.
- [9] Tang X, Chai B. Effect of CO₂ laser irradiation on experimental fracture healing: a transmission electron microscopic study. *Lasers Surg Med* 1986; 346-52.
- [10] SMOLYANINOVA TKN, ZELENIN A. Long Term and Short Term Responses of Human Lymphocytes to He Ne Laser Radiation. *Lasers in The Life Sciences* 1991; 167-78.
- [11] Saperia D, Glassberg E, Lyons RF, Abergel RP, Baneux P, Castel JC, Dwyer RM, Uitto J. Demon-

Effects of low-level laser on graft healing

- stration of elevated type I and type III procollagen mRNA levels in cutaneous wounds treated with helium-neon laser: proposed mechanism for enhanced wound healing. *Biochem Biophys Res Commun* 1986; 138: 1123-8.
- [12] Morimoto Y, Aral T, Kikuchi M, Nakajima S, Nakamura H. Effect of low-intensity argon laser irradiation on mitochondrial respiration. *Lasers Surg Med* 1994; 15: 191-9.
- [13] Urist MR. Bone: formation by autoinduction. *Science* 1965; 150: 893-9.
- [14] Groeneveld E, Burger E. Bone morphogenetic proteins in human bone regeneration. *Eur J Endocrinol* 2000; 142: 9-21.
- [15] Urist MR, Mikulski AJ. A soluble bone morphogenetic protein extracted from bone matrix with a mixed aqueous and nonaqueous solvent. *Exp Biol Med* 1979; 162: 48-53.
- [16] Bessho K, Konishi Y, Kaihara S, Fujimura K, Okubo Y, Iizuka T. Bone induction by Escherichia coli-derived recombinant human bone morphogenetic protein-2 compared with Chinese hamster ovary cell-derived recombinant human bone morphogenetic protein-2. *Br J Oral Maxillofac Surg* 2000; 38: 645-9.
- [17] Hou R, Chen F, Yang Y, Cheng X, Gao Z, Yang HO, Wu W, Mao T. Comparative study between coral-mesenchymal stem cells-rhBMP-2 composite and auto-bone-graft in rabbit critical-sized cranial defect model. *J Biomed Mater Res A* 2007; 80: 85-93.
- [18] Siéssere S, de Sousa LG, Issa JP, Iyomasa MM, Pitol DL, Barbosa AP, Semprini M, Sebald W, Bentley MV, Regalo SC. Application of low-level laser irradiation (LLLI) and rhBMP-2 in critical bone defect of ovariectomized rats: histomorphometric evaluation. *Photomed Laser Surg* 2011; 29: 453-8.
- [19] Gerbi ME, Marques AM, Ramalho LM, Ponzi EA, Carvalho CM, Santos Rde C, Oliveira PC, Nória M, Pinheiro AL. Infrared laser light further improves bone healing when associated with bone morphogenic proteins: an in vivo study in a rodent model. *Photomed Laser Surg* 2008; 26: 55-60.
- [20] Rosa AP, de Sousa LG, Regalo SC, Issa JP, Barbosa AP, Pitol DL, de Oliveira RH, de Vasconcelos PB, Dias FJ, Chimello DT, Siéssere S. Effects of the combination of low-level laser irradiation and recombinant human bone morphogenetic protein-2 in bone repair. *Lasers Med Sci* 2012; 27: 971-7.
- [21] Kuvat SV, Çizmecci O, Biçer A, Marşan G, Hocaoglu E, Bilgiç B, Emekli U. Improving bony stability in maxillofacial surgery: use of osteogenic materials in patients with profound (≥ 5 mm) maxillary advancement, a clinical study. *J Plast Reconstr Aesthet Surg* 2009; 62: 639-45.
- [22] Feifel H. Knochenregeneration in Pro Osteon 500 allein und in Kombination mit Colloss im Patellagleitlagermodell des Kaninchens. *Mund Kiefer Gesichtschir* 2000; S527-S30.
- [23] Nagai N, Qin CL, Nagatsuka H, Inoue M, Ishiwari Y. Age effects on ectopic bone formation induced by purified bone morphogenetic protein. *Int J Oral Maxillofac Surg* 1999; 28: 143-50.
- [24] Boyne PJ, Lilly LC, Marx RE, Moy PK, Nevins M, Spagnoli DB, Triplett RG. De novo bone induction by recombinant human bone morphogenetic protein-2 (rhBMP-2) in maxillary sinus floor augmentation. *J Oral Maxillofac Surg* 2005; 63: 1693-707.
- [25] Ripamonti U, Crooks J, Petit JC, Rueger DC. Periodontal tissue regeneration by combined applications of recombinant human osteogenic protein-1 and bone morphogenetic protein-2. A pilot study in Chacma baboons (*Papio ursinus*). *Eur J Oral Sci* 2001; 109: 241-8.
- [26] Inoda H, Yamamoto G, Hattori T. rh-BMP2-induced ectopic bone for grafting critical size defects: a preliminary histological evaluation in rat calvariae. *Int J Oral Maxillofac Surg* 2007; 36: 39-44.
- [27] Guzzardella G, Fini M, Torricelli P, Giavaresi G, Giardino R. Laser stimulation on bone defect healing: an in vitro study. *Lasers Med Sci* 2002; 17: 216-20.
- [28] Iyomasa DM, Garavelo I, Iyomasa MM, Watanabe I-s, Issa JPM. Ultrastructural analysis of the low level laser therapy effects on the lesioned anterior tibial muscle in the gerbil. *Micron* 2009; 40: 413-8.
- [29] Pires Oliveira DA, de Oliveira RF, Zangaro RA, Soares CP. Evaluation of low-level laser therapy of osteoblastic cells. *Photomed Laser Surg* 2008; 26: 401-4.
- [30] Stein E, Koehn J, Sutter W, Wendtlandt G, Wanschitz F, Thurnher D, Baghestanian M, Turhani D. Initial effects of low-level laser therapy on growth and differentiation of human osteoblast-like cells. *Wien Klin Wochenschr* 2008; 120: 112-7.
- [31] Fávoro-Pípi E, Feitosa SM, Ribeiro DA, Bossini P, Oliveira P, Parizotto NA, Renno AC. Comparative study of the effects of low-intensity pulsed ultrasound and low-level laser therapy on bone defects in tibias of rats. *Lasers Med Sci* 2010; 25: 727-32.
- [32] Garavello-Freitas I, Baranauskas V, Joazeiro P, Padovani C, Dal Pai-Silva M, da Cruz-Höfling MA. Low-power laser irradiation improves histomorphometrical parameters and bone matrix organization during tibia wound healing in rats. *J Photochem Photobiol B* 2003; 70: 81-9.
- [33] Blaya DS, Guimarães MB, Pozza DH, Weber JB, de Oliveira MG. Histologic study of the effect of

Effects of low-level laser on graft healing

- laser therapy on bone repair. *J Contemp Dent Pract* 2008; 9: 41-8.
- [34] Kawasaki K, Shimizu N. Effects of low-energy laser irradiation on bone remodeling during experimental tooth movement in rats. *Lasers Surg Med* 2000; 26: 282-91.
- [35] Saito S, Shimizu N; of Dentistry FNUS. Stimulatory effects of low-power laser irradiation on bone regeneration in midpalatal suture during expansion in the rat. *Am J Orthod Dentofacial Orthop* 1997; 111: 525-32.
- [36] Walsh L. The current status of low level laser therapy in dentistry, Part 1. Soft tissue applications. *Aust Dent J* 1997; 42: 247-54.
- [37] Webb C, Dyson M. The effect of 880 nm low level laser energy on human fibroblast cell numbers: a possible role in hypertrophic wound healing. *J Photochem Photobiol B* 2003; 70: 39-44.
- [38] Ozcelik O, Cenk Haytac M, Seydaoglu G. Enamel matrix derivative and low-level laser therapy in the treatment of intra-bony defects: a randomized placebo-controlled clinical trial. *J Clin Periodontol* 2008; 35: 147-56.
- [39] Ozturan S, Durukan SA, Ozcelik O, Seydaoglu G, Cenk Haytac M. Coronally advanced flap adjunct with low intensity laser therapy: a randomized controlled clinical pilot study. *J Clin Periodontol* 2011; 38: 1055-62.
- [40] Lirani-Galvão A, Lazaretti-Castro M, Portero-Muzy N, Bergamaschi C, Silva O, Carvalho A, Delmas PD, Chavassieux P. Is nitric oxide a mediator of the effects of low-intensity electrical stimulation on bone in ovariectomized rats? *Calcif Tissue Int* 2010; 87: 52-9.
- [41] Cerqueira A, Silveira RL, Oliveira MG, Sant'ana Filho M, Heitz C. Bone tissue microscopic findings related to the use of diode laser (830 etam) in ovine mandible submitted to distraction osteogenesis. *Acta Cir Bras* 2007; 22: 92-7.
- [42] AboElsaad NS, Soory M, Gadalla LM, Ragab LI, Dunne S, Zalata KR, Louca C. Effect of soft laser and bioactive glass on bone regeneration in the treatment of infra-bony defects (a clinical study). *Lasers Med Sci* 2009; 24: 387-95.
- [43] Angeletti P, Pereira MD, Gomes HC, Hino CT, Ferreira LM. Effect of low-level laser therapy (GaAlAs) on bone regeneration in midpalatal anterior suture after surgically assisted rapid maxillary expansion. *Oral Surg Oral Med Oral Pathol Oral Radiol Endod* 2010; 109: e38-e46.
- [44] Matsumoto MA, Ferino RV, Monteleone GF, Ribeiro DA. Low-level laser therapy modulates cyclo-oxygenase-2 expression during bone repair in rats. *Lasers Med Sci* 2009; 24: 195-201.
- [45] Bouvet-Gerbettaz S, Merigo E, Rocca JP, Carle GF, Rochet N. Effects of low-level laser therapy on proliferation and differentiation of murine bone marrow cells into osteoblasts and osteoclasts. *Lasers Surg Med* 2009; 41: 291-7.
- [46] Vescovi P, Merigo E, Meleti M, Fornaini C, Namour S, Manfredi M. Nd: YAG laser biostimulation of bisphosphonate-associated necrosis of the jawbone with and without surgical treatment. *Br J Oral Maxillofac Surg* 2007; 45: 628-32.
- [47] Demir T, Kara C, Özbek E, Kalkan Y. Evaluation of Neodymium-Doped Yttrium Aluminium Garnet laser, scalpel incision wounds, and low-level laser therapy for wound healing in rabbit oral mucosa: A pilot study. *Photomed Laser Surg* 2010; 28: 31-7.
- [48] Byrnes KR, Barna L, Chenault VM, Waynant RW, Ilev IK, Longo L, Miracco C, Johnson B, Anders JJ. Photobiomodulation improves cutaneous wound healing in an animal model of type II diabetes. *Photomed Laser Surg* 2004; 22: 281-90.
- [49] Takeda Y. Irradiation effect of low-energy laser on rat submandibular salivary gland. *J Oral Pathol Med* 1988; 17: 91-4.
- [50] Amorim JC, de Sousa GR, de Barros Silveira L, Prates RA, Pinotti M, Ribeiro MS. Clinical study of the gingiva healing after gingivectomy and low-level laser therapy. *Photomed Laser Surg* 2006; 24: 588-94.
- [51] Merli LA, Santos MT, Genovese WJ, Faloppa F. Effect of low-intensity laser irradiation on the process of bone repair. *Photomed Laser Surg* 2005; 23: 212-5.
- [52] Karu T, Pyatibrat L, Kalendo G. Irradiation with He-Ne laser increases ATP level in cells cultivated in vitro. *J Photochem Photobiol B* 1995; 27: 219-23.
- [53] Renno AC, de Moura FM, dos Santos NS, Tirico RP, Bossini PS, Parizotto NA. Effects of 830-nm laser light on preventing bone loss after ovariectomy. *Photomed Laser Surg* 2006; 24: 642-5.
- [54] Khadra M, Kasem N, Haanæs HR, Ellingsen JE, Lyngstadaas SP. Enhancement of bone formation in rat calvarial bone defects using low-level laser therapy. *Oral Surg Oral Med Oral Pathol Oral Radiol Endod* 2004; 97: 693-700.