

Original Article

Ulnar osteotomy for a chronic radial head dislocation neglected for 15 years and secondary ulnocarpal impaction syndrome: a case report and a literature review

Jinlu Yu¹, Yongning Xia², Bin Zhao², Dong Zhu², Tiecheng Yu²

¹Department of Neurosurgery, ²Department of Orthopedics, The First Hospital of Jilin University, Changchun, China

Received April 4, 2016; Accepted July 3, 2016; Epub August 15, 2016; Published August 30, 2016

Abstract: One of the most frequently overlooked injuries is neglected radial head dislocation, which is currently known as Monteggia fracture dislocation. Chronic radial head dislocation can result in elbow stiffness, deformity, persistent pain, and instability. In this report, we described an unusual case involving chronic radial head dislocation that was neglected for 15 years and secondary ulnocarpal impaction syndrome. Chronic radial head dislocation rarely leads to ulnocarpal impaction syndrome. In such cases, it is necessary to concurrently manage both the chronic radial head dislocation and the secondary ulnocarpal impaction syndrome. Our case demonstrated that good reduction can be achieved 15 years after radial head dislocation even after secondary ulnocarpal impaction syndrome had developed. Proximal ulnar osteotomy was successfully performed to correct the chronic radial head dislocation and secondary ulnocarpal impaction syndrome. Excellent results were obtained, including restored stability of the right elbow and full ranges of flexion-extension of the right elbow and rotation of the right forearm.

Keywords: Ulnar osteotomy, radial head dislocation, ulnocarpal impaction syndrome

Introduction

Neglected radial head dislocation is one of the most frequently overlooked injuries [1], especially in children, who typically exhibit plastic deformation or green-stick fractures of the ulna [2]. Neglected radial head dislocation is currently known as Monteggia fracture dislocation, which is a relatively rare injury observed in approximately 1% of all pediatric forearm fractures [3]. Monteggia fractures are defined as all ulnar fractures associated with dislocation of the radial head [4]. Because children's bones are elastic, ulnar injuries associated with children's Monteggia fractures sometimes present as plastic deformation or green-stick fractures [5]. Such manifestations of children's Monteggia fractures are often treated using a conservative approach; thus, the associated radial head dislocations of these fractures are easily missed [2]. Reports have indicated that approximately 25-50% of these injuries might initially

be missed due to the limited experience of the primary health care provider [2, 6, 7].

Chronic radial head dislocation can result in elbow stiffness, deformity, persistent pain, and instability; in rare cases, ulnocarpal impaction syndrome can develop [4, 8]. Ulnocarpal impaction syndrome has been defined as impaction of the distal ulnar head against the triangular fibrocartilage complex (TFCC) and the ulnar-sided carpus [9-11]. In this case, the patient suffered from ulnocarpal impaction syndrome secondary to the chronic radial head dislocation. The affected radius had become relatively shortened, and the discrepancy between the radius and ulna was detectable by radiography (**Figure 1**). In such cases, it is necessary to concurrently manage the chronic radial head dislocation and the secondary ulnocarpal impaction syndrome. Regarding chronic radial dislocation, treatment options include open reduction and annular ligament reconstruction; open reduc-

Radial head dislocation and secondary ulnocarpal impaction syndrome

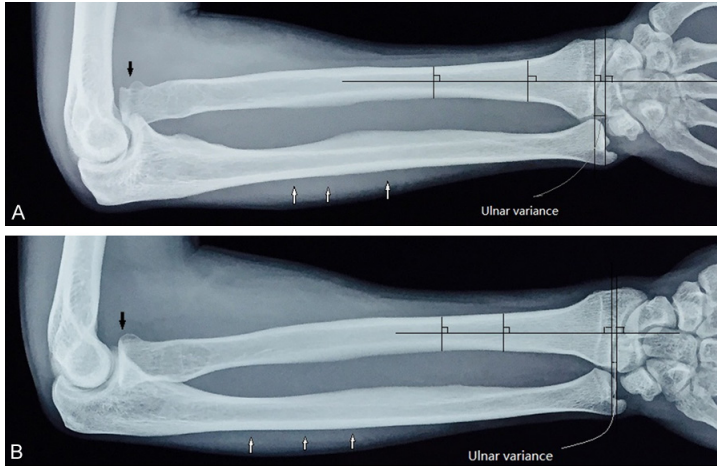


Figure 1. Neutral rotation X-ray images of the 23-year-old patient's arm at the time of diagnosis, obtained with the wrist neutral, the forearm pronated, the elbow flexed 90 degrees and the shoulder abducted 90 degrees. A. The right arm film reveals an abnormal anterior ulnar bow (white vertical arrows) and loss of the radiocapitellar relationship (black vertical arrow). The right ulnar variance is positive, indicating shortening of the distal radius relative to the distal ulna. B. The left arm film reveals a normal anterior ulnar bow (white vertical arrows) and a normal radiocapitellar relationship (black vertical arrow). The left ulnar variance is negative, indicating that the distal radius is slightly longer than the distal ulna. Note: 1. The ulnar bow line. This line, which is drawn between the distal ulna and the olecranon, defines the ulna bow. A sign of ulnar bow abnormality is greater than 1 mm of deviation of the ulnar border from the reference line. 2. Ulnar variance is measured using perpendiculars. Two lines perpendicular to the long axis of the radius are drawn through the distal ulnar aspect of the radial volar cortical rim and the dorsal rim of the distal ulna. The distance between these lines is measured and regarded as the ulnar variance.

tion and ulnar osteotomy; radial osteotomy; and radial head excision [7, 12-15]. Regarding ulnocarpal impaction syndrome, the gold standard treatment is distal ulnar shortening osteotomy [16-18]. In this report, we described an unusual case involving chronic radial head dislocation that was neglected for 15 years and secondary ulnocarpal impaction syndrome to highlight the importance of ulnar osteotomy, which simultaneously treated the chronic radial head dislocation and the secondary ulnocarpal impaction syndrome.

Case report

A 23-year-old man presented at our polyclinic with complaints of right elbow stiffness, deformity, persistent pain, instability, and right ulnar-sided wrist pain. These symptoms had been ongoing for approximately 15 years and became worse in association with activities involving ulnar deviation, extension, and/or compres-

sion. Approximately 15 years ago, his right arm hit the ground when he fell. At that time, his right elbow became stiff and felt uncomfortable and unstable; in addition, right ulnar-sided wrist pain was experienced when moving the right elbow and wrist. Over the prior 3 years, his symptoms had worsened. On clinical examination, his right elbow exhibited a cubitus deformity of 15°, which could be increased to 25° with the application of valgus force. The patient had a full range of rotation for both forearms, but his flexion-extension range of the right elbow (110°) was reduced compared with that of the left elbow (150°). On local examination, the prominently dislocated right radial head could be palpated in the antecubital fossa, valgus instability was observed in the right elbow under stress, and tenderness was detected in the ulnocarpal portion of the right wrist. Loading the ulnocarpal joint during ulnar deviation and compression created pain in the right ulnar-side wrist. The patient's neurovascular examination results were normal.

Radiographs revealed anterior bow deformation of the right ulna and right ulnar variance (**Figure 1**). Ulnar variance, which refers to the relative lengths of the distal articular surfaces of the radius and ulna, is classified as neutral (both articular surfaces the same length), positive (the ulnar surface is longer), or negative (the ulnar surface is shorter) (**Figure 1**). CT was used to visualize the right dysplastic radial head (**Figure 2**). Based on examination results and medical history, a diagnosis of a chronic radial head dislocation neglected for 15 years was determined.

Three days after the patient's admission to the hospital, ulnar osteotomy and bone grafting of the osteotomy site were performed, with contoured-plate fixation of the osteotomy site (**Figure 3**). A Kocher approach was used, with the skin incision extended along the ulnar shaft. First, the ulnar shaft was exposed, although the radiocapitellar joint was not expos-

Radial head dislocation and secondary ulnocarpal impaction syndrome

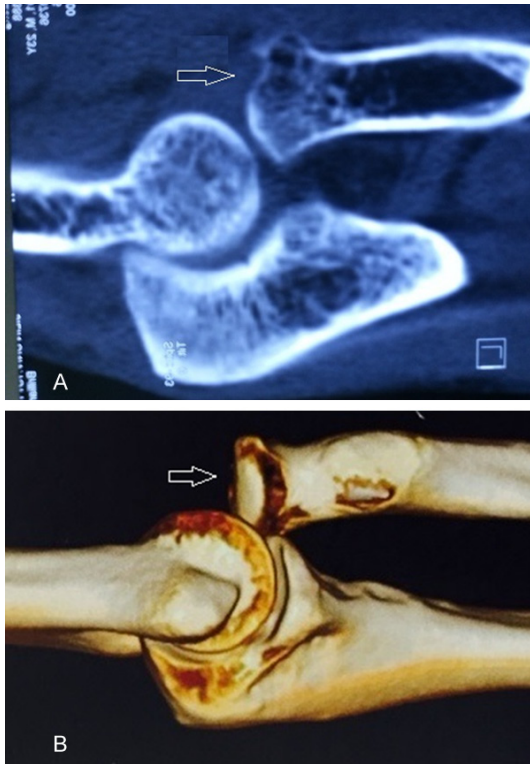

Figure 2. Hypoplasia of the right radial capitellum. Two-dimensional CT (A) and three-dimensional CT (B) indicate that the right radial capitellum had become deformed (open arrows).

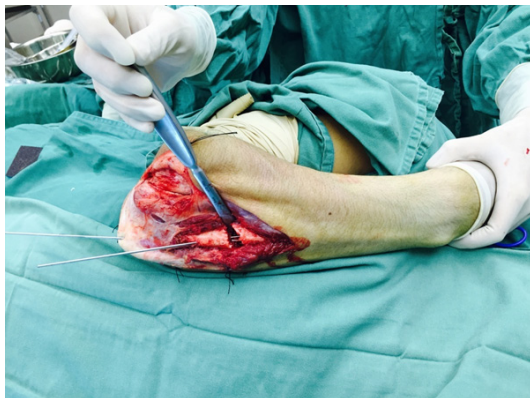

Figure 3. The ulnar osteotomy. A Kocher approach was used, with the skin incision extended along the ulnar shaft. An oblique osteotomy was performed at the proximal metaphysis of the ulnar shaft. The osteotomy site was distracted and angulated to overcorrect the deformity, which was temporarily fixed using two K-wires.

ed by the incision. An oblique osteotomy was performed at the proximal metaphysis of the ulnar shaft. The osteotomy site was distracted and angulated to overcorrect the deformity of the right ulna. The osteotomy site was tempo-

rarily fixed using two K-wires (**Figure 4**). The optimum angulation for the ulnar osteotomy site was guided by the reduction of the radial head, which was confirmed by fluoroscopy. Because the radial head was easily reduced and maintained via ulnar osteotomy, the radiocapitellar joint was not exposed, and the annular ligament was not reconstructed. A locking plate was contoured to fit over the osteotomy site and fixed with 6 screws (**Figure 3**). Because the ulna was lengthened to avoid excessive pressure on the radial head, there was a gap at the osteotomy site (**Figure 4**). Therefore, iliac bone grafting was performed, and the gap was filled with the iliac bone graft.

A postoperative cast with the elbow in 90° of flexion and the forearm in neutral rotation was applied for 3 weeks; subsequently, self-managed rehabilitation was initiated. The duration of follow-up was 12 months. The patient returned to full activity without pain in three months. He exhibited full ranges of flexion-extension of the right elbow and rotation of the right forearm (**Figure 5**).

Discussion

This patient's long-standing dislocation of the right radial head followed trauma involving plastic deformation of the ulna. The radial head had become dysplastic due to the 15-year-old radial head dislocation. In addition, subluxation of the right distal radioulnar joint occurred. Because the stability of the elbow joint depends on joint congruity, the reduction of the radial head plays an extremely important role in the stability of the elbow joint [7]. The persistence of chronic radial head dislocation mainly results from anterior-bow deformation of the ulna and a relative decrease in ulnar length [14, 19-21]. Thus, ulnar osteotomy is the key procedure for achieving and maintaining reduction because this operation can correct anterior-bow deformation of the ulna and simultaneously lengthen the ulna. The correction of anterior-bow deformity of the ulna can effectively widen the interosseous membrane, increasing reduction force to bring the radial head back to an acceptable position. Ulnar lengthening also effectively avoids excessive pressure on the radial head.

In this case, although a Kocher approach was used, neither open reduction nor annular ligament reconstruction was performed. If the soft tissues in the radiocapitellar joint occupied the

Radial head dislocation and secondary ulnocarpal impaction syndrome

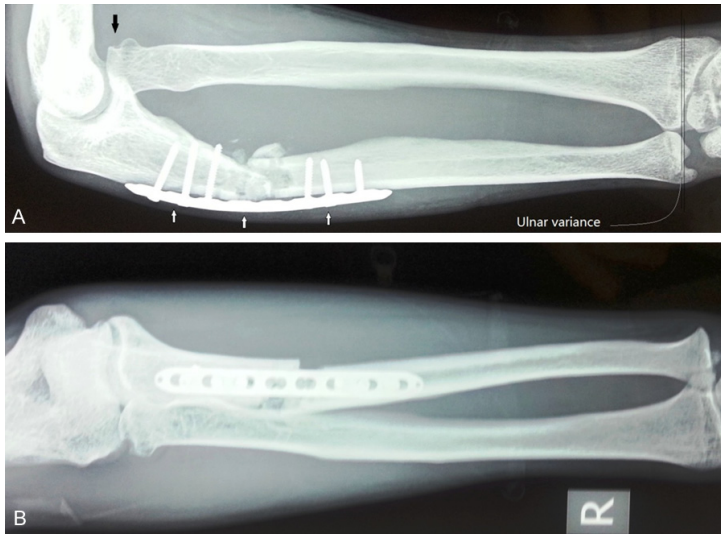


Figure 4. Six-week postoperative films of the right antero-posterior and lateral elbow. A. The right lateral arm film indicates that the abnormal anterior bow of the ulna had been corrected (white vertical arrows) and that the dislocation in the radiocapitellar relationship had been reduced (black vertical arrow). The right ulnar variance had become negative, indicating that the distal radius is slightly longer than the distal ulna. B. The right antero-posterior film.

position of the radial head and ulnar osteotomy could not effectively reduce the radial head, we would have been forced to expose the radiocapitellar joint to clear these tissues and reduce the radial head. If ulnar osteotomy can achieve and maintain reduction of the radial head, it is unnecessary to perform either open reduction or annular ligament reconstruction again because ulnar osteotomy is sufficient for achieving and maintaining reduction. Moreover, after the operation, the additional 3 weeks of cast-induced elbow immobilization allows for reconstruction of the ligaments around the radial head, a process that enhances stabilization of the radial head. Certain surgeons recommend excision of a dislocated radial head in adult patients [22]. This approach results in elbow instability and proximal migration of the radius, which causes ulnar-plus variance and wrist pain [23, 24]. In our opinion, this approach should be avoided whenever possible.

In addition, the patient suffered from right ulnocarpal impaction syndrome resulting from right radial head dislocation. Ulnocarpal impaction syndrome has been described as an impaction of the distal ulnar head against the TFCC and the ulnar-sided carpus [10]. This condition can be idiopathic or posttraumatic. Posttraumatic ulnocarpal impaction syndrome typically results from malunion of a fracture of the distal

radius or premature closure of the radial epiphysis. In relatively rare cases, ulnocarpal impaction syndrome secondary to chronic radial head dislocation is observed. In the described case, due to right radial head dislocation, the right radial head was not in contact with the capitulum of the humerus. Without the support of this capitulum, the radius can become relatively short when the wrist bears pressing loads. Positive ulnar variance between the radius and ulna was detected by radiography (Figure 1). Due to this variance, the distal ulna impinged on the lunate and triquetrum and caused pain during activities involving ulnar deviation, extension, and/or compression. This pain was recreated by loading the ulnocarpal joint in ulnar deviation and compression. Ulnocarpal impaction syndrome results in

degeneration of the TFCC, chondromalacia of the lunate and ulnar head and lunotriquetral ligament lesions. The key to managing ulnocarpal impaction is to correct the positive ulnar variance and thereby relieve the excessive load on the ulnocarpal joint [18]. Distal ulnar shortening osteotomy is typically selected to treat ulnocarpal impaction syndrome [17, 25]. In the described case, because the patient's ulnocarpal impaction syndrome was secondary to chronic radial head dislocation, proximal ulnar osteotomy was performed. Using this approach, reduction of the radial head was effectively achieved and maintained, positive ulnar variance was addressed, and the excessive load on the ulnocarpal joint was relieved.

A prior report described a case of chronic radial head dislocation neglected for 6 years that was satisfactorily corrected via surgical operation [26]. Typically, radial head dislocations that are treated within a year after injury can be successfully corrected [7, 23]. Proximal ulnar osteotomy with open reduction is the most common surgical treatment for such dislocations. Our case demonstrates that good reduction can be achieved 15 years after radial head dislocation, even after secondary ulnocarpal impaction syndrome had developed. Proximal ulnar osteotomy was successfully performed to cor-

Radial head dislocation and secondary ulnocarpal impaction syndrome

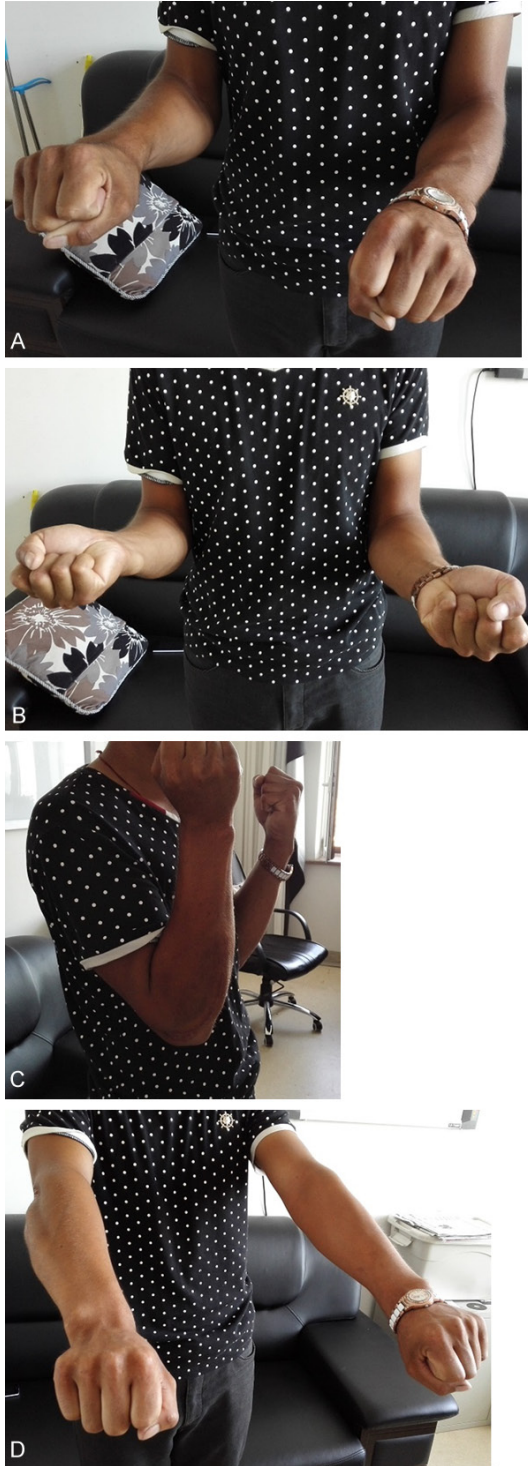

Figure 5. The patient exhibited excellent range of motion of the right arm at the 1-year follow-up after his ulnar osteotomy. A. Pronation. B. Supination. C. Flexion. D. Extension.

rect chronic radial head dislocation and secondary ulnocarpal impaction syndrome. Excellent results were obtained, including

restored stability of the right elbow and full ranges of flexion-extension of the right elbow and rotation of the right forearm.

Acknowledgements

This study was supported in part by grants 11432016 (Dong Zhu), 11272134 (Dong Zhu), 81172183 (Tiecheng Yu) and 31470932 (Tiecheng Yu) from the National Natural Science Foundation of China.

Disclosure of conflict of interest

None.

Address correspondence to: Tiecheng Yu, Department of Orthopedics, The First Hospital of Jilin University, Changchun 130021, China. E-mail: tiechengyu@163.com

References

- [1] Rajasekaran S, Venkatadass K. "Sliding angulation osteotomy": preliminary report of a novel technique of treatment for chronic radial head dislocation following missed Monteggia injuries. *Int Orthop* 2014; 38: 2519-24.
- [2] Datta T, Chatterjee N, Pal AK, Das SK. Evaluation of outcome of corrective ulnar osteotomy with bone grafting and annular ligament reconstruction in neglected monteggia fracture dislocation in children. *J Clin Diagn Res* 2014; 8: LC01-4.
- [3] Stitgen A, McCarthy JJ, Nemeth BA, Garrels K, Noonan KJ. Ulnar fracture with late radial head dislocation: delayed Monteggia fracture. *Orthopedics* 2012; 35: e434-7.
- [4] Kazakos CJ, Galanis VG, Verettas DA, Dimitrakopoulou A, Polychronidis A, Simopoulos C. Unusual patterns of Monteggia fracture-dislocation. *J Orthop Surg Res* 2006; 1: 12.
- [5] Ruchelsman DE, Klugman JA, Madan SS, Chorney GS. Anterior dislocation of the radial head with fractures of the olecranon and radial neck in a young child: a Monteggia equivalent fracture-dislocation variant. *J Orthop Trauma* 2005; 19: 425-8.
- [6] Ha T, Grant S, Huntley JS. Monteggia type IV fracture in a child with radial head dislocation irreducible by closed means: a case report. *BMC Res Notes* 2014; 7: 539.
- [7] Goyal T, Arora SS, Banerjee S, Kandwal P. Neglected Monteggia fracture dislocations in children: a systematic review. *J Pediatr Orthop B* 2015; 24: 191-9.
- [8] Hurst LC, Dubrow EN. Surgical treatment of symptomatic chronic radial head dislocation: a

Radial head dislocation and secondary ulnocarpal impaction syndrome

- neglected Monteggia fracture. *J Pediatr Orthop* 1983; 3: 227-30.
- [9] Krimmer H, Unglaub F, Langer MF, Spies CK. The distal radial decompression osteotomy for ulnar impingement syndrome. *Arch Orthop Trauma Surg* 2016; 136: 143-8.
- [10] Zahiri H, Zahiri CA, Ravari FK. Ulnar styloid impingement syndrome. *Int Orthop* 2010; 34: 1233-7.
- [11] Watson HK, Brown RE. Ulnar impingement syndrome after Darrach procedure: treatment by advancement lengthening osteotomy of the ulna. *J Hand Surg Am* 1989; 14: 302-6.
- [12] Jarrett DY, Walters MM, Kleinman PK. Prevalence of Capitellar Osteochondritis Dissecans in Children With Chronic Radial Head Subluxation and Dislocation. *AJR Am J Roentgenol* 2016; 206: 1329-34.
- [13] Tan L, Li YH, Sun DH, Zhu D, Ning SY. Modified technique for correction of isolated radial head dislocation without apparent ulnar bowing: a retrospective case study. *Int J Clin Exp Med* 2015; 8: 18197-202.
- [14] Bor N, Rubin G, Rozen N, Herzenberg JE. Chronic anterior monteggia lesions in children: report of 4 cases treated with closed reduction by ulnar osteotomy and external fixation. *J Pediatr Orthop* 2015; 35: 7-10.
- [15] Liu T, Zhang X, Li Z, Zeng W. Management of chronic radial head dislocation associated with segment bone defect in ulna after osteomyelitis. *J Trauma Acute Care Surg* 2012; 73: 1014-7.
- [16] Lautenbach M, Millrose M, Schmidt NS, Zach A, Eichenauer F, Eisenschenk A. Ulnocarpal impaction syndrome: treatment with a transverse ulnar shortening osteotomy from an ulnodorsal approach. *Arch Orthop Trauma Surg* 2014; 134: 881-5.
- [17] de Runz A, Pauchard N, Sorin T, Dap F, Dautel G. Ulna-Shortening Osteotomy: Outcome and Repercussion of the Distal Radioulnar Joint Osteoarthritis. *Plast Reconstr Surg* 2016; 137: 175-84.
- [18] Yin HW, Qiu YQ, Shen YD, Xu JG, Gu YD, Xu WD. Arthroscopic distal metaphyseal ulnar shortening osteotomy for ulnar impaction syndrome: a different technique. *J Hand Surg Am* 2013; 38: 2257-62.
- [19] Agarwal A. "Sliding angulation osteotomy" for chronic radial head dislocation following missed Monteggia injuries. *Int Orthop* 2015; 39: 595.
- [20] Kim HT, Ahn TY, Jang JH, Kim KH, Lee SJ, Jung DY. A Graphic Overlay Method for Selection of Osteotomy Site in Chronic Radial Head Dislocation: An Evaluation of 3D-printed Bone Models. *J Pediatr Orthop* 2015; [Epub ahead of print].
- [21] Song KS, Ramnani K, Bae KC, Cho CH, Lee KJ, Son ES. Indirect reduction of the radial head in children with chronic Monteggia lesions. *J Orthop Trauma* 2012; 26: 597-601.
- [22] Horii E, Nakamura R, Koh S, Inagaki H, Yajima H, Nakao E. Surgical treatment for chronic radial head dislocation. *J Bone Joint Surg Am* 2002; 84-A: 1183-8.
- [23] Bell SN, Morrey BF, Bianco AJ. Chronic posterior subluxation and dislocation of the radial head. *J Bone Joint Surg Am* 1991; 73: 392-6.
- [24] Rodgers WB, Waters PM, Hall JE. Chronic Monteggia lesions in children. Complications and results of reconstruction. *J Bone Joint Surg Am* 1996; 78: 1322-9.
- [25] Schmidle G, Arora R, Gabl M. Ulnar shortening with the ulna osteotomy locking plate. *Oper Orthop Traumatol* 2012; 24: 284-92.
- [26] Freedman L, Luk K, Leong JC. Radial head reduction after a missed Monteggia fracture: brief report. *J Bone Joint Surg Br* 1988; 70: 846-7.