

Original Article

Prenatal ultrasound detection of fetal malformations in Inner Mongolia region

Yu Wang¹, Yan Bai², Hongjuan Zhao², Chunhui Li³, Lixin He³

Departments of ¹Gynecology and Obstetrics, ³Ultrasound, Inner Mongolia Medical University Affiliated Hospital, Hohhot, China; ²Graduate School of Inner Mongolia Medical University, Hohhot, China

Received February 4, 2016; Accepted May 2, 2016; Epub September 15, 2016; Published September 30, 2016

Abstract: Objectives: Ultrasonic rates of fetal malformation and prenatal soft-marker positivity in Mongolian and Han populations were investigated through a standardized screening protocol. Methods: A retrospective study of 7753 pregnancies (Mongolian, 1314; Han, 5751; others, 688) was conducted in our hospital, examining prenatal fetal ultrasound tests performed between September, 2011 and February, 2013. All ultrasonography scan were done during weeks 17-34 of gestation. Results: Of these pregnancies (N=7753; fetuses, 7955), 396 (4.98%) instances of fetal malformation were detected, 322 (4.05%) through ultrasonic soft markers. Instances of fetal malformation totaled 50 (3.72%) and 315 (5.33%), respectively in Mongolian and Han ethnic subsets, with ultrasound soft-marker positivity in 59 (4.39%) and 245 (4.15%) fetuses, respectively. Focally intense cardiac echogenicity and mild expansion of renal pelvis were common positive signs by ultrasound. Central nervous system, cardiovascular, and genitourinary malformations predominated. Conclusions: The array and rate of fetal malformations detected by prenatal ultrasound corresponded closely with regional birth defect data. Mongolian and Han ethnic groups showed no statistically significant differences in prenatal fetal malformation detection rate or ultrasonic soft-marker positivity.

Keywords: Ultrasound, fetal malformations, Mongolian, prenatal diagnosis

Introduction

The autonomous region of Inner Mongolia has one of the higher rates of birth defects in China [1]. A standardized protocol of prenatal ultrasound testing may improve detection of congenital malformations, helping to diminish fetal deaths in the perinatal period and ultimately improve the quality of births through efforts to reduce birth defect rates. By analyzing 7955 prenatal fetal ultrasound studies, this investigation assessed the utility of a standardized prenatal ultrasound protocol, comparing rates of ultrasound-detected defects in various maternal age groups and exploring potential differences in Mongolian and Han ethnic subsets.

Materials and methods

Ultrasound examination

A total of 7753 pregnancies (7955 fetuses) in women aged 19-52 years (average, 29.73

years) were subjected to a standard protocol of prenatal testing during 17-38 weeks of gestation in our Hospital. All tests were conducted between August, 2011 and February, 2013, using an iU22 unit (Philips Healthcare, Bothell, WA, USA) and color Doppler imaging (GE E8; GE Healthcare, Little Chalfont, Buckinghamshire, UK) to perform transabdominal examinations in supine position. In each instance, images needed, main anatomic structures, and pertinent measurements were recorded.

In accord with practice guidelines [2] of the International Society of Ultrasound in Obstetrics and Gynecology (ISUOG), studies were classified by gestational age as grade I (14-17 weeks), grade II (28-32 weeks), or grade III (18-24 weeks) obstetric examinations. Degree of detail varied by examination classification, with grade II (also known the systemic fetal ultrasound or fetal malformation screening) providing the greatest detail. If cardiac abnormalities were detected, patients were referred for fetal echocardiography. The study was approved by the

Fetal malformation detection in Mongolian

Table 1. Fetal malformation statistics

| Organ system | Total | Malformation rate % | Nature of malformations (n) | |
|-----------------|-------|---------------------|-----------------------------|----------|
| | | | Isolated | Multiple |
| Central nervous | 105 | 1.32 | 59 | 46 |
| Skeletal | 42 | 0.53 | 15 | 27 |
| Digestive | 28 | 0.35 | 13 | 15 |
| Cardiovascular | 80 | 1.01 | 43 | 37 |
| Urinary | 59 | 0.74 | 42 | 17 |
| Respiratory | 16 | 0.20 | 14 | 2 |
| Facial | 49 | 0.62 | 26 | 23 |
| Reproductive | 11 | 0.14 | 4 | 7 |
| Other | 112 | 1.41 | 59 | 53 |

Table 2. Ultrasonographic soft-marker positivity rates

| Soft marker | Positivity n (%) | Distribution | | |
|-------------------------|------------------|---------------------|--------------|--------------|
| | | Location | Isolated (n) | Multiple (n) |
| Ventricular plaque | 118 (1.48) | Double ventricular | 2 | |
| | | Left ventricular | 113 | 14 |
| | | Right ventricular | 3 | 2 |
| Mild pyelectasis | 100 (1.26) | Double pelvis | 70 | 7 |
| | | Left pelvis | 15 | 1 |
| | | Right pelvis | 15 | 2 |
| Choroid plexus cysts | 22 (0.28) | Bilateral ventricle | 11 | 1 |
| | | Left ventricle | 7 | 2 |
| | | Right ventricle | 4 | |
| Ventricular expansion | 21 (0.26) | Bilateral ventricle | 16 | 7 |
| | | Left ventricle | 4 | 1 |
| | | Right ventricle | 1 | |
| Cavum vergae | 42 (0.53) | | | 12 |
| Single umbilical artery | 20 (0.25) | | | 4 |

28 fetuses with two positive soft markers; 1 fetus with three.

Table 3. Comparison of fetal malformation and soft-marker positivity rates by ethnicity

| Ultrasonography | Mongolian n (%) | Han n (%) | χ^2 | P value |
|-----------------|-----------------|------------|----------|---------|
| Malformations | 50 (3.72) | 315 (5.33) | 2.275 | 0.131 |
| Soft markers | 59 (4.39) | 245 (4.15) | 0.029 | 0.865 |

Institute Research Ethics Committee of the Hospital.

Data collection and statistical analysis

Ultrasonic soft markers of fetal malformation are stipulated [3] as following: 1) echogenic intracardiac focus (EICF) is an isolated finding, similar to bony echogenic dots, without acous-

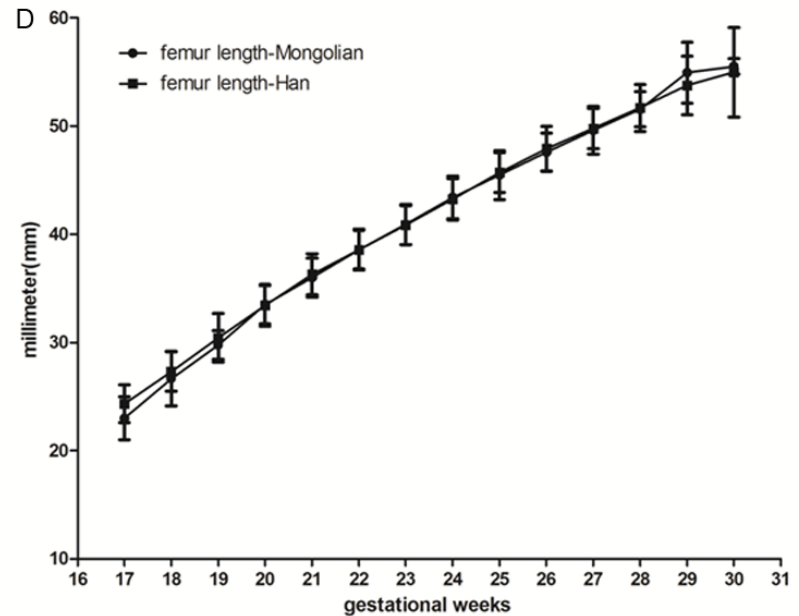
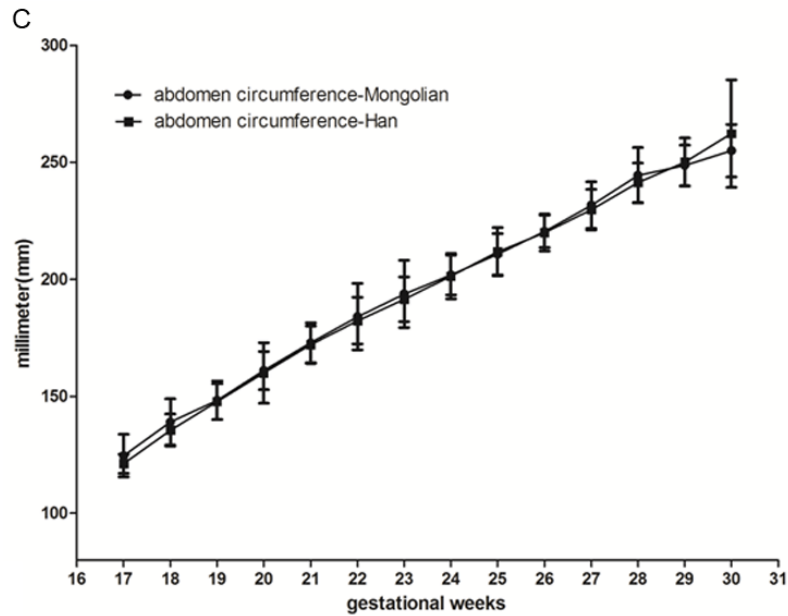
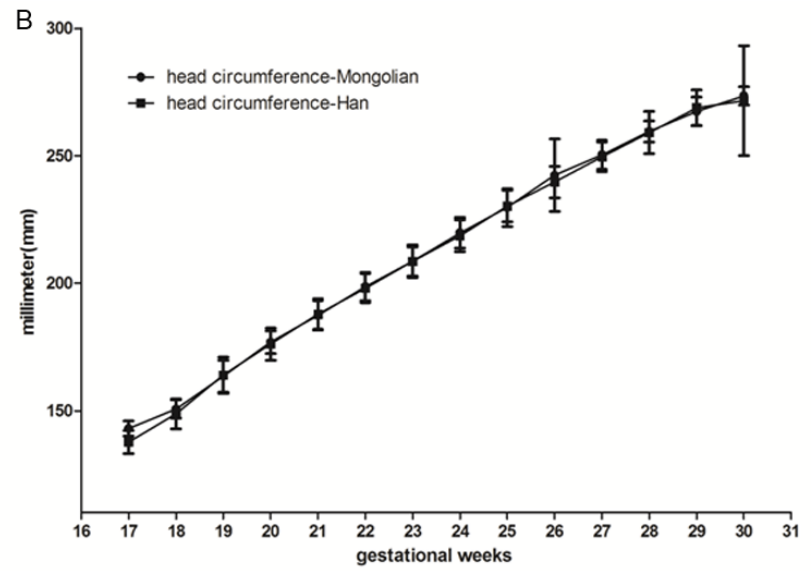
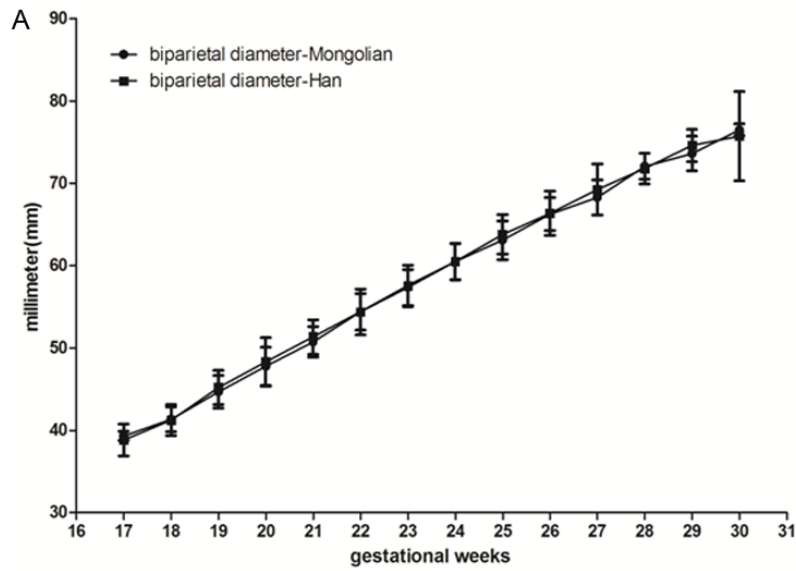
tic shadowing; 2) mild renal pyelectasis is marked by an anteroposterior pelvic diameter (APD) >4 mm at Week 20-30 or >7 mm but <10 mm at Week 30-40 of gestation, without caliectasis; 3) choroid plexus cysts (CPCs) are round or oval cystic structures (single or multiple) of lateral ventricular choroid plexus; 4) mild fetal lateral ventricle expansion is defined by a fetal ventricular diameter of 10-15 mm in second trimester; 5) single umbilical artery (SUA) is self-explanatory (two are expected); and 6) cavum vergae (CV, also known as the sixth ventricle or fornix cavity) is a non-echogenic area in midline established by first confirming the thalamic plane, then inserting a probe (10°-15° posteroinferior) along cavum septum pellucidum.

Standard software (SPSS v-13.0; SPSS Inc, Chicago, IL, USA) was used for data analysis, comparing rates of fetal malformations and soft-marker ultrasound positivity in terms of ethnicity (Mongolian vs. Han) and maternal age. Statistical significance was set at $P < 0.05$.

Results

Of the 7753 pregnancies studied, including 402 pairs of twins and three sets of triplets, fetal abnormalities were detected in 396 (4.98%) (Tables 1 and 3), with Mongolian and Han ethnicities accounting for 50 (3.72%) and 315 (5.33%) respectively, and 31 (1.82%) in others. The three most common types of deformity involved central nervous system (total, 105; rachischisis, 13; hydrocephalus, 40; Dandy-Walker syndromes, 14 (Figure 1); semilobar holoprosencephaly, 6; anencephalus, 2; and others, 44), including 14 cases of dual malformations; cardiovascular elements (total, 80; ventricular septal defect, 11; endocardial cushion defect, 9; pulmonic

Fetal malformation detection in Mongolian



Fetal malformation detection in Mongolian

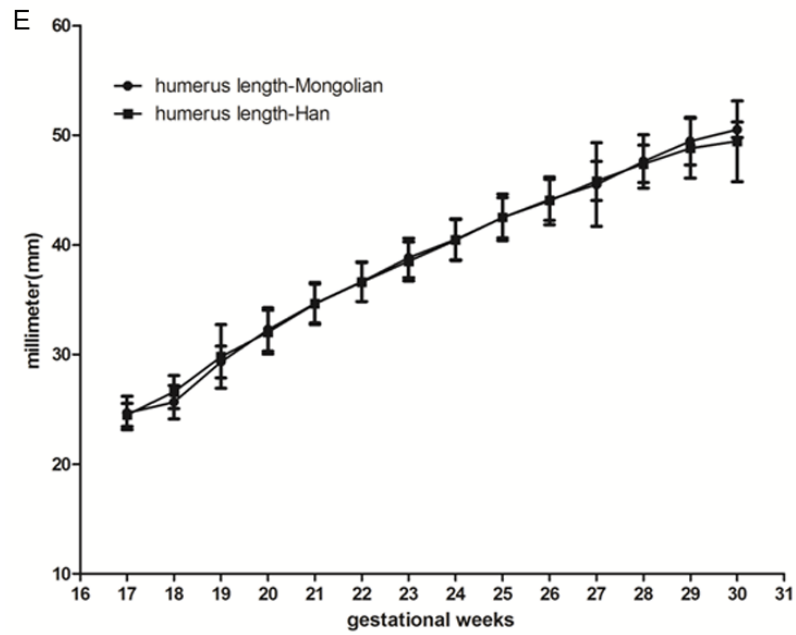


Figure 1. Comparison of biparietal diameter, head circumference, abdominal circumference, femoral length, and humoral length during gestation (17-39 weeks) by ethnicity (Mongolian vs. Han).

stenosis or atresia, 8; hypoplastic left heart, 7; and more); and genitourinary structures (total, 59; multicystic dysplastic kidneys, 11; obstruction urine road disease, 5; polycystic kidney, 11; renal agenesis, 8; hydronephrosis, 15; and others, 9).

Ultrasonic soft markers of fetal malformations were positive in 322 (4.05%) of the 7753 pregnancies studied (**Table 2**), with 59 and 245 positive outcomes in Mongolian and Han ethnic groups, respectively and 18 in others (**Table 3**). EICF (1.48%) and mild expansion of renal pelvis (1.26%) were the most common soft markers detected. Soft-marker positivity was secondary in 42 cases and subsequently was discounted; 28 fetuses displayed two positive markers (EICF and mild pyelectasis) and one fetus exhibited three ultrasonic soft markers.

Rates of fetal malformation and ultrasonic soft-marker positivity were also compared in Mongolian and Han ethnic subsets, accounting for 1314 (16.95%; twins, 29 pairs; triplets, one set) and 5751 (74.18%; twins, 159 pairs) of the 7753 pregnancies, respectively (others: 397, 5.12%; unknown ethnicity: 291, 0.04%). As shown in the **Table 3**, no statistically significant differences were evident.

Discussion

Birth defects have profound effects on the quality of regional populations. Although a 3-4% rate is typically anticipated, environmental pollutants and more frequent infections during pregnancy have clearly increased the incidence of birth defects [4]. In China, about 4-6% of all births each year are affected [5], with Inner Mongolia registering some of highest rates of fetal malformation (e.g., central nervous system defects, cardiovascular anomalies, and facial dysmorphism).

In this study, the overall rate of fetal abnormalities detected by ultrasound was 4.98%, which is comparable to a figure reported by Hu [6], but which significantly surpasses the 1.03% rate reported for China in the year 2000 [7]. Our results may be skewed to an extent, given that consultations from outlying primary hospitals were included in this analysis. Central nervous system defects ranked first among the 396 malformations we detected, again coinciding with the majority of reports [8] and consistent with birth defect data of Inner Mongolia.

Fetal ultrasonic soft-marker positivity is suggestive of chromosomal abnormalities. In newborns, the incidence of chromosomal abnormalities is low (0.1-0.2%) [9, 10], trisomy 21 being most common. Trisomies 18 and 13 are largely detectable as ultrasonic structural abnormalities, and genetic sonograms have proved useful for the screening of Down syndrome (trisomy 21) [11]. In 1987, scholars found that nuchal skin-fold thickness ≥ 6 mm and a ratio of actual-to-expected femoral length ≤ 0.91 enabled identification of Down syndrome with a sensitivity of 75% and a specificity of 98%; and prenatal ultrasonic detection of trisomies 13 (100%) and 18 (77%) was equally reliable [12]. The published literature suggests that concerns over pregnant women whose risk of fetal chromosomal abnormalities is high may be greatly reduced through prenatal ultrasonography that is devoid of soft markers, reducing the risk of trisomy 21 by 60-80% [13, 14]. In this study, 322 instances of soft-marker positivity were encountered, the top three being EICF (1.48%), mild pyelectasis (1.26%), and cavum vergae (0.53%). In a retrospective multicenter study, Kouamé [15] determined positive and negative predictive values of 76.4% and 99.8% respectively, linking polyhydramnios with fetal malformations (sensitivity, 87.3%; specificity, 99.5%) and indicating that this too may be a reliable index of birth defects. Rios [16] also reported the prenatal ultrasonography of a 20 year-old Caucasian woman with a diagnosis of oligohydramnios (G4P1A2) at 33 weeks of gestation. The fetus displayed a large lower abdominal cystic mass with a single septum, bilateral hydronephrosis, ambiguous genitalia, and a single umbilical artery. Abnormal amniotic fluid volume in late pregnancy thus appears to qualify as a soft marker of fetal chromosomal abnormalities.

There is a 2-5% incidence of fetal EICF, which is relatively common in second trimester ultrasound, with 90% occurring in left ventricle. However, 95% of EICF disappear in late pregnancy [17]. Researchers [18] have offered differing explanations for the etiology of EICF, but the occurrence rate in Asian populations is significantly higher than in other races, so the risk of associated fetal chromosomal abnormalities is considered low [19]. Fetal pyelectasis is common in ultrasounds studies of second trimester pregnancies, with an incidence of 0.3-4.5%, but mild pyelectasis may be indicative of chro-

Fetal malformation detection in Mongolian

mosomal abnormalities [20]. In 1990, international experts for the first time agreed that pyelectasis and aneuploidy (especially trisomy 21) may be related. In a high-risk population, 25% of fetal trisomy 21 occurrences were marked by mild pyelectasis, compared with only 2.8% in a fetal group with normal chromosomes [21]. Another report [22] has cited a 1% incidence of unilateral pyelectasis without chromosomal abnormalities, whereas in bilateral pyelectasis with dilatation, the rate of combined chromosomal abnormalities was 3%.

The detection rate of CPC in a low-risk population is approximately 0.5-1% [23]. These lesions generally have a good prognosis, causing no symptoms or syndromes, and disappear before 28 weeks of gestation. However, if combined with other abnormalities, especially multiple malformations, the risk of chromosomal abnormalities is high.

Mongolian and Han ethnic groups differ in regional environment and living habits, as well as in genetic and anthropologic profiles, hence our concerns that fetal malformation and soft-marker positivity rates in ultrasound studies might differ. In this retrospective analysis, we found no statistically significant difference in respective rates of detected fetal malformations for the study interval, which is in accordance with previously reported conclusions [1]. However, it has been noted that detected malformation rates for various ethnic minorities in the Xinjiang region are lower than those recorded in Han pregnancies [24]. Furthermore, the false-positive rate of ultrasonic diagnosis of fetal abnormalities is not more than 0.1% (confirmed postpartum or by odinopoeia) [25, 26]. In subsequent studies, we will accrue as much data as feasible on Mongolian fetal prenatal status and focus more on potential Mongolian and Han ethnic fetal differences.

Acknowledgements

This study was supported by the National Natural Science Foundation of China (81-560260) and the Inner Mongolia Natural Science Foundation of China (2014MS0346, 2015MS08125).

Disclosure of conflict of interest

None.

Address correspondence to: Lixin He, Department of Ultrasound, Inner Mongolia Medical University Affiliated Hospital, 1 Tongdao North Road, Hui Min District, Hohhot 010059, China. Tel: +86 13664883301; E-mail: hlxlx6211676@163.com

References

- [1] Dai BZ, Su YF, Hao XJ, Jiao LT. Analysis of the results of a birth defects baseline survey in Inner Mongolian Autonomous Region. *Chinese Journal of Family Planning* 2012; 20: 683-686.
- [2] ISUOG. Trimester routine fetal ultrasound Operations Guide. *Chinese Journal of Prenatal Diagnosis* 2012; 4: 25-34.
- [3] Gu WR, Li XT, Yan YL, Zhang YP, Zhu MW, Zhang JH, Zhou YQ. Prenatal diagnostics and outcome of ultrasonographic soft markers. *Fudan University Journal of Medical Sciences* 2010; 37: 180-187.
- [4] Ministry of Health of the People's Republic of China. Report on Women and Children's Health Development in China. 2011.
- [5] Hu QY, Chen CP, Deng XY, He Y, Li L. Prenatal systematic ultrasonic examination in diagnosis of fetal congenital malformations. *Chinese Journal of Medical Imaging Technology* 2012; 28: 343-346.
- [6] Wang Y, Fan Y, Xiong XQ, Wei M. Two-dimensional ultrasound prenatal diagnosis of fetal malformations. *Chinese Journal of Medical Imaging Technology* 2003; 19: 785-786.
- [7] Yang CP. Analysis of the Value of Antenatal Sonographic Diagnosis on Fetal Anomaly. *Journal of Clinical Research* 2010; 27: 656-658.
- [8] Rembouskos G, Cicero S, Longo D, Sacchini C, Nicolaides KH. single umbilical artery at 11-14 weeks' gestation: Relation to chromosomal defects. *Ultrasound Obstet Gynecol* 2003; 22: 567-570.
- [9] Zuo QH. Genetics of intelligence retardation. Practical eugenics. Beijing: People's Education Press; 1998. pp. 529.
- [10] Zhu BS, Jiao CX, Zhu S, Dong XD, Hu YY, Liu YX, Feng HY, Liu J, Tang XH, Zhang YX, Wang RH, Zhu XZ, Zhang XM. A Study on the Incidence of Down's Syndrome and the Interference by Prenatal Screening. *Chinese Journal of Obstetrics & Gynecology and Pediatrics* 2005; 1: 20-23.
- [11] Fang YM, Benn P, Egan JF. Use of the genetic sonogram in the United States in 2001 and 2007. *Ultrasound Med* 2008; 27: 1543-1548.
- [12] Benacerraf BR, Gelman R, Frigoletto FD. Sonographic identification of second-trimester fetuses with Down's Syndrome. *N Engl J Med* 1987; 317: 1371-1376.
- [13] Yang WJ, Wu QQ, Yao L, WANG L, LI M, WANG X, LI L. The relevance study of fetal cardiac abnor-

Fetal malformation detection in Mongolian

- malities screened by prenatal ultrasound and chromosomal abnormalities. Chinese Journal of Medical Ultrasound (Electronic Edition) 2011; 8: 765-771.
- [14] Liu YH, Song HL, Liu YL, Jin ZP. Clinical value of prenatal ultrasound screening for fetal malformation due to chromosomal abnormalities. Journal of China Clinic Medical Imaging 2009; 20: 477-478.
- [15] Kouamé N, N'goan-Domoua A M, Nikiéma Z, Konan AN, N'guessan KE, Séitchéou A, Tra-Bi ZO, N'gbesso RD, Kéita AK. Polyhydramnios: A warning sign in the prenatal ultrasound diagnosis of fetal malformation. Diagn Interv Imag 2013; 94: 433-43.
- [16] Rios LT, Araujo Júnior E, Nardoza LM, Caetano AC, Moron AF, Martins Mda G. Prenatal diagnosis and postnatal ultrasound findings of cloacal anomaly: a case report. Case Rep Pediatr 2012; 2012: 969860.
- [17] Zhang Y, Jiang KX, Wang JJ, Cai AL, Guo YJ, Sun W. Echocardiographic Observation and Clinical Significance of Echogenic Intracardiac Foci in Fetuses. Journal of China Medical University 2011; 40: 439-443.
- [18] Towner D, Gerscovich EO, Chiong BB, Rhee-Morris L, McGahan JP. Comparison of single versus multiple echogenic foci in the fetal heart regarding risk of aneuploidy. J Ultrasound Med 2010; 29: 1061-1067.
- [19] Rebarber A, Levey KA, Funai E, Monda S, Paidas M. An ethnic predilection for fetal echogenic intraeardiac focus identified during targeted mid-trimester ultrasound examination: a retrospective review. BMC Pregnancy Childbirth 2004; 4: 112-115.
- [20] Tian XX, Li XY, Zheng CG. Research progress of Pregnancy fetal ultrasound soft signs associated with chromosomal abnormalities. Guangxi Medical Journal 2008; 30:1706-1708.
- [21] Raniga S, Desai PD, Parikh H. Ultrasonographic soft markers of aneuploidy in second trimester: are we lost. Medscape General Medicine 2006; 8: 9.
- [22] Beke A, Papp C, Tóth-PálE, Mezei G, Joó JG, Csaba A, Papp Z. Trisomies and other chromosome abnormalities detected after positive sonographic findings. J Reprod Med 2005; 50: 675-691.
- [23] Li SL. Textbook of Fetal Abnormalities. the second edition People's Military Medical Press. 2009.
- [24] Qian RY, Liu H, Zhong N, Wang R, Zou HY, He J, Yu WZ. Analysis of birth defects in Xinjiang multi-ethnic region. Journal of Clinical Rehabilitative Tissue Engineering Research 2011; 15: 3797-3800.
- [25] Romosan G, Henriksson E, Rylander A, Valentin L. Diagnostic performance of routine ultrasound screening for fetal abnormalities in an unselected Swedish population in 2000-2005. Ultrasound Obstet Gynecol 2009; 34: 526-533
- [26] Nakling J, Backe B. Routine ultrasound screening and detection of congenital anomalies outside a university setting. Acta Obstet Gynecol Scand 2005; 84: 1042-1048.