

Original Article

Endoscopic retrograde cholangiopancreatography-related perforation: recommendations from a single institution experience

Ding Shi, Dong Wu, Xujun Hu

Department of Gastroenterology, Ningbo No. 2 Hospital, Ningbo, China

Received February 23, 2016; Accepted June 4, 2016; Epub September 15, 2016; Published September 30, 2016

Abstract: Background: Endoscopic retrograde cholangiopancreatography (ERCP)-related duodenal perforation is a serious complication associated with high mortality. We aimed to characterize and define improvements for ERCP through a retrospective review of ERCP-related perforations in our institution. Methods: The review of our medical records identified six cases of ERCP-related perforations between March 2003 and March 2013. Associated clinical manifestations and outcomes, perforation types, imaging ERCP-related findings and treatment modalities were analyzed. Results: Between March 2003 and March 2013, 2071 ERCPs were performed, 6 (0.29%) of which resulted in ERCP-related perforations. The perforations localized in one instance to the horizontal part of duodenum, in one case to the bile duct, in one patient to the hepatic duct, and two times a periampullary perforation occurred. Perforation was suspected in 2 patients during the ERCP because of specific radiological findings, and in four patients after ERCP because of subsequent clinical behavior. The latter four perforations were confirmed by computed tomography (CT). The perforation of the horizontal part of duodenum was managed surgically, whereas the remaining five cases were managed conservatively. Conclusion: Successful management of ERCP-related perforation requires a timely diagnosis and vigilant clinical and radiographic monitoring. CT is an important diagnostic modality in ERCP-related perforations.

Keywords: Endoscopic retrograde cholangiopancreatography, duodenum, perforation, diagnosis, management

Introduction

Endoscopic retrograde cholangiopancreatography (ERCP) combines endoscopy, fluoroscopy and radiography to diagnose and treat a variety of biliary and pancreatic ductal system diseases. Although this is a very powerful technique, it is accompanied by substantial risk for iatrogenic pathology, especially pancreatitis and perforation; and thus, the safe application of ERCP requires substantial training of the practitioner [1]. Although fortunately relatively uncommon, perforation is one of the most serious complications of ERCP due to its potentially lethal nature. The reported incidence of perforation ranges between 0.11% and 1.6% [2-8], and the associated mortality rate varies from 4.5% to 33.3% [3-5, 7, 8]. Hence, the prevention of perforation during ERCPs is one of the most pressing concerns in practical gastroenterology [9]. Especially, delayed diagnosis and treatment of

this complication may result in fatality, and timely recognition and execution of proper management according to established guidelines is considered of utmost importance to avert fatal outcome [10]. Strikingly, systematic studies of ERCP outcomes are rare [5, 8, 11] and mostly constitute case reports and series that do not cover all types of ERCP-related perforations, mainly due to the relative rarity of these adverse events [2, 12-16]. Thus, there is great need for documenting experience obtained in high volume centers in this respect to allow better insight in factors that can prevent perforation. This consideration prompted us to report a retrospective analysis of a series of ERCP-related perforations from a single high-volume Chinese tertiary referral center, which might aid practitioners elsewhere to manage such complications. Our series included all types of perforating injuries resulting from ERCP, and this allowed us to define a management algorithm

Endoscopic retrograde cholangiopancreatography-related perforation

Table 1. Characteristics of patients with ERCP-related perforations

Age	Gender	ERCP indication	ERCP procedure	Manifestation of perforation	Time of diagnosis	Type of perforation	Perforation affirm	Radiologic findings	Type of management
66	M	CBD Stones	EST + balloon dilation	Tachypnea, Tachycardia, abdominal distension	0 h	I	ERCP	Intra-and retroperitoneal air (Figure 1A)	Surgical treatment (Figure 1B)
63	M	CBD Stones	Needle-knife pre-cut + EST + stone extraction by basket	Unexpected abdominal pain with lever, leukocytosis after ERCP	15 h	II	CT	Retroperitoneal air (Figure 1C)	Conservative management + CT guided percutaneous external drainage due to retroperitoneal abscess
68	M	Benign biliary Stricture + CBD stones	Needle-knife precut + EST + stone extraction by basket	Unexpected abdominal pain, abdominal tenderness, rebound tenderness, leukocytosis after ERCP	72 h	II	CT	Retroperitoneal air, fluid collection (Figure 1D)	Conservative management + CT guided percutaneous external drainage due to retroperitoneal abscess
77	M	CBD Stones	EST + stone extraction by basket	No special manifestation	0 h	III	ERCP	Unusual guidewire position (Figure 2A)	No special treatment
72	M	Pancreas Head Cancer	EST + ERBD	Leukocytosis after ERCP	48 h	IV	CT	Retroperitoneal air (Figure 2B)	Conservative management
81	F	CBD Stones	EST + stone extraction by basket	Liver function damage and hemoglobin decrease	16 h	III	CT	Hepatic parenchyma and subcapsular hematoma (Figure 2C and 2D)	Conservative management

Footnotes: ERCP: Endoscopic Retrograde Cholangiopancreatography, CT: Computer Tomography, ERBD: Endoscopic Retrograde Biliary Drainage.

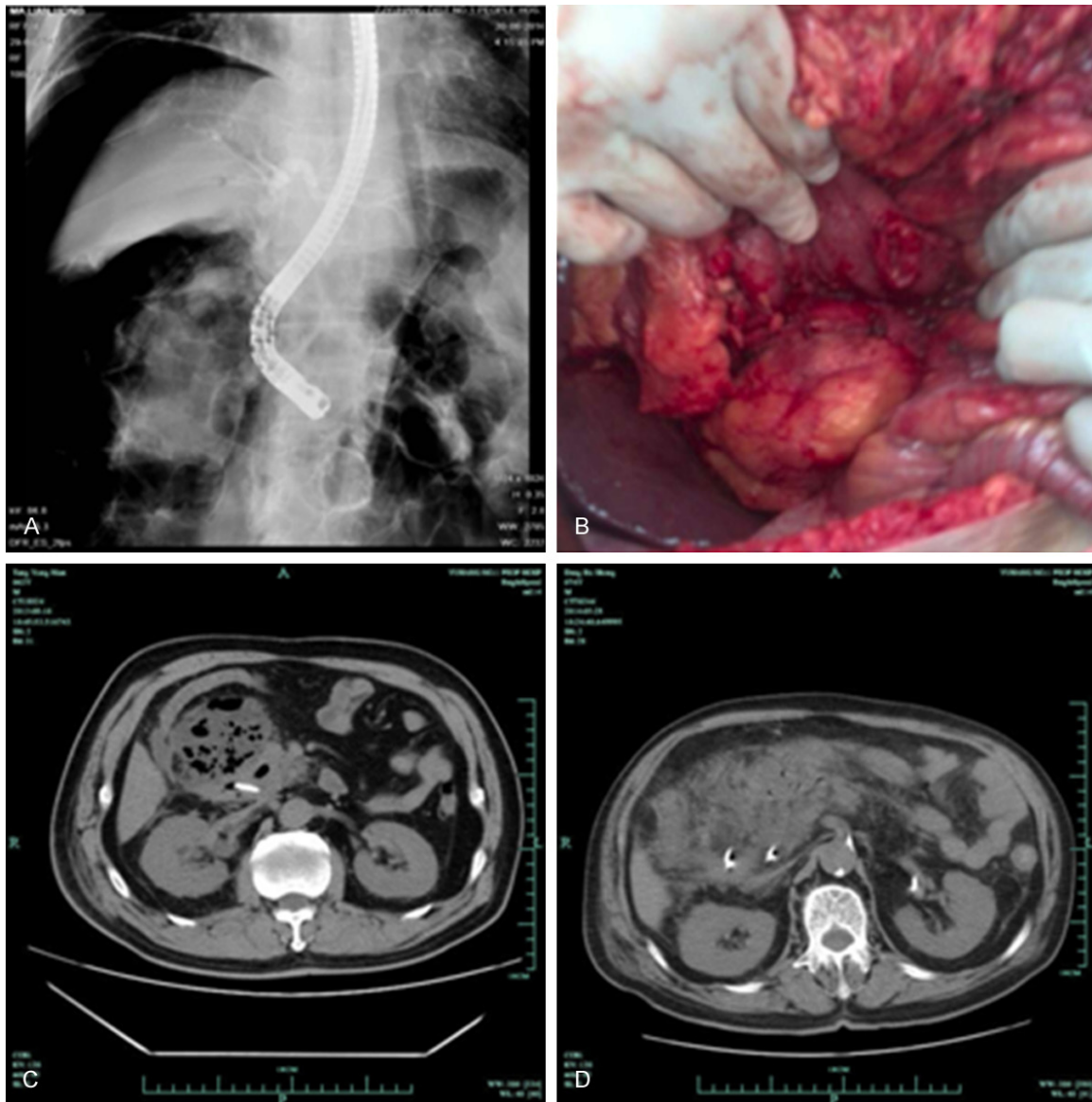


Figure 1. Aspects of the two types of perforations. An X-ray radiograph and intraoperative photograph of a type I perforation; and an example of a type II perforation on CT. A. Fluoroscopy showing the pneumoperitoneum. B. A perforation was found in the horizontal part during the operation. C. CT showing the presence of retroperitoneal air. D. CT showing retroperitoneal fluid deposition.

for ERCP-related perforations suitable for the entire body of ERCP-associated perforations.

Materials and methods

Between March 2003 and March 2013, 2,071 ERCPs were performed in our hospital. Among these procedures, ERCP-associated perforations occurred in six patients (0.29%). Medical records of all these six patients were retrospectively reviewed. Age, gender, indication for endoscopy/ERCP, timing or delay to diagnosis

and final management strategy, as well as the type of perforation, associated complications, length of hospital stay and delayed morbidity, were analyzed for each case. The use of this information was approved by the appropriate Medical Ethics Committee of our hospital. Informed consent was obtained from the patients.

ERCP-related perforation has been divided into three or four types using the following classifications. Type I (remote from the papilla) [17]

results from the scope itself [18, 19]. Most type I perforations can be immediately recognized by the endoscopist during the procedure. Type II (periampullary) [17] is related to sphincterotomy [18, 19]. In some cases with large perforations, skin emphysema and a clear kidney shadow can be found during the procedure. Up to 20-30% of type II are not immediately diagnosed [20]. The patients may report abdominal pain and discomfort, which are followed by fever and leukocytosis. The occurrence of these perforations can be confirmed by computed tomography (CT) scan of the abdomen, which reveals the presence of retroperitoneal air or fluid deposition. Type III (at the level of the distal bile duct) [17] can be recognized by an unusual guidewire position [18, 19]. If recognized in a timely manner, this type of perforation can be adequately managed by simply pulling the guidewire back into a safe position. Type IV (retroperitoneal air alone) [17] are tiny retroperitoneal perforations caused by the use of compressed air during endoscopy [19].

Surgical procedures were immediately performed following type I perforations in all cases in our series upon detection. The associated surgical procedures include duodenal primary repair and drainage of the retroperitoneal space and abdominal cavity, and removal of retained bile duct stones with the insertion of a T-tube. Other cases were managed conservatively. Conservative management consisted of bowel resting, nasogastric tube decompression of the upper gastrointestinal tract, nasal biliary drainage and broad-spectrum intravenous antibiotics such as piperacillin/tazobactam or ciprofloxacin, and metronidazole (even if patients presented as afebrile).

Results

A series encompassing all four major types of ERCP-related perforations

Patient characteristics of the six cases of ERCP-related perforations identified in our search are listed in **Table 1**. These cases included one endoscope-related duodenal perforation (which represents a type I perforation and two needle-knife-related periampullary perforations that constitute type II perforations), two bile duct perforations secondary to guidewire trauma (which are type III perforations), and one tiny retroperitoneal perforation considered to be caused by the use of compressed air during

endoscopy (which is a type IV perforation). Thus, our case series uniquely encompasses the perforations of all four categories normally used for classifying this complication of ERCP.

Perforation diagnosis

Type I perforations in our series was immediately recognized during the procedure by observing the accumulation of subphrenic free air during X-ray visualization (**Figure 1A**). Type II perforations in our series were definitively diagnosed at 15-72 hours following ERCP, although no unusual findings before the end of ERCP were reported for this type of perforation. Radiological films of the ERCP procedure were retrospectively reviewed. Furthermore, *post-hoc* analysis did not reveal any indication that might explain or predict any subsequent perforation. All patients with type II perforation complained of epigastric pain after ERCP. Retroperitoneal air (**Figure 1C**) or fluid accumulation (**Figure 1D**) was indicated after a swift CT of the upper abdomen. These findings highlighted the importance of adequate and rapid medical imaging following unusual pain upon an ERCP procedure, even in the absence of abnormalities during the procedure. One case with type III perforation was immediately diagnosed during the procedure from observing an unusual guidewire positioning (**Figure 2A**). The other case with type III perforation was diagnosed by CT of the upper abdomen which revealed hepatic parenchyma and subcapsular hematoma (**Figure 2C and 2D**), in which medical imaging was indicated by apparent damage to liver functionality and a decrease in hemoglobin level in conjunction with mild right upper abdominal pain following ERCP. However, results of the retrospective analysis of this case did not reveal any unusual guidewire positioning during ERCP procedures. The type IV perforation present in our series was diagnosed by the retroperitoneal air visible in CT (**Figure 2B**), which was carried out in response to apparent leukocytosis after the ERCP procedure. Thus, overall, it appears that one should not be conservative in requesting medical imaging if unexplained pain or other symptoms occur after ERCP when one wants to ascertain the timely detection of perforation.

Clinical outcomes

The patient case with type I perforation was discharged 46 days after surgery (**Figure 1B**).

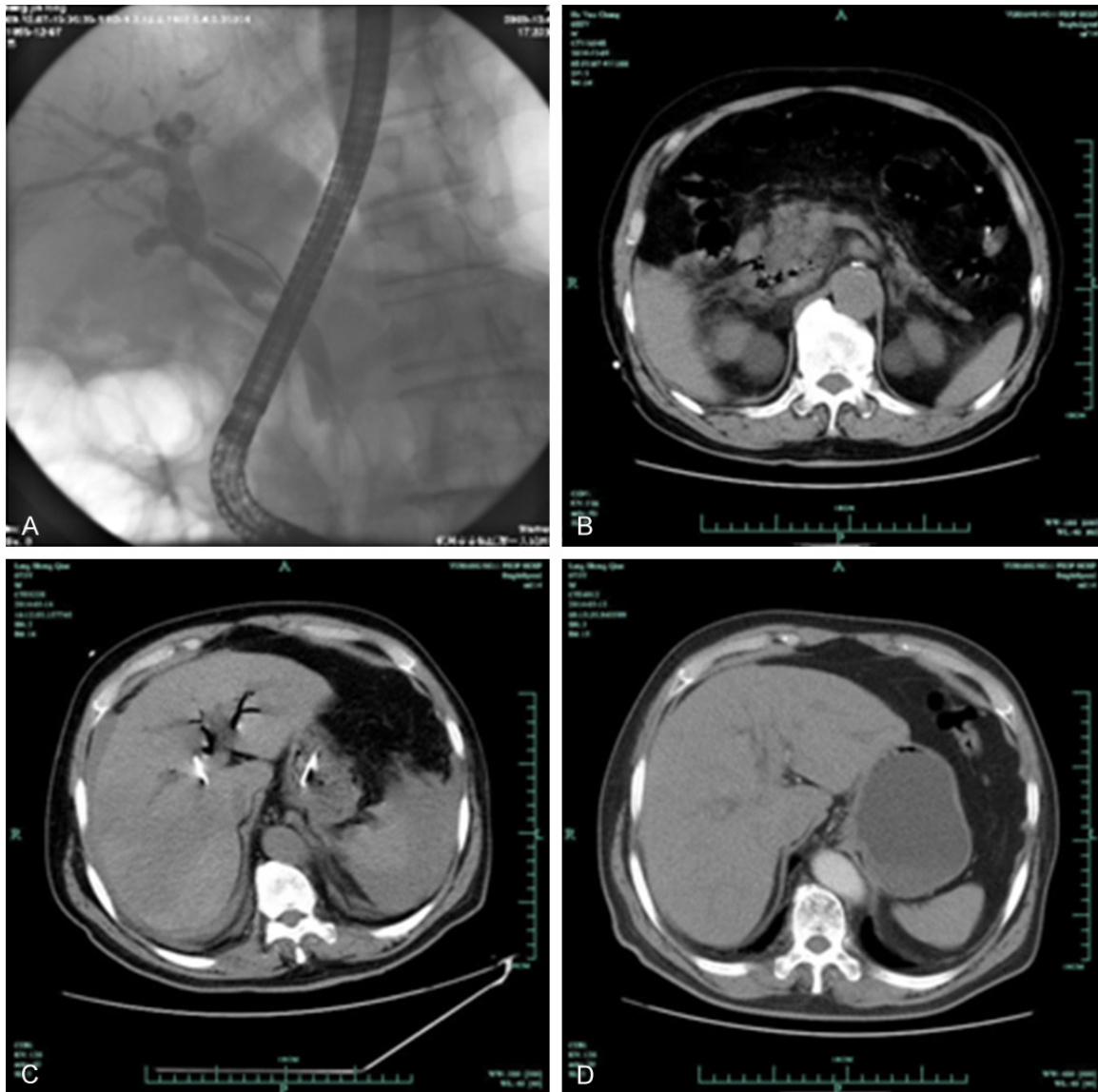

Figure 2. An example of an X-ray radiograph of a type III perforation and CT aspect of type III and type IV perforations, (A) Fluoroscopy showing an unusual guidewire position. (B) CT showing retroperitoneal air. (C) CT showing hepatic parenchyma (arrows) and subcapsular (arrowheads) hematoma. (D) As compared to the image presented in (C), CT did not show hematoma before ERCP in this image.

Two cases with type II perforation had retroperitoneal abscess formation, and were successfully treated by CT-guided percutaneous external drainage, which was continued for 28 and 61 days, respectively. Two cases with type III perforations and one case with type IV perforation did not require specific intervention, and were managed conservatively with good results. Thus, if timely detected, ERCP-related perforations would not be specifically dangerous.

Discussion

The incidence of ERCP-related duodenal perforation is low, and has been reported to be approximately 0.14-1.3% [15, 21-26]. However, as an evident iatrogenic injury that is very difficult to completely avoid, it has significant impact on endoscopists. A final good conclusion with complete recovery of the patient from perforation is of utmost importance, and thus, the evaluation of past cases for possible les-

sons and for obtaining guidance for future procedures is necessary.

Furthermore, as illustrated by the cases presented above, timely and correct diagnosis remains the foundation of the successful management of ERCP-related complications. The detection and diagnosis of these scope-related injuries (type I) are rather straightforward, since the perforations of this type are large enough to be readily identified by endoscopy through the observation of yellowish intra/retroperitoneal fat tissues or intra-abdominal organs. This was the situation presented in the current series, and this notion fit well with the body of medical literatures on this subject [27, 28]. Moreover, the pneumoperitoneum resulting from this type of perforation is also immediately evident in X-rays, making it recognizable to endoscopists at once to allow for adequate management. The type I perforation in our series was discovered by observing free air under the diaphragm. Type I perforation occurs primarily in the second part of the duodenum, as a result of tearing by the distal end of the endoscope or due to the migration of the biliary stents, which are located in the retroperitoneal space [4, 29]. However, the type I perforation presented in our series occurred in the horizontal part of the duodenum; and thus, might have related to balloon migration, since there was no subphrenic free air in the X-ray before dilation of the balloon, and balloon migration was observed in the course of dilating. This is rather unusual, and it appears to be few examples of balloon migration caused by type I perforations. Two cases of balloon dilation-related perforation were reported by Motomura *et al.* [15], but these were type II perforations and were not accompanied by balloon migration during the dilation of the balloon. Thus, our specific case, although apparently rare, indicates that possible balloon migration and subsequent type I perforation cannot be ignored; and practitioners should be watchful that this does not occur.

Unlike type I, which is immediately obvious, the detection of a potential type II perforation during the ERCP procedure can be very difficult [15]. In a medical literature, the rate of delayed diagnosis of type II was reported to be approximately 30% [25]. Koc *et al.* reported that the total delayed diagnosis rate of perforations for all types was 64.30% [12]. The type II perfora-

tion presented in our series was also diagnosed only after completion of the ERCP procedure, and retrospective analysis of the radiological films did not provide any clue as to when this type of perforation was inflicted. Thus, it is imperative to immediately perform CT following epigastric pain complaints in patients who underwent ERCP. The presence of perforations can be revealed by CT of the abdomen and the presence of retroperitoneal air or fluid accumulation [3, 15, 19], allowing adequate management to be initiated.

Most type III perforations are usually detected during the ERCP procedure as they occur [18]. However, among the type III perforations presented in our series, one perforation was discovered by CT only after ERCP, but not due to impaired liver function or decreased hemoglobin levels. Hepatic parenchyma and subcapsular hematomas were major signs upon medical imaging, which might be related to the deep cannulation by the guidewire. This is a fairly unique situation. Kayashima *et al.* reported one case of liver parenchyma perforation, but this event resulted from guidewire piercing through the liver capsular, since this was evident from the detection of air and contrast medium leakage around the spleen [30]. In our case, the mechanism behind the type III perforation is similar to that reported by Kayashima *et al.*; however, in our case, the guidewire did not pierce through the liver capsula. Our case in conjunction with that reported by Kayashima warns against deep cannulation by the guidewire into the intrahepatic bile duct.

There are no specific guidelines for the treatment of ERCP-related perforations. Due to their uncommon nature, prospective comparative studies on this subject are highly problematic at present [31]. Since type I perforations involve the leakage of a large volume of bile and intestinal juice, which are evident during endoscopy or X-ray imaging, immediate surgical intervention is an obvious response. Although an increased number of duodenal perforations have been treated successfully with endoclips or endoloops [3, 14] or using an over-the-scope clips [32, 33], surgery remains the major treatment means for type I perforations [25, 34, 35]. Some reports described that over 80% of patients with type I perforations required surgery [5, 25]. The type I perforation in our series had a good outcome due to timely surgery in

line with this prevailing view. Conservative treatment is chosen for most type II perforations, because periampullary perforations are relatively small and difficult to detect in the operation theatre, and surgery is not recommended in most cases [19]. The two cases with type II perforation in our series were also managed conservatively and had a good outcome. Based on our experience, if conservative treatment is performed, biliary drainage is necessary to prevent further bile leakage from the perforation site [19]. Sufficient nasal biliary drainage is the basis of conservative treatment success. In addition, there is gathering momentum on the treatment of duodenal perforations with endoclips or endoloops, in which a substantial number of cases with successful outcomes has been reported [3, 14]. However, as type II perforations involve the periampullary region, there is a possibility that the common bile duct is closed by the endoclips; and thus, nasal biliary drainage is recommended in these cases. In addition, nasogastric tube decompression and late external drainage of retroperitoneal abscesses also importantly contribute to the treatment success of conservative management strategies. Nevertheless, in case of relatively large perforations that defy closure by clips or in cases with fluid accumulation increases or when the patient's condition worsens, surgical treatment should be considered [5, 13, 26].

Type III and IV perforations, which generally do not have serious consequences, are not particularly managed. The three cases in our series have been uneventful after a brief medical treatment.

In conclusion, the cases presented in this study covered uniquely all four types of ERCP-related perforations and showed the importance of rapid medical imaging if alarm symptoms occur. This also shows that conservative management is adequate in many instances.

Disclosure of conflict of interest

None.

Address correspondence to: Ding Shi, Department of Gastroenterology, Ningbo No. 2 Hospital, Ningbo 315000, China. Fax: +86-574-87362216; E-mail: shidingyuhang@163.com

References

- [1] Ekkelenkamp VE, Koch AD, Rauws EA, Borsboom GJ, de Man RA and Kuipers EJ. Competence development in ERCP: the learning curve of novice trainees. *Endoscopy* 2014; 46: 949-955.
- [2] Katsinelos P, Lazaraki G, Chatzimavroudis G, Gkagkalis S, Vasiliadis I, Papaeuthimiou A, Terzoudis S, Pilpilidis I, Zavos C and Kountouras J. Risk factors for therapeutic ERCP-related complications: an analysis of 2,715 cases performed by a single endoscopist. *Ann Gastroenterol* 2014; 27: 65-72.
- [3] Jin YJ, Jeong S, Kim JH, Hwang JC, Yoo BM, Moon JH, Park SH, Kim HG, Lee DK, Jeon YS and Lee DH. Clinical course and proposed treatment strategy for ERCP-related duodenal perforation: a multicenter analysis. *Endoscopy* 2013; 45: 806-812.
- [4] Avgerinos DV, Llaguna OH, Lo AY, Voli J and Leitman IM. Management of endoscopic retrograde cholangiopancreatography: related duodenal perforations. *Surg Endosc* 2009; 23: 833-838.
- [5] Polydorou A, Vezakis A, Fragulidis G, Katsarelis D, Vagianos C and Polymeneas G. A tailored approach to the management of perforations following endoscopic retrograde cholangiopancreatography and sphincterotomy. *J Gastrointest Surg* 2011; 15: 2211-2217.
- [6] Li G, Chen Y, Zhou X and Lv N. Early management experience of perforation after ERCP. *Gastroenterol Res Pract* 2012; 2012: 657418.
- [7] Miller R, Zbar A, Klein Y, Buyeviz V, Melzer E, Mosenkis BN and Mavor E. Perforations following endoscopic retrograde cholangiopancreatography: a single institution experience and surgical recommendations. *Am J Surg* 2013; 206: 180-186.
- [8] Alfieri S, Rosa F, Cina C, Tortorelli AP, Tringali A, Perri V, Bellantone C, Costamagna G and Doglietto GB. Management of duodeno-pancreato-biliary perforations after ERCP: outcomes from an Italian tertiary referral center. *Surg Endosc* 2013; 27: 2005-2012.
- [9] Ekkelenkamp VE, Koch AD, de Man RA and Kuipers EJ. Training and competence assessment in GI endoscopy: a systematic review. *Gut* 2016; 65: 607-15.
- [10] Lai CH and Lau WY. Management of endoscopic retrograde cholangiopancreatography-related perforation. *Surgeon* 2008; 6: 45-48.
- [11] Rabie ME, Mir NH, Al Skaini MS, El Hakeem I, Hadad A, Ageely H, Shaban AN, Obaid M and Hummadi AM. Operative and non-operative management of endoscopic retrograde cholangiopancreatography-associated duodenal injuries. *Ann R Coll Surg Engl* 2013; 95: 285-290.

- [12] Koc B, Bircan HY, Adas G, Kemik O, Akcakaya A, Yavuz A and Karahan S. Complications following endoscopic retrograde cholangiopancreatography: minimal invasive surgical recommendations. *PLoS One* 2014; 9: e113073.
- [13] Turner RC, Steffen CM and Boyd P. Endoscopic duodenal perforation: surgical strategies in a regional centre. *World J Emerg Surg* 2014; 9: 11.
- [14] Yu DW, Hong MY and Hong SG. Endoscopic treatment of duodenal fistula after incomplete closure of ERCP-related duodenal perforation. *World J Gastrointest Endosc* 2014; 6: 260-265.
- [15] Motomura Y, Akahoshi K, Gibo J, Kanayama K, Fukuda S, Hamada S, Otsuka Y, Kubokawa M, Kajiya K and Nakamura K. Immediate detection of endoscopic retrograde cholangiopancreatography-related periampullary perforation: fluoroscopy or endoscopy? *World J Gastroenterol* 2014; 20: 15797-15804.
- [16] Milek T, Ciostek P, Porzycki P and Kwiatkowska M. Treatment results of gastrointestinal perforation after endoscopic retrograde cholangiopancreatography. *Prz Gastroenterol* 2013; 8: 299-304.
- [17] Stapfer M, Selby RR, Stain SC, Katkhouda N, Parekh D, Jabbour N and Garry D. Management of duodenal perforation after endoscopic retrograde cholangiopancreatography and sphincterotomy. *Ann Surg* 2000; 232: 191-198.
- [18] Kim BS, Kim IG, Ryu BY, Kim JH, Yoo KS, Baik GH, Kim JB and Jeon JY. Management of endoscopic retrograde cholangiopancreatography-related perforations. *J Korean Surg Soc* 2011; 81: 195-204.
- [19] Lee TH, Han JH and Park SH. Endoscopic treatments of endoscopic retrograde cholangiopancreatography-related duodenal perforations. *Clin Endosc* 2013; 46: 522-528.
- [20] Prachayakul V and Aswakul P. Endoscopic retrograde cholangiopancreatography-related perforation: Management and prevention. *World J Clin Cases* 2014; 2: 522-527.
- [21] Kodali S, Monkemuller K, Kim H, Ramesh J, Trevino J, Varadarajulu S and Wilcox CM. ERCP-related perforations in the new millennium: A large tertiary referral center 10-year experience. *United European Gastroenterol J* 2015; 3: 25-30.
- [22] Assalia A, Suissa A, Ilivitzki A, Mahajna A, Yassin K, Hashmonai M and Krausz MM. Validity of clinical criteria in the management of endoscopic retrograde cholangiopancreatography related duodenal perforations. *Arch Surg* 2007; 142: 1059-1064.
- [23] Kapral C, Duller C, Wewalka F, Kerstan E, Vogel W and Schreiber F. Case volume and outcome of endoscopic retrograde cholangiopancreatography: results of a nationwide Austrian benchmarking project. *Endoscopy* 2008; 40: 625-630.
- [24] Cotton PB, Garrow DA, Gallagher J and Romagnuolo J. Risk factors for complications after ERCP: a multivariate analysis of 11,497 procedures over 12 years. *Gastrointest Endosc* 2009; 70: 80-88.
- [25] Kwon W, Jang JY, Ryu JK, Kim YT, Yoon YB, Kang MJ and Kim SW. Proposal of an endoscopic retrograde cholangiopancreatography-related perforation management guideline based on perforation type. *J Korean Surg Soc* 2012; 83: 218-226.
- [26] Kim J, Lee SH, Paik WH, Song BJ, Hwang JH, Ryu JK, Kim YT and Yoon YB. Clinical outcomes of patients who experienced perforation associated with endoscopic retrograde cholangiopancreatography. *Surg Endosc* 2012; 26: 3293-3300.
- [27] Enns R, Eloubeidi MA, Mergener K, Jowell PS, Branch MS, Pappas TM and Baillie J. ERCP-related perforations: risk factors and management. *Endoscopy* 2002; 34: 293-298.
- [28] Freeman ML. Complications of endoscopic retrograde cholangiopancreatography: avoidance and management. *Gastrointest Endosc Clin N Am* 2012; 22: 567-586.
- [29] Cho KB. The management of endoscopic retrograde cholangiopancreatography-related duodenal perforation. *Clin Endosc* 2014; 47: 341-345.
- [30] Kayashima H, Ikegami T, Kasagi Y, Hidaka G, Yamazaki K, Sadanaga N, Itoh H, Emi Y, Matsuura H and Okadome K. Liver Parenchyma Perforation following Endoscopic Retrograde Cholangiopancreatography. *Case Rep Gastroenterol* 2011; 5: 487-491.
- [31] Lee TH, Bang BW, Jeong JI, Kim HG, Jeong S, Park SM, Lee DH, Park SH and Kim SJ. Primary endoscopic approximation suture under cap-assisted endoscopy of an ERCP-induced duodenal perforation. *World J Gastroenterol* 2010; 16: 2305-2310.
- [32] Donatelli G, Dumont JL, Vergeau BM, Chiche R, Quioc JJ, Tuszyński T and Meduri B. Colic and gastric over-the-scope clip (Ovesco) for the treatment of a large duodenal perforation during endoscopic retrograde cholangiopancreatography. *Therap Adv Gastroenterol* 2014; 7: 282-284.
- [33] Nishiyama N, Mori H, Kobara H, Rafiq K, Fujihara S, Kobayashi M, Oryu M and Masaki T. Efficacy and safety of over-the-scope clip: including complications after endoscopic submucosal dissection. *World J Gastroenterol* 2013; 19: 2752-2760.
- [34] Fathi A, Lahmi F and Kozegaran R. Surgical management of ERCP-related complications.

Endoscopic retrograde cholangiopancreatography-related perforation

- Gastroenterol Hepatol Bed Bench 2011; 4: 133-137.
- [35] Tribonias G, Voudoukis E, Vardas E, Theodoropoulou A, Margarita-Eleni M and Paspatis G. Endoscopic Retrograde Cholangiopancreatography-Related Large Jejunal Perforation: Operate or Apply Over-the-Scope Clip Device? Clin Endosc 2014; 47: 281-283.