

## Case Report

# Brunner Gland Cyst: Report of Three Cases

Michelle Powers<sup>1</sup>, Gregory S. Sayuk<sup>2</sup> and Hanlin L. Wang<sup>3</sup>

<sup>1</sup>Department of Pathology and Immunology, Washington University School of Medicine, St. Louis, Missouri, USA; <sup>2</sup>Division of Gastroenterology, Department of Medicine, Washington University School of Medicine, St. Louis, Missouri, USA and <sup>3</sup>Department of Pathology and Laboratory Medicine, Cedars-Sinai Medical Center, Los Angeles, California, USA

Received 12 December 2007; Accepted and available online 1 January 2008

**Abstract:** Brunner gland cyst is a benign polypoid or nodular lesion of the duodenum that may not be familiar to gastroenterologists and pathologists because of its rarity. There have been only 9 cases documented in the world literature under various names. In this report, we describe the clinicopathologic features of three such cases to raise the awareness of its existence.

**Key Words:** Brunner gland, cyst, duodenum, endoscopy

### Introduction

Polypoid, nodular or mass lesions of the Brunner glands of the duodenum are rare, typically caused by Brunner gland hyperplasia, adenoma or hamartoma. These lesions may occasionally cause gastrointestinal bleeding or obstructive symptoms, but are classically discovered incidentally [1, 2]. Cystic lesions of the Brunner glands are exceedingly rare. There have been only 9 cases documented in the literature under various terms [3-11], some of which appear to represent cystic dilatation of the Brunner gland ducts in the context of hamartoma. Because of the rarity, the existence of Brunner gland cyst may not be known to some gastroenterologists and pathologists.

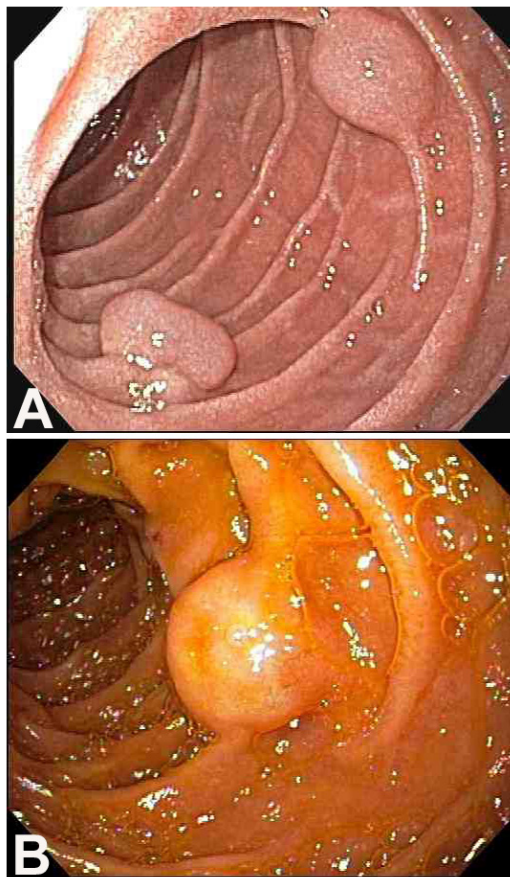
### Case Report

Case 1 was a 46-year-old woman with dyspepsia and odynophagia, carrying a presumptive diagnosis of esophageal motility disorder. On upper endoscopic evaluation, two polypoid lesions were detected in the second part of the duodenum, one 1.8 cm in diameter, and the other 2.2 cm (**Figure 1A**). Interestingly, during the biopsy procedure with a cold forceps, the polyps ruptured and were flattened such that they were no longer raised afterwards.

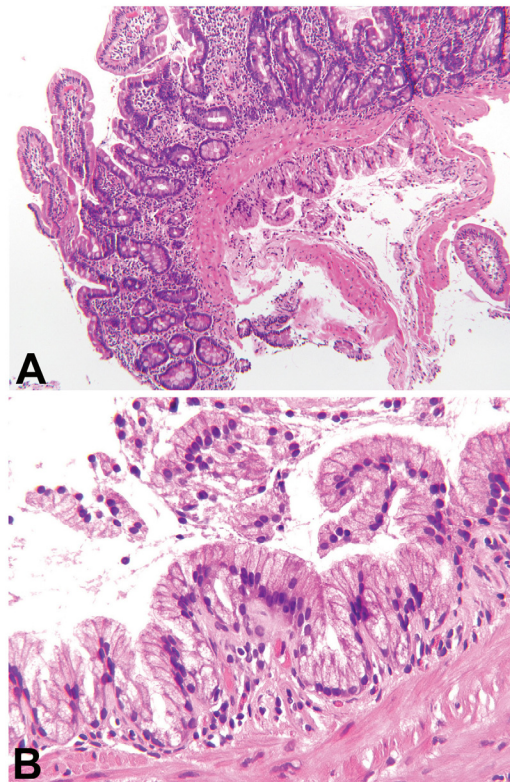
Case 2 was a 67-year-old woman with unexplained iron-deficiency anemia. Upper endoscopic examination revealed non-bleeding erosive gastropathy. In addition, a 1.5 cm sessile polyp with no bleeding was found in the second part of the duodenum (**Figure 1B**), which was biopsied with a cold forceps.

Case 3 was a 59-year-old woman abdominal pain, heartburn and steatorrhea. Upper endoscopic examination showed a hiatal hernia, linear erythematous streaks in the gastric antrum, and a 1.0 cm nodule in the duodenal bulb. The nodule was very soft and felt to be submucosal. Similar to that observed in case 1, the nodule appeared to be completely gone following biopsy.

In all three cases, histologic examination of the biopsies from the duodenal lesions showed unremarkable duodenal mucosa. However, a cystic structure was present in the submucosa immediately underneath the muscularis mucosae (**Figure 2A**). The cyst was lined by a single layer of tall columnar epithelium with clear cytoplasm and basally located nuclei, cytologically identical to those forming the Brunner glands (**Figure 2B**). Although micropapillary architecture was focally noted, no cytologic atypia or dysplasia was evident. No histologic evidence of Brunner gland hyperplasia or hamartoma was observed



**Figure 1** Endoscopic view showing two polypoid lesions in the duodenum in case 1 (A) and one polypoid lesion in the duodenum in case 2 (B).



**Figure 2** Photomicrographs of Brunner gland cyst. **A.** Low-power view showing a cystic space in the submucosa immediately underneath the muscularis mucosae (H&E; original magnification X100). **B.** High-power view showing that the cyst was lined by a single layer of tall columnar epithelium with no cytologic atypia (H&E; original magnification X400).

in these cases.

### Discussion

In this brief report, we describe three cases of a rare clinicopathologic entity of Brunner gland cyst as a reminder of its existence, which should be included in the differential diagnosis of duodenal polyp or nodule. Soft and submucosal appearance and rupture or flattening of the lesions following endoscopic biopsies may provide a clue to the diagnosis. This lesion is completely benign and typically discovered incidentally. It has been suggested that Brunner gland cyst be a retention cyst probably secondary to obstruction of a major Brunner gland duct [4, 11].

Brunner gland cysts have been variably termed cyst of Brunner's glands [4], Brunner's gland cystadenoma [5], Brunner's cyst [6], cystic hamartoma of Brunner's glands [7], mucocele of Brunner's glands [8], and cystic Brunner's

gland hamartoma [10]. Importantly, they differ from Brunner gland hamartoma, adenoma or hyperplasia histologically in that the latter lesions are composed of solid aggregates of Brunner glands, sometimes admixed with fibromuscular, adipose and/or lymphoid tissues. Mild dilatation of the ducts may be present in these lesions,<sup>1</sup> but hyperplastic lobules of Brunner gland acini without cystically dilated spaces constitute the predominant portion of the lesions. In contrast, hyperplasia of the Brunner glands is not characteristically seen in Brunner gland cyst.

*Please address all correspondences to Hanlin L. Wang, MD, PhD, Department of Pathology and Laboratory Medicine, Cedars-Sinai Medical Center, 8700 Beverly Boulevard, Los Angeles, CA 90048, USA. Tel: 310-423-9533; Fax: 310-423-0122; Email: [hanlin.wang@cshs.org](mailto:hanlin.wang@cshs.org)*

### References

## Powers et al/Brunner Gland Cyst

- [1] Levine JA, Burgart LJ, Batts KP and Wang KK. Brunner's gland hamartomas: clinical presentation and pathological features of 27 cases. *Am J Gastroenterol* 1995;90:290-294.
- [2] Patel ND, Levy AD, Mehrotra AK and Sobin LH. Brunner's gland hyperplasia and hamartoma: imaging features with clinicopathologic correlation. *AJR Am J Roentgenol* 2006;187: 715-722.
- [3] Rankin FW and Newell CE. Benign tumors of the small intestine. *Surg Gynec Obstet* 1933; 57:501-507.
- [4] Hatley W. Cyst of Brunner's glands. *Br J Radiol* 1968;41:384-385.
- [5] Wolk DP, Knapper WH and Farr GH. Brunner's gland cystadenoma of the duodenum. *Am J Surg* 1973;126:439-440.
- [6] Taura M, Taura S, Kummerow FA, Noritomi S and Iwanaga S. An ultrastructural study of the Brunner's cyst. *Gastroenterol Jpn* 1977;12: 241-244.
- [7] Golan J, Dollberg L, Dollberg M, Farkash T and Rivkin L. Cystic hamartoma of Brunner's glands. *Int Surg* 1978;63:173-175.
- [8] Fisher JK. Mucocele of a Brunner gland. *Radiology* 1980;136:320.
- [9] Chatelain D, Maillet E, Boyer L, Checkouri G, Mourra N and Flejou JF. Brunner gland hamartoma with predominant adipose tissue and ciliated cysts. *Arch Pathol Lab Med* 2002; 126:734-735.
- [10] Yamakawa M, Murata I, Yamao T, Kawai K and Kohno S. Cystic Brunner's gland hamartoma. *Gastrointest Endosc* 2003;57:919.
- [11] Varnholt H, Gang DL, Desilets DJ and Pantanowitz L. Brunner gland cyst. *Int J Surg Pathol* 2007;15:64-65.