

Case Report

Langerhans cell histiocytosis (LCH) occurring in the skull: report of 3 cases and review of the literature

Jincheng Fang*, Zhiquan Jiang*

*Department of Neurosurgery, The First Affiliated Hospital, Bengbu Medical College, Bengbu, Anhui, China. *Equal contributors and co-first authors.*

Received October 13, 2016; Accepted November 23, 2016; Epub January 1, 2017; Published January 15, 2017

Abstract: Langerhans cell histiocytosis (LCH) is a far-between disease of unknown etiology and is characterized by a clonal proliferation of Langerhans cells from single organ to multisystem involvement. Here we report 3 cases which lesions occurring in the head of the skull: right temporal bone, right occipital bone and the left frontal temporal bone. Microsurgical resection of lesions was performed, and the pathologic diagnosis was LCH. Because of its infrequency and possibly variable display, LCH should be considered and included in the differential diagnosis at the time when we encounter head of the skull placeholder.

Keywords: Langerhans cell histiocytosis, LCH, head of the skull, temporal bone, occipital bone, frontal temporal bone, and placeholder

Introduction

Langerhans cell histiocytosis (LCH) is a far-between condition characterized by neoplastic proliferation of Langerhans cells [1]. The etiology is still unclear, common hypotheses include uncontrolled and irregular multiplication of lymphocytes and histiocytes after a gene mutation or infection, some fragmentary manifestations are not believed to be of a reactive pattern though but effectively represent real neoplasms [2, 3]. Although it's can be diagnosed in any age group, a majority of LCH affects children between 1 and 4 years of age with a morbidity 5-6 cases per million children [4, 5]. Head and neck involvement, primarily skull base, is noted in about 60% of the cases [6]. It's involving the head of the skull region is uncommon and can resemble malignant excrescences on imaging due to high cellularity. One of the most continual presenting imaging features is osteal involvement with lytic lesions according to their clinical and pathologic features. Although understanding the presence of sharp margins with beveled-edges can be helpful, tissue sampling is usually necessary for confirming the diagnosis [7]. But head of the skull lesions are

extremely rare. Almost no related articles report characteristic imaging of LCH occurring in head of the skull lesions up to now. We report 2 male teenager patients and a female adult with head of the skull Langerhans cell histiocytosis, with a literature review.

Case report

Case 1

A 12-year-old male with pain in the right temporal half for half month and aggravated with right eyelid swelling for a week. And there was no history of trauma. Computed tomography (CT) multiplanar reconstruction images revealed the irregular soft tissue mass in the right temporal bone and Enhanced CT showed lesions significantly enhanced (**Figure 1**). On magnetic resonance imaging (MRI), the lesion showed low signal intensity on T1-weighted images and mixed-signal intensity on T2-weighted images (**Figure 2**). There were no other lesions in the systemic survey. All laboratory results were normal.

Microsurgical resection of the lesion was performed, and histopathologic examination re-

Langerhans cell histiocytosis (LCH) in the skull

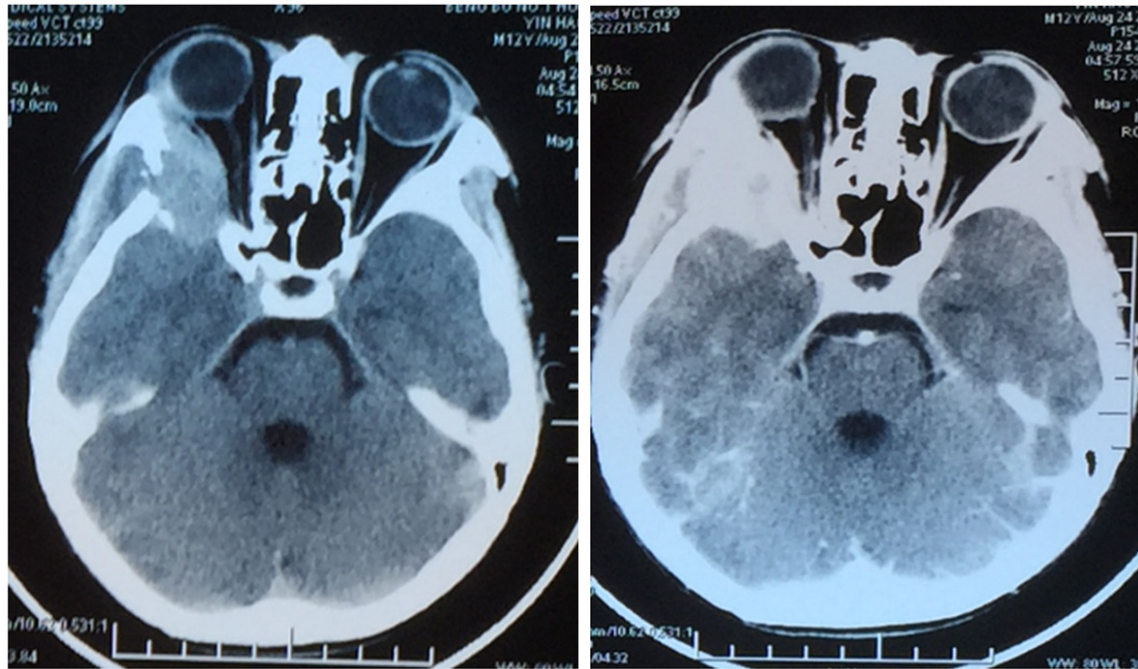


Figure 1. CT multiplanar reconstruction images show an irregular soft tissue mass in the right temporal fossa and Enhanced CT showed lesions significantly enhanced.

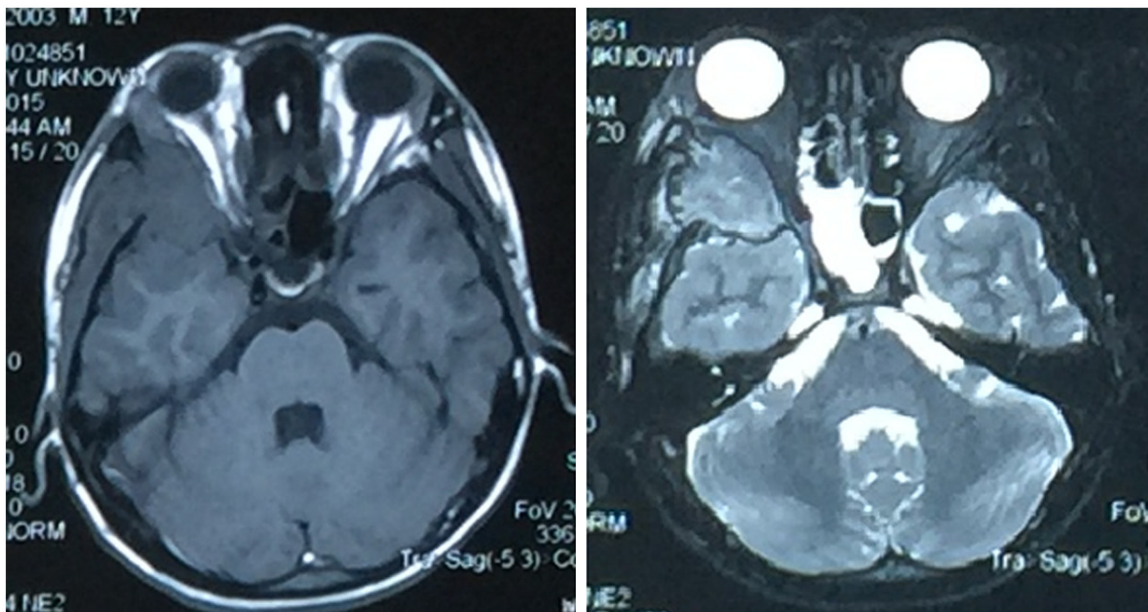


Figure 2. Magnetic resonance imaging (MRI), the lesion showed low signal intensity on T1-weighted images and mixed-signal intensity on T2-weighted images.

revealed a proliferation of histiocytes with an infiltration of eosinophils. Immunohistochemically, these histiocytes were positive for S100 (+++), CD1a (+++), CD68 (++) and LCA (++) (**Figure 3**).

A diagnosis of LCH was made. Postoperative recovery was good, one month after surgery, review of head MRI found the right temporal fossa good recovery (**Figure 4**).

Langerhans cell histiocytosis (LCH) in the skull

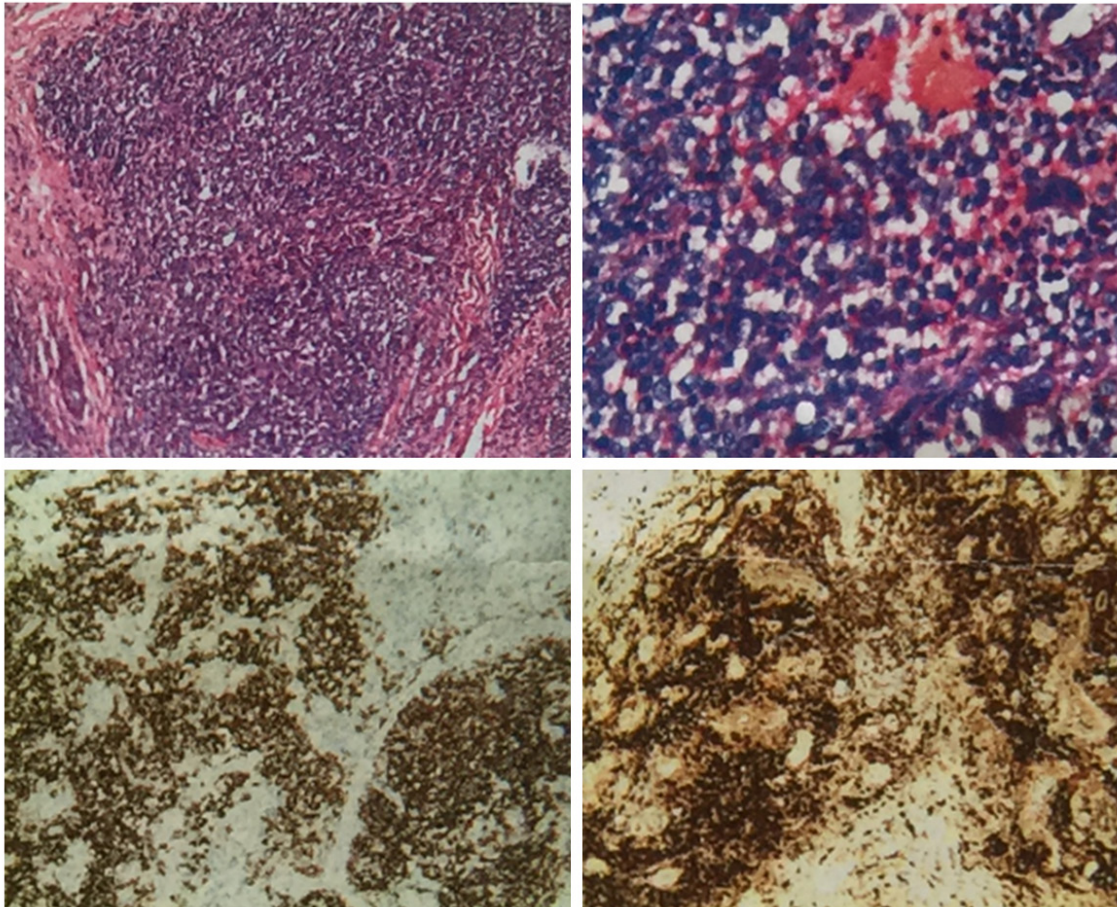


Figure 3. Histopathologic examination (100×) reveals proliferation of histiocytes with an infiltration of eosinophils. Immunohistochemically, these histiocytes were positive for S100 (+++), CD1a (+++), CD68 (++) and LCA (++)

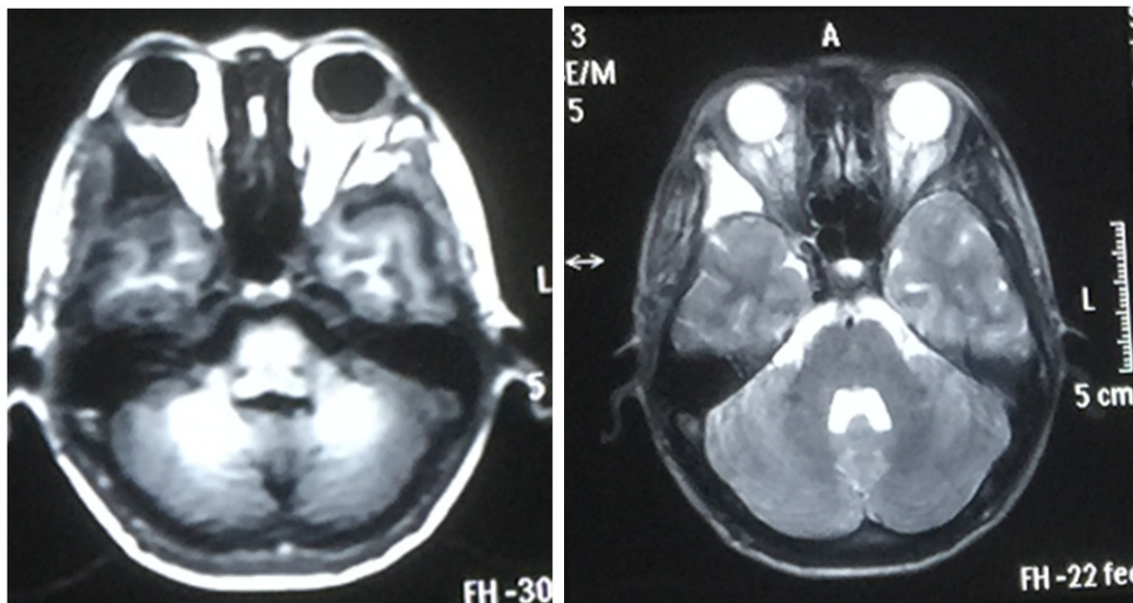


Figure 4. One month after surgery, review of head MRI showed complete resection of the lesion, with good recovery.

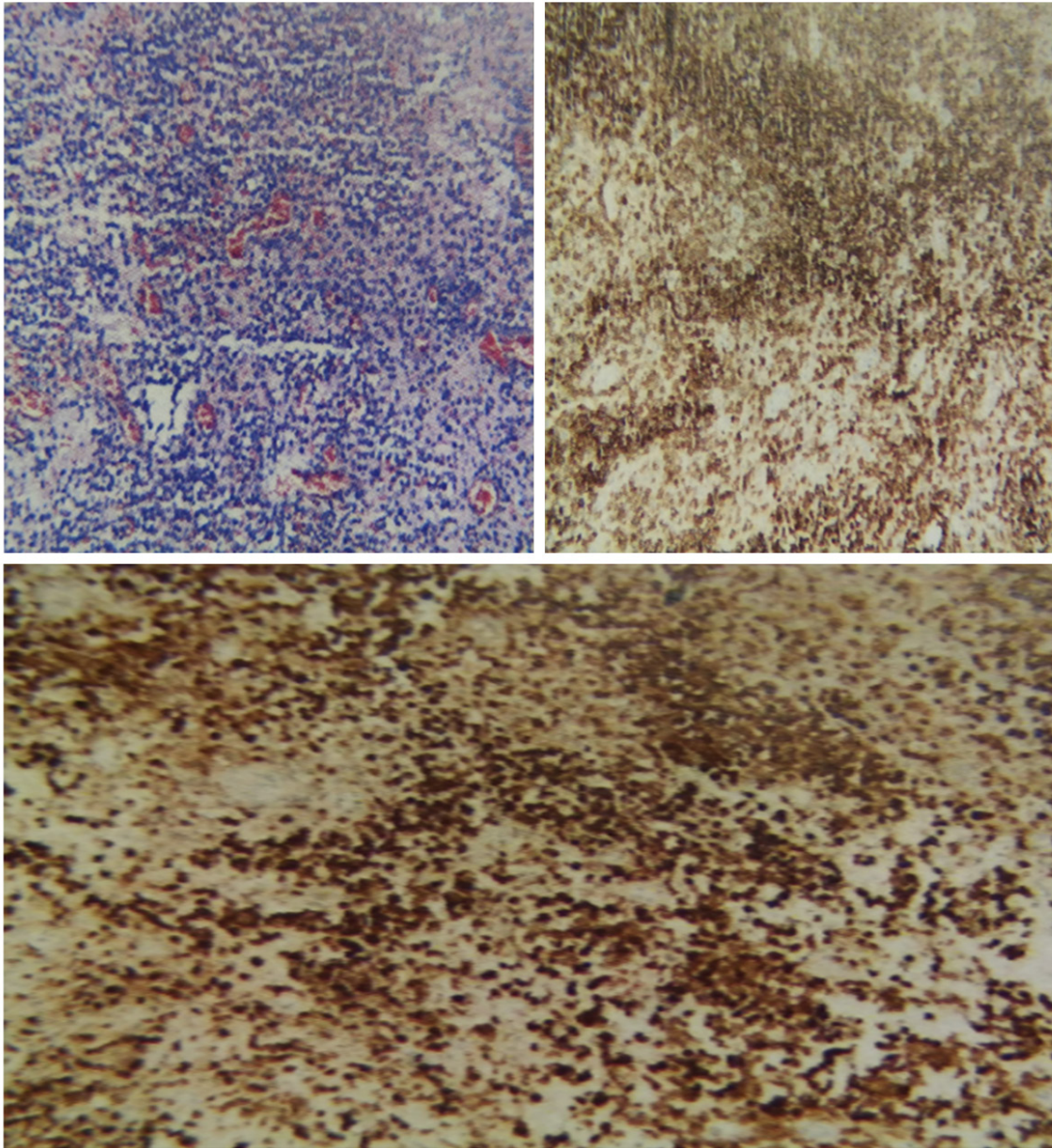


Figure 5. Histopathologic examination (100×) reveals proliferation of histiocytes with an infiltration of eosinophils. Immunohistochemically, these histiocytes were positive for S100 (+), CD1a (+), CD163 (+), Ki67 (+, 15%), GFAP (-), Syn (-).

Case 2

A 53-year-old female with pain in the left fronto-temporal for 20 days and local could sense vascular pulsation. Radiograph, computed tomography and magnetic resonance imaging showed an irregular soft tissue mass (3*3 cm), Corresponding brain parenchyma Oppressed. After microsurgical resection of the lesion was performed, histopathologic examination revealed a proliferation of histiocytes with an infil-

tration of eosinophils. Immunohistochemically, these histiocytes were positive for S100 (+), CD1a (+), CD163 (+), Ki67 (+, 15%), GFAP (-), Syn (-) (**Figure 5**).

Case 3

A 15-year-old male with pain in the right occipital for a month, excision of scalp lump was performed at local hospital. However, lesions were not completely removed, reviewed computed

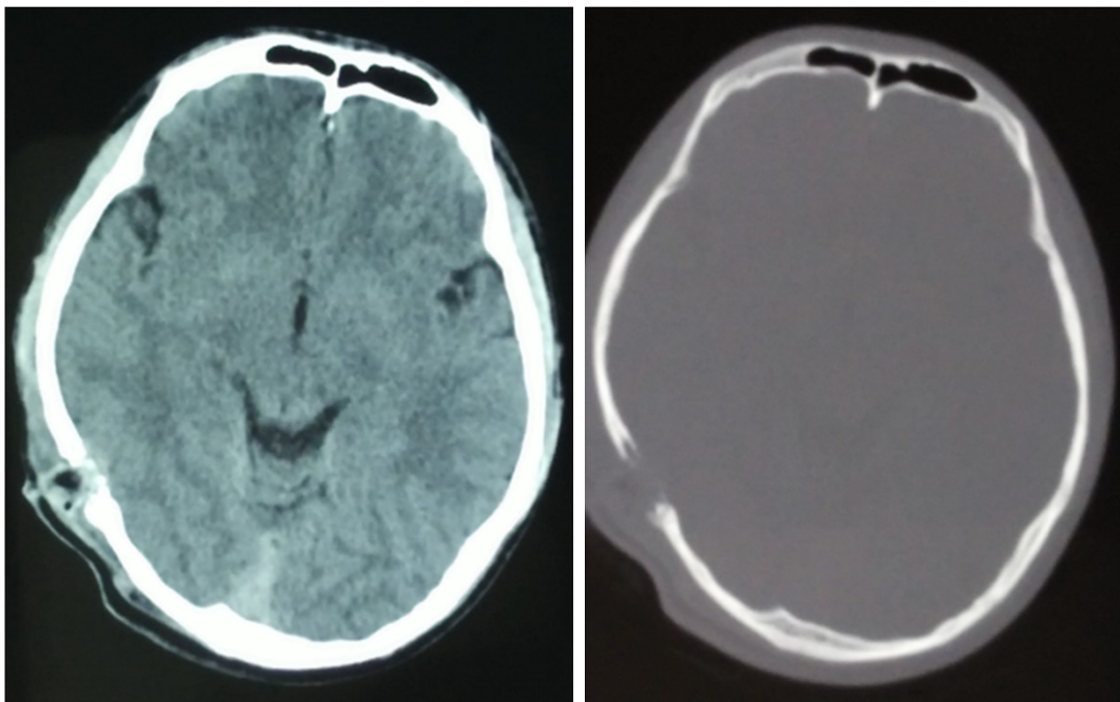


Figure 6. CT multiplanar reconstruction images show an irregular soft tissue mass in the right occipital region.

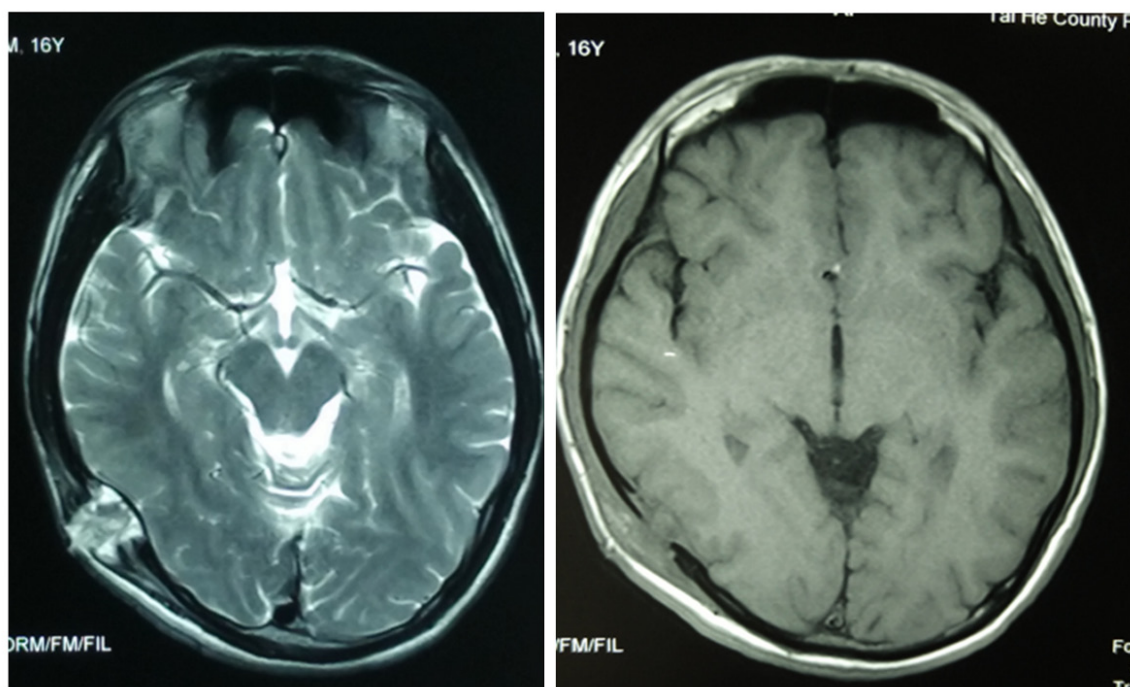


Figure 7. Magnetic resonance imaging (MRI), the lesion showed low signal intensity on T1-weighted images and mixed-signal intensity on T2-weighted images.

tomography and magnetic resonance imaging showed an irregular soft tissue mass (2*2 cm)

(**Figure 6**). On magnetic resonance imaging (MRI), the lesion showed low signal intensity on

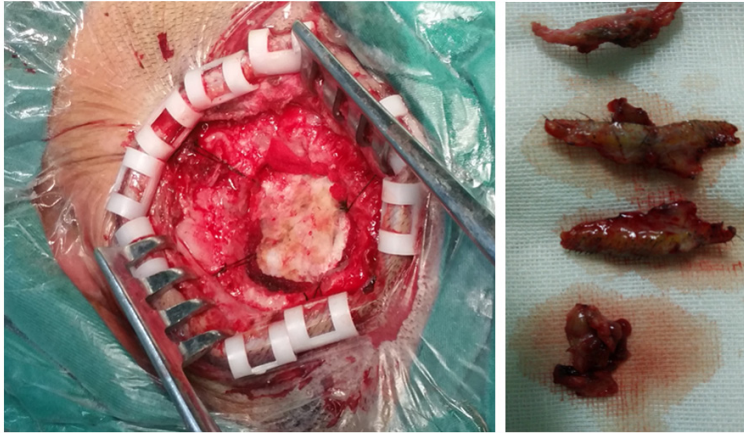


Figure 8. Microsurgical resection of the lesion was performed, microsurgical resection of the lesion was performed, and lesions of bone and soft tissue were excised.

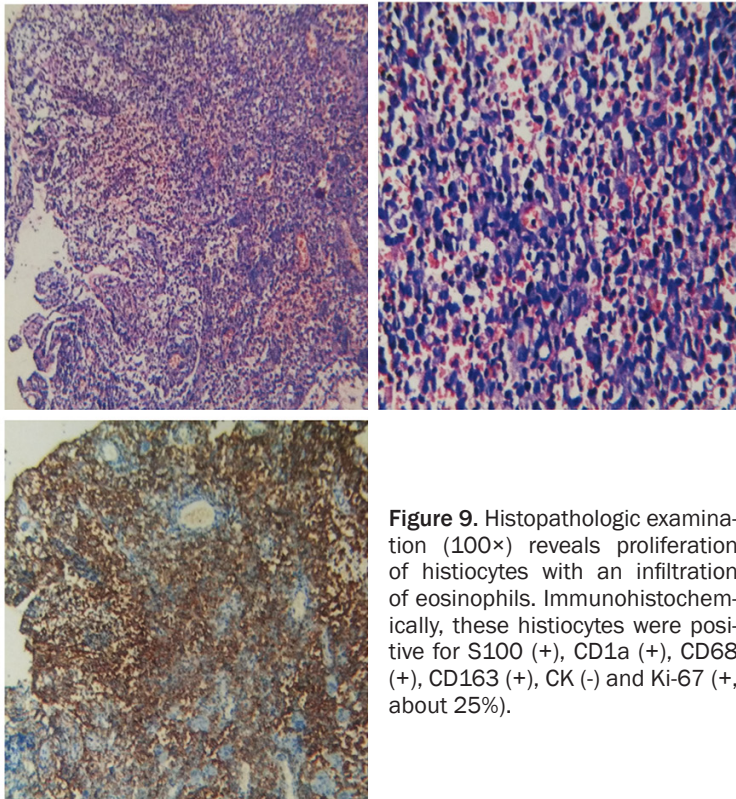


Figure 9. Histopathologic examination (100×) reveals proliferation of histiocytes with an infiltration of eosinophils. Immunohistochemically, these histiocytes were positive for S100 (+), CD1a (+), CD68 (+), CD163 (+), CK (-) and Ki-67 (+, about 25%).

T1-weighted images and mixed-signal intensity on T2-weighted images (**Figure 7**).

Microsurgical resection of the lesion was performed; lesions of bone and soft tissue were excised. And histopathologic examination revealed a proliferation of histiocytes with an

infiltration of eosinophils (**Figure 8**). Immunohistochemically, these histiocytes were positive for S100 (+), CD1a (+), CD68 (+), CD163 (+), CK (-) and Ki-67 (+, about 25%) (**Figure 9**). One week after surgery, review of head CT showed complete resection of the lesion, with good recovery (**Figure 10**).

Discussion

Langerhans cell histiocytosis is an abnormal proliferation of tissue macrophages. It's a disease which frustrates both clinician and scientist. The etiology is unknown, its pathogenesis is ill understood and the clinical course is unpredictable. LCH has a wide clinical spectrum and prognosis varies accordingly. Patient age ranges from 5 to 15 years in about 90% of the cases with a slight male predominance [8, 9]. In older children 'single system' disease, usually affecting bone, is a common presentation and may spontaneously regress or require minimal treatment. In the current international LCH trial, 122 of 225 registered patients have single system disease and in all of these the disease is confined to bone (Gadner H, personal communication, 1993). LCH confined to skin or to lymph nodes has, also been reported [10, 11]. However, few lesions confined to brain, in particular, occur in the temporal fossa, occipital bone or frontal temporal bone. We report 3 cases which lesions occurring in the head of the skull: right temporal bone, right occipital bone and the left frontal temporal bone. Tumors and tumorous lesions of the brain should be excluded, such as meningioma, osteoma, eosinophilic granuloma and gliomas. Meningiomas often cause skull inner, outer

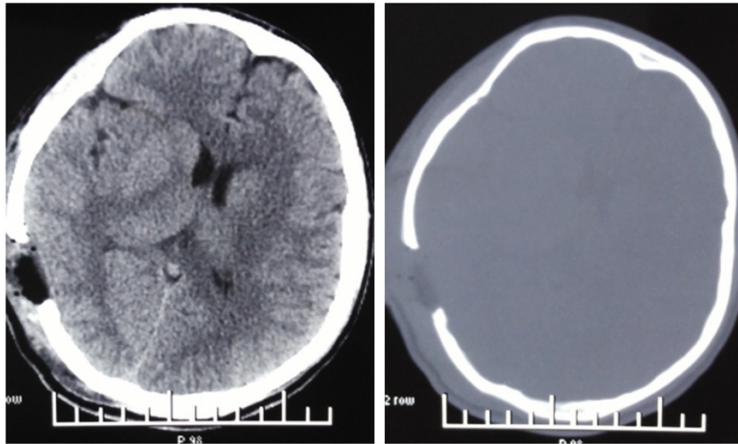


Figure 10. One week after surgery, review of head CT showed complete resection of the lesion, with good recovery.

panels and boards barrier hyperplasia; besides, we can see dural tail sign on CT and MRI. Osteoma lesions always developed to outside of the head, few violations of brain tissue. Gliomas are often widespread violations of brain. Although radiologic characteristics of the lesion did not indicate a diagnosis of LCH in the current case, the histopathologic diagnosis was LCH. We should stress that a diagnosis of LCH can only be finally made on histopathologic findings of a biopsy. An arrangement of histiocytosis in loose mesh-works or clusters and immunoreactivity for S-100 and CD1a antigens are helpful for the diagnosis of LCH [11]. Because of its rarity and possibly variable presentation, the diagnosis of LCH may be overlooked or neglected. When we encounter temporal fossa placeholder, it might be difficult to remember the possibility of LCH.

Treatment of LCH depends on the extent of the disease. Various forms of treatment for a lesion affecting brain have been attempted, which include resection, local steroid injection, radiotherapy, and chemotherapy alone or in combination. The results of treatment of solitary lesions are always satisfactory, although recurrence occurs in some patients (11%) [12]. In contrast, multifocal and multisystem types of LCH are generally treated with chemotherapy, in combination with other therapeutic modalities. In these patients, Microsurgical resection of the lesion was performed.

Disclosure of conflict of interest

None.

Address correspondence to: Zhiqian Jiang, Department of Neurosurgery, The First Affiliated Hospital, Bengbu Medical College, Bengbu, Anhui, China. E-mail: bbjiangzhq@163.com

References

- [1] Saxena T, Kumar K, Sen S, Tandon R. Langerhans cell histiocytosis presenting as a limbal nodule in an adult patient. *Am J Ophthalmol* 2004; 138: 508-10.
- [2] Postini AM, Andreacchio A, Boffano M, Pagano M, Brach Del Prever A, Fagioli F. Langerhans cell histiocytosis of bone in children. *J Pediatr Orthop B* 2012; 21: 457-62.
- [3] Aricò M, Danesino C. Langerhans' cell histiocytosis: is there a role for genetics? *Haematologica* 2001; 86: 1009-14.
- [4] Saliba I, Sidani K, El Fata F, Arcand P, Quintal MC, Abela A. Langerhans' cell histiocytosis of the temporal bone in children. *Int J Pediatr Otorhinolaryngol* 2008; 72: 775-86.
- [5] Nicollas R, Rome A, Belaïch H, Roman S, Volk M, Gentet JC, Michel G, Triglia JM. Head and neck manifestation and prognosis of Langerhans' cell histiocytosis in children. *Int J Pediatr Otorhinolaryngol* 2010; 74: 669-73.
- [6] Coleman MA, Matsumoto J, Carr CM, Eckel LJ, Nageswara Rao AA. Bilateral temporal bone langerhans cell histiocytosis: radiologic pearls. *Open Neuroimag J* 2013; 7: 53-7.
- [7] Ginat DT, Johnson DN, Cipriani NA. Langerhans cell histiocytosis of the temporal bone. *Head Neck Pathol* 2016; 10: 209-12.
- [8] Islinger RB, Kuklo TR, Owens BD, Horan PJ, Choma TJ, Murphey MD, Temple HT. Langerhans' cell histiocytosis in patients older than 21 years. *Clin Orthop Relat Res* 2000; 379: 231-5.
- [9] Stull MA, Kransdorf MJ, Devaney KO. Langerhans cell histiocytosis of bone. *Radiographics* 1992; 12: 801-23.
- [10] Broadbent V, Egeler RM, Nesbit ME Jr. Langerhans cell histiocytosis-clinical and epidemiological aspects. *Br J Cancer Suppl* 1994; 23: S11-6.
- [11] Hoover KB, Rosenthal DI, Mankin H. Langerhans cell histiocytosis. *Skeletal Radiol* 2007; 36: 95-104.
- [12] Howarth DM, Gilchrist GS, Mullan BP, Wiseman GA, Edmonson JH, Schomberg PJ. Langerhans cell histiocytosis: diagnosis, natural history, management, and outcome. *Cancer* 1999; 85: 2278-90.