

## Case Report

# Primary merkel cell carcinoma of the oral mucosa: a case report with review of literature

Seung-Myoung Son<sup>1</sup>, Chang Gok Woo<sup>1</sup>, Kyoung Won Kim<sup>2,3</sup>, Ho-Chang Lee<sup>1,3</sup>, Ok-Jun Lee<sup>1,3</sup>

Departments of <sup>1</sup>Pathology, <sup>2</sup>Oral and Maxillofacial Surgery, Chungbuk National University Hoispital, <sup>3</sup>Chungbuk National University College of Medicine, Cheongju, Seowon-Gu, Korea

Received May 8, 2017; Accepted June 20, 2017; Epub October 1, 2017; Published October 15, 2017

**Abstract:** We present a case of primary Merkel cell carcinoma in the oral mucosa of a 60-year-old man. The patient underwent incisional biopsy of the tumor. Histologically, the tumor was composed of small monotonous cells in a solid sheet-like and single-cell row growth pattern. Immunohistochemically, tumor cells were positive for pan-cytokeratin, CD56, and synaptophysin, and negative for leukocyte common antigen, vimentin, S-100 protein, HMB-45, and thyroid transcription factor 1. Cytokeratin 20 staining showed a paranuclear dot-like pattern in tumor cells. Therefore, the diagnosis of Merkel cell carcinoma was made. The patient received chemotherapy with etoposide and cisplatin followed by 62 Gy radiation in 31 fractions over seven weeks. Follow-up brain CT scans after three and five months showed complete remission of the mass and enlarged lymph node. He is currently doing well with no evidence of recurrence. The present case is the first report of Merkel cell carcinoma arising in the buccal vestibule. The patient is currently doing well with no evidence of recurrence at six months.

**Keywords:** Merkel cell carcinoma, oral mucosa, CK20, review

## Introduction

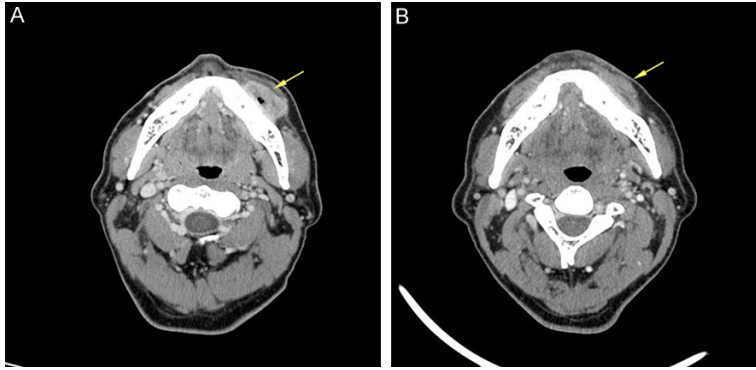
Merkel cell carcinoma (MCC) is a rare cutaneous neuroendocrine carcinoma that predominantly occurs in the sun-exposed skin of the elderly [1]. It is an aggressive malignancy characterized by frequent local recurrence, regional lymph node metastasis, and distant spread [2]. MCC occurs mainly on the face and neck regions, whereas mucosal MCC is rare [3]. The first case of an oral mucosal MCC was reported in 1988 [4]. Several case reports of MCC in the oral mucosa have been published, including tumors arising in the mucobuccal fold, labial mucosa, and glossopharyngeal, palatal, and alveolar mucosa [2, 4-10]. We report a case of primary MCC arising in the buccal vestibule in an adult male. To the best of our knowledge, this is the first report of MCC arising in the buccal vestibule.

## Case report

A 60-year-old man was referred to the Department of Oral and Maxillofacial Surgery with a painful mass in the left mandible identi-

fied by a general dentist. The mass had been detected three months prior to presentation with swelling and discharge. An orthopantomogram and a facial bone computed tomography (CT) scan revealed a 3.3 cm enhancing mass with necrosis originating from the left lower buccal vestibular area. The outer margin of the mass was well-delineated (**Figure 1A**). Based on suspicion of malignancy such as lymphoma, an incisional biopsy was performed.

Microscopic examination of the biopsy specimen revealed a highly cellular mass in the lamina propria of the oral mucosa with ulceration of non-keratinized surface epithelium. The tumor cells invaded downward through the connective tissue of the lamina propria (**Figure 2A**). The tumor was composed of small monotonous cells in a solid sheet-like and single-cell row growth pattern (**Figure 2B**). The tumor cells had round to ovoid nuclei and a scant eosinophilic cytoplasmic rim. Nuclei showed a finely granular and dusty chromatin with inconspicuous nucleoli (**Figure 2C**). Numerous mitotic figures and areas of necrosis were observed.



**Figure 1.** A. Pre-treatment computed tomography (CT) scan of head and neck revealed a 3.3-cm-sized well defined enhancing mass originating from the left lower buccal vestibular area. B. Postchemotherapy and radiotherapy CT scan after 3 months of diagnosis shows no residual mass.

**Table 1** summarizes the details of antibodies we used. Immunohistochemistry revealed that tumor cells were diffuse and strong positive for both CD56 and synaptophysin, indicating neuroendocrine differentiation (**Figure 2D**). Pancytokeratin immunostaining was also diffuse and strong. Cytokeratin 20 (CK 20) staining in tumor cells showed a homogeneous paranuclear dot-like pattern, which is a specific feature of MCC (**Figure 2E**). Tumor cells showed negative immunoreactivity to leukocyte common antigen (LCA), vimentin, S-100 protein, HMB-45, and thyroid transcription factor 1 (TTF-1).

Although lymph node enlargement was detected at left neck level 1b, further surgical treatment was not performed. The patient received chemotherapy with etoposide and cisplatin followed by 62 Gy radiation in 31 fractions over seven weeks. Follow-up brain CT scans after three and five months showed complete remission of the mass and enlarged lymph node (**Figure 1B**). The patient is currently doing well with no evidence of recurrence at six months after the diagnosis of MCC.

### Discussion

MCC is a rare neuroendocrine neoplasm arising from Merkel cells [11], which are present in the basal epidermal layer, hair follicles, and oral mucosa, as complexes with sensory axons [10]. MCC most commonly develops in the sun-exposed skin of the head and neck region and rarely occurs in the mucosal membrane [11]. Exposure to sun plays a role in the development of MCC of the skin and lower lip [12]; how-

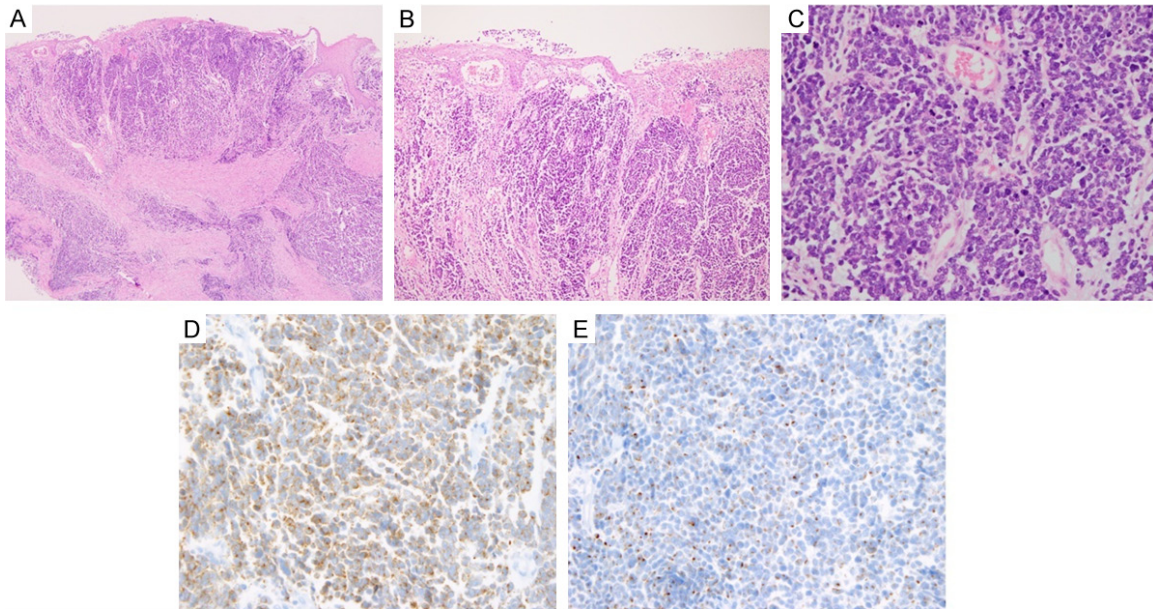
ever, environmental risk factors for intraoral MCC have not been identified to date [13]. The presence of Merkel Cell Polyomavirus (MCPyV) in most cases of MCC was first reported in 2008 [14]. However, because seroprevalence of MCPyV among the general population is high, any direct effect of the virus on cancer remains controversial [15].

Since the first report by Mir *et al.* [4] in 1988, eight cases originating from the intraoral mucosa have been reported (**Table 1**). Our case is the first report of MCC arising in the buccal vestibule. MCC typically occurs in the sixth and seventh decades with a slight male predominance [16]. Our reviews revealed a strong male predominance (88.9%) with an age range of 14 to 73 years (77.8%).

Microscopically, MCC is composed of small undifferentiated cells with a solid sheet or trabecular pattern. The tumor cells have scant cytoplasm, round and vesicular nuclei with finely granular chromatin, and multiple nucleoli. Because of their resemblance to other small round blue cell tumors, including small cell neuroendocrine carcinoma, extraskeletal Ewing sarcoma/primitive neuroectodermal tumor, lymphoma, neuroblastoma, amelanotic melanoma, and poorly differentiated squamous cell carcinoma, immunohistochemical confirmation is required.

Tumor cells showed positive immunoreactivity for pan-cytokeratin, CD56, and synaptophysin and negative immunoreactivity for vimentin, LCA, HMB-45, and S100 protein. Taken together, these findings excluded a diagnosis of extraskeletal Ewing sarcoma/primitive neuroectodermal tumor, lymphoma, neuroblastoma, and amelanotic melanoma. Furthermore, a distinctive paranuclear dot-like pattern of CK20 positivity was noted, which is a characteristic feature of MCC together with the expression of the neuroendocrine markers CD56 and synaptophysin. Additionally, TTF-1, which is negative in MCC but positive in small cell carcinoma, was negative in our case [17].

## Merkel cell carcinoma of the oral mucosa



**Figure 2.** A. The epicenter of tumor was located in the lamina propria of oral mucosa, covered by thin thin non-keratinized squamous epithelium. The tumor cells invaded downward through a connective tissue layer. B. The tumor was composed of small monotonous cells that were arranged in solid sheets and in single cell rows (magnification,  $\times 40$ ). C. The tumor cells had round to ovoid nuclei with finely granular chromatin and inconspicuous nucleoli (magnification,  $\times 400$ ). D. The immunostaining for synaptophysin was diffuse positive (magnification,  $\times 400$ ). E. The tumor cells showed paranuclear dot-like immunopositivity for cytokeratin 20 (magnification,  $\times 400$ ).

**Table 1.** Antibodies and dilutions used in immunohistochemical analyses

Antibody	Clone	Dilution	Source
Pan-cytokeratin	AE1/AE3	1:300	Novocastra
CK20	Ks20.8	1:100	Novocastra
CD56	123C3.D5	1:200	Cell Marque
Synaptophysin	SP11	1:20	Neomarkers
LCA	X16/99	1:50	Novocastra
Vimentin	V9	1:300	Cell Marque
S-100	S-100	1:800	Dako
HMB-45	HMB-45	1:100	Cell Marque
TTF-1	SPT24	1:200	Novocastra

MCC shows an aggressive clinical course with frequent local recurrence and regional metastasis. The three-year survival rate is 31-68% and the local recurrence rate is 55-79% [8]. Because of the rarity of mucosal MCC, there are no definite guidelines for treatment. For cutaneous MCC, the primary modality remains surgical excision with a margin of 2-3 cm [18]. Postoperative radiation therapy is generally recommended for locoregional control [19]. The tumor is generally radiosensitive, and radiotherapy is sometimes used as the primary treatment with curative intent [10]. The role of

chemotherapy remains controversial in patients with nonmetastatic disease. *Vogo et al.* reported that MCC is chemosensitive but not chemocurable [20]. Although many chemotherapy regimens show positive results, no survival benefit has been conclusively demonstrated [8].

The biological behavior of MCC of the oral mucosa is not fully understood; however, four out of eight reported oral MCCs resulted in recurrence or metastasis within approximately two years or less from the time of their initial diagnoses (**Table 2**).

Our case represents a rare occurrence of primary MCC presenting as an oral mucosal lesion with neck lymph node enlargement. The patient underwent incisional biopsy and subsequently received radiotherapy and chemotherapy. Although intraoral MCC is extremely rare, it should be included in the differential diagnosis of a small round cell tumor occurring in the oral mucosa, as early and prompt diagnosis could facilitate appropriate treatment and may improve the prognosis.

### Disclosure of conflict of interest

None.

## Merkel cell carcinoma of the oral mucosa

**Table 2.** Clinical features of previously reported cases of Merkel cell carcinoma arising in the oral mucosa

Reference	Age (years)	Sex	Site	Surgical treatment	Radio-therapy	Chemo-therapy	Outcome
Mir et al. [4]	53	M	Right posterior mandibular border	Right hemimandibulectomy and supraomohyoid neck dissection	No	No	No follow up
Hayter et al. [2]	73	M	Right buccal sulcus	Excision	Yes	No	Wide metastasis, died after 8 months
Inoue et al. [5]	14	F	Hard palate	Partial maxillary resection	No	No	Recurrence at 1 year and died
Longo et al. [6]	63	M	Floor of mouth	Wide resection	Yes	Yes	Recurrence and died at 26 months
Baker et al. [7]	49	M	Floor of mouth	Excision, right marginal mandibulectomy and right neck dissection	No	No	Died due to postoperative multiorgan failure
Yom et al. [8]	57	M	Tongue	Excision	Yes	Yes	Recurrence and wide metastasis at 6 weeks
Prabhu et al. [9]	28	M	Right mandibular alveolar mucosa	Right hemimandibulectomy and radical neck dissection	Yes	No	No recurrence for 18 months
Roy et al. [10]	15	M	Floor of mouth	Excision	Yes	Yes	No recurrence for 9 months
Present case	60	M	Left lower buccal vestibular area	Not performed	Yes	Yes	No recurrence for 6 months

**Address correspondence to:** Dr. Ok-Jun Lee, Department of Pathology, Chungdae-ro 1, Cheongju 28644, Seowon-Gu, Korea; Chungbuk National University College of Medicine, Chungdae-ro 1, Cheongju 28644, Seowon-Gu, Korea. Tel: +82-43-269-6260; Fax: +82-43-269-6269; E-mail: ok5218@hanmail.net

### References

- [1] Koljonen V. Merkel cell carcinoma. *World J Surg Oncol* 2006; 4: 7.
- [2] Hayter JP, Jacques K and James KA. Merkel cell tumour of the cheek. *Br J Oral Maxillofac Surg* 1991; 29: 114-116.
- [3] Medina-Franco H, Urist MM, Fiveash J, Heslin MJ, Bland KI and Beenken SW. Multimodality treatment of Merkel cell carcinoma: case series and literature review of 1024 cases. *Ann Surg Oncol* 2001; 8: 204-208.
- [4] Mir R, Sciubba JJ, Bhuiya TA, Blomquist K, Zelig D and Friedman E. Merkel cell carcinoma arising in the oral mucosa. *Oral Surg Oral Med Oral Pathol* 1988; 65: 71-75.
- [5] Inoue T, Shimono M, Takano N, Saito C and Tanaka Y. Merkel cell carcinoma of palatal mucosa in a young adult: immunohistochemical and ultrastructural features. *Oral Oncol* 1997; 33: 226-229.
- [6] Longo F, Califano L, Mangone GM and Errico ME. Neuroendocrine (Merkel cell) carcinoma of the oral mucosa: report of a case with immunohistochemical study and review of the literature. *J Oral Pathol Med* 1999; 28: 88-91.
- [7] Baker P and Alguacil-Garcia A. Moderately differentiated neuroendocrine carcinoma in the floor of the mouth: a case report. *J Oral Maxillofac Surg* 1999; 57: 1143-1147.
- [8] Yom SS, Rosenthal DI, El-Naggar AK, Kies MS and Hessel AC. Merkel cell carcinoma of the tongue and head and neck oral mucosal sites. *Oral Surg Oral Med Oral Pathol Oral Radiol Endod* 2006; 101: 761-768.
- [9] Prabhu S, Smitha RS and Punnya VA. Merkel cell carcinoma of the alveolar mucosa in a young adult: a rare case report. *Br J Oral Maxillofac Surg* 2010; 48: 48-50.
- [10] Roy S, Das I, Nandi A and Roy R. Primary Merkel cell carcinoma of the oral mucosa in a young adult male: report of a rare case. *Indian J Pathol Microbiol* 2015; 58: 214-216.
- [11] Gioacchini FM, Postacchini V, Simonetti O, Ofidani A, Magliulo G and Re M. Merkel cell carcinoma: a systematic review of ENT presentations. *Eur Arch Otorhinolaryngol* 2013; 270: 2191-2199.
- [12] Agelli M and Clegg LX. Epidemiology of primary Merkel cell carcinoma in the United States. *J Am Acad Dermatol* 2003; 49: 832-841.
- [13] Mahomed F. Neuroendocrine cells and associated malignancies of the oral mucosa: a review. *J Oral Pathol Med* 2010; 39: 121-127.
- [14] Feng H, Shuda M, Chang Y and Moore PS. Clonal integration of a polyomavirus in human Merkel cell carcinoma. *Science* 2008; 319: 1096-1100.
- [15] Pink R, Ehrmann J, Molitor M, Tvrdy P, Michl P, Pazdera J and Hanuliak J. Merkel cell carcinoma. A review. *Biomed Pap Med Fac Univ Palacky Olomouc Czech Repub* 2012; 156: 213-217.
- [16] Nazarian Y, Shalmon B, Horowitz Z, Bedrin L, Pfeffer MR and Talmi YP. Merkel cell carcinoma



## Merkel cell carcinoma of the oral mucosa

- of unknown primary site. *J Laryngol Otol* 2007; 121: e1.
- [17] Leech SN, Kolar AJ, Barrett PD, Sinclair SA and Leonard N. Merkel cell carcinoma can be distinguished from metastatic small cell carcinoma using antibodies to cytokeratin 20 and thyroid transcription factor 1. *J Clin Pathol* 2001; 54: 727-729.
- [18] Eich HT, Eich D, Staar S, Mauch C, Stutzer H, Groth W, Krieg T and Muller RP. Role of postoperative radiotherapy in the management of Merkel cell carcinoma. *Am J Clin Oncol* 2002; 25: 50-56.
- [19] Lehrer MS, Hershock D and Ming ME. Merkel cell carcinoma. *Curr Treat Options Oncol* 2004; 5: 195-199.
- [20] Voog E, Biron P, Martin JP and Blay JY. Chemotherapy for patients with locally advanced or metastatic Merkel cell carcinoma. *Cancer* 1999; 85: 2589-2595.