

Original Article

Pathological and immunohistochemical features of radiation-induced liver disease in rats

Zhenhua Yang, Rong Zhang, Qian Wang, Yiming Wang

Department of Oncology, The First Affiliated Hospital of Jinan University, Guangzhou, China

Received November 23, 2016; Accepted November 27, 2016; Epub February 1, 2017; Published February 15, 2017

Abstract: Objective: The objective of this study was to improve understanding of the key pathological and immunohistochemical features of radiation induced liver disease and of associated liver regeneration and fibrosis, using a rat based model of radiation-induced liver injury. Methods: Female Sprague-Dawley rats were divided into two groups (n=40 per group). The control (non-irradiated) group was randomly divided into four sub-groups from which blood and liver tissue samples were obtained after 1, 2, 3 and 4 months respectively (n=10 per group). The experimental group were subjected to a single dose of 25 Gy radiation to the right liver lobe and then divided into four similar sub-groups (n=10 per group) from which blood and liver tissue samples were obtained 1, 2, 3 and 4 months post-irradiation. Tissue samples were stained with HE and Masson's stains to examine the pathology. Immunohistochemical and ELISA assays were used to detect and analyze the serum levels of ALT and AST enzymes and cytokines HGF, EGF and TGF- β in the liver tissues. Results: Serum levels of HGF, EGF and TGF- α , all of which are markers of tissue regeneration, were significantly higher in liver tissues of experimental group rats compared with those in the comparable control groups ($P < 0.05$). Expression levels of TGF β were also significantly higher in a range of liver cell types in the experimental compared with the control groups, especially 3 to 4 months post-irradiation. There were obvious pathological signs of liver fibrosis 3 and 4 months after radiation treatment in the experimental groups, which were lacking in the control groups, indicating continued damage to liver tissue had occurred several months after radiation treatment. Conclusions: A single dose of radiation treatment can result in significant liver tissue injury and the formation of liver fibrosis that continues for 3 to 4 months post-treatment, which may become irreversible. However, it also enhanced the production of certain cytokines involved in the proliferation and regeneration of liver cells to repair and promote proliferation of hepatic portal area.

Keywords: Rat, radiation induced hepatic injury, HGF, EGF, TGF- α , TGF- β

Introduction

The recent development of 3D conformational and intensity-modulated radiation therapies has fuelled an increase in the use of radiotherapy to treat primary liver carcinoma [1]. In order to improve the local control rate in liver cancers, the radiation dose of these therapies is gradually increased, resulting in radiation-induced liver injury (RILI), which is one of the most common complications of the treatment. Radiation-induced liver disease (RILD) is caused by radiation-induced injury to the liver tissue, resulting in a series of physiological and pathological changes occurring in hepatic cells in response to a certain dose of radiation. The clinical onset is occult, but once established, the disease will progress and is difficult to

reverse [2]. Therefore, early prevention is the key to reducing radiation-induced liver damage.

In this study, a radiation liver injury model was established by application of a single radiation dose of 25 Gy to the right hand liver lobe of Sprague Dawley (SD) rats, to mimic external radiation exposure. The liver tissues of SD female rats of a blank (non-irradiated) control group, and of irradiated rats 1, 2, 3, and 4 months post-radiation were extracted and stained with haematoxylin and eosin (HE) and with Masson's trichome stain, for microscopic analysis. In addition, immunohistochemistry analyses were carried out, including detection and measurement of TGF- β , HGF, EGF, and TGF- α . Changes in serum levels of alanine transami-

nase (ALT) and aspartate transaminase (AST) were also measured, as indicators of rat liver function. The aim was thus to characterize the microstructural and immunohistochemical features of chronic radiation-induced liver injury, in SD rats as a model animal, in order to provide a basis for the study of liver regeneration and hepatic fibrosis caused by radiation-induced liver injury.

Materials and methods

Experimental animals

Eighty specific-pathogen-free (SPF) grade 6 weeks old female SD rats (body weight, 180-220 g), were provided by Guangdong Medical Laboratory Animal Center (Guangdong, China). Eighty rats were randomly assigned to the experimental and control groups, each of which was (randomly) sub-divided into four groups (per CG, n=10; per EG, n=10), representing 1, 2, 3 or 4 months after irradiation with a single dose of 25 Gy to the right liver lobe, or after no irradiation, respectively. The number of rats in each experimental sub-group varied between a minimum of 8 and a maximum of 10.

Establishment of a radiation-induced liver injury model

Firstly, a radiation field was defined and set, for each individual animal. SD rats were administered with a 3% nembutal solution (100 mg/kg), prior to administration of an intraperitoneal local anesthesia. They were then fixed in the supine position before carrying out type-B ultrasonic location of the right lobe of the liver. The medial boundary was defined as the right margin of the spine, the upper boundary was the upper diaphragm, and the distance between the upper and lower boundary was 3 cm. The external boundary was open and the field size was about 3 cm by 3 cm. The boundaries of the radiation field were drawn on the body surface.

The radiation method employed a SIEMENS linear accelerator (6MV) to carry out irradiation to the right hand liver lobe. The solid state detector was 100 cm, the irradiation depth was 2 cm, and the irradiation dose rate was 200 cGy/min. The total dose of a single fraction irradiation was 25 Gy. All rats were given free access to diets and water ad libitum. This research was approved in accordance with Jinan University

Guidelines and Regulations on the Use and Care of Lab Animals.

Serum analysis and tissue microscopy

The experimental procedures that follow were each conducted on sera/tissue samples (as appropriate) from rats irradiated for 1, 2, 3, or 4 months, and for control rats at the same time points.

Serum immunological markers (ALT, AST, EGF, HGF, TGF- α) were measured by using an aorta abdominalis cannula to collect a 5 ml blood sample from each rat. Samples were centrifuged at 3000 rpm to extract sera which was then subjected to chemical analysis using a HITACHI biochemical analyzer and determined using standard kits (RapidBio Lab, CA, USA) to detect and measure levels of ALT and AST, and ELISA kits (Tongwei Co, China) to detect the concentrations of HGF, EGF and TGF- α .

After anesthesia, the right liver lobe was excised from the irradiated region, and fixed in 10% neutral formalin, before Paraffin embedding. Embedded samples were then sectioned (4 μ m thickness) and stained with HE stain and Masson's trichome stain, to observe the pathological changes of the liver tissue under an ordinary optical microscope. The extent of liver fibrosis observed by microscopy was graded as follows: 0, no fibrosis; 1, mild fibrosis (fibrous deposition located only in the central leaflet); 2, moderate fibrosis (fibrous deposition extending to the outside of the central leaflet but not reaching the leaflet margin); 3, severe liver fibrosis (fibrous deposition extending to the edge of the leaflet); 4, early cirrhosis [3].

The expression of TGF- β in liver tissue samples was estimated through immunohistochemistry method which was stained by TGF- β mouse anti-human monoclonal antibody. The intensity of staining of the tissue slices represents the relative proportion of TGF- β positive cells (among the total cells), and was judged by two pathologists using a double blind method for the observation of sections, and a semi-quantitative method to interpret the results. Scores were assigned to A: the percentage of TGF- β cells, and B: the intensity of positive staining. Scores for each of these categories were defined as follows. A: > 75% positive cells, 4

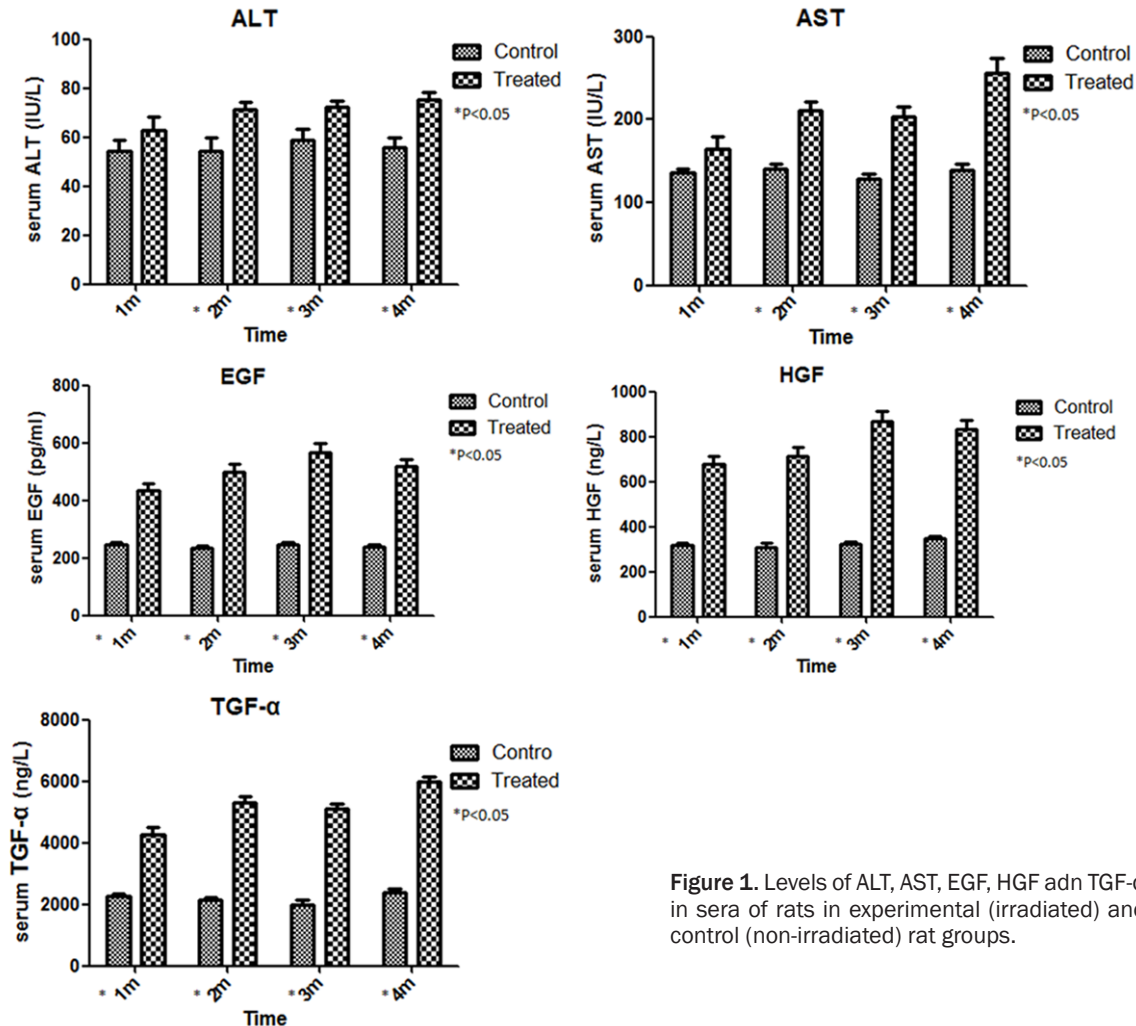


Figure 1. Levels of ALT, AST, EGF, HGF and TGF-α in sera of rats in experimental (irradiated) and control (non-irradiated) rat groups.

points; 51%-75% positive cells, 3 points; 26%-50% positive cells, 2 points; 6%-25% positive cells, 1 point; ≤ 5% positive cells, 0 points; B: colourless, 0 point; canary yellow: 1 point; yellow: 2 points. Multiplying A and B together, a combined score was assigned as follows: 0 points, negative (-); 1-4 points, weakly positive (+); 5-8 points, positive (++); 9-12 points, strongly positive (+++). The third pathologist will redefine that when the judgments of the two pathology experts differed.

Statistical methods

Data were analyzed using SPSS13.0 software. Results are presented as means ± standard deviations (s.d.). Differences between groups were identified by the student t-test, or by ANOVA, as appropriate. A value of $P \leq 0.05$ was defined as statistically significant.

Results

Serology

The levels of the enzymes ALT and AST in the experimental (irradiated) group after 2, 3, or 4 months of irradiation were significantly higher than those in the comparative blank control groups ($P < 0.05$), indicating that the experimental group continued to exhibit impaired liver function even 2, 3, or 4 months after irradiation, compared with the control group. In addition, the serum levels of HGF in the experimental group 1, 2, 3, and 4 months after irradiation were significantly higher than those of the blank control group ($P < 0.05$). EGF, HGF, and TGF-α, are important immunological factors involved in liver regeneration, and in the post-irradiation experimental groups, EGF and HGF serum levels were increased compared

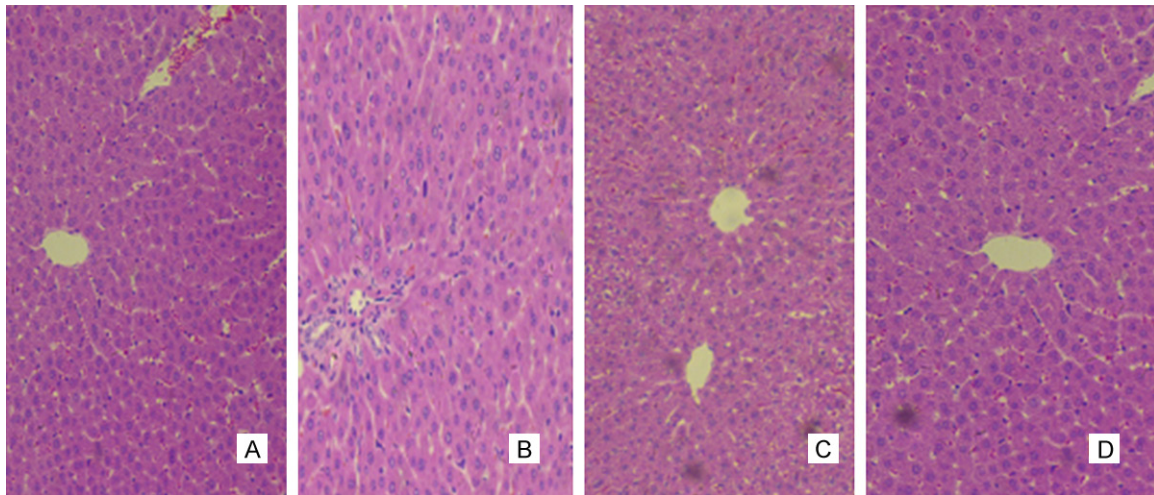


Figure 2. HE stained right liver lobe tissue samples of control (non-irradiated) rats. A: 1 m control group; B: 2 m control group; C: 3 m control group; D: 4 m control group.

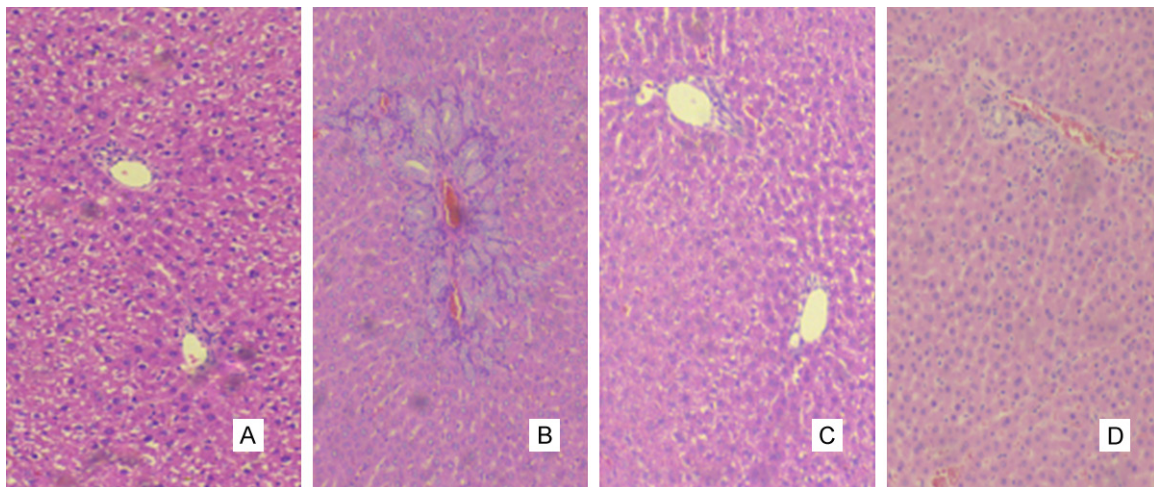


Figure 3. HE stained right liver lobe tissue samples of rats given a single 25 Gy dose of radiation to the right liver lobe. A: 1 m post-irradiation group; B: 2 m post-irradiation group; C: 3 m post-irradiation group; D: 4 m post-irradiation group.

with the control group, indicating that the livers of the experimental animals were in a state of regenerative proliferation. Details of this are shown in **Figure 1**.

Pathological evaluation of HE stained tissue samples

In the control group, light microscopy of stained liver tissue sections revealed a normal liver microstructure to the right liver lobe. The interlobular arteries and veins and the ductus biferi interlobularis in the hepatic portal area were all as evidenced by clearly visible, the hepatic blood sinus space appeared normal,

and no inflammatory reactions were visible near the central veins (see **Figure 2**). In the experimental groups, pathology associated with acute radiation injury was visible in the right liver lobe, with different pathological manifestations and features becoming visible with increasing duration post-radiation treatment. One month post-irradiation, liver cell inflammation was observed surrounding the central veins, and the hepatic sinusoidal liver cells were swollen and showed signs of necrosis (see **Figure 3A**). Two-months after irradiation, there was evidence of mild bile duct hyperplasia coupled with a small amount of liver cell necrosis,

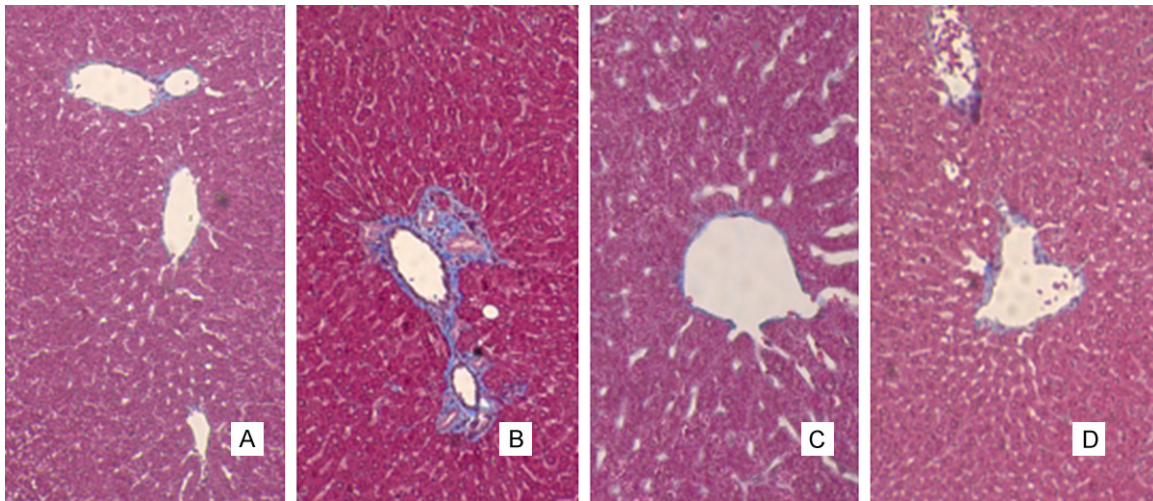


Figure 4. Masson stained right liver lobes of control group mice. A: 1 m control group; B: 2 m control group; C: 3 m control group; D: 4 m control group.

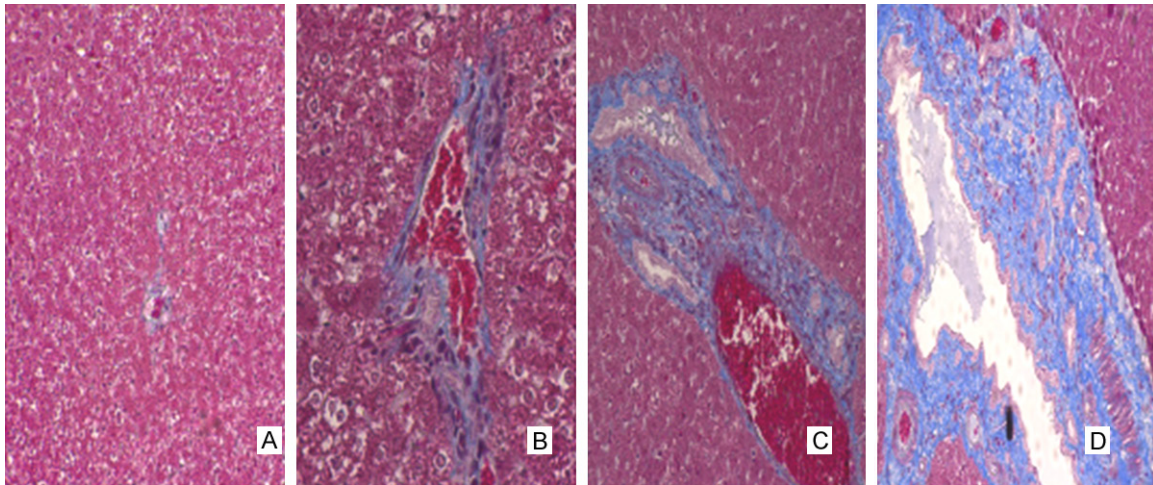


Figure 5. Masson stained right liver lobes of rats given a single 25 Gy dose of radiation to the right liver lobe. A: 1 m post-irradiation group; B: 2 m post-irradiation group; C: 3 m post-irradiation group; D: 4 m post-irradiation group.

some infiltration of lymphocytes in to the portal area and swelling of the cells peripheral to the central vein (see **Figure 3B**). The stained tissues of the 3-month-post-irradiation experimental group exhibited hepatic sinus dilation, swelling of hepatic cells and an absence of visible reticular fibers (see **Figure 3C**). Four months post-irradiation there was evidence of spotty necrosis of hepatic cells, hepatic sinus dilation and an absence of visible reticular fibers. In addition, hyperplasia of the interlobular veins, interlobular arteries, and of the bile duct epithelium was visible in this group (**Figure 3D**). Overall, HE staining of tissues from the experimental group showed that with increasing dura-

tion post-irradiation there was a decrease in liver inflammation but an increase in hyperplasia of the interlobular veins, arteries and bile duct epithelium and a breakdown of reticular fibers.

Pathological evaluation of tissue samples stained with Masson's trichome stain

With HE staining, the collagen fibers and liver cells are bound to the eosin stain, making it difficult to identify the fine hepatic sinusoidal reticular fibers and to identify any fibrosis in the leaflet. Therefore, tissue samples were additionally stained with Masson's stain in order to

Table 1. Comparison of the degree of fibrosis of the liver tissue of rats from the control and irradiated groups

Group	Cases	Pathological results of the liver fibrosis rats					P
		0	1	2	3	4	
C1 m	10	10	0	0	0	0	
C2 m	9	9	0	0	0	0	
C3 m	9	9	0	0	0	0	
C4 m	10	10	0	0	0	0	
1 m	9	9	0	0	0	0	1.000
2 m	9	8	1	0	0	0	0.317
3 m	8	5	3	0	0	0	0.050*
4 m	8	1	6	2	0	0	0.000*

*The mean difference is significant at the 0.05 level.

better visualize the degree of liver fibrosis. The results revealed that, in the control group, a small amount of fiber deposition could be seen in the portal blood vessels, and no obvious staining was visible to other liver tissue structures (see **Figure 4**). In the experimental (irradiated) group, one month after irradiation swelling of the hepatic cells was evident, and a small amount of fibrous proliferation was seen in the central vein (**Figure 5A**). Two months after irradiation, increased fiber hyperplasia was seen in the central veins (see **Figure 5B**). Three months after irradiation, the central vein and portal tracts displayed collagen fiber hyperplasia, to a greater degree than in the 1 month or 2 months post-irradiation groups, and there was no obvious Masson positive staining in the surrounding hepatic cells (**Figure 5C**). Four months after irradiation a significant degree of collagen fiber hyperplasia could be seen in the central veins and arteriovenous regions of the portal area, and a small amount of collagen and fiber hyperplasia was visible in liver cells and in the hepatic sinus (see **Figure 5D**). The numbers of rats in the experimental groups 3 and 4 months after irradiation that exhibited fibrosis of the liver tissue were increased compared with those in the comparable control groups ($P < 0.05$), indicating that hepatic fibrosis appeared relatively slowly, 3 to 4 months after radiation treatment (**Table 1**).

Immunohistochemistry

In the control groups, no obvious staining of TGF- β positive cells was evident among rats at

any of the time points (1, 2, 3, or 4 months). Only a small amount of brownish yellow particles were seen in the hepatic cells of the central vein of rats in these groups (see **Figure 6**). One or 2 months after irradiation, TGF- β positive cells were found predominantly in the peripheral hepatic cells of the central vein (see **Figure 7A** and **7B**), but the number of visibly positive cells was relatively low. By 3 or 4 months after irradiation, TGF- β positive cells were evident in a range of liver cell types, including portal fibroblasts, vascular endothelial cells, central vein peripheral cells, partial liver cells and the fibrous septum, showing yellow granulation, especially in the 4-month-post-irradiation group (**Figure 7C** and **7D**). TGF- β expression in the portal area of rats in this experimental group was most obvious, identified by the dark color and wide range (see **Figure 7D**). With increasing duration beyond 1 month post-irradiation, the number of TGF- β cells in liver tissue samples from the experimental group significantly increased, compared with those in the comparable control groups (see **Table 2**) ($P < 0.05$). This indicated TGF- β was an important factor in the process of liver regeneration, as the increase in its expression levels is indicative of the formation of new liver fiber.

Discussion

Liver cancer is one of the most prevalent forms of cancer threatening the health of Chinese people. In 2011, there were approximately 356,000 cases [4] of hepatocellular carcinoma in China, equating to an incidence rate of 26.39/100,000, and ranking fourth among all types of malignant tumors occurring in China. In recent years, there has been a significant decline in the incidence of and mortality rates associated with liver cancer, but a large number of new cases still occur each year due to population growth and, in particular, growth in the ageing population [5]. In recent years, new radiotherapy technologies have been developed, including stereotactic radiotherapy (SBRT) or proton therapy, and this has resulted in a significant increase in the use of radiotherapy as a treatment for liver carcinoma [1]. However, in line with this increase in radiotherapy treatment, there has also been an increase in RILD. It is therefore very important to understand the process of liver regeneration and hepatic fibro-

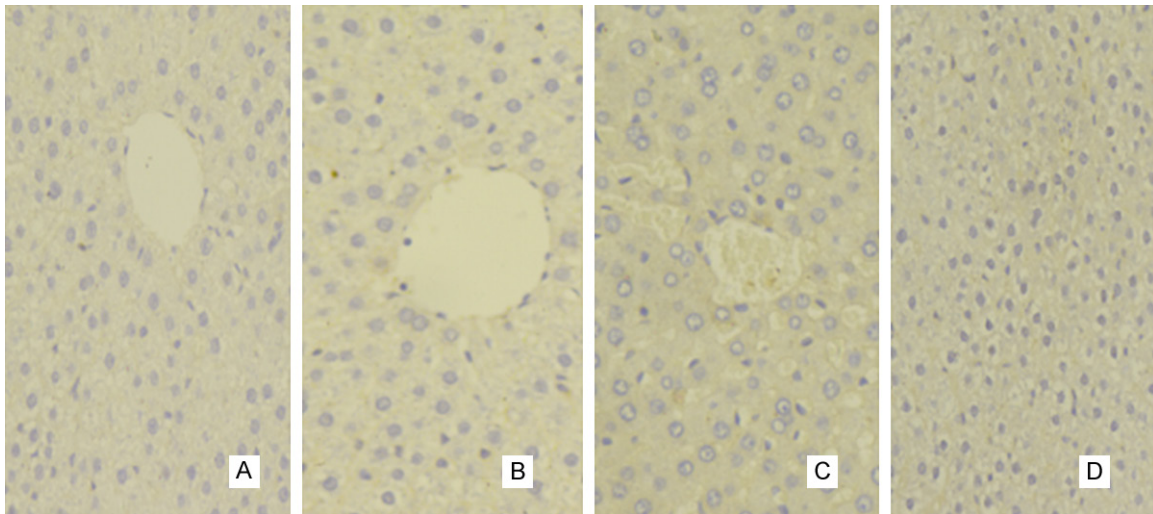


Figure 6. TGF- β stained positive cells in liver tissue of the control groups. A: 1 m control group; B: 2 m control group; C: 3 m control group; D: 4 m control group.

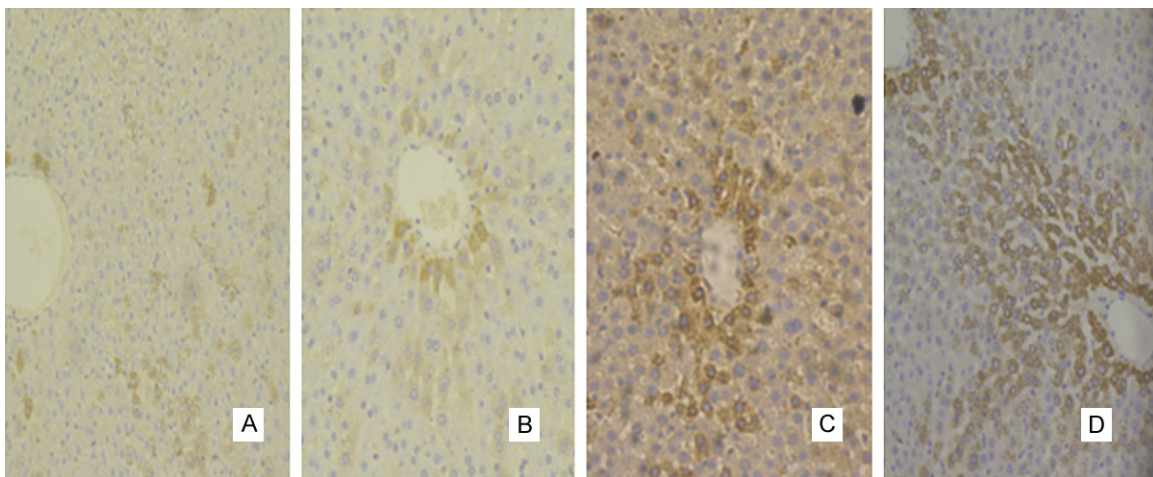


Figure 7. TGF- β stained positive cells in liver tissues of the experimental groups. A: 1 m post-irradiation group; B: 2 m post-irradiation group; C: 3 m post-irradiation group; D: 4 m post-irradiation group.

Table 2. Comparison of the levels of expression of TGF- β in liver tissues of experimental and control group rats (Wilcoxon rank sum test for comparison of two independent samples)

Group	Cases	Positive cases				P
		-	+	++	+++	
C1 m	10	8	2	0	0	
C2 m	9	9	0	0	0	
C3 m	9	8	1	0	0	
C4 m	10	8	2	0	0	
1 m	9	8	1	0	0	0.606
2 m	9	3	6	0	0	0.040*
3 m	8	0	8	0	0	0.000*
4 m	8	0	8	0	0	0.001*

*The mean difference is significant at the 0.05 level.

sis in radioactive liver injury, in order to design effective intervention technologies and treatments.

The activity levels of ALT and AST enzymes are the criteria most widely used to assess liver injury. In the present study both ALT and AST were significantly increased in the liver tissues of rats 2, 3, and 4 months after application of a single dose of radiation to the right liver lobe, compared with control rats. HE and Masson staining of liver tissues revealed that, 3 months after irradiation treatment, there were obvious signs of liver fibrosis which was evident in the experimental group but not the control group. Four months after irradiation treatment, a large number of collagen fibers were visible in the

hepatic veins of the right liver lobe of the experimental group rats, and the overall degree of fibrosis was increased compared to that of the 3-month-post-irradiation. With increasing duration post-irradiation, irreversible fibrosis occurred in the right liver lobe.

Epidermal growth factor (EGF) is one of the key hepatocyte cell proliferation factors, which can control liver cells from the G0 phase of the cell cycle, through the G1 phase checkpoint, to the S phase. EGF also promotes DNA synthesis [6]. Skarpen *et al.* found that, after partial hepatectomy, EGF plasma levels increased 2 to 3 fold [7], and that EGF played the role of promoting mitosis in the early stages of liver regeneration. Other researchers have reported EGF upregulation to be a major feature of cirrhosis of the liver [8]. In addition to its role in DNA synthesis and cell proliferation in liver cells, EGF has also been shown to have the ability to promote the proliferation of hepatic stellate cells (HSC) [9]. At the present time, it is believed that HSC activation is an important process in hepatic fibrosis. HSC has the ability to synthesize a large amount of extracellular matrix (ECM) which utilizes collagen as the main source component, promoting the formation of liver fibrosis [10]. In the present study, serum EGF was significantly higher 1, 2, 3, or 4 months post-irradiation in the irradiated group compared with the control group, which may be related to its release from hepatocytes following injury and/or due to the upregulation of compensatory EGF synthesis after irradiation. EGF is overexpressed in the fibrotic liver [8], and is member of a signature predictive of progressive cirrhosis, hepatocellular carcinoma, and death in patients with cirrhosis [11]. Moreover, the present study was shown that the pharmacological inhibition of the EGF receptor to attenuate liver fibrosis [12], and the direct effect of EGF stimulation on the expression of activation markers in human primary HSCs [13]. This increase in serum EGF levels may mean simultaneous hepatocyte regeneration and hepatic fibrosis, which may explain the observed hepatic fibrosis in the irradiated group 3, or 4 months post-irradiation.

Hepatocyte growth factor (HGF) is the most powerful stimulating factor for DNA synthesis in mature liver cells and the promoting factor of liver regeneration. Most liver related theories put forward HGF as a regenerative factor with

the functions of cell protection and inhibition of fibrosis, that can effectively inhibit the deposition of extracellular matrix and the occurrence of fibrosis *in vivo* [14]. Meanwhile, it is also known that HGF has a strong role in promoting mitosis of cells, and it is thought that it could promote the synthesis of DNA in cells and guide the regeneration of liver cells [15]. Research has shown that impaired liver cells might increase HGF synthesis, and that HGF could be used as an index of liver damage and liver regeneration [16]. In the present study, the experimental groups exhibited higher serum HGF levels than the comparable control groups 1, 2, 3 and 4 months post-irradiation. The observed increase in the level of HGF that occurred one month after irradiation might be related to the mass release of HGF following damage to the liver matrix. Thereafter, the further increase in HGF serum levels might be related to an increase in HGF synthesis following liver damage. The increased levels of HGF in the serum could promote proliferation of liver cells, fibroblasts and epithelial cells and the formation of vascular and liver complex arrangements and structures, so as to accelerate liver regeneration [17].

TGF- α is an essential mitogenic polypeptide in the process of hepatocyte proliferation and differentiation. It can promote the differentiation, growth and regeneration of local cells [18]. In the present study, a large amount of TGF- α was generated in the sera of rats 1, 2, 3 or 4 months post-irradiation compared with the comparable control groups, and showed a positive correlation with EGF levels. The observed increase in HGF in the sera of irradiated rats might be related to compensatory regeneration of this cytokine after irradiation.

TGF- β is an important factor in the termination phase of the liver regeneration process [19]. Previous studies have shown that TGF- β is closely associated with the occurrence and development of liver fibrosis. In the rat liver cirrhosis model, the expression of TGF- β gene was over expressed [20]. There have also been reports of the successful use of TGF- β to induce fibrosis in the rat urethra [21]. In the present study, the expression of TGF- β positive cells in the right liver lobe tissue of the experimental group rats 3 or 4 months post-irradiation was significantly higher compared to that in the

comparable control groups. Combining this with the results of the Masson staining of liver tissue samples, a large amount of collagen fiber hyperplasia was visible in the central veins of the right hepatic portal area 3 and 4 months post-irradiation. The up-regulation of TGF- β expression that was evident 3 and 4 months post-irradiation indicated that hepatic fibrosis had occurred by this time. However, the fact that the expression intensity of TGF- β was gradually and consistently increasing between 1 and 4 months post-irradiation, suggests that the single dose of irradiation treatment continued to cause damage to liver cells, especially Kuffer cells, long after the irradiation treatment. The suggested mode of action of TGF- β is through its effects on HSC, increasing their activation, differentiation, and proliferation, and thereby increasing the production of extracellular matrix (ECM), which contains collagen as the main component, so as to promote the formation of liver fibrosis. Furthermore, it has been shown that activated HSC can themselves secrete a significant amount of TGF- β , which may therefore aggravate liver fibrosis further via a positive feedback loop [10].

In the present study we found that, after irradiation, liver function, as measured by levels of AST and ALT, was impaired. Over time (post-irradiation), serum EGF, HGF and TGF- α levels increased, which might be a compensatory liver tissue regeneration reaction following hepatic inflammation and necrosis of liver cells. We further observed that signs of liver fibrosis could be seen from 3 months post-irradiation and that primary fiber hyperplasia in the central vein and portal area was obviously increased even before that, at 1 or 2 months post-irradiation. By four months after irradiation, spotty necrosis was seen in the liver cells, hepatic sinus dilation and inflammatory reactions were decreased, but a large amount of collagen fiber hyperplasia could be seen in central veins, which was greater than that visible in the 3 month post-irradiation group. These findings are consistent with our immunohistochemistry results and suggest that liver fibrosis began to appear 3 months after irradiation, and that by 4 months, it was more obvious, and accompanied by an increase in serum levels of EGF, HGF, TGF- α , and TGF- β .

In summary, this study has investigated the occurrence and development of radiation

induced liver injury over the course of 4 months post-treatment, by detecting and observing serum levels of EGF, HGF, TGF- α and by pathological HE and Masson staining to evaluate TGF- β expression. The results suggest that, in a rat model, serum EGF and HGF are markers of liver regeneration and liver injury, and that TGF- β is a marker of liver fibrosis, and that these markers are more sensitive than ALT, AST in predicting the extent of radiation induced liver injury. The findings provide a basis for further research on the biomolecular mechanisms of radioactive-induced liver injury and liver regeneration.

Acknowledgements

The study was supported by Guangdong Province Science and technology plan fund (No. 2012B031800156).

Disclosure of conflict of interest

None.

Address correspondence to: Dr. Yiming Wang, Department of Oncology, The First Affiliated Hospital, Jinan University, 613 Huangpu West Rd, Guangzhou 510630, China. Tel: 86-20-38688888; Fax: 86-20-38688888; E-mail: Yimingwangna@163.com

References

- [1] Rim CH, Seong J. Application of radiotherapy for hepatocellular carcinoma in current clinical practice guidelines. *Radiat Oncol J* 2016; 34: 160-7.
- [2] Zhang J, Zhou S, Zhou Y, Feng F, Wang Q, Zhu X, Ai H, Huang X, Zhang X. Hepatocyte growth factor gene-modified adipose-derived mesenchymal stem cells ameliorate radiation induced liver damage in a rat model. *PLoS One* 2014; 9: e114670.
- [3] Oh W, Pyo S, Lee K, Lee B, Shin D, Cho SI, Lee SM. Effect of *Holotrichia diomphalia* larvae on liver fibrosis and hepatotoxicity in rats. *J Ethnopharmacol* 2003; 87: 175-80.
- [4] Zuo T, Zheng R, Zeng H, Zhang S, Chen W. [Analysis of liver cancer incidence and trend in China]. *Zhonghua Zhong Liu Za Zhi* 2015; 37: 691-6.
- [5] Chen W, Zheng R, Baade PD, Zhang S, Zeng H, Bray F, Jemal A, Yu XQ, He J. Cancer statistics in China, 2015. *CA Cancer J Clin* 2016; 66: 115-32.
- [6] Shi J, Line P. Effect of liver regeneration on malignant hepatic tumors. *World J Gastroenterol* 2014; 20: 16167.

- [7] Skarpen E, Oksvold MP, Grøsvik H, Widnes C, Huitfeldt HS. Altered regulation of EGF receptor signaling following a partial hepatectomy. *J Cell Physiol* 2005; 202: 707-16.
- [8] Komuves LG, Feren A, Jones AL, Fodor E. Expression of epidermal growth factor and its receptor in cirrhotic liver disease. *J Histochem Cytochem* 2000; 48: 821-30.
- [9] Pinzani M, Gesualdo L, Sabbah GM, Abboud HE. Effects of platelet-derived growth factor and other polypeptide mitogens on DNA synthesis and growth of cultured rat liver fat-storing cells. *J Clin Invest* 1989; 84: 1786-93.
- [10] Chen Y, Li D, Wu J, Chen Y, Lu H. Tetrandrine inhibits activation of rat hepatic stellate cells stimulated by transforming growth factor- β in vitro via up-regulation of Smad 7. *J Ethnopharmacol* 2005; 100: 299-305.
- [11] Hoshida Y, Villanueva A, Sangiovanni A, Sole M, Hur C, Andersson KL, Chung RT, Gould J, Kojima K, Gupta S, Taylor B, Crenshaw A, Gabriel S, Minguez B, Iavarone M, Friedman SL, Colombo M, Llovet JM, Golub TR. Prognostic gene expression signature for patients with hepatitis C-related early-stage cirrhosis. *Gastroenterology* 2013; 144: 1024-30.
- [12] Fuchs BC, Hoshida Y, Fujii T, Wei L, Yamada S, Lauwers GY, McGinn CM, DePeralta DK, Chen X, Kuroda T, Lanuti M, Schmitt AD, Gupta S, Crenshaw A, Onofrio R, Taylor B, Winckler W, Bardeesy N, Caravan P, Golub TR, Tanabe KK. Epidermal growth factor receptor inhibition attenuates liver fibrosis and development of hepatocellular carcinoma. *Hepatology* 2014; 59: 1577-90.
- [13] El Taghdouini A, Najimi M, Sancho-Bru P, Sokal E, van Grunsven LA. In vitro reversion of activated primary human hepatic stellate cells. *Fibrogenesis Tissue Repair* 2015; 8: 14.
- [14] Ali G, Masoud M. Bone marrow cells ameliorate liver fibrosis and express albumin after transplantation in CCl₄-induced fibrotic liver. *Saudi J Gastroenterol* 2012; 18: 263-7.
- [15] Kang L, Mars W, Michalopoulos G. Signals and cells involved in regulating liver regeneration. *Cells* 2012; 1: 1261-92.
- [16] Eichbaum MH, de Rossi TM, Kaul S, Bruckner T, Schneeweiss A, Sohn C. Serum levels of hepatocyte growth factor/scatter factor in patients with liver metastases from breast cancer. *Tumour Biol* 2007; 28: 36-44.
- [17] Libetta C, Esposito P, Martinelli C, Grosjean F, Gregorini M, Rampino T, Dal Canton A. Hepatocyte growth factor (HGF) and hemodialysis: physiopathology and clinical implications. *Clin Exp Nephrol* 2016; 20: 371-8.
- [18] Stolz DB, Mars WM, Petersen BE, Kim TH, Michalopoulos GK. Growth factor signal transduction immediately after two-thirds partial hepatectomy in the rat. *Cancer Res* 1999; 59: 3954-60.
- [19] Nakamura T, Ueno T, Sakamoto M, Sakata R, Torimura T, Hashimoto O, Ueno H, Sata M. Suppression of transforming growth factor- β results in upregulation of transcription of regeneration factors after chronic liver injury. *J Hepatol* 2004; 41: 974-82.
- [20] Yang KL, Hung KC, Chang WT, Li EI. Establishment of an early liver fibrosis model by the hydrodynamics-based transfer of TGF- β 1 gene. *Comp Hepatol* 2007; 6: 9.
- [21] Sangkum P, Gokce A, Tan RB, Bouljihad M, Kim H, Mandava SH, Saleem SN, Lasker GF, Yafi FA, Abd Elmageed ZY, Moparty K, Sikka SC, Abdel-Mageed AB, Hellstrom WJ. Transforming growth factor- β 1 induced urethral fibrosis in a rat model. *J Urol* 2015; 194: 820-7.