

Case Report

Wolffian tumor: report of five cases and review of literature

Ning Yu^{1,2}, Dahua Zhao², Yufang Liu³, Tingguo Zhang¹

¹Department of Pathology, Shandong University School of Medicine, Jinan, China; Departments of ²Pathology,

³Obstetrics and Gynecology, Affiliated Hospital of Binzhou Medical University, Binzhou, China

Received December 19, 2016; Accepted December 27, 2016; Epub March 1, 2017; Published March 15, 2017

Abstract: Wolffian tumor is a rare neoplasm, arising from the remnants of the mesonephric duct, such as the broad ligament, tube, ovarian hilum, peritoneum and mesosalpinx. Its synonyms include Female adnexal tumor of probable wolffian origin (FATWO), wolffian adenoma and wolffian adnexal tumor. It is thought to be a benign lesion, although in some cases metastasis or recurrences have been reported even after a long interval following the initial diagnosis. In this cases report, we present five cases of FATWO and review the literature based on clinical and pathological features. The aim of the study was to call attention to this rare tumor and to avoid high rate of misdiagnosis.

Keywords: Female adnexal tumor, wolffian tumor

Introduction

In 1973, Kariminejad and Scully [1] reported nine cases of morphologically distinctive lesions characterized by epithelial cells that grow in diffuse, tubular, spindle cell, and sieve-like patterns. On the basis of their location in the broad ligament, in which Wolffian remnants are abundant, they coined the term female adnexal tumor of probable Wolffian origin (FATWO). Although the diagnosis of this tumor is based on the exclusion of other possibilities, these tumors do not closely resemble any neoplasm that arises from either a Müllerian duct derivation or the surface of the ovary. This nomenclature is used because these tumors are primarily located in sites with abundant Wolffian remnants [2]. In 2003, the World Health Organization nominated FATWO as a tumor of presumptive Wolffian origin that is characterized by various epithelial patterns. In the 4th edition of WHO, FATWO is officially named Wolffian tumor, and the behavior of this lesion is defined as borderline or uncertain [3]. We report five cases of Wolffian tumors. Thus far, less than 100 cases, including our five cases, have been reported in the literature.

Cases report

The clinical features of the patients are listed in **Table 1**. The patients aged from 29 years to 52 years, and their average age was 39.6. One

patient suffered from abdominal pain; four other patients manifested pelvic cavity mass during physical exams. The serum tumor markers of CA125 and CEA of our five patients are normal.

Gross examination

The size of the tumors ranged from 6.5 cm to 17 cm; anatomical analysis revealed a well-capsulated smooth surface solid mass, and the cut section of the mass appeared as grayish-yellow to white soft tissue (**Figure 1**). The tumors were unilateral, with three cases located in the mesosalpinx and two cases located in the broad ligament.

Microscopic examination

The tumor contained a variable admixture of diffuse, solid, and sieve-like cystic areas, with a packed tubular pattern that dominates the majority of our cases (**Figure 2**). The nuclei of the tumor are uniform and ovoid, circular, fusiform, or irregular; significant nuclear pleomorphism and mitoses in the five cases are less than 1 per 10 in high-power fields (400×). Tumor cells may be arranged in dense tubules; they may also display cyst formations in sieve-shaped structures. In the diffuse area, small tubular structures can be revealed by PAS or reticular fiber staining. PAS stain was positive for the basement membrane but was negative

Table 1. Clinicopathologic Features of five cases of Wolffian tumors

| Case | Age | Clinical symptom | Site | Size | Gross apperance | Therapy | Follow-up time | Recurrence |
|------|-----|------------------|---------------------|--------------|---|---|-----------------------|------------|
| 1 | 29 | Pelvic mass | Right mesosalpinx | 7×5×4 cm | Oval-shaped, well-capsulated, solid-cysticmass, gray-red | Neoplasms resection | 11 years and 8 months | No |
| 2 | 48 | Pelvic mass | Right mesosalpinx | 6×5×4 cm | Lobular-shaped, well-capsulated, solidmass, gray-white | Neoplasms resection and uni-lateral salpingo-oophorectomy | 10 years and 5 months | No |
| 3 | 52 | Abdomianl pain | Left broad ligament | 17 cm | Oval-shaped, well-capsulated, solid-cystic mass, gray-yellow | Neoplasms resection and uni-lateral salpingo-oophorectomy | 9 years and 6 months | No |
| 4 | 39 | Pelvic mass | Left broad ligament | 7.5×5.5×4 cm | Smooth surface, well-capsulated, solid mass, gray-yellow | Neoplasms resection | 10 years and 7 months | No |
| 5 | 30 | Pelvic mass | Right mesosalpinx | 6.5 cm | Oval-shaped, smooth surface, ell-capsulated, solidmass, gray-yellow | Neoplasms resection | 3 years and 7 months | No |

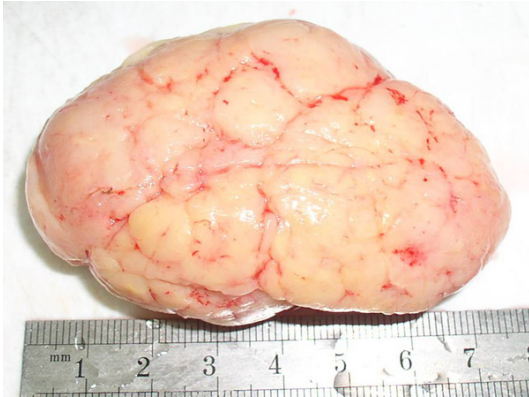

Figure 1. Gross photograph of the tumor of the Left broad ligament. A solid mass with smooth surface.

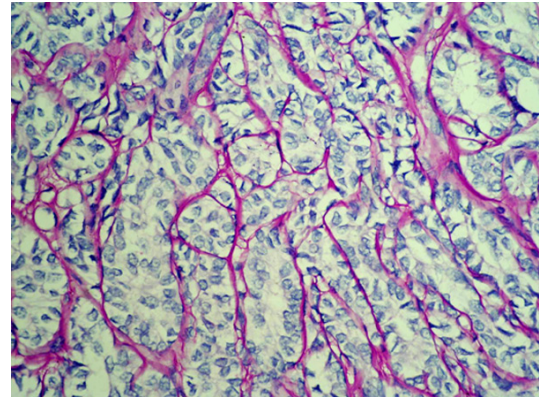


Figure 3. PAS staining highlighted the basement membrane (×400).

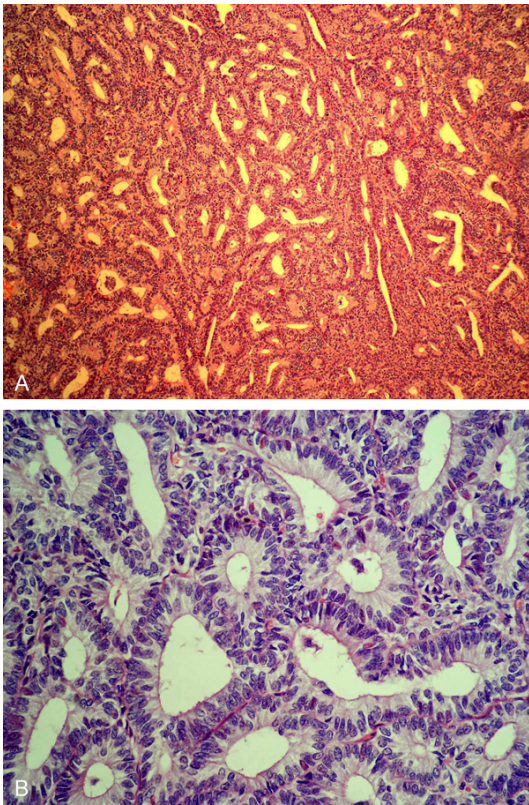


Figure 2. A. Low-power view of the female adnexal tumor of probable wolffian origin with prominent sieve-like pattern of growth (×100). B. High-power view of the uniform and ovoid, low cuboidal epithelial cells lining the tubules (×400).

for intracytoplasmic cells in all of our five cases (Figure 3).

Immunohistochemistry findings

Immunohistochemical staining was performed on formalin-fixed paraffin-embedded tissues of

the tumor by using standard avidin-biotin-complex peroxidase technique (Table 2). The tumor was diffusely positive for Vimentin (Figure 4A) and CD99, focal positive for pan-cytokeratin (CK; Figure 4B), CD10 (Figure 4C), and calretinin. Three cases exhibited a focally positive α -inhibin expression (Figure 4D), but the two other cases were negative. The epithelial membrane antigen (EMA) was negative. The proliferating index of MIB-1 of cases 4 and 5 were 2% and 3%, respectively.

Discussion

Female Wolffian tumors are highly rare. Young and Scully [4] reported a series of 11 cases of Wolffian tumors in the ovary. Studies have provided evidence supporting its Wolffian origin. In males, the Wolffian duct gives rise to the reproductive system; in females, the Wolffian ducts degenerate. The remnants of the Wolffian duct are usually located in the broad ligament and the mesosalpinx, which can form several structures, such as hydatids of Morgagni and Gartner's cysts.

Most researchers favor a Wolffian origin on the basis of the following conditions: (a) occurrence in the same sites as mesonephric remnants; (b) morphological dissimilarity to other ovarian tumors of either epithelial stromal or sex cord-stromal types; and (c) histochemical, immunohistochemical, and ultrastructural homology with the mesonephric duct [5]. Our cases were characterized as Wolffian tumors because of their classical location within the broad ligament in our two cases and in the mesosalpinx in three cases, together with their histological features [6].

Table 2. Immunohistochemical results of five cases of Wolffian tumors

| Case | CK (AE1/AE3) | Vimentin | CD10 | CD99 | α -inhibin | EMA | Calretinin | Ki-67 |
|------|--------------|----------|---------|------|-------------------|-----|------------|-------|
| 1 | Focal + | + | Focal + | + | - | - | Focal + | NO |
| 2 | Focal + | + | Weak + | + | - | - | + | NO |
| 3 | + | + | Weak + | + | + | - | + | NO |
| 4 | Focal + | + | Weak + | + | + | - | Focal + | 2% |
| 5 | + | + | Focal + | + | Weak + | - | + | 3% |

Grossly, they are solid tumors with certain cases that show cystic components. The characteristic microcystical features are medium-sized neoplastic cells arranged in three distinct patterns: a sieve-like pattern, closed packed tubules, and solid pattern. The tumor cells comprise a small cytoplasm and show the form of epithelial cells; in some instances, the tumor cells resemble a spindle. Some cases, such as significant nuclear fission, indicate poor cell differentiation, may be associated with malignant biological behaviors. In addition, tubular structures without mucus secretion and Müllerian tubes on the origin of tumor histological features can support the diagnosis. Regarding the difference between Wolffian and Müllerian structures and their tumors, we proposed that immunophenotypes are not substantially different and no specific marker for Wolffian structures exists. Gartner et al [7] suggested three major differences between Wolffian and Müllerian structures in microcystical features: (a) Wolffian epithelial cells and nuclei are significantly smaller than those of Müllerian cysts; (b) Wolffian ducts and tubules have a better-defined basement membrane than Müllerian ducts and tubules; and (c) Müllerian epithelium responds to cyclical hormonal stimulation, but Wolffian epithelium does not.

Studies have focused on diagnostic immunohistochemistry applications to establish an immunohistochemical profile of Wolffian tumors for diagnosis and supportive evidence of a Wolffian origin. Rahilly et al [5] compared Wolffian tumors through immunohistochemical analysis and found that these tumors express cytokeratins (CAM 5.2 and PKK1) and vimentin; the tumors are also stained positive for S-100 protein. Devouassoux-Shisheboran et al [8] found that Wolffian tumors in a larger study of 25 cases are immunoreactive for pancytokeratin (AE1/3) (100%), CAM 5.2 (100%), vimentin (100%), calretinin (91%), cyto-

keratin 7 (88%), androgen receptor (78%), α -inhibin (68%), estrogen receptor (28%), progesterone receptor (24%), and EMA (12%). The immunotype of pan-cytokeratin (AE1/3), vimentin, and EMA of our five cases were consistent with those described in most literature reports. Two cases showed low Ki-67 labeling indexes, which are consistent with the slow growth rate and the gradual clinical course of Wolffian tumors.

A previous study [9] demonstrated that CD10 can be a marker of Wolffian remnants and neoplasm in the female genital tract. Wolffian remnants and tumors are positive for CD10; by contrast, the normal glandular epithelia of the female genital tract and their tumors are almost constantly negative. All of our five cases show that CD10 was positive. Therefore, CD10-positive findings could be a helpful marker of tumors with Wolffian origin.

The differential diagnosis of Wolffian tumors includes Sertoli-Leydig cell tumors, endometrioid ovarian adenocarcinomas, and endometrioid adenocarcinomas of the fallopian tube [10, 11]. Wolffian tumors, especially those located in the ovary, may be confused morphologically with Sertoli-Leydig cell tumors. The main differences are as follows: Sertoli-Leydig cell tumors are possibly associated with endocrine symptoms and are composed of Leydig cells. Sertoli-Leydig cell tumors have not been detected in the broad ligament or other locations of Wolffian remnants [12]. In terms of immunostaining, α -inhibin staining is of limited value in this differential diagnosis. In our cases, α -inhibin was negatively expressed (2/5); two previous similar studies [8, 13] found positive staining with α -inhibin in 68% and 90% (9/10) of Wolffian tumors, respectively. However, we found that Wolffian tumors stained with α -inhibin are patchy and weak; this observation is different from the diffuse strong positivity usually found in Sertoli-Leydig cell tumors. Fur-

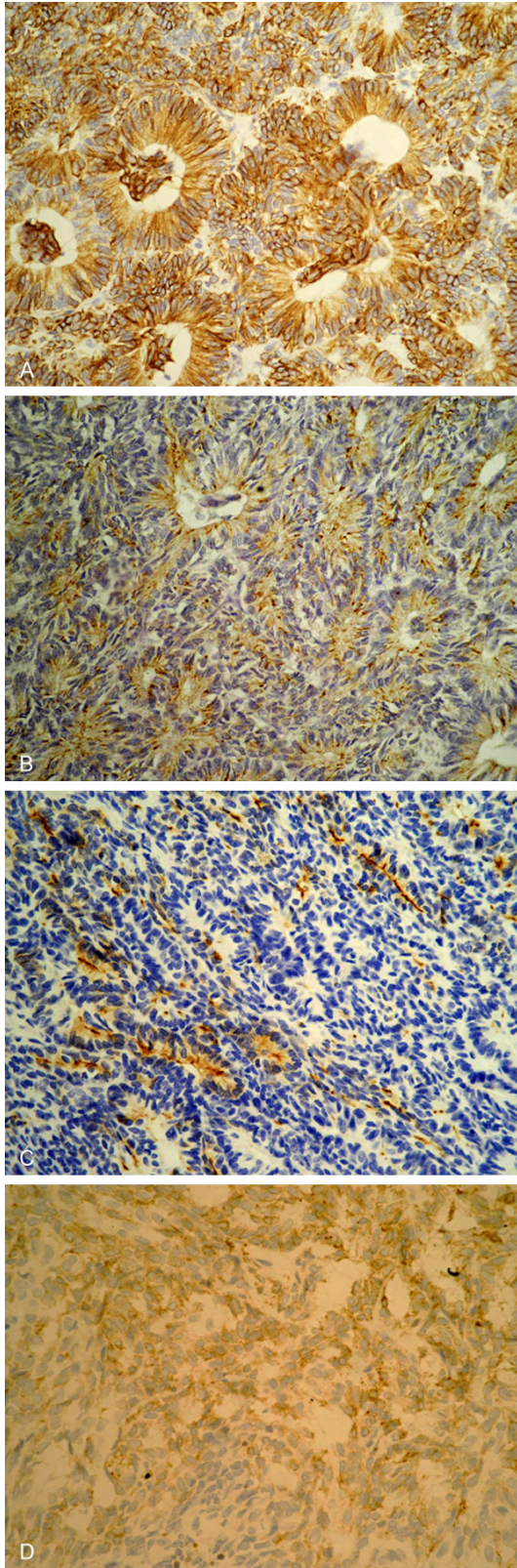


Figure 4. Tumor cells are strongly positive for Vimentin ($\times 400$) (A), focal positive for cytokeratin (AE1/3) ($\times 400$) (B) and for CD10 ($\times 400$) (C). weak positive for α -inhibin ($\times 400$) (D).

thermore, Wolffian tumors show AE1/AE3 and CD10 positive expression; PAS stains accentuated a prominent peritubular basement membrane; by contrast, sex cord-stromal tumors indicate no such expression. These findings will help perform differential diagnosis of tumors.

Endometrioid carcinomas of the fallopian tube or ovary can indicate closely packed tubular glands similar to Wolffian tumors. A total of 20 cases of endometrioid carcinoma of the fallopian tube resembling Wolffian tumors have been reported in the English literature [12, 14]. Several features are indicative of endometrioid carcinoma. The tumor arose from the fallopian tube or ovary; conversely, Wolffian tumors usually arise outside the tube within the broad ligament or ovary. The degree of nuclear atypia and mitotic activity was more impressive than that observed in Wolffian tumors. The presence of squamous differentiation and colloid-like secretion in glands was more consistent with endometrioid carcinoma. Nevertheless, the presence of intraluminal mucin has not been reported in Wolffian tumors. Immunohistochemistry is available in this regard; the EMA positivity and α -inhibin and calretinin negativity were also consistent with endometrioid carcinoma; by contrast, Wolffian tumors are positive for α -inhibin and calretinin but are usually negative for EMA [14].

Recommendations have yet to be provided regarding patient treatment because of the rarity of these tumors. Surgical debulking with total abdominal hysterectomy (TAH) and bilateral salpingo-oophorectomy are considered the most effective initial treatments. To our knowledge, three of our five patients were subjected to tumorectomy and two young patients were treated with laparoscopic-assisted unilateral salpingo-oophorectomy. Chemotherapy and radiation therapy have not been found as an effective treatment for recurrent Wolffian tumors; treatment options are more limited. The hormone dependency of Wolffian tumors may be considered, and hormonal therapy can be administered when conventional treatment fails; in this case, tumor mass can be surgically removed, and both ovaries and uterus are preserved, and tumors are stained positive for progesterin receptors [15]. In other studies [10, 16, 17], Gleevec, a tyrosine kinase inhibitor known as the preferred treatment against gastrointestinal stromal tumors, was effective for one

patient with Wolffian tumors diagnosed as metastatic and C-kit positive. This treatment may be a possible option but may require further confirmation.

Wolffian tumors usually express a benign behavior, but certain cases have malignant potential, with recurrence and/or metastasis detected several years after the initial surgical treatment. In other studies [2, 10, 11, 15, 16, 18, 19], eight patients with disease recurrence have been documented. The median time of recurrence was 48 months, with a range from 13 months to 96 months; five recurrences were found in the pelvis and the abdomen, two recurrences were detected in the liver, and one recurrence was observed in the lungs [10]. Certain tumor characteristics, including hypercellularity, cellular pleomorphism, and increased number of mitotic figures, are associated with an increased risk of recurrence. However, tumors with minimal nuclear atypia and a low mitotic rate may also recur [21]. Sometimes, Wolffian tumors behave as aggressive lesions. In a systematic review of the English literature, three cases died of this tumor [20]. Considering the malignancy of Wolffian tumors, Sivirdis et al [22] proposed some criteria, including large size (>10 cm), hypercellularity, capsular invasion, capsule rupture, and noticeable tumor implants or metastases. However, the prognosis of Wolffian tumors does not correlate with clinical presentation or cytology. Thus, some authors recommended an observation period of at least 6-8 years [11].

Our five patients were followed up for 43 months to 11 years after they were discharged from the hospital. No evidence of recurrence was observed in the five patients. Nevertheless, long-term follow-up is required for patients with Wolffian tumors.

Disclosure of conflict of interest

None.

Address correspondence to: Tingguo Zhang, Department of Pathology, Shandong University School of Medicine, Jinan 250012, China. E-mail: Zhang-TG2015@163.com

References

[1] Kariminejad MH, Scully RE. Female adnexal tumor of probable wolffian origin. *Cancer* 1973; 31: 671-677.

[2] Ramirez PT, Wolf JK, Malpica A, Deavers MT, Liu J, Broaddus R. Wolffian duct tumors: case reports and review of the literature. *Gynecologic Oncology* 2002; 86: 225-230.

[3] Kurman RJ, Carcangiu ML, Herrington CS, Young RH. World Health Organization classification of tumors. female reproductive organs. (4th edition). Lyon: IARC Press; 2014. pp. 118-119.

[4] Young RH, Scully RE. Ovarian tumors of probable wolffian origin: a report of 11 cases. *Am J Surg Pathol* 1983; 71: 25-135.

[5] Rahilly MA, Williams AR, Krausz T, al Nafussi A. Female adnexal tumor of probable wolffian origin: a clinicopathological and immunohistochemical study of three cases. *Histopathology* 1995; 26: 69-74.

[6] Li CC, Qian ZR, Hirokawa M, Sano T, Pan CC, Hsu CY, Yang AH, Chiang H. Expression of adhesion molecules and Ki-67 in female adnexal tumor of probable Wolffian origin (Wolffian tumors): report of two cases and review of the literature. *APMIS* 2004; 112: 390-398.

[7] Gardner GH, Greene RR, Peckham B. Tumors of the broad ligament. *Am J Obstet Gynecol* 1957; 73: 536-554.

[8] Devouassoux-Shisheboran M, Silver SA, Tavassoli FA. Wolffian adnexal tumor, so-called female adnexal tumor of probable Wolffian origin (Wolffian tumors): immunohistochemical evidence in support of a Wolffian origin. *Hum Pathol* 1999; 30: 856-863.

[9] Ordi J, Romagosa C, Tavassoli FA, Nogales F, Palacin A, Condom E, Torné A, Cardesa A. CD10 expression in epithelial tissues and tumors of the gynecologic tract: a useful marker in the diagnosis of mesonephric, trophoblastic and clear cell tumors. *Am J Surg Pathol* 2003; 27: 178-186.

[10] Ramirez PT, Wolf JK, Malpica A, Deavers MT, Liu J, Broaddus R. Wolffian duct tumors: case reports and review of the literature. *Gynecol Oncol* 2002; 86: 225-230.

[11] Sheyn I, Mira JL, Bejarano PA, Husseinazadeh N. Metastatic female adnexal tumor of probable Wolffian origin: a case report and review of the literature. *Arch Pathol Lab Med* 2000; 124: 431-434.

[12] Huang W, Zhao Y, Zhao J, Huang Y, Wang J, Zhang Q. Endometrioid carcinoma of the fallopian tube resembling an adnexal tumor of probable wolffian origin: a case of report and review of the literature. *Pathol Res Practice* 2010; 206: 180-184.

[13] Kommoss F, Oliva E, Bhan AK, Young RH, Scully RE. Inhibin expression in ovarian tumors and tumor-like lesions: an immunohistochemical study. *Mod Pathol* 1998; 11: 656-664.

[14] Fukunaga M, Bisceglia M, Dimitri L. Endometrioid carcinoma of the fallopian tube resem-

- bling a female adnexal tumor of probable wolffian origin. *Adv Anat Path* 2004; 11: 269-272.
- [15] Atallah D, Rouzier R, Voutsadakis I, Sader-Ghorra C, Azoury J, Camatte S, Morice P, Duvillard P. Malignant female adnexal tumor of probable wolffian origin relapsing after pregnancy. *Gynecol Oncol* 2004; 95: 402-404.
- [16] Syriac S, Durie N, Kesterson J, Lele S, Mhaweche-Fauceglia P. Female adnexal tumor of probable wolffian origin (wolffian tumor) with recurrence 3 years postsurgery: C-kit gene analysis and a possibility of a new molecular targeted therapy. *International Journal of Gynecological Pathology* 2011; 30: 231-235.
- [17] Steed H, Oza A, Chapman WB, Yaron M, De Petrillo D. Female adnexal tumor of probable wolffian origin: a clinicopathological case report and a possible new treatment. *Int J Gynecol Cancer* 2004; 14: 546-550.
- [18] Heller DS, Kadire B, Cracchiolo B. Malignant female adnexal tumor of probable wolffian origin case report. *J Reprod Med* 2011; 56: 175-177.
- [19] Lesin J, Forko-Ilić J, Plavec A, Planinić P. Management of Wolffian duct tumor recurrence without chemotherapy. *Arch Gynecol Obstet* 2009; 280: 855-857.
- [20] Heatley MK. Is female adnexal tumor of probable wolffian origin a benign lesion? A systematic review of the English literature. *Pathology* 2009; 41: 645-648.
- [21] Wagatsuma S, Yaegashi N, Namiki T, Sato S, Yajima A. A case of female adnexal tumor of probable Wolffian origin: histologically, tumor cells showed three different patterns. *Tohoku J Exp Med* 1997; 181: 371-377.
- [22] Sivridis E, Giatromanolaki A, Koutlaki N, Anastasiadis P. Malignant female adnexal tumor of probable Wolffian origin: criteria of malignancy. *Histopathology* 2005; 46: 716-718.