Int J Clin Exp Pathol 2017;10(8):8222-8232
www.ijcep.com /ISSN:1936-2625/IJCEP0058465

Original Article

High-grade serous ovarian and fallopian tube carcinomas with similar clinicopathological characteristics might originate from serous tubal intraepithelial carcinoma in Chinese women

Jingmei Wang[1], Hongyan Wu[1], Yan Zhang[2], Yifen Zhang[1], Xinxiu Li[3], Qingya Zhao[3], Fanqing Meng[1], Qin Huang[1,4], Yaping Wang[3]

Departments of [1]Pathology, [2]Obstetrics and Gynecology, Affiliated Drum Tower Hospital of Nanjing University Medical School, Nanjing, Jiangsu Province, China; [3]Jiangsu Key Laboratory of Molecular Medicine, Department of Medical Genetics, Nanjing University Medical School, Nanjing, Jiangsu Province, China; [4]Department of Pathology and Laboratory Medicine, VA Boston Healthcare System and Harvard Medical School, Boston, Massachusetts, USA

Received May 30, 2017; Accepted July 8, 2017; Epub August 1, 2017; Published August 15, 2017

Abstract: Aims: This study aimed to compare the clinicopathological features, incidence, and prognosis between type II ovarian carcinoma (OC) and fallopian tube carcinoma (FTC) in Chinese women and to analyze the origin of high-grade serous carcinoma (HGSC). Methods: Three hundreds and seventy-four OC cases and 45 FTC cases were retrospectively studied with histomorphology, tissue microarray, and immunohistochemistry. Results: Our data showed that the characteristics of OC and FTC in Chinese women were younger at diagnosis with worse prognosis. There was no significant difference between type II OC and FTC in the clinicopathological information and survival. Serous tubal intraepithelial carcinoma (STIC) were found in 41.7% (43/103) of ovarian high-grade serous carcinoma (HGSC) and 52.4% (22/42) cases of tubal HGSC, and 26 patients were found with only fallopian tube (FT) mucosal invasive carcinoma. Seventy-eight of 87 cases of ovarian HGSC with tubal lesions (STIC and/or FT mucosal invasive carcinoma) was in advanced stage. There was no significant difference between newly assigned FTC (ovarian HGSC with tubal lesions and FTC) and type II OC without tubal lesions in many clinicopathological parameters, expression of immunohistochemical indicators and survival, but type I OC was quite much different from the former two. Conclusions: Our data suggested that OC of type II and FTC might be originated from the same organ, and strongly supported the dualistic model of epithelial ovarian cancer. Moreover, this study provided a further clinical basis for the prophylactic salpingectomy to reduce the risk of OC.

Keywords: Ovarian cancer, fallopian tube cancer, Chinese women, serous tubal intraepithelial carcinoma, high-grade serous carcinoma

Introduction

At present, ovarian cancer (OC) ranks first in gynecologic oncology mortality because of the inability of early diagnosis [1]. A dualistic model of epithelial ovarian cancer divides epithelial ovarian cancer into two broad categories, designated as type I and type II with different characteristics in histomorphology, immunohistochemistry, molecular genetic phenotypes, and clinical pathways [2]. Briefly, type I OC include mucinous carcinoma (MC), endometrioid carcinoma (EC), clear cell carcinoma (CCC) and low-grade serous carcinoma (LGSC), with the features of slow progression and favorable overall prognosis, but low sensitivity to chemotherapy. Type II OC are defined as high-grade neoplasms, with high-grade serous carcinoma (HGSC) as the most common histological type, and show the features of rapid progression, poor prognosis, but high sensitivity to chemotherapy. Recent studies suggest that a large proportion of HGSC may arise from the distal fallopian tube epithelium, with the serous tubal intraepi-

Table 1. The primary antibodies used for immunohistochemistry

Name	Clone	Dilution	Manufacturer
P53	BP53.12	1:150	Invitrogen, USA
Ki67	SP6	1:500	Neomarkers, USA
Cyclin D1	SP4	1:80	Neomarkers, USA
Estrogen receptor (ER)	EP1	1:150	Epitomics, USA
Progesterone receptor (PR)	EP2	1:250	Epitomics, USA
P16	6H12	1:100	Novocastra, UK

Table 2. FIGO Stage of type I and type II primary OC patients

FIGO stage	No. of patients	Percentage (%)
Type I		
I	88	62.41
II	12	8.51
III+IV	41	29.08
Type II		
I	21	9.01
II	27	11.59
III+IV	185	79.40

thelial carcinoma (STIC) observed in the tubal fimbriae in prophylactic salpingo-oophorectomy from women carrying *BRCA* mutations and the specimens of cytoreductive surgery for ovarian HGSC [3-7]. STIC was detected in more than 40-60% of ovarian HGSC specimens by Sectioning and Extensively Examining the FIMbriated (SEE-FIM) protocol, and closely related to *TP53* mutations [8, 9]. As the most adjacent organ associated with ovary, fallopian tube carcinoma (FTC) is a rare gynecological malignancy, and the true incidence of FTC may have been underestimated [10].

The incidence and mortality of OC in Chinese women are rising recently with unknown reasons [11, 12]. In fact, clinicopathologic investigation with comparative analysis between OC and FTC in Chinese women is also lacking. The relationship between OC and FTC is not fully understood. Even in most studies from Europe and America, the clinicopathologic characteristics of OC and FTC were studied separately without consideration of STIC as the origin of HGSC. Therefore, the aim of this study was to explore the characteristics of OC and FTC in Chinese women and test our hypothesis that HGSC of OC and FTC might originate from STIC in Chinese women.

Materials and methods

Study population

Over the study period from 2003 to 2014, a total of 419 radical resection cases with 374 OCs and 45 FTCs, which were carried out at the Nanjing Drum Tower Hospital in China, were retrospectively studied. The study protocol was approved by the medical ethics committee of the Nanjing Drum Tower Hospital. Histopathological classification of OC and FTC was based on the 2014 World Health Organization (WHO) classification, and the International Federation of Gynecology and Obstetrics (FIGO) surgical staging system. The treatment of all patients followed the 2011 NCCN Clinical Practice Guidelines (including the FTC and primary peritoneal cancer).

Following clinicopathological data were collected, including age at diagnosis, chief complaint, family history of malignancy, age of menarche, menopausal status, preoperative serum levels of CA125 and CA19-9, cytology of ascites or peritoneal washings, lymph node metastasis, FIGO stage, and the methods of surgical treatment. All patients were followed-up by telephones or at outpatient clinic visits.

Histopathologic and immunohistochemical evaluations

All radical resection specimens were submitted for histopathological examination with a standard surgical pathology tissue processing protocol. Tissue sections were stained by hematoxylin and eosin (HE). Tissue microarray (TMA) was constructed manually with a TMA instrument (Beecher instrument Co., MTA-1, USA) with 1 mm-core. Dupicated TMA cores were made for each case to ensure the validity and effectiveness of immunohistochemistry (IHC) studies. Once completed, each TMA block was sectioned at 4 micrometer in thickness for routine HE stain and IHC. IHC was routinely performed with the automated Dako EnVison System (Dako, USA). The primary antibodies used for this project were listed in **Table 1**. A routine IHC protocol was based on the recommendation of the manufacturers. Both negative and positive controls were included in each assay.

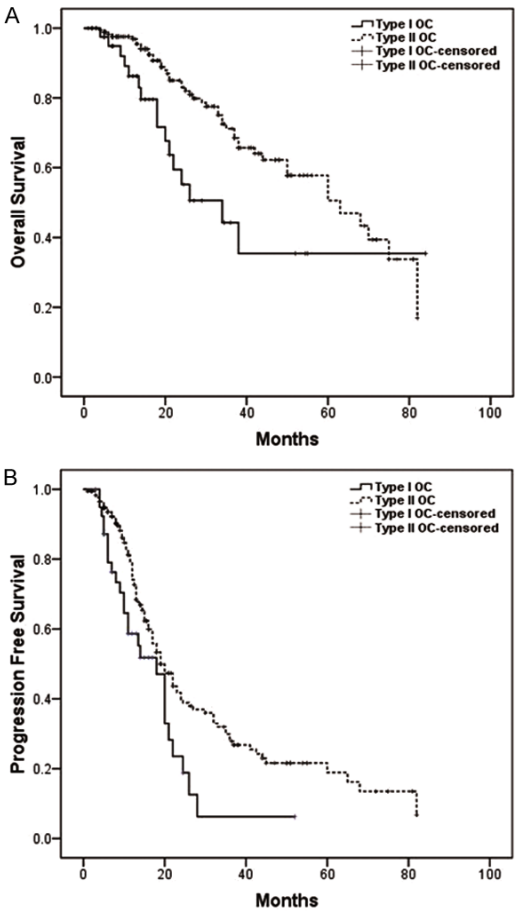

Figure 1. Kaplan-Meier survival analysis for cases of type I OC and type II OC in advanced stage. A: *P*=0.007; B: *P*=0.012.

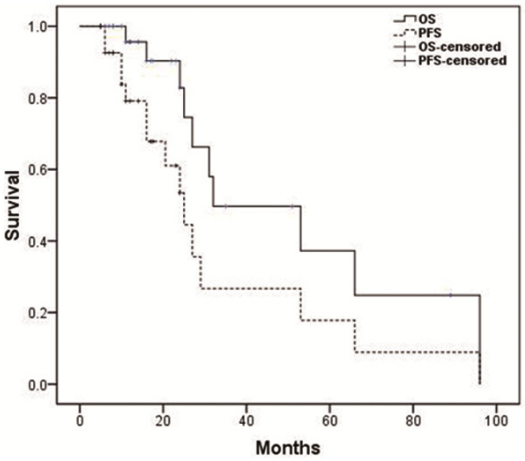

Figure 2. Kaplan-Meier survival analysis for FTC patients in advanced stage.

The IHC stained TMA slides were independently reviewed by two gynecological oncology pathologists who were blinded with the clinical and survival information of each patient. The result of p16 IHC staining was evaluated using a semi-quantitative scoring system proposed by Barnes [13]. Ki-67 and cyclin D1 immunoreactivity was assessed by calculating the percentage of the estimated number of positive nuclear stained cells over the number of total neoplastic cells on the same TMA core. Cyclin D1 expression was classified into low expression, when the percentage of positive cells was less than or equal to 10%, and high expression, when the percentage of positive cells was greater than 10% [14]. The method for assessment of p53 expression followed that described in the previous publication [15]. ER and PR expression was semi-quantitatively assessed with the H-score value [16], which was considered as positive if H-score was >0, otherwise as negative if H-score was 0.

Statistical analysis

The Statistical Package for the Social Sciences (SPSS, version 17.0, Chicago, USA) was used for analysis. For continuous variables, the descriptive values were calculated with the Microsoft excel as means, standard error with deviation, and range. The χ^2 test and Fisher's exact tests were used for analysis of differences among groups. The Kaplan-Meier estimation method was used for survival analysis with a log rank test to assess the significance in difference in survival among groups. The Cox regression model was employed to determine independent prognostic factors for survival. A *P*-value of <0.05 was considered to be statistically significant.

Results

Patients and clinical outcomes

There were 141 cases of type I OC, including 40 cases of MC, 31 cases of EC, 39 cases of CCC, 21 cases of LGSC, and 10 cases of other subtypes. The age of type I OC patients were from 16 to 88 years, with the mean age of 50 years and median age of 51 years. Two hundred and thirty-three cases of type II OC included 219 cases of HGSC, 3 cases of malignant mixed mesodermal tumor (MMMT), 11 cases of poorly differentiated endometrioid carcinoma and undifferentiated carcinoma. Both of the mean and median ages for type II OC patients were

Table 3. Analysis of clinicopathological parameters in patients of type II OC and FTC

Clinicopathological parameters	FTC	Type II OC	*P*-value
Age of onset	56.93±1.57	56.24±0.64	0.666
Age of menarche	15.14±0.28	14.95±0.2	0.526
Menopause status			0.476
Yes	27	156	
No	16	70	
Family history of malignancy			0.077
Yes	9	24	
No	35	205	
Preoperative serum CA125 (U/ml)			0.284
≤35	1	15	
>35, ≤500	18	74	
>500	19	121	
Preoperative serum CA199 (U/ml)			0.777
≤37	35	189	
>37	3	24	
FIGO stage			0.170
I	7	21	
II	8	27	
III+IV	30	185	

56 years with range of 32-85 years. The majority of types I OCs (62.41%) were diagnosed as FIGO I stage, whereas most of type II OCs (79.40%) were in an advanced stage (III+IV) (**Table 2**).

We received 364 patients survival information after a follow-up of 1-202 months. Among these, 22 of 139 (15.83%) type I OC patients were died of cancer with survival period of 4-47 months. Sixteen of 22 cases were in stage III or IV at the time of diagnosis. The mortality rate of type II OC patients was 22.67% (51/225) and the survival time was from 4 to 82 months. Among them, 49 patients were in stage III or IV. Regarding the overall survival (OS) and progression free survival (PFS) of patients in advanced stage, we found significant differences between type I OC and type II OC (**Figure 1**). Patients in advanced type I OC showed worse prognosis than that of type II OC.

Forty-five patients were diagnosed as FTC, including 42 cases of HGSC, 1 case of MMMT, 1 case of unclassified poorly differentiated carcinoma, and 1 case LGSC. Among them, 30 patients were in stage III or IV. The ages of onset were from 39 to 84 years, with the mean age of 57 years and median age of 55 years. The survival analysis showed that OS and PFS were 51 and 33 months, respectively (**Figure 2**).

As shown in **Table 3**, our results indicated that type II OC and FTC had no prominent difference in the age of onset, age of menarche, menopause status, family history of malignancy, preoperative serum levels of CA125 and CA19-9, and FIGO stage. The survival analysis of the patients with advanced type II OC and those with FTC showed no significant difference (**Figure 3**). Also, there was no significant difference in PFS between patients with type II OC and FTC in early stage (I+II) either (P=0.807).

Immunohistochemical analysis

Excluding patients received neoadjuvant chemotherapy, our results showed that there was no significant difference in the expression of the immunohistochemical markers between FTC and type II OC (**Table 4**). The positive expression rates of p53 in FTC and type II OC were 65.7% and 74.1%, respectively, and medium to strong positive expression rates were 73.5% and 76.8% in p16, respectively. The high expression rates of cyclin D1 were 36.4% and 48.0%, and ER were 67.6% and 68.9% as well as PR was 44.1% and 56.7%, respectively. In addition, Ki-67 index was slightly higher in FTC.

Assessment of STIC in OC and FTC

One hundred and forty-three OC cases including 106 cases of type II OC and 37 cases of type I OC, were collected from 2010 to 2014, and the fallopian tubes were sampled using the SEE-FIM protocol. STICs were observed in 43 of 103 (41.7%) type II OC patients (**Figure 4**). STICs were not only found in fimbrial end of tube (34 cases), but also in the fallopian tube ampulla (9 cases). STICs were confirmed by immunohistochemical staining of p53 and Ki-67 [17, 18]. There were also 26 patients with only FT mucosal invasive carcinoma (**Figure 4**). Moreover, we reviewed the OC cases from 2003 to 2009 which were diagnosed according to the conventional criteria of primary site, and

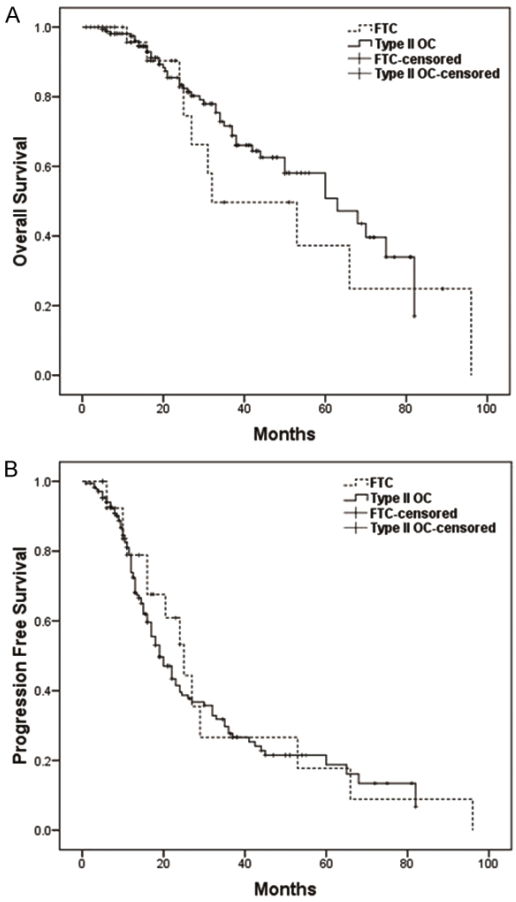

Figure 3. Kaplan-Meier survival analysis for cases of type II OC and FTC in advanced stage.

Table 4. Immunohistochemical analysis in patients of type II OC and FTC

	FTC	Type II OC	*P*-value
p53			
Positive	23	137	0.310
Negative	12	48	
p16			
-	2	19	0.074
+	7	23	
++	4	54	
+++	21	85	
cyclin D1			
High expression	12	86	0.216
Low expression	21	93	
ER			
Positive	23	122	0.883
Negative	11	55	
PR			
Positive	15	101	0.175
Negative	19	77	
Ki-67 index	41.48±3.60	37.10±1.28	0.258

the tubes were sampled using the traditional method. In 18 HGSC patients, the tubal lesions (STIC and/or FT mucosal invasive carcinoma) were observed in unilateral or bilateral fimbrial end/ampulla of tube, of which 14 cases showed STIC, and 4 cases showed invasive mucosal carcinoma in tube.

A total of 87 OC cases were associated with the tubal lesions. Among 42 patients with fallopian tube HGSC, 22 cases (52.38%) had STIC (**Figure 5**). According to several related references [19-21], we named these 129 cases mentioned above as cases of "newly assigned FTC".

The tubal lesions were not observed in other 74 OC patients, included 37 cases of type II OC and 37 cases with type I OC.

Clinicopathological characteristics in cases with newly assigned FTC

The clinicopathological characteristics of the 129 cases of newly assigned FTC were compared with cases of type II OC without tubal lesions and type I OC patients, respectively (**Table 5**). The results showed that there was no significant difference between newly assigned FTC and type II OC without tubal lesions in age of onset, age of menarche, menopause status, family history of malignancy, preoperative serum levels of CA125 and CA19-9, and FIGO stage. However, there were significant differences between newly assigned FTC and type I OC in age of onset, age of menarche, menopause status, preoperative serum levels of CA125 and CA19-9, and FIGO stage. In addition, the majority of cases of newly assigned FTC and type II OC without tubal lesions were in advanced stage (III or IV), while most cases in the type I OC group were in early stage (I or II).

The Kaplan-Meier estimation showed no significant difference in the OS and PFS between advanced patients of newly assigned FTC and type II OC without tubal lesions, while significant difference between newly assigned FTC and type I OC (**Figure 6**). The mean OS of advanced patients with newly assigned FTC and type I OC were 52.17 months and 21.81 months, while the mean PFS were 28.68 months and 14.57 months, respectively.

Table 6 showed that the expression of p53, p16, ER, and Ki-67 were high in the former two

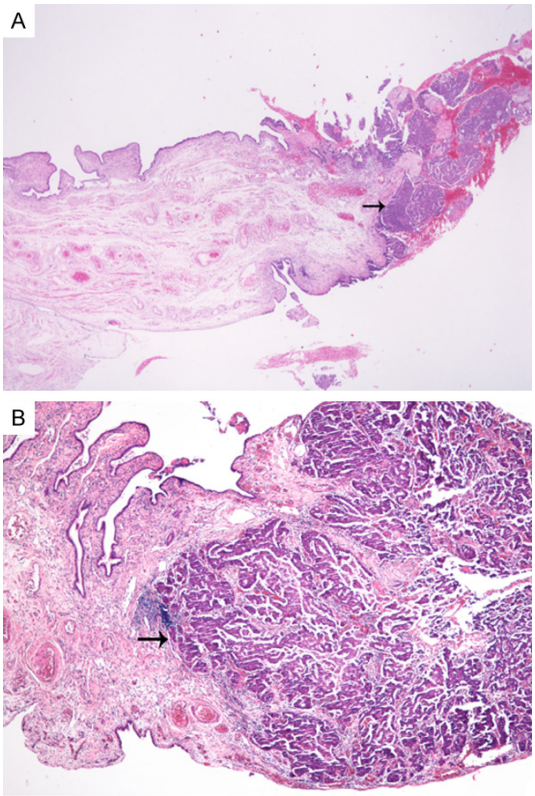

Figure 4. STIC and FT mucosal invasive HGSC in ovarian HGSC patients. A: STIC, as black arrows denoted (HE×20); B: FT mucosal invasive carcinoma (as black arrows denoted, HE×40).

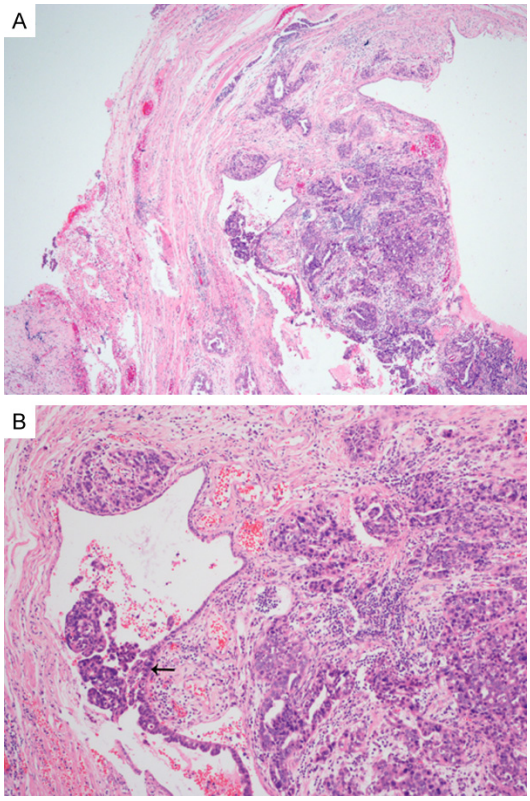

Figure 5. Tubal invasive HGSC with STIC. (A) HE×40, (B) STIC as black arrows denoted, HE×100.

groups, and those in type I OC were much lower. Cyclin D1 was significantly high expressed in type I OC patients. In addition, there was no significant difference in PR expression among the three groups.

Cox's regression analysis showed that FIGO stage was an independent prognostic factor in cases of newly assigned FTC (OR=8.619) (**Table 7**).

Discussion

Due to the lack of specific clinical symptoms, it was hard to have an early diagnosis with OC, and most patients presented with advanced-stage disease [22]. Most patients are postmenopausal women aged near 60-year-old, and its etiology was associated with a variety of factors. BRCA mutation was the most well-known risk factor [23, 24]. Moreover, hormone levels, chronic inflammation, smoking, high fat diet, obesity, infertility and environmental factors were also risk factors of OC. And the pathogenesis and histological changes of FTC were very similar to OC.

In western countries, the median age of patients with OC was over 60 years [25, 26]. In our study, the median and mean ages of onset for type II OC patients were similar to another research from China [27], but less than patients in western countries. This may be related to China's one-child policy or ethnic differences. Family history in this study included breast cancer, OC and other malignancies. Among them, 18 cases were with breast cancer/OC family history, 11 cases with gastric cancer, 10 cases with esophageal cancer and 18 cases with other miscellaneous malignancy. Malignancies of digestive tract were the most common.

Similar to the literatures, our data showed that HGSC was the most common histological subtype of OC (219/374, 58.56%), and most advanced cases were patients with type II OC. These results were consistent with the large number and rapid clinical progression of type II

Table 5. The clinicopathological characteristics in patients of newly assigned FTC, type II OC without tubal lesions, type I OC

Clinicopathological parameters	Newly assigned FTC	Type II OC without tubal lesions	Type I OC	*P*-value	
				*P*1	*P*2
Age of onset	57.40±0.84	56.32±1.60	51.16±2.85	0.546	0.042
Age of menarche	14.94±0.16	15.22±0.31	14.41±0.22	0.421	0.091
Menopause status				0.621	0.003
Yes	89	23	15		
No	38	12	20		
Family history of malignancy				0.250	0.381
Yes	17	2	7		
No	112	35	30		
Preoperative serum CA125 (U/ml)				0.882	0.000
≤35	5	1	10		
>35, ≤500	45	12	14		
>500	65	21	6		
Preoperative serum CA199 (U/ml)				0.296	0.000
≤37	104	34	18		
>37	11	1	12		
FIGO stage				0.218	0.000
I	7	5	26		
II	17	3	1		
III+IV	105	29	10		

Notes: *P*1: Newly assigned FTC vs. Type II OC without tubal lesions; *P*2: Newly assigned FTC vs. Type I OC.

OC. The mean OS for advanced type I OC and type II OC patients were 43.51 and 55.94 months, while the corresponding mean PFS were 17.44 and 30.98 months, respectively. Therefore, our results also implied that type I OC was insensitive to chemotherapy, and the prognosis of patients with advanced type I OC was worse than that of type II OC.

Compared with a clinical research with large sample of primary FTC [28], our data showed that FTC patients in Chinese population had the following characteristics: younger age of onset (median age: 55 vs. 62), a higher number of clinically advanced cases (67% vs. 53%), and the median OS and PFS being significantly shorter in patients with advanced disease (OS: 32 m vs. 62 m; PFS: 25 m vs. 38 m). These suggested that FTC in the Chinese population has a worse prognosis.

Several clinical researches [1, 26, 29] compared the prognosis of serous OC and FTC patients, but the results were variable. Some found the prognosis was similar between serous OC and FTC patients [30], and some concluded that FTC patients had better prognosis than OC patients in advanced stage. A study [26] analyzed the prognostic of 12336 cases of pelvic HGSC from 2004 to 2009, and found that the prognosis of patients of tubal HGSC in advanced stage is better than patients of OC. However, the criteria for assessment for the primary site are not mentioned in the literature. Our data indicated that OS and PFS of type II OC patients in advanced stage have no significant difference compared with FTC patients according to the traditional criteria of primary site.

The WHO classification and subsequent literatures combined OC and FTC together [31, 32], based on their similar epidemiological characteristics and clinical features. We found no significant difference between cases of type II OC and FTC in the clinicopathologic parameters and immunohistochemical markers. And survival analysis showed that there were no significant differences between the two groups in OS of patients in the advanced stage, and in PFS of patients not only in early stage but also in advanced stage. These suggested that etiology

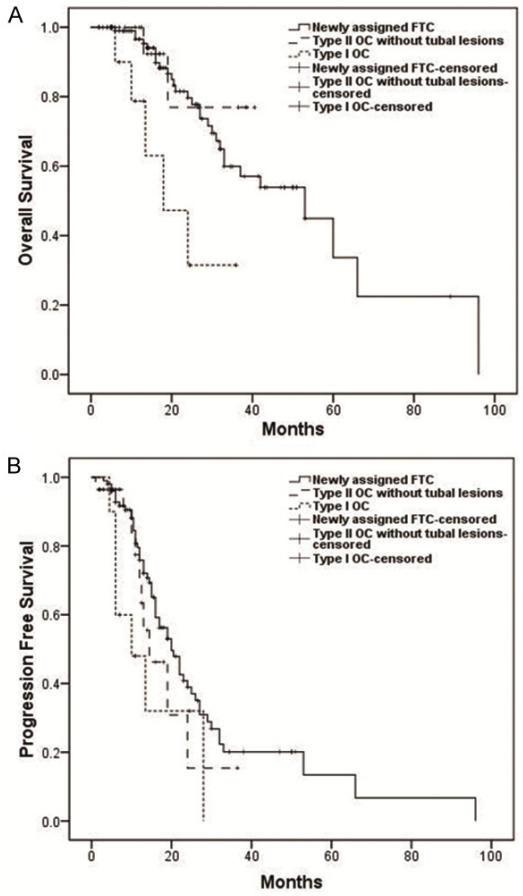

Figure 6. Kaplan-Meier survival analysis for cases in advanced stage of newly assigned FTC, type II OC without tubal lesions, type I OC. A: Newly assigned FTC vs. type II OC without tubal lesions (*P*=0.554), and Newly assigned FTC vs. Type I OC (*P*=0.004). B: Newly assigned FTC vs. Type II OC without tubal lesions (*P*=0.328), and Newly assigned FTC vs. Type I OC (*P*=0.040).

and pathogenesis of FTC and OC might be similar, which supported the hypothesis that type II OC and FTC were in essentially the same disease.

STIC provided a basis for the early identification and prevention of ovarian HGSC, which was of great clinical significance. In our study, 43 cases of HGSC showed STIC, including 9 cases of ipsilateral STIC, 1 case of contralateral STIC, 25 cases of bilateral ovarian lesions with unilateral STIC and 8 cases of bilateral ovarian lesions with bilateral STIC. The rate of STIC was similar to reported in the literature [8]. We also found 18 cases with the tubal lesions in patients using non-SEE-FIM protocol. Moreover, STIC were closely related to FTC. Our histological findings provided powerful pathological support for the hypothesis that most pelvic HGSC originate from the fallopian tube.

In the newly revised FIGO staging guidelines, OC, FTC and peritoneal cancer staging were unified [31]. In some cases, the primary site may not be possible to clearly delineated should be listed as "undesigneted" or described as "fallopian tube-ovarian HGSC" [33, 34]. However, it was extremely important to determine the primary site of pelvic HGSC for epidemiological studies, morbidity, mortality, data collection and clinical trials. Some studies recommended that pelvic HGSCs, which are only associated with FT mucosal invasive HGSC, should be included in the fallopian tube origins. Evidence includes: (1) The majority of FT mucosal invasive HGSC was associated with STIC; (2) The progression of tumor invasion was in situ carcinoma/intraepithelial neoplasia to early invasive cancer, and further progressing to invasive cancer; (3) It was impossible to observe the whole histology of the lesion due to the limitations of pathological samples and slides.

For a long time, most clinical studies have identified OC and FTC as two separate cancers, and did not consider that the histological features of HGSC mostly associated with STIC. Therefore, these studies might be biased. Considering this, we firstly combined cases of OC with the tubal lesions and the "traditional" FTC, and defined as "newly assigned FTC". Compared patients of newly assigned FTC with type II OC without tubal lesions, there was no significant difference in the clinicopathological parameters as well as in OS and PFS of patients with advanced stage, and the results of IHC were similar between the two groups. These were similar to the analysis between the "conventional" type II OC and FTC (**Tables 3**, **4** and **Figure 3**), and provided a basis for the hypothesis that "tubal epithelium may be the origin of high-grade ovarian serous carcinomas that lack evidence of tubal involvement" [4]. However, there were significant differences between cases of newly assigned FTC and type I OC in a number of clinicopathological parameters, and survival in patients with advanced disease, which was consistent with the dualistic model of epithelial ovarian cancer. Furthermore, Cox's regression analysis showed that FIGO stage

Table 6. Immunohistochemical analysis in patients of newly assigned FTC, type II OC without tubal lesions, type I OC

	Newly assigned FTC	Type II OC without tubal lesions	Type I OC	*P*-value	
				*P*1	*P*2
p53				0.396	0.000
Positive	86	28	5		
Negative	32	7	32		
p16				0.583	0.000
-	13	1	12		
+	15	4	15		
++	30	10	7		
+++	58	14	1		
cyclin D1				0.061	0.002
High expression	58	9	28		
Low expression	57	20	7		
ER				0.509	0.000
Positive	75	17	11		
Negative	40	12	24		
PR				0.589	0.168
Positive	58	13	13		
Negative	57	16	22		
Ki-67 index	39.73±1.79	41.27±3.56	27.12±4.00	0.698	0.007

*Notes: P*1: Newly assigned FTC vs. Type II OC without tubal lesions; *P*2: Newly assigned FTC vs. Type I OC.

Table 7. The analysis of independent prognostic factors by Cox regression model for patients with newly assigned FTC

	Sig.	Exp (B)	95.0% CI for Exp (B)	
			Lower	Upper
FIGO stage (I+II vs. III+IV)	0.035	8.619	1.169	63.566

was an independent prognostic factor in newly assigned FTC patients.

Bilateral salpingo-oophorectomy (BSO) has become the standard-of-care for risk reduction in women at hereditary risk of ovarian cancer in Europe and the US. However, this operation has not been widely recognized and implemented in China. Our data also provides theoretical support for prophylactic resection of the bilateral fallopian tubes instead of BSO [35].

In summary, our data shows the younger age of onset and the worse prognosis in Chinese women of type II OC and FTC than that of western country. The clinicopathological characteristics of type II OC were similar to FTC, and STIC is a common histological change in pelvic HGSC in Chinese women. Moreover, there is no significant difference in many clinicopathological parameters between cases of newly assigned FTC and type II OC without tubal lesions, but much different from cases of type I OC. Our results are consistent with the dualistic model of epithelial ovarian cancer. It should be noted that research of newly assigned FTC is limited to a region and a small number of cases. Further clinical investigations with larger regions and more samples are required.

Acknowledgements

This work was supported by Medical Science and Technology Development Program Fund of Nanjing City (YKK10071 and YKK16090).

Disclosure of conflict of interest

None.

Address correspondence to: Yaping Wang, Jiangsu Key Laboratory of Molecular Medicine, Department of Medical Genetics, Nanjing University Medical School, Nanjing, Jiangsu Province, China. E-mail: wangyap@nju.edu.cn

References

[1] Wethington SL, Herzog TJ, Seshan VE, Bansal N, Schiff PB, Burke WM, Cohen CJ and Wright JD. Improved survival for fallopian tube cancer: a comparison of clinical characteristics and outcome for primary fallopian tube and ovarian cancer. Cancer 2008; 113: 3298-3306.

[2] Shih Ie M and Kurman RJ. Ovarian tumorigenesis: a proposed model based on morphological and molecular genetic analysis. Am J Pathol 2004; 164: 1511-1518.

[3] Colgan TJ, Murphy J, Cole DE, Narod S and Rosen B. Occult carcinoma in prophylactic oophorectomy specimens: prevalence and association with BRCA germline mutation status. Am J Surg Pathol 2001; 25: 1283-1289.

[4] Kurman RJ and Shih Ie M. The origin and pathogenesis of epithelial ovarian cancer: a proposed unifying theory. Am J Surg Pathol 2010; 34: 433-443.
[5] Medeiros F, Muto MG, Lee Y, Elvin JA, Callahan MJ, Feltmate C, Garber JE, Cramer DW and Crum CP. The tubal fimbria is a preferred site for early adenocarcinoma in women with familial ovarian cancer syndrome. Am J Surg Pathol 2006; 30: 230-236.
[6] Piek JM, van Diest PJ, Zweemer RP, Jansen JW, Poort-Keesom RJ, Menko FH, Gille JJ, Jongsma AP, Pals G, Kenemans P and Verheijen RH. Dysplastic changes in prophylactically removed Fallopian tubes of women predisposed to developing ovarian cancer. J Pathol 2001; 195: 451-456.
[7] Vang R, Shih Ie M and Kurman RJ. Fallopian tube precursors of ovarian low- and high-grade serous neoplasms. Histopathology 2013; 62: 44-58.
[8] Przybycin CG, Kurman RJ, Ronnett BM, Shih Ie M and Vang R. Are all pelvic (nonuterine) serous carcinomas of tubal origin? Am J Surg Pathol 2010; 34: 1407-1416.
[9] Salvador S, Rempel A, Soslow RA, Gilks B, Huntsman D and Miller D. Chromosomal instability in fallopian tube precursor lesions of serous carcinoma and frequent monoclonality of synchronous ovarian and fallopian tube mucosal serous carcinoma. Gynecol Oncol 2008; 110: 408-417.
[10] Berek JS, Crum C and Friedlander M. Cancer of the ovary, fallopian tube, and peritoneum. Int J Gynaecol Obstet 2012; 119 Suppl 2: S118-129.
[11] Huang Z, Zheng Y, Wen W, Wu C, Bao P, Wang C, Zhong W, Gao YT, Jin F, Xiang YB, Shu XO and Beeghly-Fadiel A. Incidence and mortality of gynaecological cancers: secular trends in urban Shanghai, China over 40 years. Eur J Cancer 2016; 63: 1-10.
[12] Teng Z, Han R, Huang X, Zhou J, Yang J, Luo P and Wu M. Increase of incidence and mortality of ovarian cancer during 2003-2012 in Jiangsu province, China. Front Public Health 2016; 4: 146.
[13] Barnes DM, Dublin EA, Fisher CJ, Levison DA and Millis RR. Immunohistochemical detection of p53 protein in mammary carcinoma: an important new independent indicator of prognosis? Hum Pathol 1993; 24: 469-476.
[14] Bali A, O'Brien PM, Edwards LS, Sutherland RL, Hacker NF and Henshall SM. Cyclin D1, p53, and p21Waf1/Cip1 expression is predictive of poor clinical outcome in serous epithelial ovarian cancer. Clin Cancer Res 2004; 10: 5168-5177.
[15] Yemelyanova A, Vang R, Kshirsagar M, Lu D, Marks MA, Shih Ie M and Kurman RJ. Immunohistochemical staining patterns of p53 can serve as a surrogate marker for TP53 mutations in ovarian carcinoma: an immunohistochemical and nucleotide sequencing analysis. Mod Pathol 2011; 24: 1248-1253.
[16] Finn RS, Press MF, Dering J, O'Rourke L, Florance A, Ellis C, Martin AM and Johnston S. Quantitative ER and PgR assessment as predictors of benefit from lapatinib in postmenopausal women with hormone receptor-positive, HER2-negative metastatic breast cancer. Clin Cancer Res 2014; 20: 736-743.
[17] Vang R, Visvanathan K, Gross A, Maambo E, Gupta M, Kuhn E, Li RF, Ronnett BM, Seidman JD, Yemelyanova A, Shih Ie M, Shaw PA, Soslow RA and Kurman RJ. Validation of an algorithm for the diagnosis of serous tubal intraepithelial carcinoma. Int J Gynecol Pathol 2012; 31: 243-253.
[18] Visvanathan K, Vang R, Shaw P, Gross A, Soslow R, Parkash V, Shih Ie M and Kurman RJ. Diagnosis of serous tubal intraepithelial carcinoma based on morphologic and immunohistochemical features: a reproducibility study. Am J Surg Pathol 2011; 35: 1766-1775.
[19] Kulkarni S, Singh N and Faruqi AZ. Tubal handling significantly affects site assignment in non-uterine high-grade serous carcinoma. Histopathology 2015; 67: 585-587.
[20] Singh N, Gilks CB, Wilkinson N and McCluggage WG. Assignment of primary site in high-grade serous tubal, ovarian and peritoneal carcinoma: a proposal. Histopathology 2014; 65: 149-154.
[21] Singh N, Gilks CB, Wilkinson N and McCluggage WG. Assessment of a new system for primary site assignment in high-grade serous carcinoma of the fallopian tube, ovary, and peritoneum. Histopathology 2015; 67: 331-337.
[22] Chornokur G, Amankwah EK, Schildkraut JM and Phelan CM. Global ovarian cancer health disparities. Gynecol Oncol 2013; 129: 258-264.
[23] George SH and Shaw P. BRCA and early events in the development of serous ovarian cancer. Front Oncol 2014; 4: 5.
[24] Yang D, Khan S, Sun Y, Hess K, Shmulevich I, Sood AK and Zhang W. Association of BRCA1 and BRCA2 mutations with survival, chemotherapy sensitivity, and gene mutator phenotype in patients with ovarian cancer. Jama 2011; 306: 1557-1565.
[25] Menon U, Gentry-Maharaj A, Hallett R, Ryan A, Burnell M, Sharma A, Lewis S, Davies S, Philpott S, Lopes A, Godfrey K, Oram D, Herod J, Williamson K, Seif MW, Scott I, Mould T, Woolas R, Murdoch J, Dobbs S, Amso NN, Leeson S, Cruickshank D, McGuire A, Campbell S, Fallowfield L, Singh N, Dawnay A, Skates SJ, Par-

mar M and Jacobs I. Sensitivity and specificity of multimodal and ultrasound screening for ovarian cancer, and stage distribution of detected cancers: results of the prevalence screen of the UK Collaborative Trial of Ovarian Cancer Screening (UKCTOCS). Lancet Oncol 2009; 10: 327-340.

[26] Usach I, Blansit K, Chen LM, Ueda S, Brooks R, Kapp DS and Chan JK. Survival differences in women with serous tubal, ovarian, peritoneal, and uterine carcinomas. Am J Obstet Gynecol 2015; 212: 188.e181-186.

[27] Li X, Zheng S, Chen S, Qin F, Lau S and Chen Q. Trends in gynaecological cancers in the largest obstetrics and gynaecology hospital in China from 2003 to 2013. Tumour Biol 2015; 36: 4961-6.

[28] Pectasides D, Pectasides E, Papaxoinis G, Andreadis C, Papatsibas G, Fountzilas G, Pliarchopoulou K, Macheras A, Aravantinos G and Economopoulos T. Primary fallopian tube carcinoma: results of a retrospective analysis of 64 patients. Gynecol Oncol 2009; 115: 97-101.

[29] Moore KN, Moxley KM, Fader AN, Axtell AE, Rocconi RP, Abaid LN, Cass IA, Rose PG, Leath CA 3rd, Rutledge T, Blankenship D and Gold MA. Serous fallopian tube carcinoma: a retrospective, multi-institutional case-control comparison to serous adenocarcinoma of the ovary. Gynecol Oncol 2007; 107: 398-403.

[30] Dunn MS, Manahan KJ and Geisler JP. Primary carcinoma of the fallopian tube and epithelial ovarian carcinoma: a case-control analysis. J Reprod Med 2008; 53: 691-694.

[31] Mutch DG and Prat J. 2014 FIGO staging for ovarian, fallopian tube and peritoneal cancer. Gynecol Oncol 2014; 133: 401-404.

[32] Pereira A, Perez-Medina T, Magrina JF, Magtibay PM, Rodriguez-Tapia A, Peregrin I, Mendizabal E and Ortiz-Quintana L. International Federation of gynecology and obstetrics staging classification for cancer of the ovary, fallopian tube, and peritoneum: estimation of survival in patients with node-positive epithelial ovarian cancer. Int J Gynecol Cancer 2015; 25: 49-54.

[33] Prat J. FIGO's staging classification for cancer of the ovary, fallopian tube, and peritoneum: abridged republication. J Gynecol Oncol 2015; 26: 87-89.

[34] Prat J. Staging classification for cancer of the ovary, fallopian tube, and peritoneum. Int J Gynaecol Obstet 2014; 124: 1-5.

[35] Daly MB, Dresher CW, Yates MS, Jeter JM, Karlan BY, Alberts DS and Lu KH. Salpingectomy as a means to reduce ovarian cancer risk. Cancer Prev Res (Phila) 2015; 8: 342-348.