

Erratum

Primary cardiac lymphoma mimicking atrial myxoma in an HIV and EBV-positive patient: a case report: Int J Clin Exp Pathol. 2018; 11(11): 5497-5501

Guanghui Gong^{1,2,3}, Ting Lin^{4,5}, Keda Yang^{1,2}

¹Department of Pathology, Xiangya Hospital, Central South University, Changsha, Hunan, People's Republic of China; ²Department of Pathology, School of Basic Medical Science, Central South University, Changsha, Hunan, People's Republic of China; ³Institute of Reproductive and Stem Cell Engineering, School of Basic Medical Science, Central South University, Changsha, People's Republic of China; ⁴Hunan Provincial Key Laboratory for The Prevention and Treatment of Ophthalmology and Otolaryngology Diseases with Traditional Chinese Medicine, Changsha, People's Republic of China; ⁵Hunan Provincial Key Discipline of Chinese Head and Neck Science, Changsha, People's Republic of China

Received January 24, 2019; Accepted February 22, 2019; Epub March 1, 2019; Published March 15, 2019

In this article published in IJCEP0085329, The correct **Figure 2** is provided. On page 5499, line 5, 0-8 mg/LI should be 0-8 mg/L.

South University, 87 Xiangya Road, Changsha 410008, Hunan, People's Republic of China. Tel: 86-13170417861; Fax: 86-731-84327291; E-mail: 348709454@qq.com

Address correspondence to: Dr. Keda Yang, Department of Pathology, Xiangya Hospital, Central

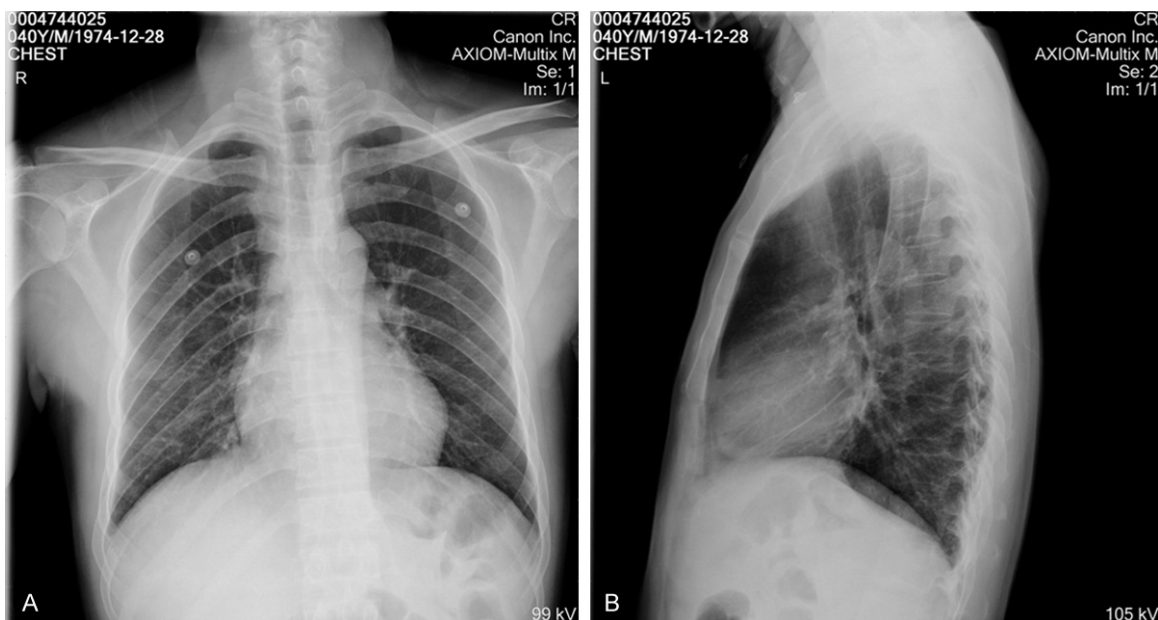


Figure 2. Post-surgery Chest X ray was negative for metastasis (A. Anteroposterior film; B. Lateral film).