

## Case Report

# Concurrent bilateral testicular hamartomas and serous borderline tumors in a patient with complete androgen insensitivity syndrome: a case report and review of the literature

Ching-Heng Ting, Pao-Shu Wu

*Department of Pathology, MacKay Memorial Hospital, New Taipei City, Taiwan, China*

Received January 8, 2019; Accepted March 22, 2019; Epub May 1, 2019; Published May 15, 2019

**Abstract:** We report a case of complete androgen insensitivity syndrome (CAIS) accompanied by serous borderline tumors in a 75-year-old patient. Müllerian epithelial tumors are extremely rare condition in CAIS patients with only a few case reports. We report a case of late-diagnosed testicular feminization with hamartomas, and the first report of serous tumor with borderline malignant potential in such cases.

**Keywords:** Complete androgen insensitivity syndrome, serous borderline tumor, testicular hamartoma

### Introduction

Complete androgen insensitivity syndrome (CAIS) is a rare condition of male pseudohermaphroditism in patients with XY karyotype but with female phenotype. The risk of neoplastic disease in CAIS patients is lower than in other types of disorders of sex development (DSD) [1]. However, previous reports showed few cases of gonadal cystic lesion with Müllerian epithelium [2-7]. Here we present an extremely rare case of late-diagnosed CAIS with serous borderline tumor arising from paragonadal tissue, and with concurrent bilateral testicular hamartomas.

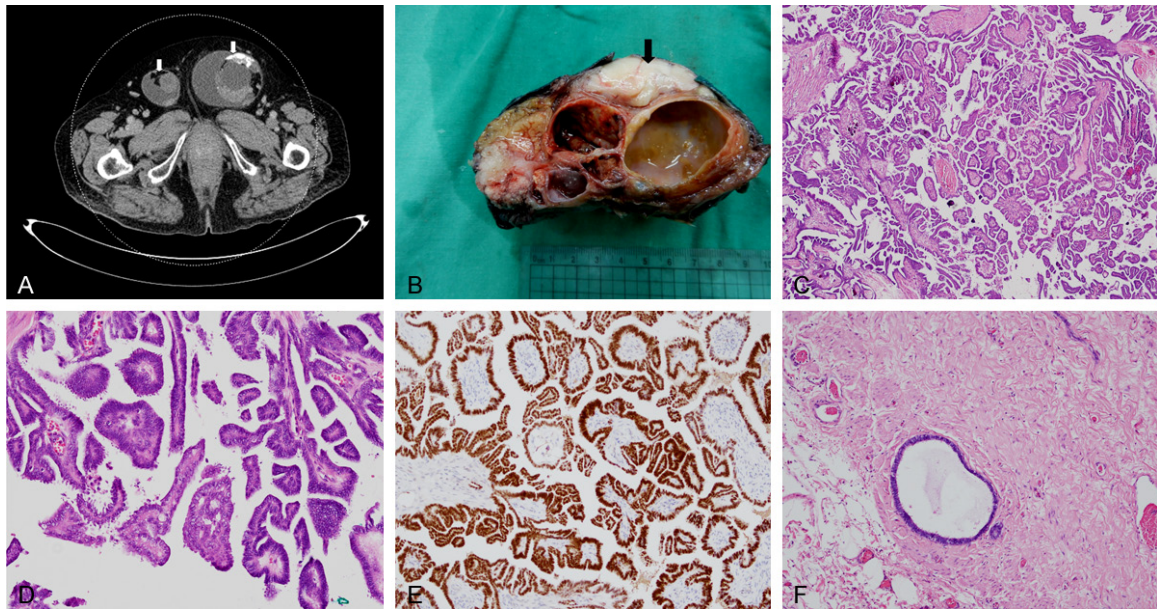
### Case report

A 75-year-old married woman, gravidity 0 and parity 0, visited our outpatient department due to enlarged left inguinal mass. According to her medical record, she was infertile due to primary amenorrhea and absence of uterus. Physical examination showed a protruding mass at left inguinal area. Further computed tomography (CT) scan revealed bilateral multilocular masses with heterogenous solid and cystic components herniating into the canal of Nuck (**Figure**

**1A**). The left side mass was 19 cm in size, and the right side mass was 7 cm in size. Multiple enhancing nodules with calcification and another cystic lesion on omentum were also identified. Serum tumor markers such as CEA (0.83 ng/mL) and CA19-9 (10.59 U/mL) were within normal range but CA-125 (87.37 U/mL) was elevated.

According to the above findings, ovarian cancer with peritoneal dissemination was suspected and a subsequent tumor eradication operation was performed. During the operation, uterus and bilateral fallopian tubes were not identified. Bilateral intra-abdominal masses protruding into inguinal canals were removed. Staging operation was completed with bilateral gonadectomy, omentectomy and lymph node dissection including bilateral pelvic, para-aortic, and subaortic lymph nodes.

Macroscopically, the left abdominal and inguinal tumor mass showed cystic and solid components with rough surface and focally polypoid inner lining. The bilateral gonads were multinodular, firm, and tan-white in color (**Figure 1B**). The majority of tumor mass was located within pelvic cavity and the soft tissue of inguinal



**Figure 1.** Bilateral inguinal tumors. A. Pelvic CT scan showed bilateral heterogeneous tumors with solid and cystic components (white arrows). B. Gross features of left inguinal mass showed a cystic tumor of para-gonadal tissue and tan-white, firm, and nodular gonad (arrow). C. Histologic features of para-gonadal tumor showed complex hierarchical branching papillae with frequent psammomatous calcification (H&E 40×). D. High-power-field shows papillary lining cells with cytologic atypia (H&E 200×). E. Diffuse nuclear stain for PAX8 of tumor cells (100×). F. Simple serous cysts were seen in para-gonadal tissue (H&E 100×).

canal, only focal surface attachment to the left gonad was seen. The right side inguinal mass showed only little amount of polypoid tumor on the surface of peritoneum.

Histologically, the tumor showed hierarchical, branching papillae, lined by cuboidal to columnar epithelium with only mild nuclear atypia. Numerous psammomatous calcifications were seen within the tumor (**Figure 1C** and **1D**). The tumor cells showed diffuse nuclear immunostaining for PAX8 (**Figure 1E**), supporting the Müllerian origin. According to the histological features and immunoprofile, serous borderline tumor was diagnosed. The majority of tumor was located within the peritoneum and para-gonadal soft tissue. Bilateral gonads were not directly involved. Serous borderline tumor arising from para-gonadal tissue was the pathologic diagnosis. The omental cystic lesion showed the same histologic feature of serous borderline tumor. Histologic examination of pelvic, para-aortic, and subaortic lymph nodes showed extensive calcification without tumor involvement. Beside serous borderline tumor, we also found Mullerian-type cysts resembling endosalpingiosis in para-gonadal soft tissue (**Figure 1F**).

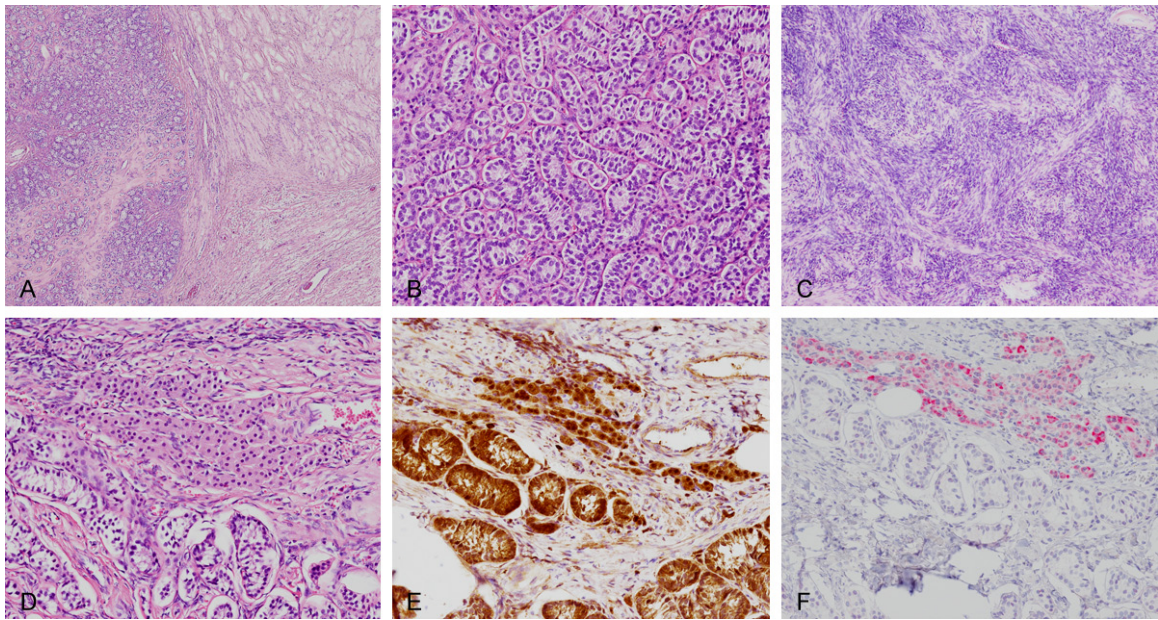
The histologic features of bilateral gonads showed multi-nodular architecture (**Figure 2A**). Nodules of immature Sertoli cell tubules were noted (**Figure 2B**). The background stroma showed fibrotic and hyalinizing degeneration. Foci of ovarian-type stroma and clusters of Leydig cells were also identified (**Figure 2C** and **2D**), and these findings were supported by immunostains of calretinin,  $\alpha$ -inhibin, and Melan-A (**Figure 2E** and **2F**).

Further cytogenetic study was performed and showed 46XY at 5 metaphases (**Figure 3**). With the histologic features, cytogenetic study, and the normal female external appearance and external genitalia, complete androgen insensitivity syndrome (CAIS) with bilateral testicular feminization and hamartomas was diagnosed.

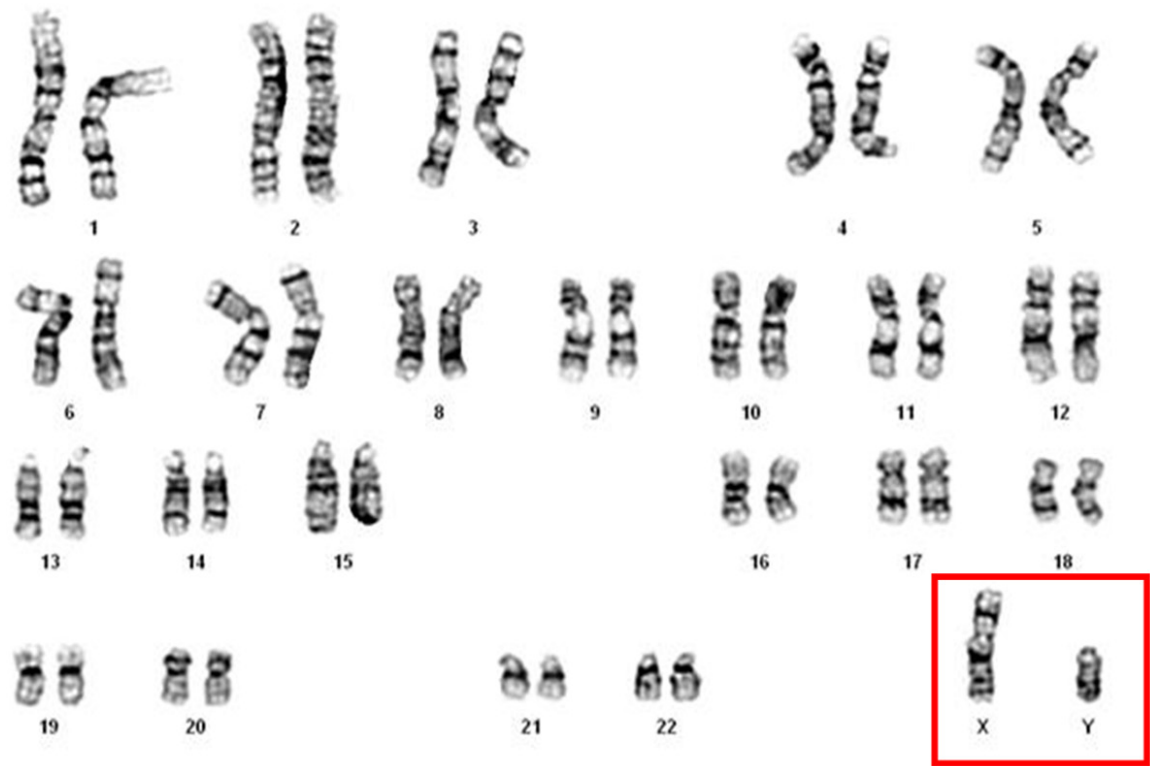## Discussion

Androgen insensitivity syndrome (AIS) is a rare disease, but it is the most common cause of male pseudohermaphroditism with estimated incidence about 1/20000 [8, 9]. AIS can be further classified into complete AIS (CAIS), partial AIS (PAIS), and mild AIS (MAIS), according to the degree of genital masculinization. The hallmark





**Figure 2.** Bilateral gonads. A. Low magnification field showed a multinodular testicular hamartoma. Hyalinizing degeneration was focally seen (H&E 40×). B. The nodules were mainly composed of compact Sertoli cell tubules. Spermatogenesis was absent (H&E 200×). C. Ovarian-type stroma was occasionally seen (H&E 100×). D. Cluster of Leydig cell aggregates was identified (H&E 200×). E. Both Sertoli cell tubules and stromal Leydig cells were stained with calretinin (200×). F. Stromal Leydig cells were positive for Melan-A (200×).



**Figure 3.** Cytogenetic study of cultured blood lymphocytes showed karyotype 46XY at 5 metaphases.

of genetic abnormality is the defect of the androgen receptor gene [10]. In CAIS, the

patients have normal female external genitalia but the internal genital organs are absent due

to the anti-Müllerian hormone (AMH). Their gonads are present as testes rather than ovaries.

Gonadal neoplasms are the main concern in CAIS patients, especially malignant germ cell tumors. The risk of neoplastic development was considered high previously [11, 12], but recent reports suggest only small number of cases developed malignant germ cell tumors or precursor lesions [13-15]. Prophylactic orchiectomy is the historical standard procedure in CAIS patients, but the timing of surgery is remained controversial. Recently, preservation of gonads with close monitor has become an optional strategy [16]. Besides germ cell tumors, Rutgers and Scully reported the testicular feminization features such as hamartomatous nodules (hamartomas) and Sertoli cell adenoma in CAIS patients [15]. In our case, multi-nodular compact Sertoli cell tubules, ovarian stroma, and stromal Leydig cells hyperplasia were consistent with the features of hamartoma. We are also in agreement with the previous theory that testicular hamartomas in CAIS are not truly neoplastic, but rather than a malformative process [17].

Due to the effect of existing AMH, Müllerian structures, including fallopian tubes, uterus, and upper portion of vagina are regressed in most patients. However, the Müllerian remnants can still be found in CAIS patients [17], such as in the present case. Several previous reports of gonadal cysts or serous cystadenoma suggest Müllerian remnants may be the origin of these cystic lesions. The age distribution of serous cysts is wide, but they mainly occur in post-pubertal age (18 to 78 years old) [2-7]. The prevalence rate of Müllerian cysts or tumors is difficult to evaluate due to the rarity of disease and frequent prophylactic orchiectomy at young age. In our case, we report the first case of serous tumor with borderline malignant potential, which has not been reported previously. Simple serous cystic component is also identified adjacent to serous borderline tumor, suggesting the potential of tumorigenesis and malignant transformation from Müllerian remnants in CAIS patients.

In conclusion, we present a CAIS patient with concurrent bilateral testicular hamartomas and serous borderline tumor. Müllerian remnants may be the origin of para-gonadal cysts.

Although extremely rare, neoplastic growth and even malignant transformation can occur in these patients and clinicians should be aware of this.

## Disclosure of conflict of interest

None.

**Address correspondence to:** Dr. Pao-Shu Wu, Department of Pathology, MacKay Memorial Hospital, No. 45, Minsheng Rd, Tamsui District, New Taipei City 251, Taiwan, China. Tel: +886-2-280-94661; Fax: +886-2-28093385; E-mail: pw2136@gmail.com

## References

- [1] Looijenga LH, Hersmus R, Oosterhuis JW, Cools M, Drop SL and Wolffenbuttel KP. Tumor risk in disorders of sex development (DSD). *Best Pract Res Clin Endocrinol Metab* 2007; 21: 480-495.
- [2] Baksu A, Kabukcuoglu F, Baksu B and Goker N. Bilateral sertoli cell adenoma and serous cyst in a patient with androgen insensitivity syndrome. *Eur J Obstet Gynecol Reprod Biol* 2004; 114: 104-107.
- [3] Fernandez-Vega I, Santos-Juanes J and Garcia-Pravia C. Bilateral sertoli cell adenoma in gonads, associated with serous cystadenoma. *Pol J Pathol* 2014; 65: 154-156.
- [4] Jedrzejczak P, Serdynska-Szuster M, Wachowiak-Ochmanska K, Szuster M, Talarczyk J, Jasinski P and Pawelczyk L. Laparoscopic gonadectomy for androgen insensitivity syndrome—case report. *Ginekol Pol* 2010; 81: 457-460.
- [5] Ozdemir O, Sari ME, Akmut E, Selimova V, Unal T and Atalay CR. Complete androgen insensitivity syndrome with a large gonadal serous papillary cystadenofibroma. *J Hum Reprod Sci* 2014; 7: 148-150.
- [6] Tourlakis D, Schnabel J and Fersis N. Bilateral gonadal cysts and late diagnosis of androgen insensitivity syndrome treated by laparoscopic gonadectomy. *Case Rep Obstet Gynecol* 2011; 2011: 230845.
- [7] Yanai Y, Hiroi H, Osuga Y, Fujimoto A, Momoeda M, Yano T and Taketani Y. Androgen insensitivity syndrome with serous gonadal cyst. *Fertil Steril* 2008; 90: 2018, e9-11.
- [8] Farhud DD, Zarif Yeganeh M, Sadighi H and Zandvakili S. Testicular feminization or androgen insensitivity syndrome (AIS) in iran: a retrospective analysis of 30-year data. *Iran J Public Health* 2016; 45: 1-5.
- [9] Quigley CA, De Bellis A, Marschke KB, el-Adawy MK, Wilson EM and French FS. Androgen receptor defects: historical, clinical, and molecu-

- lar perspectives. *Endocr Rev* 1995; 16: 271-321.
- [10] Jaaskelainen J. Molecular biology of androgen insensitivity. *Mol Cell Endocrinol* 2012; 352: 4-12.
- [11] Manuel M, Katayama PK and Jones HW Jr. The age of occurrence of gonadal tumors in intersex patients with a Y chromosome. *Am J Obstet Gynecol* 1976; 124: 293-300.
- [12] Morris JM and Mahesh VB. Further observations on the syndrome, "testicular feminization". *Am J Obstet Gynecol* 1963; 87: 731-748.
- [13] Chaudhry S, Tadokoro-Cuccaro R, Hannema SE, Acerini CL and Hughes IA. Frequency of gonadal tumours in complete androgen insensitivity syndrome (CAIS): a retrospective case-series analysis. *J Pediatr Urol* 2017; 13: 498. e1-498.e6.
- [14] Cools M, van Aerde K, Kersemaekers AM, Boter M, Drop SL, Wolffenbuttel KP, Steyerberg EW, Oosterhuis JW and Looijenga LH. Morphological and immunohistochemical differences between gonadal maturation delay and early germ cell neoplasia in patients with undervirilization syndromes. *J Clin Endocrinol Metab* 2005; 90: 5295-5303.
- [15] Rutgers JL and Scully RE. The androgen insensitivity syndrome (testicular feminization): a clinicopathologic study of 43 cases. *Int J Gynecol Pathol* 1991; 10: 126-144.
- [16] Deans R, Creighton SM, Liao LM and Conway GS. Timing of gonadectomy in adult women with complete androgen insensitivity syndrome (CAIS): patient preferences and clinical evidence. *Clin Endocrinol (Oxf)* 2012; 76: 894-898.
- [17] Kumavat PV, Chaudhari CS, Padmanabhan A, Gadgil NM, Margam SS, Kshirsagar GR, Rathod UD. Hamartomatous nodule, sertoli cell adenoma in complete androgen insensitivity syndrome with Wolffian/Müllerian duct remnants: an unusual case report. *Annals of Pathology and Laboratory Medicine* 2017; 4: 73-77.