

Case Report

Aquagenic acrokeratoderma: a case report and review of the literature

Xiang Liu¹, Zhichao Liu², Shupeng Zhang³

¹Shandong First Medical University & Shandong Academy of Medical Sciences, Taian, Shandong, China;
Departments of ²Dermatology, ³Pathology, Second Affiliated Hospital of Shandong First Medical University, Taian, Shandong, China

Received March 24, 2020; Accepted April 28, 2020; Epub June 1, 2020; Published June 15, 2020

Abstract: A case of aquagenic acrokeratoderma was reported and the related literature was reviewed. The patient is a 41-year-old male with white papules and plaques on his hands and feet for 2 years after sweating or having contact with water for 3 minutes. The patient was diagnosed with aquagenic acrokeratoderma by relevant examination in our hospital, and was given topical use of 10% salicylic acid ointment once a day and 10% urea cream twice a day. The symptoms were partially relieved and the patients is being followed up.

Keywords: Aquagenic acrokeratoderma, differential diagnosis, treatment

Introduction

Aquagenic acrokeratoderma is a keratotic skin disease that occurs after contact with water. It is reported that the disease is more common in women than in men, and the involvement of the dorsal side of the hand and the feet is most common. Most cases have no abnormal feeling and a few cases can be accompanied by burning or itching in the skin lesions. In this paper, a case of aquagenic acrokeratoderma of a middle-aged male that involved both hands, feet and ankles is reported retrospectively, and we review the literature.

Case report

The patient was a 41-year-old male with white papules and plaques on his hands and feet for 2 years after sweating or contact with water for 3 minutes. Two years ago, the patient's hands and feet had no obvious inducement to become white and swollen after sweating or contact with water. There was no itching, pain, or other discomfort, and the skin lesions gradually disappear after leaving the environment for 20-30 min. untreated. The patient was in good health, no systemic disease, no history of hand and foot hyperhidrosis, no family history of heredi-

tary disease and similar history. Dermatology examination: after immersing both hands in water 3 min, there were symmetrical white papules and white hyperkeratosis spots on the thenar eminence, dorsum of fingers, palms, and wrist flexors of both hands (**Figure 1**). White and dark brown hyperkeratotic patches were scattered around both ankles, lateral edges of feet, and toenails (**Figure 2**). No abnormality was found in other skin and mucous membranes. Histopathology showed hyperkeratosis and focal thickening of the epidermis with only a small amount of lymphocyte infiltration in the papillary layer of the dermis (**Figure 3**). Combined with medical history, and clinical manifestations, and skin reaction after contacting with water and histopathology, aquagenic acrokeratoderma was diagnosed. The symptoms were partially relieved by external use of 10% salicylic acid ointment once a day and 10% urea cream twice a day, and the patient is currently being followed up.

Discussion

Aquagenic acrokeratoderma was first reported in 1996 [1], when it was described as transient reactive papular acrokeratosis associated with hereditary translucent papular acrokeratosis, a

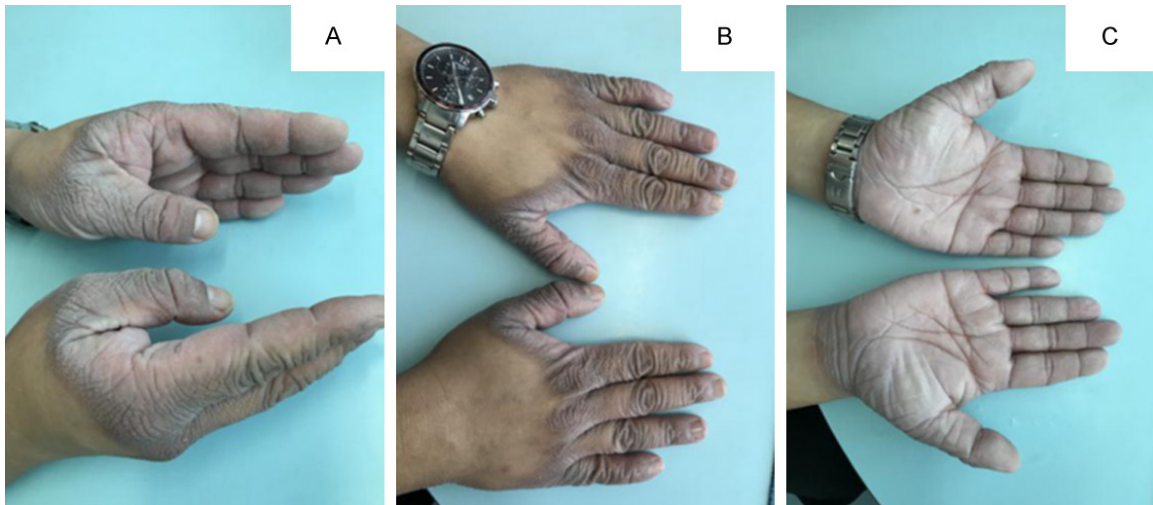


Figure 1. After immersing both hands in water 3 min, there were symmetrical white papules and white hyperkeratosis spots on the thenar eminence, dorsum of fingers, palms, and wrist flexors of both hands (A-C).

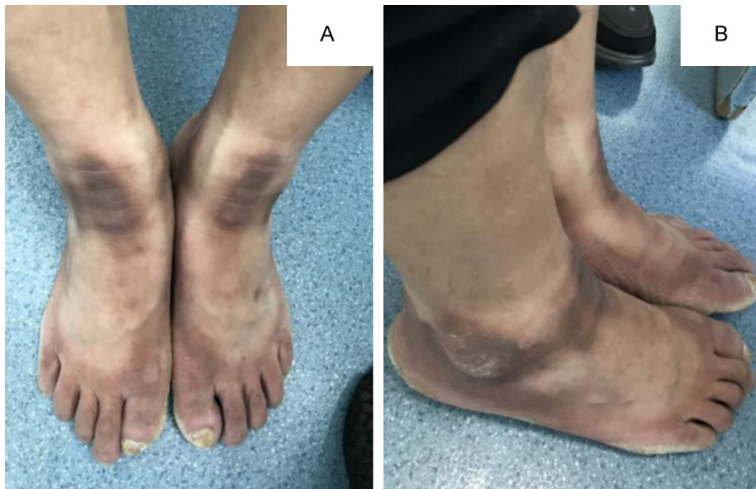

Figure 2. White and dark brown hyperkeratosis patches are scattered around both ankles, lateral edges of feet, and toenails (A, B).

keratosis that occurs after contact with water. At present, the name has not been unified, and it also is known as “aquagenic syringeal acrokeratoderma”, “aquagenic palmoplantar keratoderma” and so on. According to the literature [2-6], the disease is more common in young women, with the history of illness lasting from 1 week to 30 years. Most patients have no abnormal feeling after touching water, or only the local skin has a sense of tightness, while a few patients will get a burning or itching sensation. A few cases have a family history. In addition to the common locations such as palms and feet, some cases involved the nose, mouth, upper lip or double ankle joints and calves, and most of

the complications were hyperhidrosis and cystic fibrosis. In addition, some scholars have pointed out that the disease is not as rare as expected, and there may be a large number of untreated cases due to the temporary characteristics of the course of the disease [4, 5]. A variety of treatments that can improve the condition have been reported in domestic and foreign literatures [4-6, 7, 8], including single or combined use of corticosteroids, calcipotriene ointment [9], 0.025%-0.1% tretinoin cream [10, 11], soaking in 2% alum solution [12], urea cream, sali-

cyclic acid ointment, aluminum hydroxide ointment, 0.01% tazarotene with formalin alcohol [13], botulinum toxin injection [14-16], oral anticholinergic drugs, antihistamines and local narrow band ultraviolet (NB-UVB) irradiation [17], tap water ion electroosmosis therapy [18], and endoscopic thoracic sympathectomy [19], as well as self-limited cases [13]. Because its etiology and pathogenesis are not clear, and the efficacy of related treatment methods are different, there is no consensus on clinical treatment.

The typical skin lesions of aquagenic acrokeratoderma are transient reactive skin keratosis

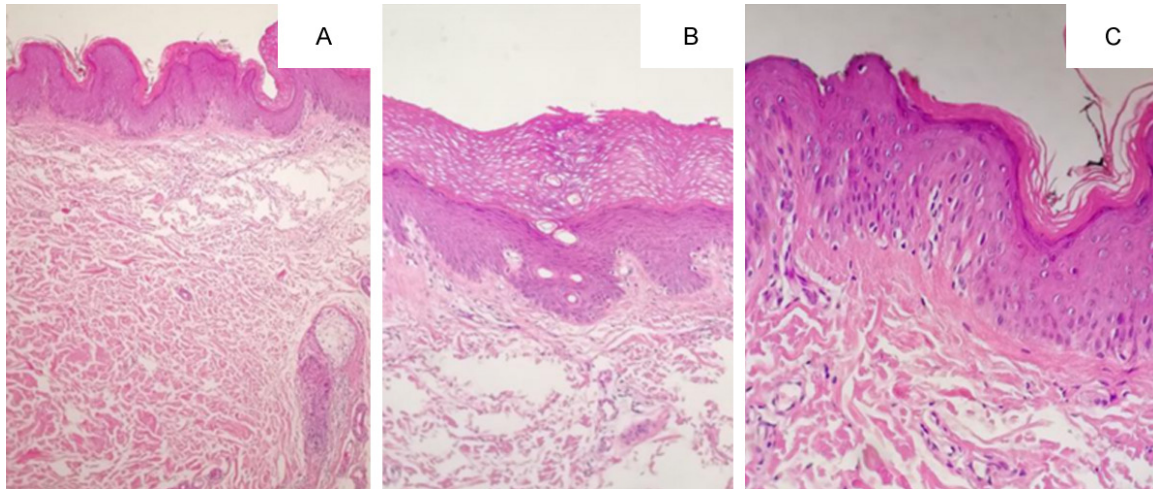


Figure 3. Histopathology showed that the epidermis was locally thickened, with hyperkeratosis and positive keratosis, and there was only a small amount of lymphocyte infiltration around the small vessels of the papillary dermis, which was consistent with non-specific keratosis. A. (H&E: 10×10). B. (H&E: 10×20). C. (H&E: 10×40).

papules caused by water stress, focal skin swelling with translucent white or yellow edematous papules or patches and whitish hyperkeratosis. Some cases can be noted to have dilated sweat gland pores and palms that are sweaty, with or without pain, burning sensation and itching. The lesion can decrease or disappear soon after drying, and the metatarsal skin is less involved [20]. Some reports show that the disease is related to heredity and may be an autosomal recessive hereditary dermatosis [13, 21, 22]. Other major viewpoints are related to sweat tube distortion [2], stratum corneum barrier dysfunction [8], and electrolyte concentration in sweat. Some related studies have shown that the homozygous or heterozygous mutation of F508 in the cystic fibrosis gene (CFTR) reduces the reabsorption of electrolytes in the endocrine tube, which leads to the increase of chloride and sodium content in sweat and causes the symptoms [23]. The role of osmotic sensitive receptor-vanilloid receptor 1 (TVRT-1) and the abnormal expression of aquaporin AQP3, AQP5 and AQP10 may also be related to the pathogenesis of this disease [8]. Other studies have shown that the disease is related to the increase of sodium reabsorption caused by the inhibitory effect of cyclooxygenase-2 inhibitor on epidermal cells [3, 8]. The histopathology of aquagenic acrokeratoderma is generally shown in the focal cuticular layer, spinous layer hypertrophy, and sweat gland orifice dilatation of the epidermis [3]. Cemil found that compared with the normal appearance

area of the thenar area, in addition to the revealed a marked dilatation of sweat duct puncta of the lesion after touching water, the “tripe-like” structure could also be seen under the dermoscope [24]. Therefore, in view of the fact that the width of the sweat gland opening of the lesion is 3 times wider than that of the normal skin area under dermoscope, dermoscopy can be used as a rapid and non-invasive diagnostic method before histopathology or as an alternative to histopathology to supplement the diagnosis of the disease after “water contact reaction” [8].

This patient was a male, middle-aged onset, no history of hand and foot hyperhidrosis, no family-related history of similar disease. After immersion in water for 3 min, symmetrical white papules and white keratosis appeared on the thenar eminence, the dorsum and ventrum of the finger, palm, and wrist flexion of both hands, and the skin of the foot became white and swollen. The skin lesions gradually disappeared after being away from water 20-30 min, and no uncomfortable symptoms such as pain, burning sensation, and itching were reported. Histopathology showed hyperkeratosis and focal thickening of the epidermis with only a small amount of lymphocyte infiltration in the papillary layer of the dermis. Combined with the clinical manifestations, water contact reaction and histopathology, the diagnosis of aquagenic acrokeratoderma was clear. This disease needs to be distinguished from hereditary papula-

translucent acrokeratoderma, symmetric acral keratoderma, acrokeratoelastoidosis, aquagenic urticaria, and aquagenic pruritus. Clinical manifestations, water contact reaction and recovery time can help to differentiate, and dermoscopy or dermatopathological examination can be used if necessary. The etiology, pathogenesis, and corresponding treatment of aquagenic acrokeratoderma is worthy of further research and exploration.

Acknowledgements

All procedures performed in studies involving human participants were in accordance with the ethical standards of the institutional and with the national research committee and with the Helsinki declaration and its later amendments or comparable ethical standards. The study was performed according to the Declaration of Helsinki and was approved by the ethics committee of the Second Affiliated Hospital of Shandong First Medical University. Written informed consents were obtained from all the subjects recruited into our study.

Disclosure of conflict of interest

None.

Address correspondence to: Zhichao Liu, Department of Dermatology, Second Affiliated Hospital of Shandong First Medical University, No. 366 Taishan Avenue, Taian 271000, Shandong, China. E-mail: liu517206@163.com

References

- [1] English JC and McCollough ML. Transient reactive papulotranslucent acrokeratoderma. *J Am Acad Dermatol* 1996; 34: 686-687.
- [2] Kutlubay Z, Engin B, Baglam S, Khatib R, Demirkesen C and Aydemir EH. Case report: treatment failure in a case of aquagenic syringeal acrokeratoderma. *J Cosmet Laser Ther* 2015; 17: 224-226.
- [3] Rongioletti F, Tomasini C, Crovato F and Marchesi L. Aquagenic (pseudo) keratoderma: a clinical series with new pathological insights. *Br J Dermatol* 2012; 167: 575-582.
- [4] Ertürk-Özdemir E, Özcan D and Seçkin D. Acquired aquagenic syringeal acrokeratoderma: a case series of 10 patients. *Australas J Dermatol* 2015; 56: 43-45.
- [5] Żychowska M, Batycka-Baran A, Szepietowski J and Baran W. Translucent whitish papules on the palms after exposure to the water aquagenic syringeal acrokeratoderma. *Postepy Dermatol Alergol* 2017; 34: 372-374.
- [6] Peña-Romero AG, Toussaint-Caire S, Charli-Joseph Y, Dela Barreda-Becerril F and Domínguez-Cherit J. From classical to unusual: report on 5 cases of transient reactive aquagenic pseudokeratoderma and review of the literature. *Am J Dermatopathol* 2017; 39: 935-942.
- [7] Houle MC, Al Dhaybi R and Benohanian A. Unilateral aquagenic keratoderma treated with botulinum toxin A. *J Dermatol Case Rep* 2010; 4: 1-5.
- [8] Sezer E, Erkek E, Duman D, Sahin S and Cetin E. Dermatoscopy as an adjunctive diagnostic tool in aquagenic syringeal acrokeratoderma. *Dermatology* 2012; 225: 97-9.
- [9] Durmaz EÖ, Sezer E, Şahin S, Ekici ID and Özkan F. Transient reactive papulotranslucent acrokeratoderma: a report of 3 cases showing excellent response to topical calcipotriene. *Cutis* 2015; 96: E13-6.
- [10] Sun Y and Jia H. Two cases of aquagenic acrokeratoderma. *Int J Dermatol Venereol* 2012; 38: 352.
- [11] Liu HX, Li ZL and Xu BL. Aquagenic acrokeratoderma: a case report. *Chin J Lepr Skin Dis* 2015; 31: 43-44.
- [12] Liu C, Tang ZH, Bei H, Ceng HY, Luo WX and Liu PM. A case of aquagenic acrokeratoderma. *Chin J Derm Venereol* 2010; 24: 658-659.
- [13] Luo DQ. Aquagenic acrokeratoderma: a case with family history and unusual involvements of the palms and soles, and the dorsum of fingers and toe. *J Dermatol* 2011; 38: 612-615.
- [14] Diba VC, Cormack GC and Burrows NP. Botulinum toxin is helpful in aquagenic palmoplantar keratoderma. *Br J Dermatol* 2005; 152: 394-395.
- [15] Poletti ED and Muñoz-Sandoval R. Images in clinical medicine. Aquagenic keratoderma. *N Engl J Med* 2014; 371: 952.
- [16] Garayar Cantero M, Delgado Mucientes C and Muñoz Fernández-Lomana C. Use of botulinum toxin in the treatment of aquagenic keratoderma: one case report. *Dermatol Ther* 2018; 31: e12689.
- [17] Chen W and Li BJ. A case of aquagenic acrokeratoderma. *Chin J Derm Venereol* 2010; 24: 656-657.
- [18] Errichetti E and Piccirillo A. Aquagenic keratoderma treated with tap water iontophoresis. *Indian J Dermatol* 2015; 60: 212.
- [19] Sezer E, Durmaz EÖ, Çetin E and Şahin S. Permanent treatment of aquagenic syringeal acrokeratoderma with endoscopic thoracic sympathectomy. *Indian J Dermatol Venereol Leprol* 2015; 81: 648-650.

Aquagenic acrokeratoderma: a case report and review of the literature

- [20] Zhao BA. Chinese clinical dermatology. In: Bian Zhao editor. Jiangsu: Phoenix Science and Technology Press; 2017. pp. 1197-1232.
- [21] Saray Y and Seckin D. Familial aquagenic acrokeratoderma: case reports and review of the literature. *Int J Dermatol* 2005; 44: 906-909.
- [22] Zhao F and Su DB. Two cases of aquagenic acrokeratoderma. *Chin J Derm Venereol* 2013; 27: 1149-1150.
- [23] D'Erme AM, Braggion C, de Martino M and Greco A. Aquagenic palmoplantar keratoderma: a sign of cystic fibrosis early in life. *Int J Dermatol* 2014; 53: e536-8.
- [24] Cemil BC, Gonul M, Gokce A and Bilen G. Aquagenic syringeal acrokeratoderma: report of a case with dermoscopic findings. *Indian J Dermatol* 2018; 63: 359-360.