

Acute transverse myelitis following vaccination against H1N1 influenza: a case report

Li Gui, Kangning Chen, Yinqi Zhang

Department of Neurology, Southwest Hospital, Third Military Medical University, Chongqing 400038, China.

Received March 1 2011; accepted March 18, 2011; Epub March 22, 2011; published March 31, 2011

Abstract: H1N1 vaccination is currently safe, and only rare acceptable side-effects have been reported. Here we describe for the first time a serious adverse event, i.e., acute transverse myelitis, following H1N1 vaccination in China. After the standard treatment with methylprednisolone, the patient recovered completely.

Keywords: H1N1, influenza, vaccination, side-effects, transverse myelitis

Introduction

In the control of H1N1 influenza campaign, immunization with different kinds of H1N1 influenza vaccines is being carried out in China as well as in other countries [1]. These vaccines are relatively safe. Some reactions include soreness, redness, irritation or swelling at the injection site; low-grade fever; and muscle aches in adults after receiving the trivalent inactivated influenza vaccine flu shot. In children after receiving the attenuated live vaccine nasal spray, side effects may include running nose, sneezing, headache, vomiting, muscle aches and fever. Serious side effects are extremely rare, such as anaphylactic reaction or Guillain-Barre syndrome. Herein we present a patient who developed transverse myelitis on the 6th day after vaccination.

Case report and discussion

The patient was a 13-year-old student from Guizhou province. On February 2, 2010, he was inoculated with one dose of vaccine (split-virion formulation, containing 15 µg haemagglutinin) against H1N1 influenza. He was on vacation at home during that period without history of accident, taking any medicine or catching cold. Five days after the vaccination (February 7, 2010), he started feeling unwell and weakness of left leg. Gradually he developed motor and sensory impairment in both lower extremities and could not raise the arms, which evolved over 1 week,

and finally resulted in flaccid paraplegia with retention of urine, fecal incontinence, and loss of sensation below T4 dermatomal level. Other systems were completely normal. On investigation the patient's blood, urine and stool did not show any abnormality. Cerebrospinal fluid pressure was normal, in which there were 28 mg/100 ml of proteins (normal range: 8~43 mg/100 ml) and 10 white blood cells/ml (normal range: 0~4 white blood cells/ml). MRI of brain, visual evoked potential (VEP), brainstem auditory evoked potential (BAEP), chest X-ray and ECG were normal. But somatosensory evoked potential (SEP) could not be evoked from L4 to T6. MRI revealed diffuse abnormal signals of the spinal cord between the cervical (at C4/5 level) and the thoracic cords (at T6 level) (**Figure 1**). He was therefore diagnosed as having acute transverse myelitis.

Steroid pulse therapy with methylprednisolone (15mg/kg) was started from the first day of admission and lasted for 5 days, followed by a tailing course of corticosteroids, physical therapy and acupuncture. One month later, MRI was performed, the abnormal signals was decreased obviously (**Figure 2**). After 6 months, the neurologic deficit improved, and the patient could walk without help.

All the members of the family (4 persons) were vaccinated similarly on the same day with the same vaccine. Many persons in the village were also vaccinated, but none of the others devel-

SAE of H1N1 vaccination

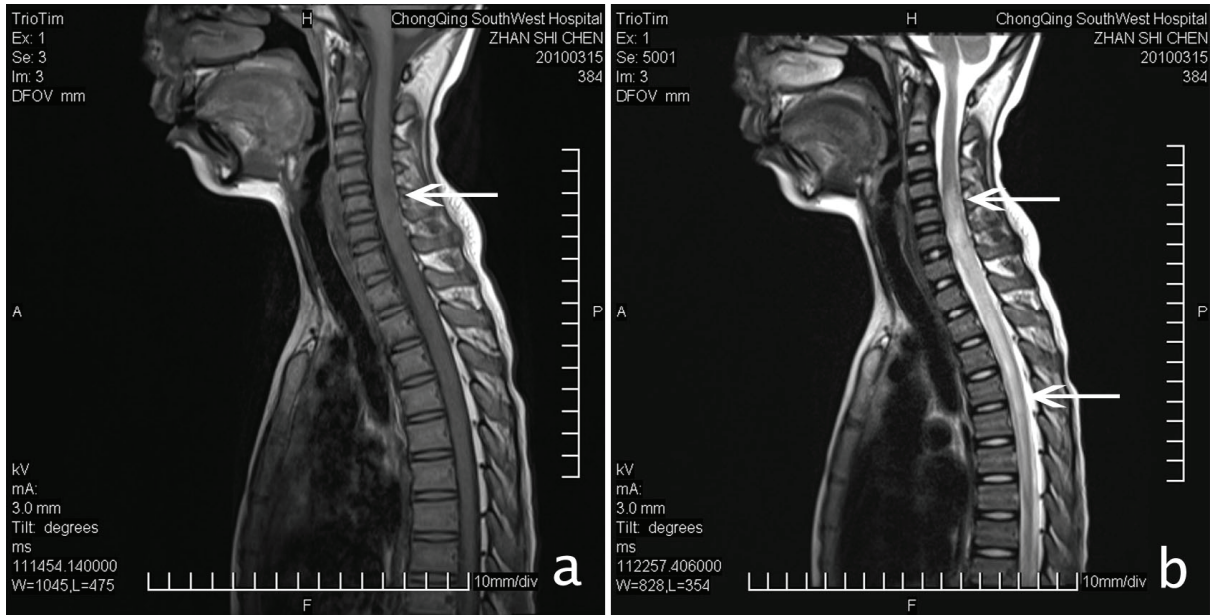


Figure 1. MRI was performed in the acute stage. (a) T1-weighted image showing diffuse swelling in cervical and thoracic cords (as indicated by arrow); (b) T2-weighted image revealing hyperintensity in the spinal cord from C4 to T6 (as indicated by arrows).

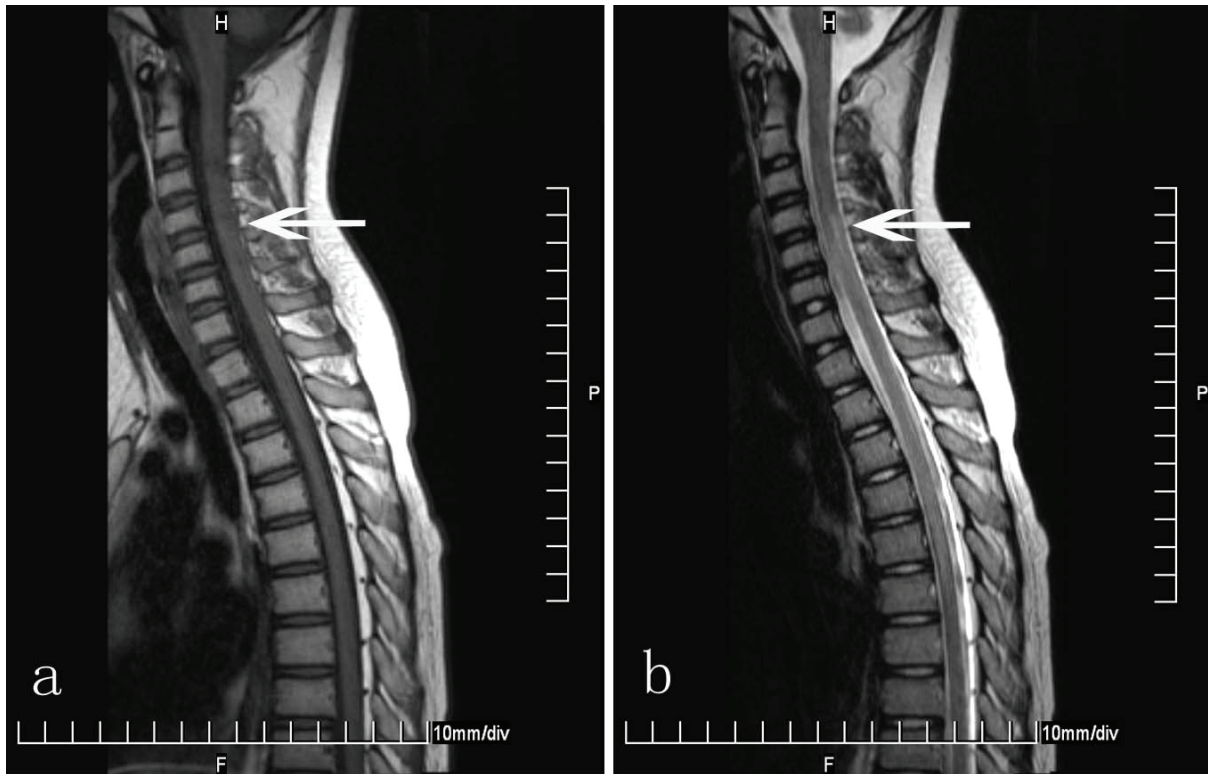


Figure 2. Repeat MRI was performed 1 month later after steroid therapy. (a) T1-weighted image showing a marked decrease in swelling of the cervical and thoracic cords (as indicated by arrows); (b) T2-weighted image revealing a decrease of the signal intensity in the spinal cord from C4 to T6 (as indicated by arrows).

oped transverse myelitis.

Transverse myelitis has been reported previously to occur after vaccination [2]. However, there is no report of transverse myelitis occurring after immunization with H1N1 influenza vaccine [1, 3-5]. We thought it worthwhile to present this case and raise the concern to the potential severe adverse events although it is very difficult to confirm or exclude the possible relevance between the vaccination and occurrence of the myelitis since idiopathic myelitis and a number of other common diseases of children may occur coincidentally after vaccinations.

Please correspondence to: Dr. Kangning Chen, Department of Neurology, Southwest Hospital, Third Military Medical University, Chongqing, China. E-mail: ckn_640827@126.com

References

- [1] Zhu FC, Wang H, Fang HH, Yang JG, Lin XJ, Liang XF, Zhang XF, Pan HX, Meng FY, Hu YM, Liu WD, Li CG, Li W, Zhang X, Hu JM, Peng WB, Yang BP, Xi P, Wang HQ and Zheng JS. A novel influenza A (H1N1) vaccine in various age groups. *N Engl J Med* 2009; 361: 2414-2423.
- [2] Holt S HD, Krishnan KR, Critchley EMR. A novel influenza A (H1N1)vaccine in various age groups. *Brit Med J* 1976; 2: 1037-1038.
- [3] Liang XF, Wang HQ, Wang JZ, Fang HH, Wu J, Zhu FC, Li RC, Xia SL, Zhao YL, Li FJ, Yan SH, Yin WD, An K, Feng DJ, Cui XL, Qi FC, Ju CJ, Zhang YH, Guo ZJ, Chen PY, Chen Z, Yan KM and Wang Y. Safety and immunogenicity of 2009 pandemic influenza A H1N1 vaccines in China: a multicentre, double-blind, randomised, placebo-controlled trial. *Lancet* 375: 56-66.
- [4] Greenberg ME, Lai MH, Hartel GF, Wichems CH, Gittleson C, Bennet J, Dawson G, Hu W, Leggio C, Washington D and Basser RL. Response to a monovalent 2009 influenza A (H1N1) vaccine. *N Engl J Med* 2009; 361: 2405-2413.
- [5] Chowell G BS, Colchero MA, Lopez-Gatell H, Alpuche-Aranda C, Hernandez M, Miller MA. Severe respiratory disease concurrent with the circulation of H1N1 influenza. *New Engl J Med* 2010; 361: 674-679.