

Brief Communication

No evidence of endometriosis within serous and mucinous tumors of the ovary

Tadashi Terada

Department of Pathology, Shizuoka City Shimizu Hospital, Shizuoka, Japan

Received November 25, 2011; accepted January 31, 2012; Epub February 12, 2012; Published February 28, 2012

Abstract: Ovarian endometriosis can transform into malignant tumors. The author retrospectively examined HE slides of 112 serous tumors and 75 mucinous tumors for the existence of ovarian endometriosis. When endometriosis is present within the tumors, the term “endometriosis-derived tumor” was applied. When endometriosis is recognized adjacent to the tumor, the term “endometriosis-associated tumor” was used. Of the 112 serous tumors (46 benign, 18 borderline, and 50 malignant), 4 (3.5%) (2 benign and 2 malignant) were endometriosis-associated tumors. None was endometriosis-derived tumor. Of the 75 mucinous tumors (30 benign, 26 borderline, and 19 malignant), 4 (5%) (1 borderline and 3 benign) were endometriosis-associated tumors. No tumors showed endometriosis-derived tumors. The data suggest that endometriosis does not transform into serous and mucous tumors. The author felt the limitation of retrospective survey, because the limited numbers of slides (5 to 15) were obtained from each tumor. The author also felt that endometriosis can be difficult to discern because of degenerative changes and other similar lesions such as fallopian tube, fimbria, inclusion cysts, rete ovarii, paraovarian cyst, and Müllerian ducts remnants. Prospective study using whole ovarian examination is required.

Keywords: Ovary tumor, endometriosis, ovary serous tumor, ovary mucinous tumor, endometriosis-derived tumor

Introduction

It is well recognized that malignant transformation can occur in ovarian endometriosis [1, 2]. Nishida et al [2] reported that 18 cases of atypical endometriosis and one case of ovarian carcinoma were recognized in the 147 cases of the ovarian endometriosis; thus the incidence of malignancy in ovarian endometriosis is 0.7%. Kontoravdis et al [3] reported that there were 13 (2%) cases of ovarian malignancy among 667 cases of endometriosis. Two of the most common malignant tumors of such a situation were clear cell adenocarcinoma and endometrioid adenocarcinoma [3]. Stern et al [4] reported that ovarian malignancies were associated with endometriosis in 3.2 - 10% of cases, and these percentages varied among observers.

The histologically types of endometriosis-associated malignancy were mostly clear cell adenocarcinoma and endometrioid adenocarcinoma, and serous and mucous tumors are infrequently associated with endometriosis [4-9].

Yoshikawa et al [4] reported that malignancies in endometriosis are clear cell (39.2%), endometrioid (21.2%), serous (3.3%), and mucinous type (3.0%). Vercelli et al [10] reported that among the endometriosis-associated malignant, serous tumor accounted for 3.6%, mucinous tumor 5.6%, endometrioid tumor 26.3%, clear cell tumor 21%, and mixed tumor 22%.

The author reviewed 187 serous and mucinous tumors for the existence of endometriosis.

Materials and methods

The author reviewed HE-slides (1 - 11 slides) of 112 cases of serous tumors and 75 cases of mucinous tumors of the ovary in the last 12 years of our pathology laboratory for the presence of endometriosis. Mixed tumors were present in 11 cases, and they were labeled as serous, mucinous, or other tumors depending on the majority histology. In the present study, when endometriosis was present within the tumors, the term “endometriosis-derived tumor”

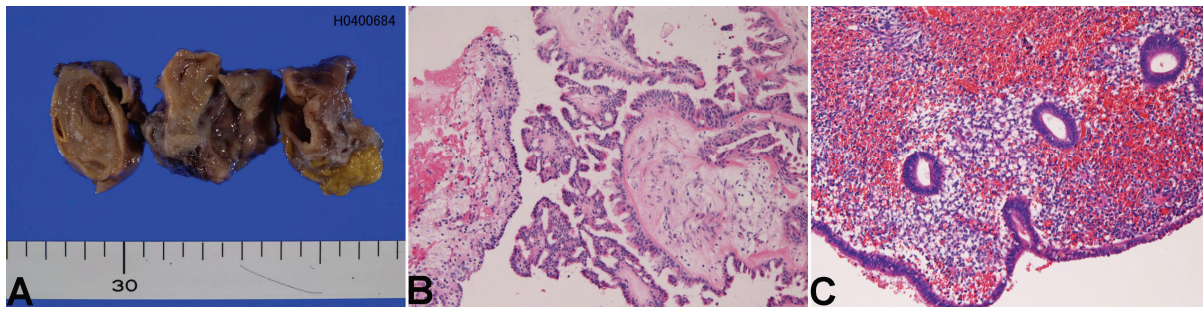


Figure 1. A case of endometriosis-associated serous papillary adenocarcinoma. A. Macroscopic features. The carcinoma element was not obvious because it was examined by frozen sections. B. The serous adenocarcinoma element. HE, $\times 100$. C. Endometriosis was present in the vicinity of the serous adenocarcinoma. HE, $\times 100$.

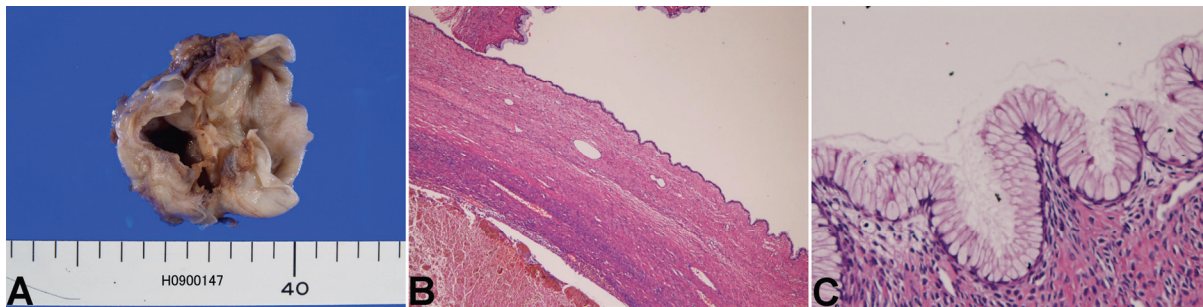


Figure 2. A case of endometriosis-associated mucinous cystadenoma. A. macroscopic features. B. The endometriosis (chocolate cyst) (lower) is seen in the vicinity of the mucinous cystadenoma (upper). HE, $\times 40$. C. The mucinous cystadenoma area. HE, $\times 100$.

was applied. When endometriosis was recognized adjacent to the tumor, the term “endometriosis-associated tumor” was used.

Results

Of the 112 serous tumors, 46 were benign, 18 were borderline, and 50 were malignant. Of the 112 cases, 4 cases (3.5%) (2 benign and 2 malignant) were endometriosis-associated tumors (**Figure 1**). None was endometriosis-derived tumor. Of the 75 mucinous tumors, 30 were benign, 26 were borderline, and 19 were malignant, 4 cases (5%) (1 borderline and 3 benign) were endometriosis associated tumors (**Figure 2**). None was endometriosis-derived tumor.

That is, there were 8 cases of tumors with endometriosis adjacent to the tumors. However, there were no cases in which endometriosis was present within the tumors. Of course, there were no merges between tumor epithelium and endometriosis epithelium.

Discussion

In the present study, the authors identified no cases of endometriosis-derived serous and mucous tumors in the 187 cases. This strongly suggests that endometriosis does not transform into serous and mucous tumors of the ovary. In the present study, there were 4 cases of endometriosis-associated tumors. However, in these tumors, the tumors and endometriosis were located separately, and there were no merges between endometriosis epithelium and tumor epithelium. This suggests that the endometriosis-associated tumors were simply coincidental.

Previous studies on the frequency of endometriosis in serous and mucous tumor in about 5% [4, 10, 11]. However, the previous studies have not demonstrated the direct transition between endometriosis epithelium and tumor epithelium.

During the review, the author felt that endometriosis is difficult to diagnose. Endometriosis is

defined as heterotopic presence of endometrium (endometrial epithelium and endometrial stroma). However, these endometrial elements are frequently desquamated, resulting in the so-called "chocolate cysts". In addition, the endometrial stroma is occasionally absent in endometriosis. The presence of tall columnar epithelium without endometrial stroma is recognized in serous tumors, mucous tumors, and other tumors, as well as in endosalpingiosis, rete ovarii, fimbria, paraovarian cyst, inclusion cyst, and Müllerian duct remnants. In the present study, the endometriosis-like tall columnar epithelium without endometrial stroma was recognized in several cases, but these cases cannot be labeled as endometriosis. The cilia of fallopian tube associated cysts do not exclude endometriosis because endometriosis may show ciliated metaplasia [12]. In any way, the criteria of endometriosis in so-called endometriosis-associated ovarian tumors are not unified. It is mandatory that the presence of endometrial epithelium and endometrial stroma is essential for the diagnosis of endometriosis.

Address correspondence to: Dr. Tadashi Terada, Department of Pathology, Shizuoka City Shimizu Hospital, Miyakami 1231 Shimizu-Ku, Shizuoka 424-8636, Japan Tel: 81-54-336-1111; Fax: 81-54-336-1315; E-mail: piyo0111jp@yahoo.co.jp

References

- [1] Scully RE, Richardson GS, Barlow JF. The development of malignancy in endometriosis. *Clin Obstet Gynecol* 1966; 9: 384-411.
- [2] Nishida M, Watanabe K, Sato N, Ichikawa Y. Malignant transformation of ovarian endometriosis. *Gynecol Obstet Invest* 2000; 50: 18-25.
- [3] Kontoravdis A, Augoulea A, Lambrinouadaki I, Christodoulakos G, Tzorziotis D, Grammatikakis I, Kontravdis N, Crestsas G. Ovarian endometriosis associated with ovarian cancer and endometrial-endocervical polyps. *J Obstet Gynecol Res* 2007; 33: 294-298.
- [4] Stern RC, Dash R, Bentley RC, Snyder MJ, Haney AF, Robboy SJ. Malignancy in endometriosis: frequency and comparison of ovarian and extraovarian types. *Int J Gynecol Pathol* 2001; 20: 133-139.
- [5] Yoshikawa H, Jimbo H, Okada S, Matsumoto K, Onda T, Yasugi T, Taketani Y. Prevalence of endometriosis in ovarian cancer. *Gynecol Obstet Invest* 2000; 50: 11-17.
- [6] Valezuela P, Ramos P, Redondo S, Cabrera Y, Alvarez I, Ruiz A. Endometrioid adenocarcinoma of the ovary and endometriosis. *Eur J Obstet Gynecol Reprod Biol* 2007; 134: 83-86.
- [7] DePriest PD, Banks ER, Powell DE, van Nagell JR, Gallion HH, Puls LE, Hunter JE, Kryscio RJ, Royalty MB. Endometrioid adenocarcinoma of the ovary and endometriosis: the association in postmenopausal women. *Gynecol Oncol* 1992; 47: 71-75.
- [8] Sainz de la Cuesta R, Eichhorn JH, Rice LW, Fuller AF, Nikrui N, Goff BA. Histological transformation of benign endometriosis to early epithelial ovarian cancer. *Gynecol Oncol* 1996; 60: 238-244.
- [9] Ogawa S, Kaku T, Amada S, Kobayashi H, Hirakawa T, Ariyoshi K, Kamura T, Nakano H. Ovarian endometriosis associated with ovarian carcinoma: a clinicopathologic and immunohistochemical study. *Gynecol Oncol* 2000; 77: 298-304.
- [10] Vercellini P, Parazzini F, Bolis G, Carinell S, Dindelli M, Vendola N, Luchini L, Crosignani PG. Endometriosis and ovarian cancer. *Am J Obstet Gynecol* 1993; 169: 181-182.
- [11] Jimbo H, Yoshikawa H, Onda T, Yasugi T, Sakamoto A, Taketani Y. Prevalence of ovarian endometriosis in epithelial ovarian cancer. *Int J Gynecol Pathol* 1997; 59: 245-25.
- [12] Fukunaga M, Ushigome S. Epithelial metaplastic changes in ovarian endometriosis. *Mod Pathol* 1998; 11: 784-788.