

Case Report

Solitary plasmacytoma of the bone involving young individuals, is there a role for preceding trauma?

Whitney Pasch, Xiaohui Zhao, Sherif A Rezk

Department of Pathology and Laboratory Medicine, University of California, Irvine (UCI), Irvine, CA, USA

Received April 9, 2012; accepted May 13, 2012; Epub May 23, 2012; Published June 30, 2012

Abstract: Solitary plasmacytoma of the bone (SPB) is a rare plasma cell neoplasm that usually presents as a lytic lesion mainly localized within the axial skeleton. The occurrence of SPB in young individuals is exceedingly rare but has been sporadically reported before. We report a case of SPB involving a 21 year-old male with a prior history of trauma at the same site. We also reviewed all previous cases of SPB in young individuals that were accessible to us to investigate the incidence of prior trauma in such cases and to investigate a potential role that trauma may play in the pathogenesis of such lesions.

Keywords: Solitary plasmacytoma of the bone (SPB), young individuals, trauma

Introduction

Plasmacytomas are localized neoplasms accounting for about 5-10% of all plasma cell dyscrasias and are characterized by clonal proliferation of plasma cells that display a range of morphologic features ranging from bland and mature to anaplastic forms [1, 2]. They are not associated with anemia, hypercalcemia, renal failure, or bone marrow involvement, features that are usually seen in overt myelomas [2]. They can present as osseous plasmacytomas (solitary plasmacytoma of bone) or as extraosseous plasmacytomas (extramedullary) with a lower risk of progression into myeloma in the extraosseous constituent lesions [2]. The axial skeleton is most common location for the osseous lesions, while the upper respiratory tract is the most common location for extramedullary lesions [2]. The male to female ratio is 2:1 and the median age at presentation is 55 years, which is approximately ten years younger than patients presenting with multiple myeloma [3, 4]. Few cases of plasmacytoma affecting young individuals have been reported before, most of which represent solitary plasmacytoma of bone [1, 5-7]. We report a case of a 21 year old male with a solitary bone plasmacytoma of the right iliac crest with a preceding history of trauma. In addition, we have reviewed all accessible cases

of solitary plasmacytoma of bone in young individuals reported in the literature to investigate a potential role that a preceding trauma may play in the pathogenesis of this disease.

Case report

A twenty-one year old male sustained a fall at work in December 2007. He presented afterwards to an outside institute with persistent back pain. A subsequent X-ray of the lumbar spine and pelvis was performed at the time and revealed a lytic lesion in the right iliac crest. The patient then presented at our facility for further work-up, which consisted of a CT scan, a whole body bone scan, and biopsy of the lytic lesion. The CT scan again identified the lytic lesion in the right iliac crest and also demonstrated soft tissue involvement, while the whole body scan was negative for any other lesions. The iliac crest biopsy revealed sheets of lambda-restricted CD138 positive plasma cells (**Figure 1**). The plasma cells showed plasma expression of IgA by immunohistochemistry but were negative for IgG, IgM, bcl-2, and all the B-cell markers. The neoplastic plasma cells did not exhibit any atypical features and bone marrow involvement was not seen. Per the providing physician, serum protein electrophoresis testing was performed at the outside institute and showed no presence

Solitary plasmacytomas in young individuals

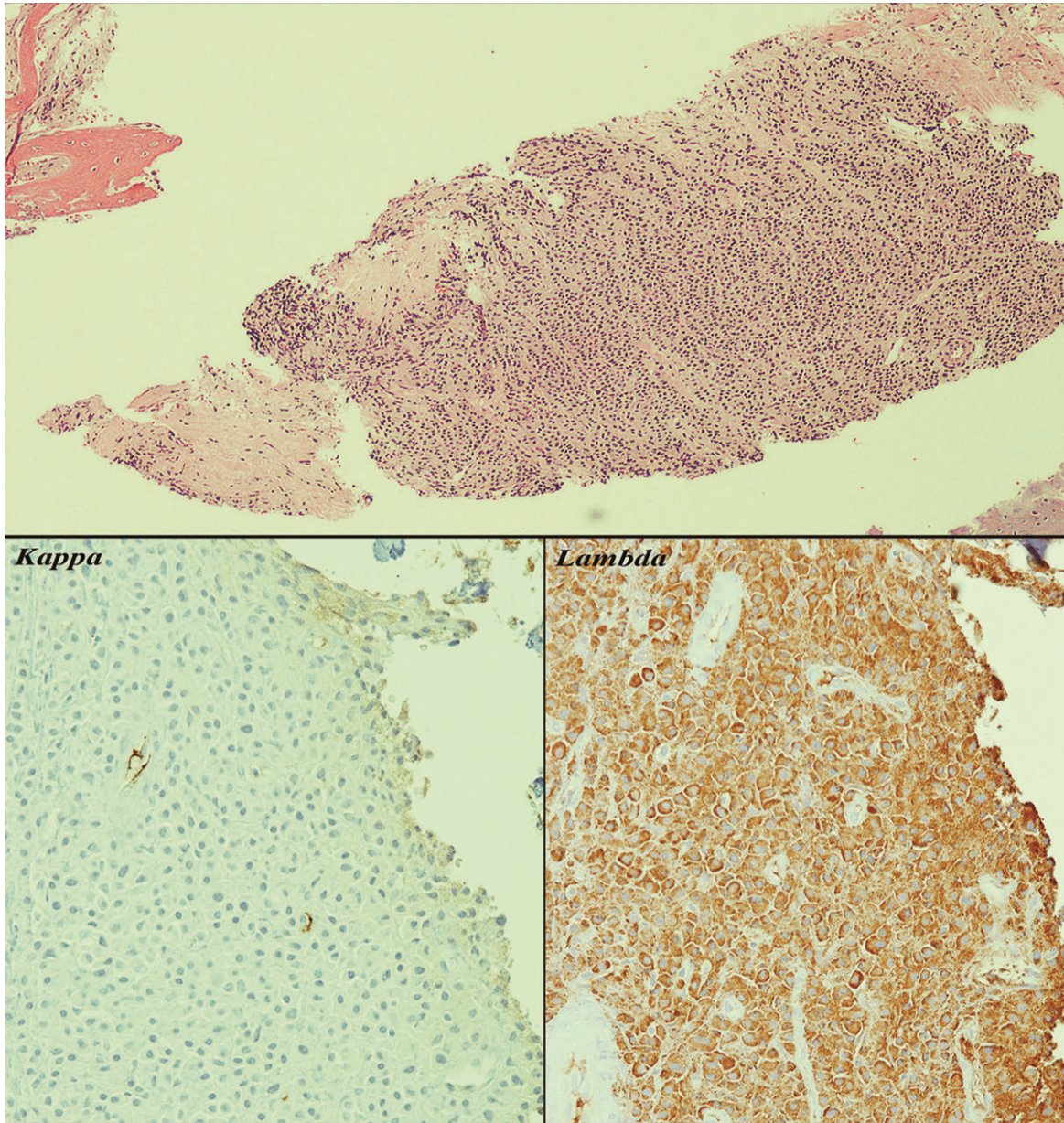


Figure 1. The composite picture shows a diffuse monotonous infiltrate of plasma cells involving the soft tissue (upper half 40X). A piece of uninvolved cortical bone and cartilage are also seen in the picture. The plasma cells clearly demonstrate Lambda restriction by immunohistochemistry (lower half 400X).

of paraproteins although the test reports could not be obtained. Cytogenetic testing was not performed at the time but a fluorescent in situ hybridization (FISH) myeloma panel testing was performed and no abnormal signals were detected. Hypercalcemia and renal failure were not present. The patient was treated at an outpatient radiation center with 50Gy for 4 weeks. Follow-up after that period was not available

despite several attempts from our part to track down the patient.

Discussion

Solitary plasmacytoma of the bone (SPB) is a rare plasma cell neoplasm that most commonly presents as an expansile lytic mass mainly localized within the axial skeleton [3]. Manage-

Solitary plasmacytomas in young individuals

Table 1. Review of published reports with SPB involving young individuals.

Cases	Age	Sex	Trauma	Light chain	Heavy chain*	Location	Lytic bone lesions	Comments
Ishida <i>et al</i> 1 st case, 1995	23	F	No	Lambda	IgG (IHC)	Vertex of head	Yes	Marrow was involved minimally later on
Ishida <i>et al</i> 2 nd case, 1995	21	M	Yes	Lambda	- (IHC)	Tibia,	Yes	
Bertoni-Salateo <i>et al</i> 1998	17	F	No	Kappa	-	Tibia	Yes	osteomyelitis for 3 years prior at same site
Mongknostritragoon <i>et al</i> 1998	27	M	Yes	Lambda	Tiny IgG (IFE)	Tibia	Yes	Electric injury 12 years prior, progressed to myeloma
Boos <i>et al</i> 1997	16	F	Yes	Kappa	-	Lumbar spine	Yes	Plasmacytoma after 6 years of fracture due to cycling
George <i>et al</i> 2002	29	M	No	Kappa	IgG (IHC)	Rib	Yes	
Gossios <i>et al</i> 2002	18	M	No	Kappa	-	Thoracic spine	Yes	Pathologic compression fracture after exercise
Panteli <i>et al</i> 2002	18	M	No	-	-	Thoracic spine	Yes	Fracture in the thoracic spine for 2 months
Hussein <i>et al</i> 2003	28	M	Yes	Kappa	IgG (IFE)	Mandible & rib	Yes	8% clonal plasma cells in bone marrow 2 months after trauma
Dumesnil <i>et al</i> 2006	14	F	Yes	Lambda	IgG (IHC)	Lumbar spine	Yes	
Kumar <i>et al</i> 2011	14	F	Yes	Lambda	-	Tibia	Yes	Fall 2 months prior
Rago <i>et al</i> 2011	22	M	Yes	Lambda	IgG (IHC)	Tibia	Yes	
Our Case 2011	21	M	Yes	Lambda	IgA (IHC)	Lumbar spine	Yes	

* IHC= Immunohistochemistry, IFE=Immunofixation

ment of SPB is achieved by local radiotherapy in most cases but up to two thirds of the patients eventually progress into plasma cell myeloma [2]. The occurrence of a SPB in young individuals is exceedingly rare but has been reported previously [1, 4, 8]. The cases of SPB reported in younger patients point to a more indolent course than that seen in older individuals [7]. Given the rarity of reported cases of younger patients with SPB, we have reviewed all such cases that have been previously reported and were accessible to us (12 cases). Our purpose is to investigate any correlation among the reported cases that may give us a possible clue to the pathogenesis of this disorder in younger patients. All the patients in the reviewed cases including our reported case were <30 years old

at presentation and presented with lytic lesions, mostly in the spine (6 cases), while 3 patients had tibial lesions, 2 patients had a rib lesion, and 1 patient had a lesion on the vertex of the head (**Table 1**) [1, 3-7, 9-13]. A slight male predominance was noted. The monoclonal plasma cells in our case were IgA positive by immunohistochemistry and while some authors have postulated that IgA paraprotein is more common to be seen in younger individuals than in older patients with SPB [12], all of the other reported cases reviewed by us were IgG positive, mainly by immunohistochemistry. The most notable feature after reviewing all cases was the presence of a history of trauma in 8 out of the 13 cases in addition to another case with a history of physical exercise leading to pain and

discomfort in the spine. The time from the occurrence of the trauma to the onset and the diagnosis of SPB varied from couple of weeks to 12 years in the reviewed cases.

Normal plasma cell development involves the stimulation of mature naïve B cells by antigen resulting in further proliferation, heavy chain class switching, and differentiation into memory B cells or plasma cells [14]. The interaction between the stromal cells and plasma cells in addition to cytokine production and osteoclast activation play an important role in plasma cell survival [11]. Trauma can cause enhanced release of cytokine resulting in increased proliferation of plasma cells and stromal cells in the bone [11]. A mouse model study performed by Rutsch *et al.* concluded that concomitant expression of *myc* and deregulated IL-6 led to a more rapid plasmacytoma occurrence [15]. This study further found Bcl-2, which encodes Bcl-x as a transcriptional target of IL-6, to be increased in quantity in the presence of plasmacytoma [15]. Given that IL-6 is a well known inflammatory cytokine that promotes B-cell proliferation occurring during bone marrow stimulation, the authors postulated that this creates a “feed-forward cytokine amplification loop” in which the tumor environment becomes ideal for plasma cell neoplasm progression [15]. Trauma of any sort can trigger injured cells to secrete these inflammatory cytokines, which can sometimes lead to plasmacytoma development. Zendri *et al* have reported a case of a primary cutaneous plasmacytoma of the lower lip in a patient who had recurrent Herpes Simplex virus infections that were proposed as trauma trigger [16]. The authors have also listed 6 other patients with previous trauma (triggered by viral infection, insect bite, or pathogen-related) that developed a primary cutaneous plasmacytoma [16]. The authors concluded that chronic stimulation of the toll-like receptors on the keratinocytes can lead to transcription of genes involved in skin inflammation, specifically IL-6, which in turn can potentially induce malignant B-cell and plasma cell proliferation and Bcl-2 expression [16]. Though the study consisted of different target populations and included all types of plasmacytomas, the article further validates the potential role that trauma can play by triggering the development of this lesion.

Although one can argue that the presence of trauma may represent a circumstantial coinci-

dence with SBP but given the rarity of such lesions in younger individuals and the identification of a preceding trauma or chronic stimulation in a considerable number of the reported cases, we speculate that trauma may play a role in the pathogenesis of such lesions and may act as the triggering stimulus for plasma cells to proliferate and eventually lead to a clonal infiltrate. Further studies are needed to confirm such a hypothesis.

Address correspondence to: Dr. Sherif A Rezk, Department of Pathology, University of California Irvine Medical center (UCI), 101 The City Drive, Bldg 54, Rm 4702, Orange, CA 92868 Tel: (714) 456-5009; Fax: (714) 456- 2394; E-mail: srezk@uci.edu

References

- [1] Dumesnil C, Schneider P, Dolgoplov I, Radi S, Leluyer B and Vannier JP. Solitary bone plasmacytoma of the spine in an adolescent. *Pediatr Blood Cancer* 2006; 47: 335-338.
- [2] McKenna RW, Kuehl WM, Grogan TM, Harris NL, Coupland RW. Plasma cell neoplasms. In: Swerdlow SH, Harris NL, Jaffe ES, Pileri SA, Stein H, Thiele J, Vardiman JW, editors. *WHO Classification of Tumors of Hematopoietic and Lymphoid Tissues*. Lyon: IARC; 2008.
- [3] Kumar P, Sharma SC, Saikia UN, Kumar N, Vyas S and Angurana SL. Solitary plasmacytoma of the proximal tibia in an adolescent. *Pediatr Blood Cancer* 2011; 56: 158-160.
- [4] Gossios K, Argyropoulou M, Stefanaki S, Fotopoulos A and Chrisovitsinos J. Solitary plasmacytoma of the spine in an adolescent: a case report. *Pediatr Radiol* 2002; 32: 366-369.
- [5] Bertoni-Salateo R, de Camargo B, Soares F, Chojniak R and Penna V. Solitary plasmacytoma of bone in an adolescent. *J Pediatr Hematol Oncol* 1998; 20: 574-576.
- [6] Panteli K, Tsiara S and Bourantas KL. Solitary bone plasmacytoma in a young patient. *J Exp Clin Cancer Res* 2002; 21: 139-141.
- [7] Rago A, Miraglia A, Mecarocci S, Pisanelli GC, Chiappetta C, Di Cristofano C, Scarchilli A, Cenfra N, Petrozza V and Cimino G. Solitary plasmacytoma of tibia: a possible correlation with younger age. *Leuk Res* 2010; 34: e181-182.
- [8] Wong CL and Mansberg R. Solitary plasmacytoma of bone: an unusual cause of severe sacral pain in a young man. *Clin Nucl Med* 2005; 30: 612-614.
- [9] Boos N, Goytan M, Fraser R and Aebi M. Solitary plasma-cell myeloma of the spine in an adolescent. Case report of an unusual presentation. *J Bone Joint Surg Br* 1997; 79: 812-814.
- [10] George SM, Ratnakar KS, Shome DK, Nair R and Al Ajmi A. Plasmacytoma of the rib in young male. *Asian Cardiovasc Thorac Ann* 2002; 10:

Solitary plasmacytomas in young individuals

- 282-284.
- [11] Hussein MA, George R, Rybicki L and Karam MA. Skeletal trauma preceding the development of plasma cell dyscrasia: eight case reports and review of the literature. *Med Oncol* 2003; 20: 349-354.
- [12] Ishida T and Dorfman HD. Plasma cell myeloma in unusually young patients: a report of two cases and review of the literature. *Skeletal Radiol* 1995; 24: 47-51.
- [13] Mongkonsritragoon W, Kyle RA, Shreck RR and Greipp PR. Primary plasmacytoma at the site of exit wounds after electrical injury. *Am J Hematol* 1998; 58: 77-79.
- [14] Rezk SA and Weiss LM. Epstein-Barr virus-associated lymphoproliferative disorders. *Hum Pathol* 2007; 38: 1293-1304.
- [15] Rutsch S, Neppalli VT, Shin DM, DuBois W, Morse HC, 3rd, Goldschmidt H and Janz S. IL-6 and MYC collaborate in plasma cell tumor formation in mice. *Blood* 2010; 115: 1746-1754.
- [16] Zendri E, Venturi C, Ricci R, Giordano G and De Panfilis G. Primary cutaneous plasmacytoma: a role for a triggering stimulus? *Clin Exp Dermatol* 2005; 30: 229-231.