

Letter to Editor

Extramuscular subcutaneous fibrolipoma containing foci of striated muscle cells: a hitherto unreported condition

Tadashi Terada

Departments of Pathology, Shizuoka City Shimizu Hospital, Shizuoka, Japan

Received September 21, 2012; Accepted October 30, 2012; Epub November 20, 2012; Published January 1, 2013

Lipoma of the cutaneous region is very common tumor. Most of cutaneous lipoma arises in the subcutaneous adipose tissue. When the tumor is composed exclusively mature lipocytes, the tumor is referred to as lipoma. When the tumor contains areas of capillary, it is called angiolipoma. When the tumor has rich fibrous tissue, it is called fibrolipoma. When the tumor consisted of spindle cells, it is called spindle cell lipoma. When the tumor is located in the striated muscles, it is called intramuscular lipoma. When the tumor contains areas of lipoblasts, it is called atypical lipomatous tumor (well differentiated liposarcoma). Lipoma containing striated muscle cells has not been reported. Herein reported is an extremely rare case of fibrolipoma containing areas of striated muscle cells.

A 68-year-old man consulted our hospital because of soft tumor in the face. Dermatologists' diagnosis was lipoma, and excision of lipoma was performed. During the excision, the tumor (2 x 1.5 x 1.5 cm) was located in the subcutaneous fat tissue, and no manipulation of fascia and striated muscles was performed. Histologically, the tumor was located in the subcutaneous tissue (**Figure 1A**), and no fascia or striated muscles were seen (**Figure 1**). The tumor is composed of mature fat tissue (80%), fibrous tissue (15%), and striated muscle cells (5%) (**Figure 1B**). There was gradual merge among the three components (**Figure 1C** and **1D**). The fat tissue is free from lipoblasts. The fibrous tissue consisted mesh-like collagen fibers. The striated muscle cells

show basophilia and cross striation. An immunohistochemical study was performed with the use of Dako Envision method, as previously reported [1, 2]. The fat tissue was positive for S100 protein and vimentin, but negative for cytokeratin (CK) AE1/3, CK CAM5.2, MDM2, CDK4, smooth muscle actin, desmin, myoglobin, and p53. The fibrous tissue was positive for vimentin, but negative for S100 protein, CK AE1/3, CK CAM5.2, MDM2, CDK4, smooth muscle actin, desmin, myoglobin, and p53. The striated muscles were positive for myoglobin (**Figure 2A**), but negative for negative for vimentin, S100 protein, CK AE1/3, CK CAM5.2, MDM2, CDK4, smooth muscle actin, desmin, and p53. Ki-67 labeling was 0.8% in fat tissue element, 0.6% in fibrous tissue element, and 0.4% in striated muscle cells element (**Figure 2B**). A pathological diagnosis of subcutaneous fibrolipoma containing islands of striated muscle cells was made. The patient is now free from tumor 3 months after the operation.

In the present case, it is very strange that the lipomatous tumor contained islands of striated muscle cells. The "striated muscle cells" are true striated muscle cells with regard to the histology and expression of myoglobin. Such a case has not been reported in the literature. The present case was diagnosed as fibrolipoma because significant amount of fibrous tissue was seen. The present tumor is not atypical lipomatous tumor because no lipoblasts were seen, and also because negative immun-expression of CDK4 and MDM2. The very low Ki-67 labeling in the current case indicates that

Lipoma containing striated muscle cells

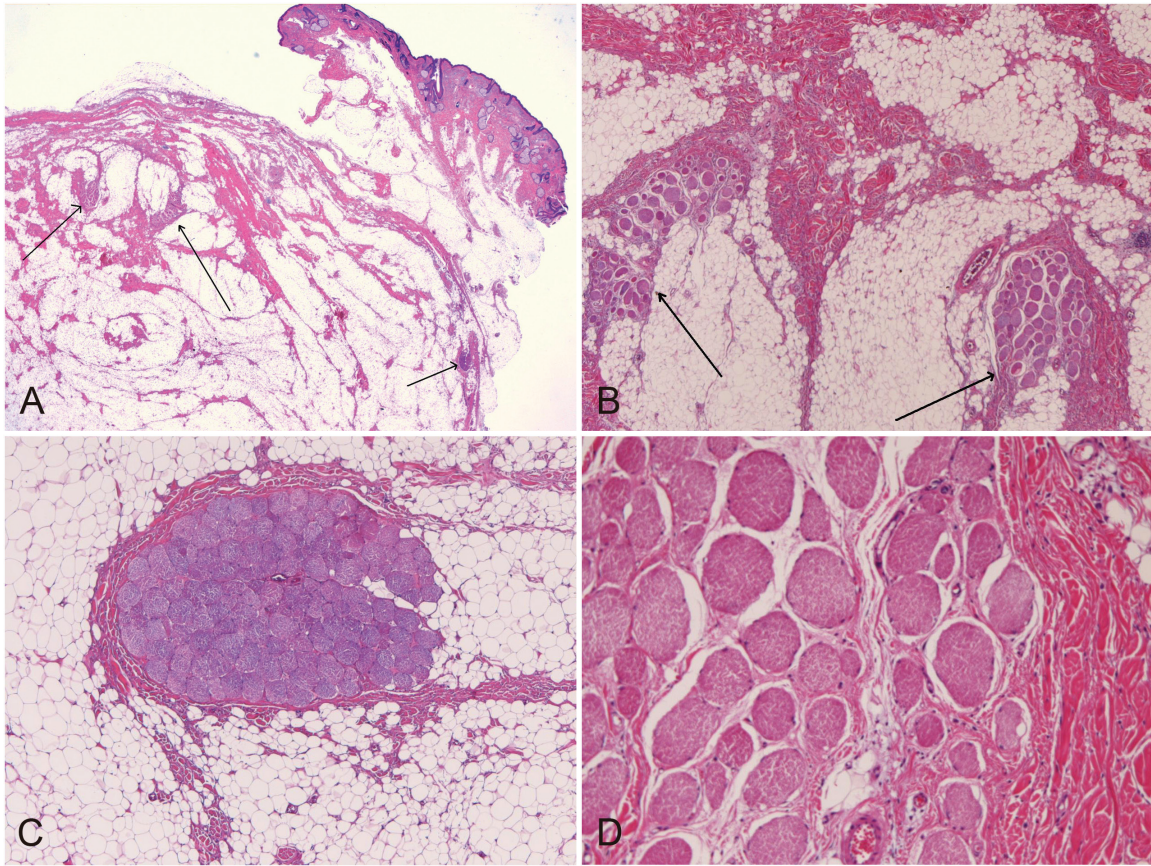


Figure 1. A, B: Very low power view of the tumor. The tumor is located in the subcutaneous tissue and does not involve fascia or striated muscle. The tumor is composed of mature fat tissue, fibrous tissue, and striated muscle cells (arrows). A: HE, X5. B: HE, x30. The striated muscle cells are continuous of fat tissue (C) and fibrous tissue (D). C, D: HE, x100.

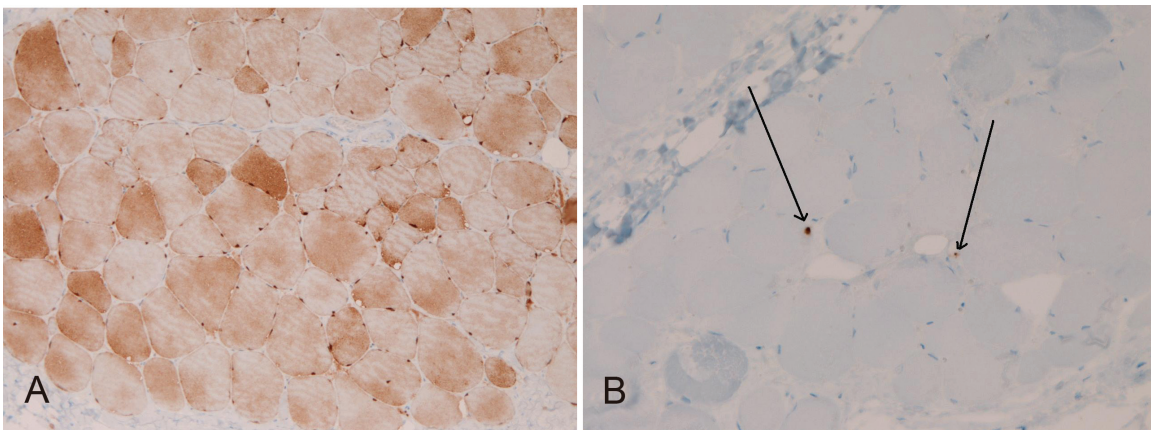


Figure 2. Immunohistochemistry. The striated muscle cells are positive for myoglobin (A), and the Ki-67 labeling are 0.4% (arrows) (B). Immunostaining: A, B: X100.

the tumor has very low proliferative capacity and that the tumor is benign. Negative p53 also

suggests that the tumor is benign. The current tumor is not spindle cell lipoma. The present

tumor is not intramuscular lipoma, because the present tumor is located not in the striate muscle, but in the subcutaneous tissue.

The pathogenesis of the presence of striated muscle cells in the present fibrolipoma is unknown. Five possibilities are considered. The first possibility is that the striated muscle cells are artifact (contamination). This is unlikely because the striated muscle cells are gradually merged with other elements, and also because the operation manipulation did not touch fascia and striated muscles. The second hypothesis is that the fat tissue transdifferentiated into striated muscle cells. This is likely. This hypothesis is supported by the low expression of Ki-67 in the striated muscle cells. The third possibility is that the tumor is monodermal teratoma. This is also likely. The forth possibility is that the tumor is congenital hamartoma. The author thinks that this is most likely. The fifth hypothesis is that stem cells in the fat tissue differentiated into striated muscle cells. This is also likely.

Conflict of interest statement

The author has no conflict of interest.

Address correspondence to: Tadashi Terada, Department of Pathology, Shizuoka City Shimizu Hospital, Miyakami 1231 Shimizu-Ku, Shizuoka 424-8636, Japan. Tel: +81-54-336-1111; Fax: +81-54-334-1173; E-mail: piyo0111jp@yahoo.co.jp

References

- [1] Terada T, Kawaguchi M, Furukawa K, Sekido Y, Osamura Y. Minute mixed ductal-endocrine carcinoma of the pancreas with predominant intraductal growth. *Pathol Int* 2002; 52: 740-746.
- [2] Terada T, Kawaguchi M. Primary clear cell adenocarcinoma of the peritoneum. *Tohoku J Exp Med* 2005; 206: 271-275.