

## Case Report

# Sustained complete remission of a limited-stage blastic plasmacytoid dendritic cell neoplasm followed by a simultaneous combination of low-dose DeVIC therapy and radiation therapy: a case report and review of the literature

Kei-Ji Sugimoto<sup>1</sup>, Asami Shimada<sup>1</sup>, Nanae Yamaguchi<sup>1</sup>, Hidenori Imai<sup>1</sup>, Mutsumi Wakabayashi<sup>1</sup>, Yasunobu Sekiguchi<sup>1</sup>, Hiroshi Izumi<sup>3</sup>, Yasunori Ota<sup>4</sup>, Norio Komatsu<sup>2</sup>, Masaaki Noguchi<sup>1</sup>

<sup>1</sup>Department of Hematology, Juntendo University Urayasu Hospital, Urayasu, Japan; <sup>2</sup>Department of Hematology, Juntendo University School of Medicine, Tokyo, Japan; <sup>3</sup>Department of Pathology, Juntendo University Urayasu Hospital, Urayasu, Japan; <sup>4</sup>Department of Pathology, Research Hospital, The Institute of Medical Science, The University of Tokyo, Japan

Received September 2, 2013; Accepted September 25, 2013; Epub October 15, 2013; Published November 1, 2013

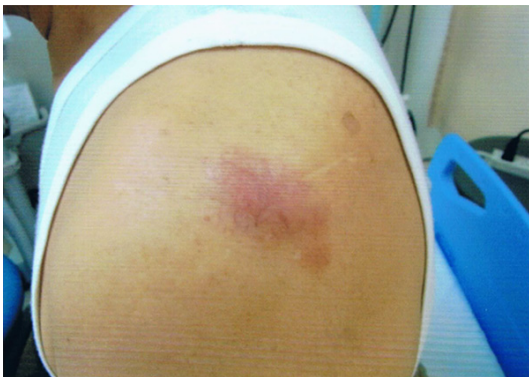**Abstract:** The patient was a 74-year-old man who was found to have a cutaneous mass on his left shoulder in February 2012. Because the mass bled easily and was tending to grow, total resection of the cutaneous tumor, which measured approximately 5 cm x 3 cm, was performed in July. Histopathological examination revealed a tumor that extended from the dermis to the cutaneous adipose tissue, but no invasion of the epidermis was seen. The tumor cells were plasmacytoid cells ranging in size from small to intermediate, and there was no nuclear irregularity. They had a high nuclear-cytoplasmic ratio, and nucleoli were observed. The tumor cells were CD4-positive, CD56-positive, and CD123-positive, and they were AE1/AE3-negative, CD3-negative, CD20-negative, and myeloperoxidase-negative. <sup>18</sup>F-fluorodeoxyglucose positron emission tomography-computed tomography (FDG-PET/CT), a bone marrow examination, etc., were performed, but no lesions were detected at other sites. Based on the above findings a diagnosis of blastic plasmacytoid dendritic cell neoplasm (BPDCN), Stage IEA, was made. Because the patient had limited-stage BPDCN and was elderly, we treated him with a simultaneous combination of low-dose DeVIC (dexamethasone, VP16, ifosfamide, and carboplatin) therapy and local radiation therapy (LRT) and sustained a complete remission for approximately 1 year. Simultaneous combination of non-CHOP (cyclophosphamide, doxorubicin, vincristine, and prednisone) chemotherapy and LRT appeared to be useful in the treatment of limited-stage BPDCN even in the elderly.

**Keywords:** Blastic plasmacytoid dendritic cell neoplasm, DeVIC, local radiation therapy, CD4, CD56, CD123

## Introduction

Blastic plasmacytoid dendritic cell neoplasms (BPDCNs) are rare tumors, and in recent years it has been learned that the cells of origin are the precursors of plasmacytoid dendritic cells and that they give rise to cutaneous and bone marrow infiltration and leukemic dissemination [1]. In the past, BPDCNs were considered to be a form of natural killer (NK)-cell neoplasms because of being CD56-positive, but that has since been shown not to be correct. BPDCNs

are very rare hematopoietic organ tumors, and they are more common in males, and most common in the elderly, with almost all of the patients being 60 years of age or over. Lesions develop at more than one site, and abnormal cells are observed in the skin in almost 100% of the cases, with the skin being followed in frequency by bone marrow and peripheral blood. Although BPDCNs initially respond to chemotherapy, they almost always relapse, ultimately undergo leukemic phase, and lead to the patient's death. The clinical course is progres-



**Figure 1.** Tumor findings in the left shoulder. The tumor measured approximately 5 cm x 3 cm in size, was elastic soft, and had irregular margins, and there was no mobility or tenderness. Capillary dilatation was observed.

sive, and median survival time even in the early stage clinically is 12-14 months. While 80%-90% respond to initial chemotherapy, almost all of the cases relapse and acquire resistance to treatment. Reports of long-term survival have been seen when chemotherapy for acute leukemia and allogeneic hematopoietic stem cell transplantation have been performed to treat young patients.

Below we report a case of limited-stage BPDCN in an elderly patient treated with a simultaneous combination of DeVIC (dexamethasone, VP16, ifosfamide, carboplatin) therapy and local radiation therapy (LRT), which has been becoming the standard treatment for limited-stage NK-cell neoplasms, and in which a complete remission has continued for more than one year. The literature also suggests that a simultaneous combination of non-CHOP (cyclophosphamide, doxorubicin, vincristine, and prednisone) chemotherapy and LRT is beneficial from the standpoint of improving treatment outcome.

### Case report

The patient was a 74-year-old man with a chief complaint of reddening and a mass on his left shoulder. His past history revealed polypectomy for a colorectal polyp at 64 years and 67 years of age. He had undergone transurethral resection for a urinary bladder tumor at 70 years and 73 years of age. At 72 years of age a right lower lobectomy with lymph node dissection had been performed for lung cancer. The

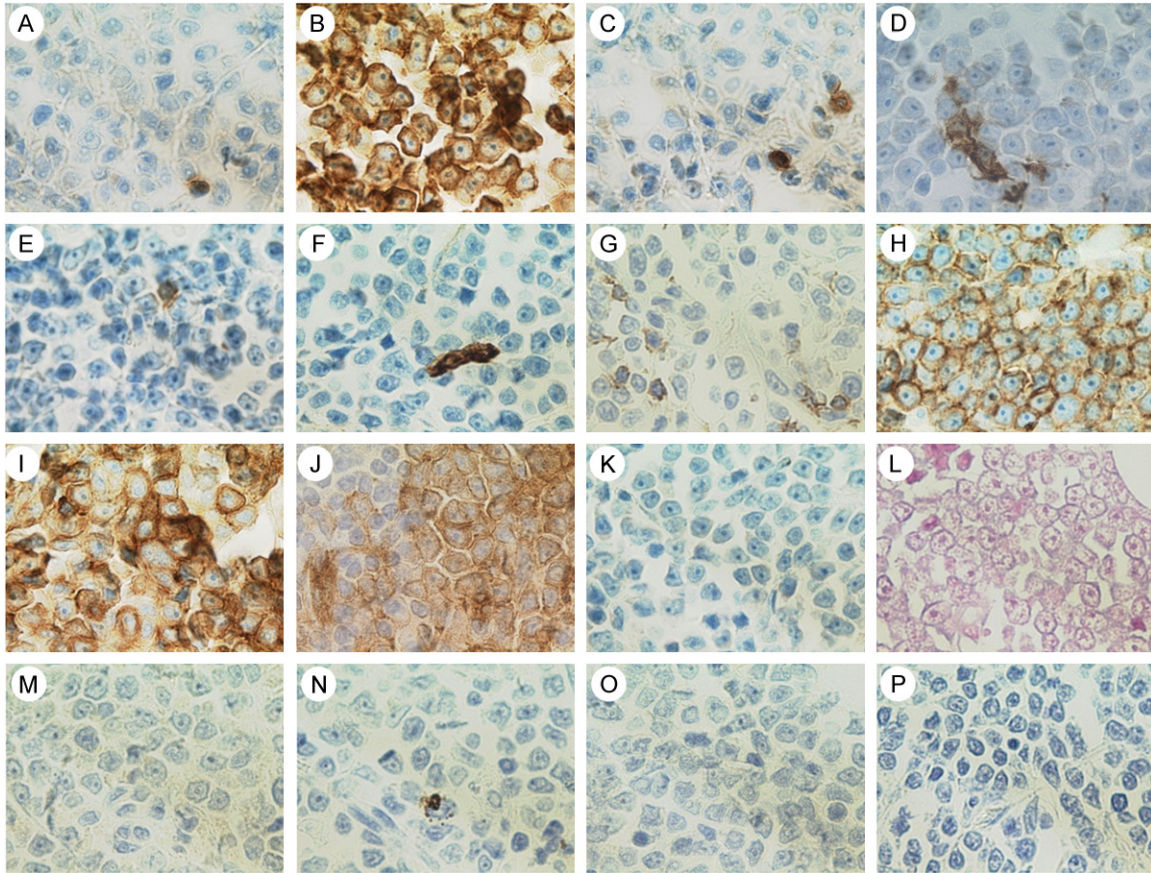
patient had hypertension, a lipid abnormality, and hyperuricemia.

### History of the present illness

In February 2012 the patient's family called his attention to reddening and a mass on his left shoulder, and because it bled easily and was tending to increase in size, he was examined by a local physician in May. The patient was referred to the plastic surgery department the same month. The tumor measured approximately 5 cm x 3 cm, was elastic and soft, and had an irregular margin, but it was not mobile or tender. Capillary dilatation was observed (**Figure 1**). In July, the cutaneous tumor was resected, and because a malignant lymphoma was suspected, the patient was referred to the hematology department for a thorough examination and treatment.

Histopathological examination revealed that the tumor extended from the dermis to the cutaneous adipose tissue, and no invasion of the epidermis was detected. The tumor cells were plasmacytoid, ranged in size from small to intermediate, and had a high nuclear-cytoplasmic (N/C) ratio. Because they were AE1/AE3-negative, an epidermal tumor was ruled out. Nucleoli were present, the nuclei were not irregular, and there was little apoptosis. Immunohistological staining revealed that the cells were CD3-negative, CD4-positive, CD20-negative, CD45-positive, CD56-positive, CD123 (interleukin-3 receptor alpha chain)-positive, and myeloperoxidase (MPO)-negative, and they were typical findings in BPDCN (**Figure 2**). The cells were also terminal deoxynucleotidyl transferase (TdT)-negative, and no tumor cells were detected at the margins of the surgical specimen (data not shown).

A bone marrow examination, etc., were performed after total surgical resection of the tumor, and no clear lesions were detected at any other sites. <sup>18</sup>F-fluorodeoxyglucose positron emission tomography-computed tomography (FDG-PET/CT) revealed only slight inflammatory findings after resection of the cutaneous tumor on the left shoulder, and no other lesions were detected anywhere in the patient's body (**Figure 3**). The diagnosis was BPDCN, stage IEA. In August of the same year, because the patient was elderly, we began simultaneously



**Figure 2.** Pathology of cutaneous tumor. A-P: (x 600), A: CD3-negative, B: CD4-positive, C: CD5-positive, D: CD8-negative, E: CD20-negative, F: CD34-negative, G: CD43-negative, H: CD45-positive, I: CD56-positive, J: CD123-positive, K: C-KIT-negative, L: Epstein-Barr virus-encoded small RNA (EBER) in situ hybridization-negative, M: TIA-1-negative, N: Granzyme B-negative, O: Perforin-negative, P: Myeloperoxidase (MPO)-negative.

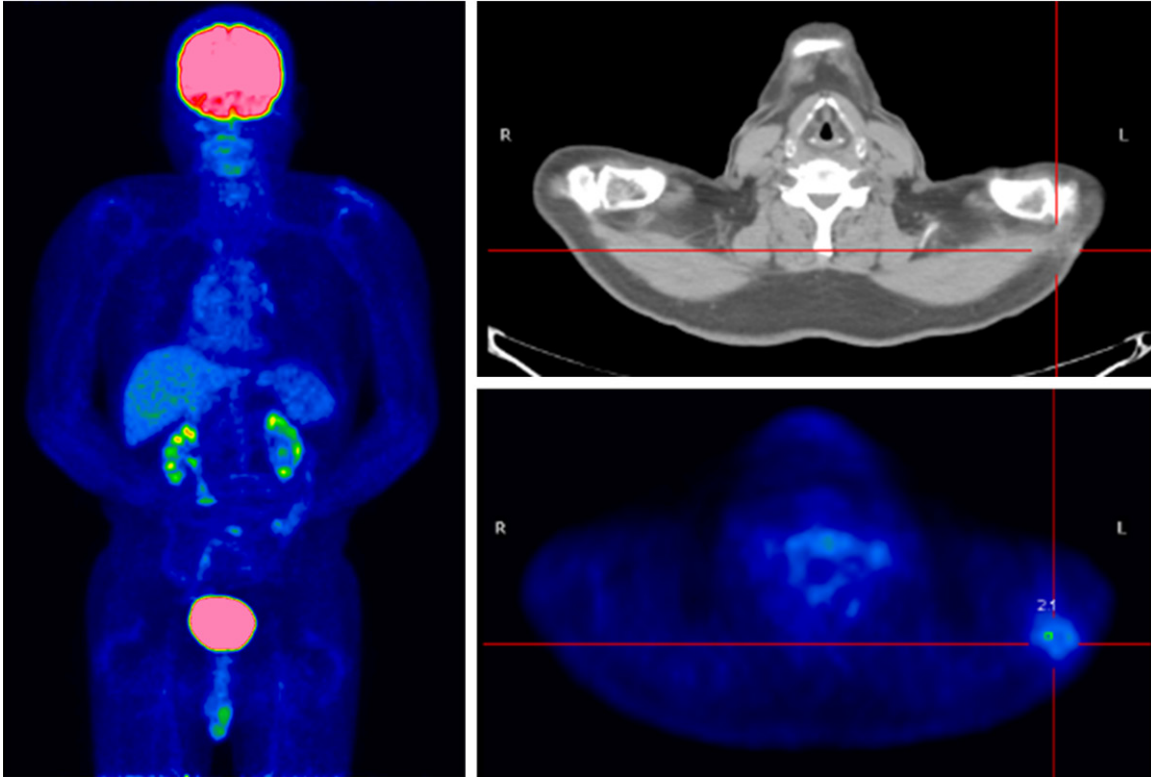
treating him with a combination of 3 courses of 2/3-dose DeVIC therapy at 8-week intervals and LRT, and a complete remission was sustained for more than one year with high tolerance.

### Discussion

Our patient's tumor cells were AE1/AE3-negative, CD3-negative, and MPO-negative. In addition to being CD4-positive, CD5-positive, CD20-positive, CD45-positive, and CD56-positive, they were CD123-positive, and the results of a Southern blot analysis showed that there was no T cell receptor (TCR) C $\beta$ 1 rearrangement, thereby ruling out NK/T cells. According to the literature, CD303 (blood dendritic cell antigen 2 [BDCA-2]), T-cell leukemia/lymphoma 1 (TCL1), cutaneous lymphocyte-associated antigen (CLA) are also said to be useful in making the diagnosis [2, 3].

Age 40 years old and under and more than 50% of the tumor cells being TdT-positive are favorable prognostic factors [4]. Our patient did not have either of these prognostic factors, and having limited-stage disease appeared to be the most important favorable prognostic factor.

DeVIC therapy is combination therapy that consists of non-multi-drug-resistance (MDR)-associated drugs (dexamethasone ifosfamide, and carboplatin), and etoposide, which is known to be effective against Epstein-Barr virus (EBV)-associated hemophagocytic syndrome, and it was devised as salvage chemotherapy for aggressive lymphomas [5]. Treatment for limited-stage nasal-type NK/T-cell lymphomas used to consist of anticancer drug therapy first and radiotherapy afterward, but the results of clinical trials have demonstrated that treatment outcome is better when



**Figure 3.**  $^{18}\text{F}$ -fluoro-2-deoxy-D-glucose-positron emission tomography/computed tomography (FDG-PET/CT). FDG-PET/CT revealed accumulation in the vicinity of the skin of the left shoulder (maximum Standardized Uptake Value [SUVmax] = 2.4), and it was accumulation due to changes after treatment. No clear abnormal accumulation was seen in the supraclavicular lymph nodes, axillary lymph nodes, or cervical lymph nodes.

DeVIC therapy and radiotherapy are performed at almost the same time [6]. This method is currently being performed in many institutions. In the past BPDCNs were sometimes thought to be NK/T-cell tumors, and we even considered simultaneous combination DeVIC therapy and radiotherapy, the same as for a limited-stage NK/T-cell tumor, in our own patient. However, because our patient was elderly we treated him with a simultaneous combination of low-dose (2/3 the dose) DeVIC therapy, with 8-week intervals between doses, and LRT. The treatment-related toxicity of this low-dose therapy is within the allowable range even for the elderly, and the course of treatment was also favorable. Low-dose DeVIC therapy and LRT appeared to be a treatment worth trying for limited-stage BPDCN in patients who are elderly and in whom hematopoietic stem cell transplantation would be difficult, etc.

There have been at least 11 reports of cases of primary cutaneous solitary BPDCN in the literature (Table 1). They were all reports from Italy,

France, and Western Europe, and the patients' median age was 71.5 years (25-83 yr) and 9 patients (75%) were male. In the 9 cases (75%) the sites were in the upper half of the body, perhaps because they were more prominent. During the follow-up period the 6 patients (50%) had survived, and the outcome has been better than in the cases that were diagnosed in the advanced stage at the initial examination. After excluding the 1 case that was impossible to follow-up, 9 of the 11 patients were treated with either chemotherapy alone or LRT alone and their outcomes were poor. However, the other 2 of the 11 cases, including our own case, were treated by a simultaneous combination of chemotherapy and LRT, and their outcomes were favorable. Total tumor resection was performed in our case, but only a biopsy was performed in the other case, and total resection may not be essential. Even when the diagnosis is advanced BPDCN, if the patient is young and has good performance status (PS) and renal function, SMILE (dexamethasone, methotrexate, ifosfamide, L-asparaginase, and etoposide)

## BPDCN followed by DeVIC

**Table 1.** Clinical findings of Primary cutaneous solitary Blastic plasmacytoid dendritic cell neoplasm (BPDCN)

Case	Sex/Age (years)	Initial location	Size (cm)	CD4	CD43	CD56	CD123	BM	LN	PB	Initial treatment	RFS (months)	OS (months)	Outcome	References
1	M/66	anterior chest	5 x 3	-	+	+	+	-	-	-	CHOP	10	24	AWD	[8]
2	F/60	face	2.7 x 2	+	NA	+	+	-	-	-	High-dose MTX, L-ASP, DEX, LRT	30	30	NED	[9]
3	M/37	leg	NA	NA	NA	NA	NA	-	-	-	CCNU, doxorubicin, CA	3	54	DCD	[10]
4	M/70	cheek	NA	NA	NA	NA	NA	-	-	-	CA, idarubicin, CCNU	NA	19	DCD	[10]
5	M/73	shoulder	NA	NA	NA	NA	NA	-	-	-	LRT	NA	36	DCD	[10]
6	M/75	arm	NA	NA	NA	NA	NA	-	-	-	Refuse treatment	NA	12	DCD	[10]
7	F/60	cheek	NA	NA	NA	NA	NA	-	-	-	MTX, L-ASP, RT	11	11	LFU	[10]
8	M/83	cheek	NA	NA	NA	NA	NA	-	-	-	LRT	8	8	Alive	[10]
9	F/25	leg	NA	NA	NA	NA	NA	-	-	-	HyperCVAD	6	38	Alive	[10]
10	M/82	scalp	NA	NA	NA	NA	NA	-	-	-	LRT	9	19	DCD	[10]
11	M/78	leg	NA	NA	NA	NA	NA	-	-	-	CHOP	12	12	Alive	[10]
12	M/74	shoulder	5 x 3	+	+	+	+	-	-	-	TR, DeVIC, LRT	12	12	NED	present

Abbreviations: AWD, alive with disease; BM, initial bone marrow involvement; CA, cytarabine; CCNU, lomustine; CHOP, cyclophosphamide, doxorubicin, vincristine, and prednisone; CVAD, cyclophosphamide, vincristine, doxorubicin, and dexamethasone; DCD, decreases, could be dead; DeVIC, carboplatin, etoposide, ifosfamide, and dexamethasone; DEX, dexamethasone; F, female; L-ASP, L-asparaginase; LFU, lost to follow-up; LN, initial lymph node involvement; LRT, local radiation therapy; M, male; MTX, methotrexate; NA, not available; NED, no evidence of disease; OS, overall survival; PB, initial peripheral blood involvement; RFS, relapse-free survival; TR, total resection.

therapy, which includes high-dose methotrexate therapy and L-asparaginase therapy, is mentioned as a candidate for non-CHOP chemotherapy for remission induction, the same as for NK-cell tumors [7]. A modification in which allogeneic hematopoietic stem cell transplantation is performed as consolidation therapy is also necessary. On the other hand, the prognosis of advanced BPDCN in the elderly can only be described as poor.

We have reported a case of BPDCN in an elderly person. Because it was limited-stage we treated the patient with a simultaneous combination of low-dose DeVIC therapy and LRT and sustained a complete remission. When a solitary, red cutaneous tumor lesion measuring 3-5 cm is observed on the face or limbs of an elderly person, a biopsy should be performed immediately, and BPDCN should be included in the differential diagnosis. A simultaneous combination of the non-CHOP regimen low-dose DeVIC therapy and LRT appeared to be a well-tolerated useful method of treatment for limited-stage BPDCN even though the patient was elderly.

#### Acknowledgements

The authors would like to thank Professor Masafumi Takimoto, Department of Pathology, Showa University, School of Medicine.

#### Disclosure of conflict of interest

The author(s) indicated no potential conflicts of interest.

**Address correspondence to:** Dr. Kei-Ji Sugimoto, Department of Hematology, Juntendo University Urayasu Hospital, 2-1-1 Tomioka, Urayasu 279-0021, Japan. Tel: +81-47-353-3111; Fax: +81-47-381-5054; E-mail: keijis@juntendo.ac.jp

#### References

- [1] Facchetti F, Jones DM and Petrella T. Blastic plasmacytoid dendritic cell neoplasm. WHO Classification of Tumours of Haematopoietic and Lymphoid Tissues. 4th ed. Lyon, France: International Agency for Research on Cancer (IARC), 2008.
- [2] Garnache-Ottou F, Feuillard J, Ferrand C, Bichle S, Trimoreau F, Seilles E, Salaun V, Garand R, Lepelley P, Maynadie M, Kuhlein E, Deconinck E, Daliphard S, Chaperot L, Besegio L, Foisseau V, Macintyre E, Bene MC, Saas P, Jacob MC; GOELAMS and GEIL study. Extended diagnostic criteria for plasmacytoid dendritic cell leukaemia. *Br J Haematol* 2009; 145: 624-636.
- [3] Petrella T, Meijer CJ, Dalac S, Willemze R, Maynadie M, Machet L, Casasnovas O, Vergier B and Teitel MA. TCL1 and CLA expression in agranular CD4/CD56 hematodermic neoplasms (blastic NK-cell lymphomas) and leukemia cutis. *Am J Clin Pathol* 2004; 122: 307-313.
- [4] Bekkenk MW, Jansen PM, Meijer CJ and Willemze R. CD56+ hematological neoplasms presenting in the skin: a retrospective analysis of 23 new cases and 130 cases from the literature. *Ann Oncol* 2004; 15: 1097-1108.
- [5] Okamoto M, Maruyama F, Tsuzuki M, Nomura T, Miyazaki H, Wakita M, Kojima H, Sobue R, Matsui T and Ino T. [Salvage chemotherapy for relapsed/refractory aggressive non-Hodgkin's lymphoma with a combination of dexamethasone, etoposide, ifosfamide and carboplatin]. *Rinsho Ketsueki* 1994; 35: 635-641.
- [6] Yamaguchi M, Tobinai K, Oguchi M, Ishizuka N, Kobayashi Y, Isobe Y, Ishizawa K, Maseki N, Itoh K, Usui N, Wasada I, Kinoshita T, Ohshima K, Matsuno Y, Terauchi T, Nawano S, Ishikura S, Kagami Y, Hotta T and Oshimi K. Phase I/II study of concurrent chemoradiotherapy for localized nasal natural killer/T-cell lymphoma: Japan Clinical Oncology Group Study JCOG0211. *J Clin Oncol* 2009; 27: 5594-5600.
- [7] Kwong YL, Kim WS, Lim ST, Kim SJ, Tang T, Tse E, Leung AY and Chim CS. SMILE for natural killer/T-cell lymphoma: analysis of safety and efficacy from the Asia Lymphoma Study Group. *Blood* 2012; 120: 2973-2980.
- [8] Ascani S, Massone C, Ferrara G, Rongioletti F, Papini M, Pileri S and Cerroni L. CD4-negative variant of CD4+/CD56+ hematodermic neoplasm: description of three cases. *J Cutan Pathol* 2008; 35: 911-915.
- [9] Fontaine J, Thomas L, Balme B, Ronger-Savile S, Traulle C, Petrella T and Dalle S. Haematodermic CD4+CD56+ neoplasm: complete remission after methotrexate-asparaginase treatment. *Clin Exp Dermatol* 2009; 34: e43-45.
- [10] Dalle S, Beylot-Barry M, Bagot M, Lipsker D, Machet L, Joly P, Dompnmartin A, d'Incan M, Maubec E, Grange F, Dereure O, Prey S, Barete S, Wetterwald M, Fraitag S and Petrella T. Blastic plasmacytoid dendritic cell neoplasm: is transplantation the treatment of choice? *Br J Dermatol* 2010; 162: 74-79.