

Original Article

Pathologic diagnosis of spontaneous splenic rupture in systemic lupus erythematosus

Ning Li¹, Jun C Wang², Ming H Zhu³, Jia Y Wang¹, Xue L Fu², Jie R Zhou¹, Song G Zheng⁴, Jie Han^{1*}, Paul Chan^{5*}

¹Department of Rheumatology, Shanghai East Hospital, Tongji University, Shanghai, China; ²Department of Pathology, Shanghai East Hospital, Tongji University, Shanghai, China; ³Department of Pathology, Shanghai Chang Hai Hospital, The Secondary Army Medical College, Shanghai, China; ⁴Division of Rheumatology & Immunology, Department of Medicine, University of Southern California; ⁵Department of Medicine, Wan Fang Hospital, Taipei Medical University, Taipei City, Taiwan. *Equal contributors.

Received October 23, 2012; Accepted December 3, 2012; Epub January 15, 2013; Published February 1, 2013

Abstract: Systemic lupus erythematosus (SLE) is a common autoimmune disease that involved multiple organ systems. Diagnosis is usually not difficult. However, SLE involved spleen with spontaneous rupture is a rare condition that has been only 5 cases reported previously; and no definite pathologic diagnosis has been reported. We present the case of a 54 year-old white American woman who had SLE for 10 years with multiple immunosuppressive agents treatment at stable condition. She had acute abdomen presented to the emergency department and received timely surgical treatment which confirmed she had spontaneous spleen rupture (SSR). Detailed pathologic study, with control of a traumatic rupture spleen of almost the same age and sex, revealed marked congestion of the red pulp and atrophy of white pulp notified in the SLE spleen. Congestion of red pulp may be the cause of SSR in the SLE spleen.

Keywords: Systemic lupus erythematosus, spleen, spontaneous rupture

Introduction

Splenic rupture in the absence of trauma called spontaneous splenic rupture (SSR), which occurs suddenly or insidiously, was first described by Aktinson and is a rare complication of infectious, hematological and neoplastic disorders [1, 2]. It has also been described in several autoimmune diseases [3].

Systemic lupus erythematosus (SLE) is a common and suffering disease that involves multiple organs, and shortens life span [4]. Involvement of spleen with subsequent spontaneous rupture is a quite rare condition that has been only 5 cases reported in English literature previously [5-9]. However, no detailed pathologic diagnosis has been studied before.

We observed a 54-year-old American woman with SLE who had SSR during the course of the disease and showed some changes histopathologically. The pathology of the ruptured SLE spleen was studied in detail, with comparison

to a traumatic ruptured spleen of a Chinese woman of almost the same age, in order to unravel the pathologic diagnosis of the SSR of SLE spleen.

Materials and methods

The study was approved by the Shanghai Tongji University East Hospital institutional review board. Four observers (N.L., J.Y. W., M.H.Z. and J.H.) evaluated the pathologic results.

Patient summary

This case involves a 54 year-old white American woman who was diagnosed to have SLE at America at the year 2000 and treated with prednisone, methotrexate and hydroxychloroquine. The disease was under controlled and the drugs were tapered to prednisone 10mg/day. She had a transient splenomegaly at year 2005, but recovered without specific treatment. She came to China at 2006, and followed-up regularly at clinic. Blood examinations

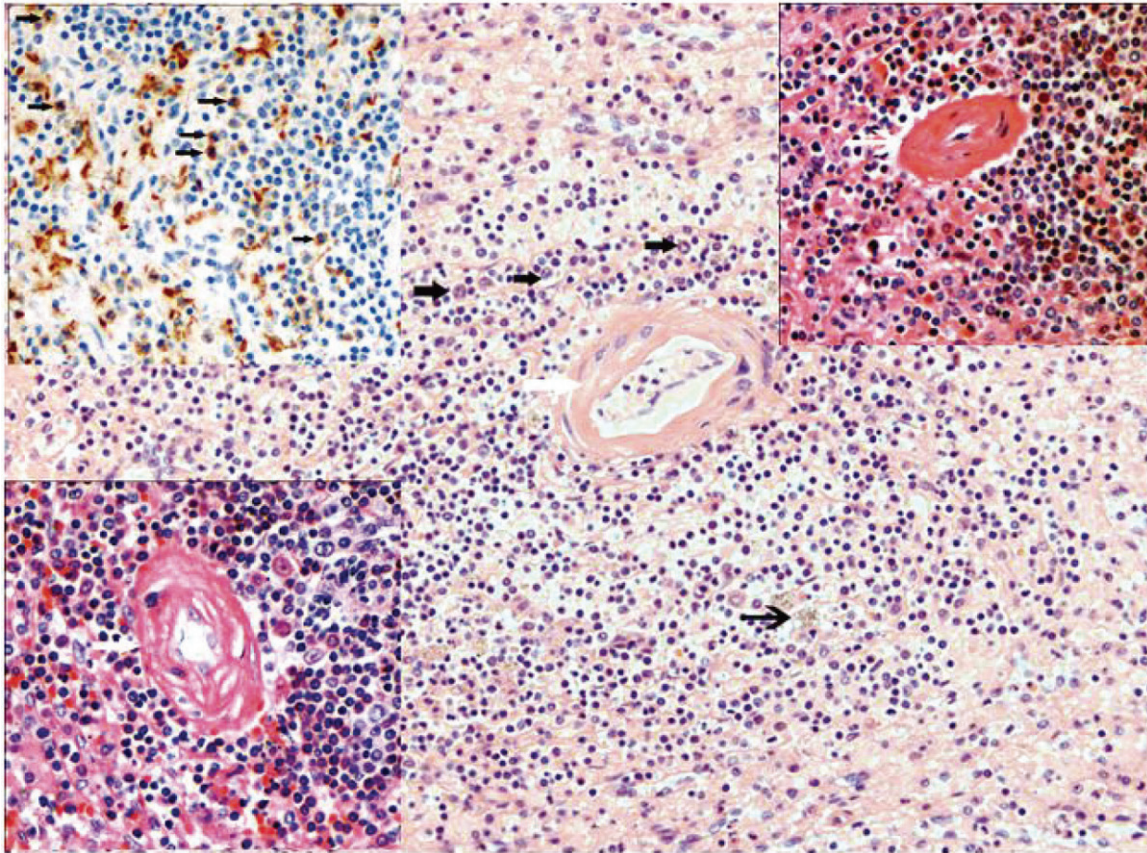


Figure 1. Histiocytes (thick arrows in the big figure and CD68 positive cells in the top left corner of the small figure), deposited hemosiderin (thin arrow), hyaline degeneration of central artery (white thick arrow) and arterial occlusion (white thin arrow) of SLE patient (H&E, 200×).

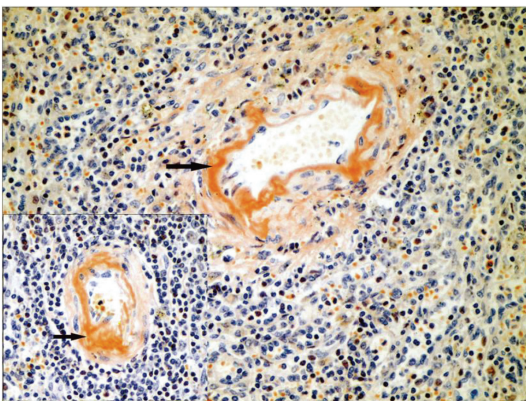


Figure 2. Amyloid substance deposit in the wall of central artery (Congo red staining, 400×).

showed elevated anti-double-DNA antibody [114.3IU/mL (<100)], and low complement 3(C3) [0.193g/L(0.22-0.34)] was found occasionally. At March 2009, she was admitted to a local hospital due to left upper quadrant dis-

comfort, diarrhea and fever. During admission, her temperature was 37.7°C, pulse rate 82/min, respiratory rate 20/min, blood pressure 125/80mmHg. She looked sick, but no jaundice. The main physical findings were upper abdominal tenderness without muscle guarding, and spleen enlargement with 1cm below umbilicus was noted. Laboratory data revealed hemoglobin was 101g/L and CRP 29mg/L. Ultrasound and CT scan of the abdomen showed splenomegaly with spotty calcified changes in spleen. Fever, abdominal pain and diarrhea subsided after treatment. Follow-up abdominal ultrasonography revealed the regression of spleen size 2 days later. She was then discharged with prednisone 5mg/day, methotrexate 20mg/week and hydroxychloroquine 300mg/day.

At February, 2010, she visited our hospital again with abdominal pain, diarrhea, nausea, vomiting and syncope for 3 hours at the emer-

Spontaneous splenic rupture in SLE

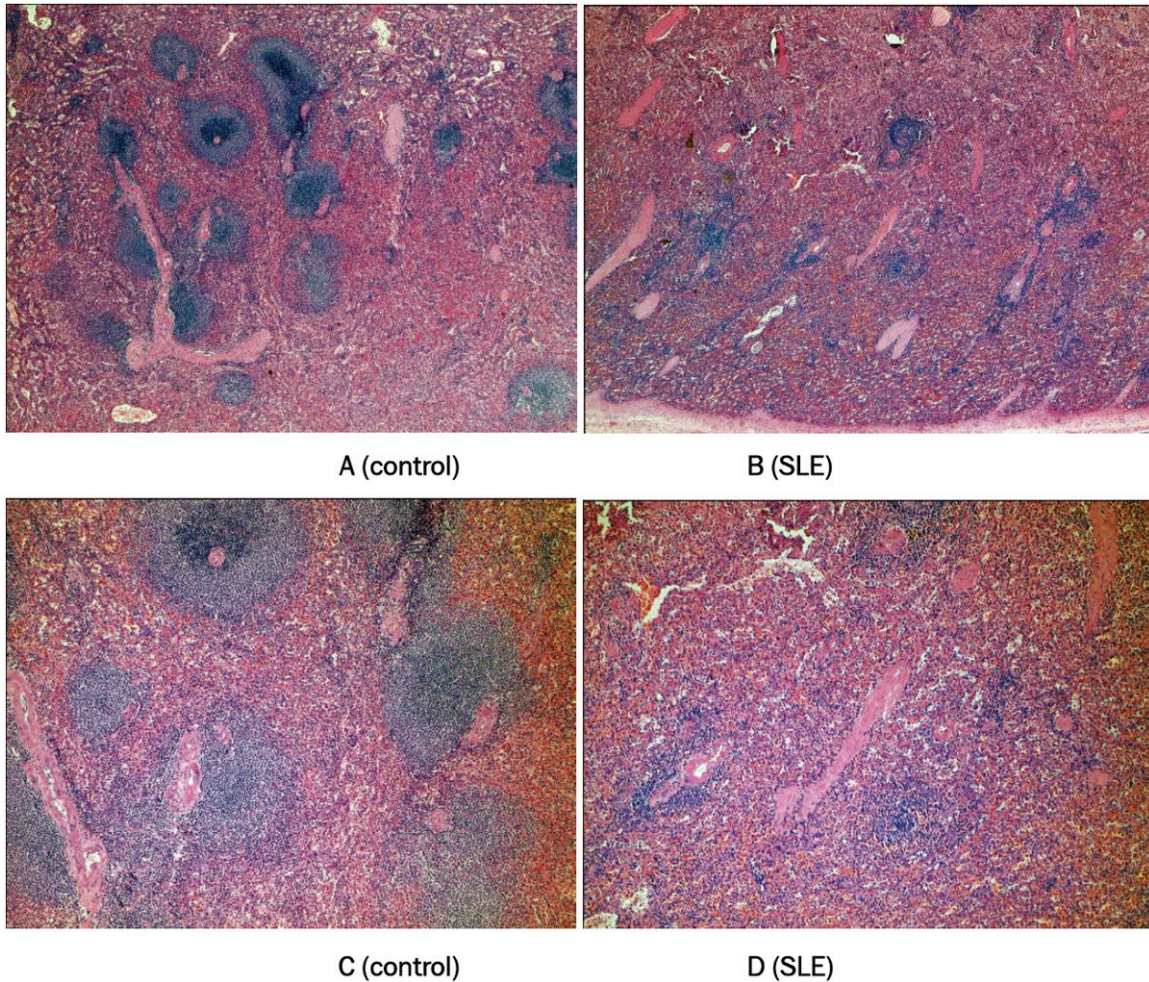


Figure 3. Compared to the control spleen, the SLE spleen showed decreased splenic corpuscle, both in numbers (A, B) and volumes (C, D), splenic atrophy of SLE was considered.

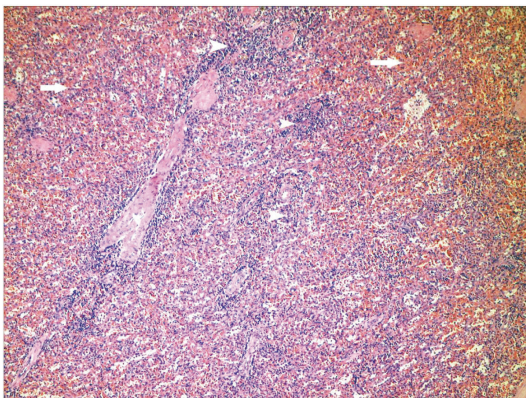


Figure 4. Chronic congestion in the red pulp (long arrows) and splenic corpuscle atrophy (short arrows) of SLE patient (H&E, 100 \times).

gency department, with no history of trauma. On examination, her temperature was 37°C,

pulse 90/min, respiratory rate 25/min, and blood pressure of 72/52mmHg. She was apathic and looked pale, with tense abdomen and muscle guarding on palpation. The spleen was palpable, but its definite size could not be determined. No uncoagulated blood was obtained by paracentesis. Abdominal ultrasound revealed a huge spleen, with size about 14.7 \times 7.9cm, with focal heterogeneous echo pattern and moderate amount of ascites.

Spontaneous splenic rupture (SSR) was suspected. An emergent laparotomy was performed which revealed hemoperitoneum secondary to ruptured spleen with subcapsular hematoma, and splenectomy was performed smoothly. The patient was discharged after 10 days hospitalization and had been following-up uneventfully.

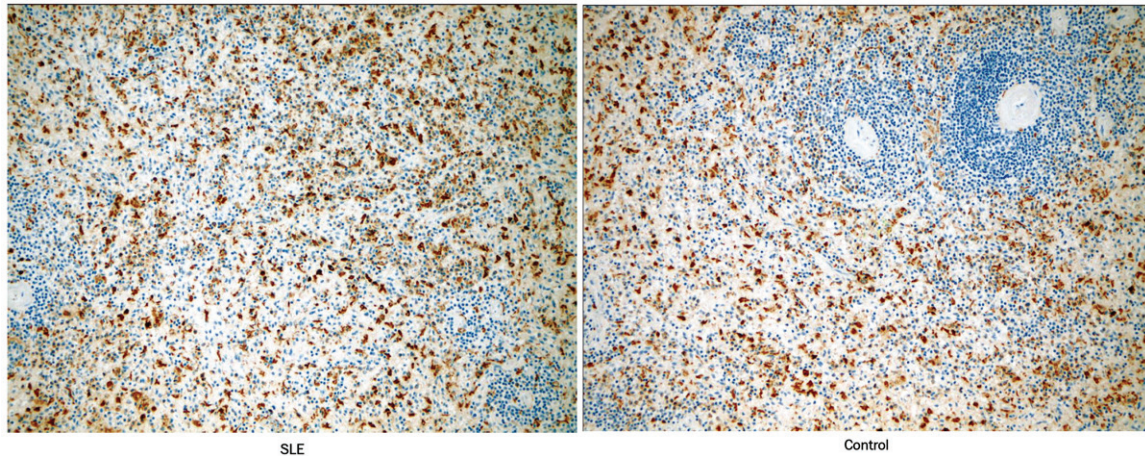


Figure 5. CD68-positive (20×).

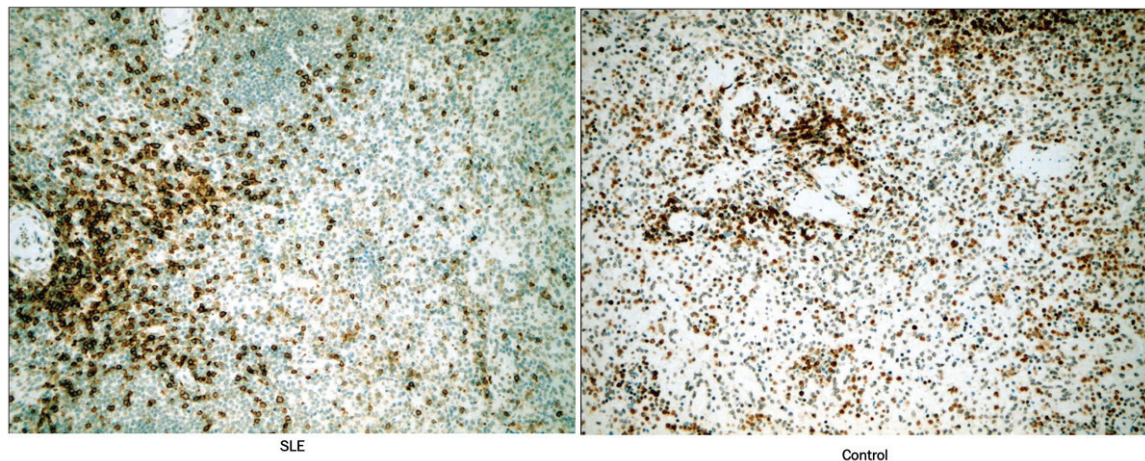


Figure 6. CD45RO-positive (20×).

Results

Both the SLE spleen and traumatic ruptured normal spleen were stained with H&E and Congo red. Paraffined sections were stained using a three-step immunoperoxidase technique with the following antibodies: CD3, CD4, CD8, CD20, CD45RO and CD68 (eBioscience, San Diego, USA).

Grossly the SLE spleen was 405g (normal about 150g), measured about 12×10×3cm. The surface was smooth and glossy, with two irregular lacerations on the anterior surface, 2×1cm and 7×0.5cm, respectively. Part of the capsule was pale in color and 2.8×1cm in size, whose boundary was obscure. No significant vascular lesion was found under microscope;

however, proliferation of histiocytes and hyaline degeneration of central artery and arterial occlusion, splenic corpuscle atrophy with local hemosiderosis was noted (**Figure 1**). By Congo red staining, we could find amyloid substance and deposit was found in the wall of central artery (**Figure 2**). Compared to the control spleen, the SLE spleen showed decreased splenic corpuscle, both in numbers and volumes, splenic atrophy was considered (**Figure 3**). However, chronic congestion in the red pulp of the SLE spleen was notified (**Figure 4**), which was speculated to be the main cause of the SSR of this patient.

There were no significant differences in numbers of CD68 (**Figure 5**) and CD45RO-positive (**Figure 6**) lymphocytes between the traumati-

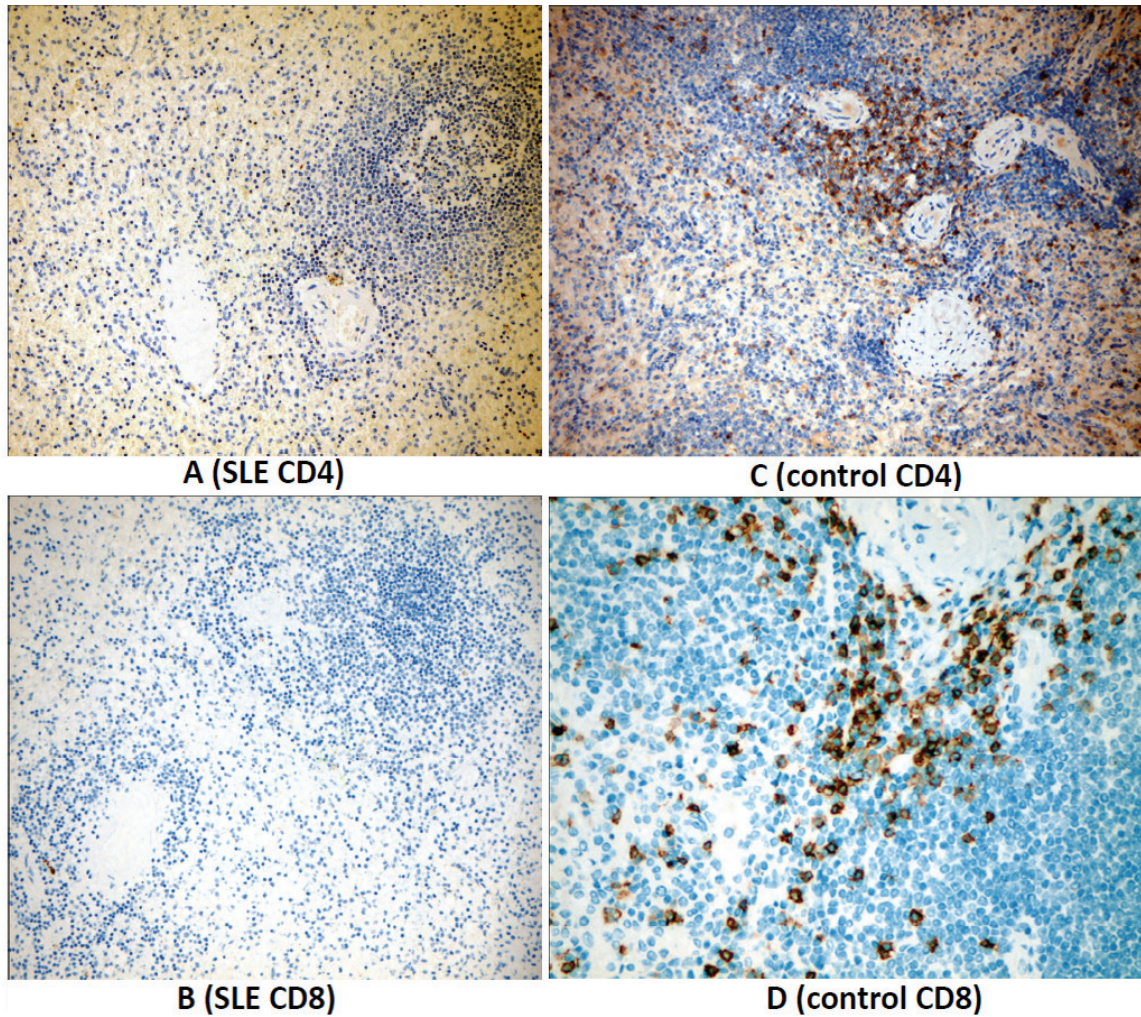


Figure 7. CD4 and CD8 was both negative in SLE spleen (A, B), while positive in control spleen (C, D).

cally ruptured spleen and the SLE spleen. The white pulp consisted of T-cell areas, mainly CD3- and CD4-positive, also CD8-positive cells, and B-cell follicles. There was significant difference between CD3-, CD4- and CD8-positive lymphocytes: CD4 and CD8 were both negative in SLE spleen, whilst positive in the control spleen (**Figure 7**); CD3 weakly-positive cells in SLE spleen were fewer than that of the control, mostly surrounded the splenic corpuscle (**Figure 8**). In the splenic corpuscle areas of the control spleen, the CD20-positive B-cells dominated, and there were also some CD20 cells scattered in the medulla whilst the SLE spleen had lesser CD-20-positive cells (**Figure 9**).

Discussion

Splenic rupture can be seen at trauma, infection and malignancy or autoimmune disease

such as this case. In diseased state, splenomegaly facilitates splenic rupture even following minor trauma. Although involvement of the reticuloendothelial system in SLE is a well-recognized concomitant condition [4], SSR is unusual. The rupture of the SLE spleen is seemed to be not related to disease duration when analyses these 6 cases. Since no previous detailed pathology of the ruptured SLE spleen was reported before, it is still difficult to conclude the main reason of spontaneous rupture. Compared to the traumatically ruptured spleen, the SLE spleen showed decreased splenic corpuscle, both in numbers and volumes, splenic atrophy was considered.

So splenomegaly may be just the main reason for spontaneous rupture. Previous report of Tolaymat stated that necrotizing vasculitis associated with extensive multifocal white pulp

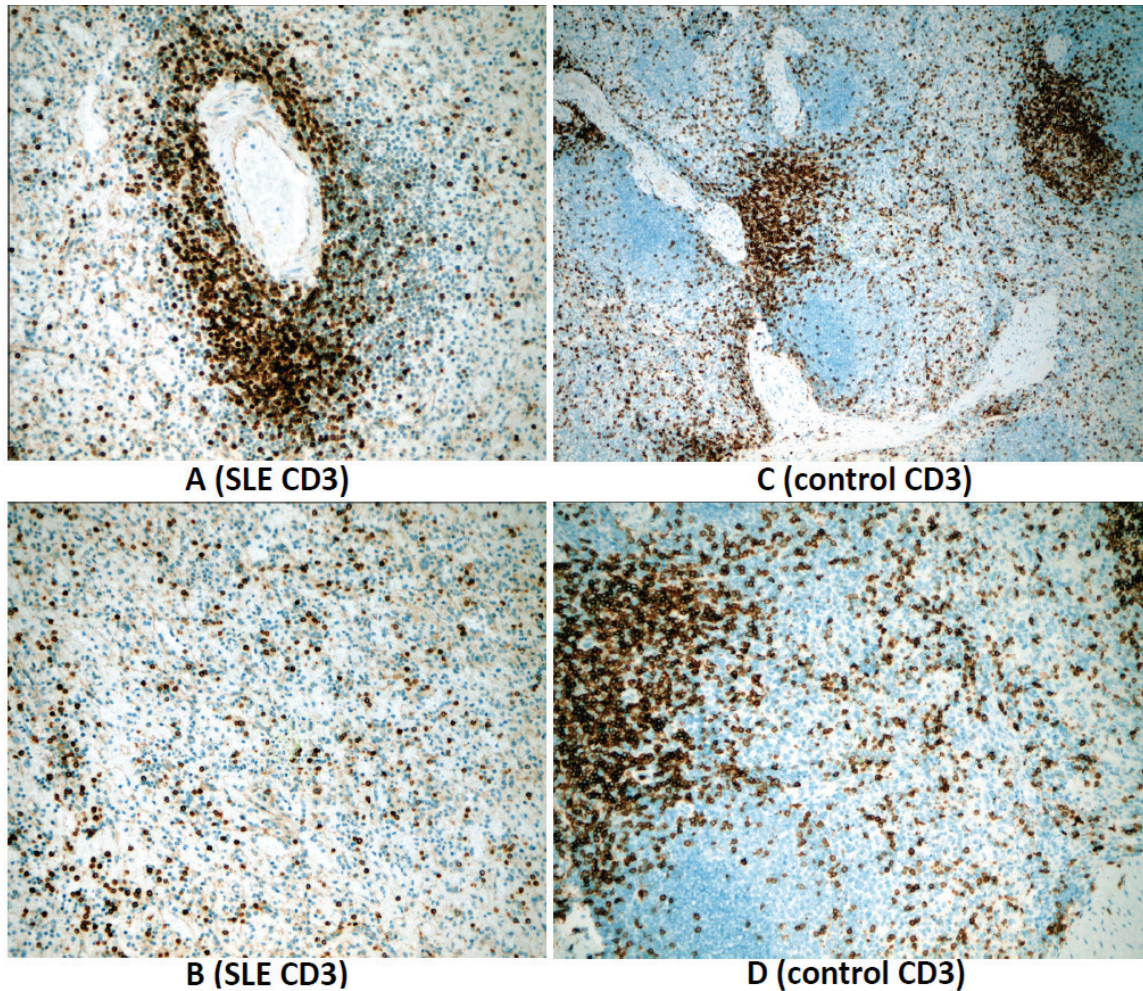


Figure 8. CD3-positive cells in SLE patient (A) and the control (B), of which there was slightly fewer positive cells in SLE (C) than in the control (D), mostly surrounded the splenic corpuscle.

necrosis, and also intraluminal fibrin thrombi were found [8]. The red pulp demonstrated marked congestion, which was also found in our SLE patient.

Unexpectedly, we failed to find any specific type of cell proliferation in the SLE spleen. Interestingly, CD4 and CD8 T lymphocytes were both negative in SLE spleen, CD3 weakly-positive T cells in SLE spleen were fewer than that of the control, mostly surrounded the splenic corpuscle.

Since SSR is quite rare, in case patients with abdominal pain, which locates mainly at upper quadrant, this entity should be suspected. Checking the hemoglobin level is also a simple and convenient measure. Common diagnostic imaging modalities include ultrasonography, CT and MRI.

Active bleeding can be identified on contrast-enhanced CT as intra- or extrasplenic areas of bright vascular enhancement with attenuation similar to or greater than that of the aorta or an adjacent major artery. The appearance may vary with the rate of hemorrhage and the imaging technique used. Newer generation multi-detector CT can have earlier data acquisition which may allow smaller amounts of active hemorrhage to be detected before the high-density contrast material is diluted by surrounding hematoma, especially in a perisplenic location.

MRI is a valuable tool in the evaluation of the spleen and sometimes superior to in many clinical settings. MRI is especially useful in the further investigation of patients with a CT diagnosis of splenomegaly to determine whether underlying tumor infiltration is present [10].

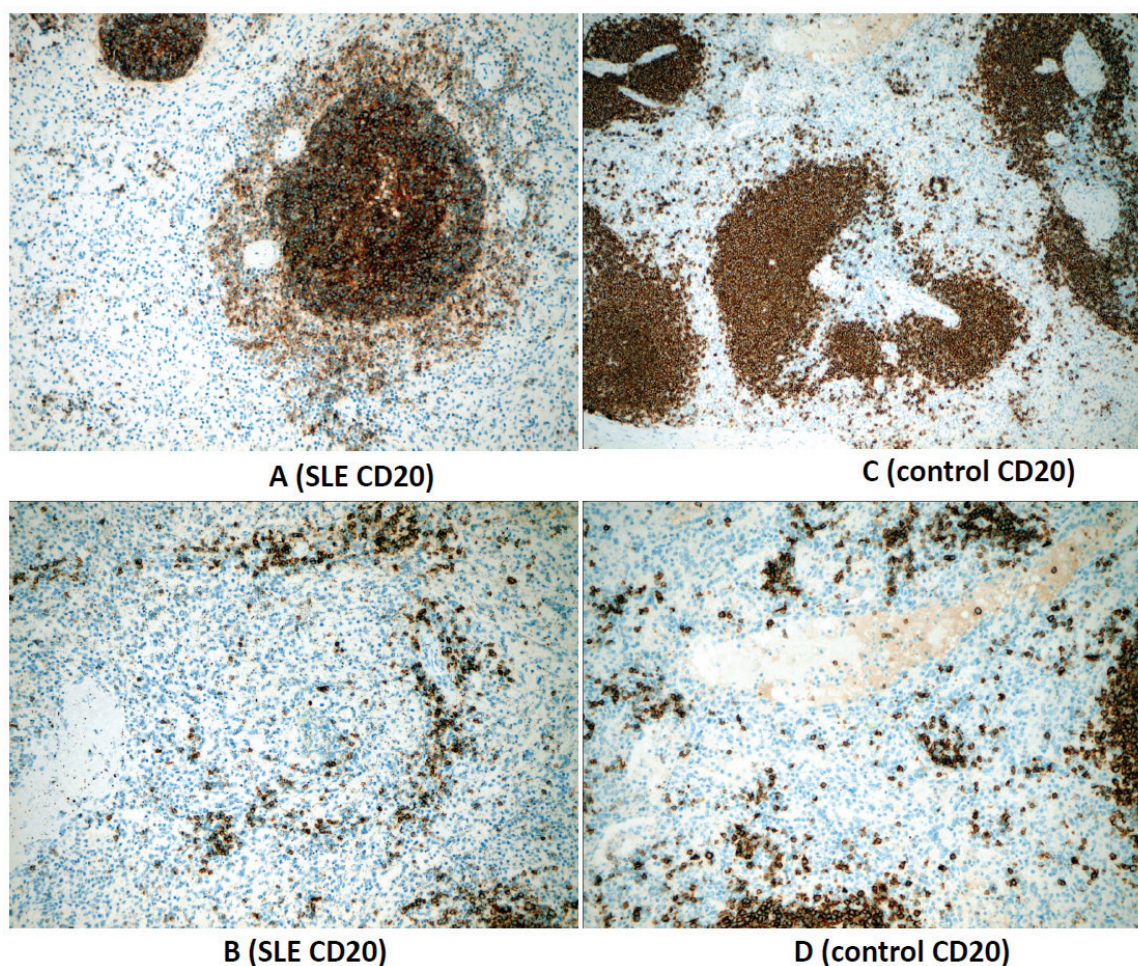


Figure 9. In the splenic corpuscle areas of the control spleen, the CD20-positive B-cells dominated (A), and there were also some CD20 cells scattered in the medulla (B). The CD20-positive B-cells in the control spleen was more than the SLE one (C and D) because of the larger and more splenic corpuscle.

The survival of these patients seems to be uncertain and needs more case studies because of a previous report of a mortality case of a 35-year-old male [7], but this case was probably due to delayed diagnosis and management.

Acknowledgements

This work was partly funded by a Research Grant for Health Science and Technology development and innovation of Pudong New Area of Shanghai (Grant No. PKJ2011-Y06).

Conflict of interest statement

None.

Address correspondence to: Dr. Jie Han, Department of Rheumatology, Shanghai East Hospital, Tongji

University, Shanghai, China. 150, Ji Mo Road, Shanghai, China 200120. E-mail: hjgj85528@yahoo.com.cn; Dr. Paul Chan, Department of Medicine, Wan Fang Hospital, Taipei Medical University, 111, Hsing-Lung Road, Section 3, Wen-Shan District, Taipei City, Taiwan 116. Phone: 886 2 29307930 ext 2815, 2817; Fax: 886 2 29339378; E-mail: chanpaul@w.tmu.edu.tw

References

- [1] Vallabhaneni S, Scott H, Carter J, Treseler P, Machtinger EL. Atraumatic splenic rupture: an unusual manifestation of acute HIV infection. *AIDS Patient Care and STDs* 2011; 25: 461-464.
- [2] Hoar FJ, Chan SY, Stonelake PS, Wolverson W, Bareford D. Splenic rupture as a consequence of dual malignant pathology: a case report. *J Clin Pathol* 2003; 56: 709-710.

Spontaneous splenic rupture in SLE

- [3] Fishman D, Isenberg DA. Splenic involvement in rheumatic disease. *Sem Arthrit Rheum* 1997; 27: 141-155.
- [4] Tsokos GC. Systemic lupus erythematosus. *N Engl J Med* 2011; 365: 2011-2021.
- [5] Zimmerman-Gorska I, Bielaka K. Splenic rupture in the course of SLE. *Pol Tyg Lek* 1971; 26: 1991-1992.
- [6] Krauser R. Spontaneous rupture of the spleen in systemic lupus erythematosus. *JAMA* 1976; 239: 1149.
- [7] Cheng-Chung W, Lan J, Liu T. Systemic lupus erythematosus with spontaneous rupture of the spleen. *J Formosan Med Assoc* 1985; 84: 1186-1990.
- [8] Tolaymat A, Mousily FA, Haafiz AB, Lammert N, Afshari S. Spontaneous rupture of the spleen in a patient with systemic lupus erythematosus. *J Rheumatol* 1995; 22: 2344-2345.
- [9] Karassa Fb, Isenberg DA. Spontaneous rupture of the spleen: an unusual complication of systemic lupus erythematosus. *Lupus* 2001; 10: 876-878.
- [10] Semelka Richard C. *Abdominal-pelvic MRI*, 3rd ed. New York, USA: Wiley, Hoboken, 2010.