

Case Report

Good response of malignant pleural effusion from carcinoma of unknown primary site to the anti-tuberculosis therapy: a case report

Qihua Gu, Chengping Hu, Jingjing Qu

Department of respiratory medicine, Xiangya Hospital affiliated to Central South University, Changsha City, Hunan, 410008, P.R. China

Received February 21, 2013; Accepted March 19, 2013; Epub April 15, 2013; Published April 30, 2013

Abstract: Malignant pleural effusion in patients with cancers or malignant pleural mesothelioma may often appear at the late stage of disease and significantly affect the patients' life quality and survival. However, there is still no very effective treatment to control malignant pleural effusion. Here we report that malignant pleural effusion in one patient was completely relieved for 15 months by the anti-tuberculosis therapy. Case presentation: A 54-year-old female patient complained of cough, dyspnea, chest pain, night sweat and light fever in the afternoon. Computed tomography (CT) of the chest revealed bilateral pleural effusion. But no tumor was found in the lung, pleura and in other sites. Blood test revealed serum carcinoembryonic antigen (CEA) level at 300 ng/mL. One week after we tried anti-tuberculosis combined therapy with isoniazid, pyrazinamide, rifapentine and ethambutol. The pleural effusion in patient was eliminated, along with decreasing CEA. But the CEA increased gradually again when the anti-tuberculosis treatment was forced to discontinuation. Sixteen months after anti-tuberculosis treatment, the symptoms of cough and breathing difficulty relapsed. Chest CT revealed left pleural effusion, pleural thickness and pericardium nodules. Thoracoscopy and biopsy were conducted. The pleural nodules specimen was pathologically diagnosed as squamous cell carcinoma. Conclusion We reported a rare case of successfully treating malignant pleural effusion caused by squamous cell carcinoma of unknown primary site with the anti-tuberculosis combined. This report provides useful evidences for that the anti-tubercular agents may have potential anticancer activity in some carcinomas.

Keywords: Malignant pleural effusion, carcinoembryonic antigen (CEA), anti-tuberculosis therapy

Introduction

According to the original diseases, pleural effusions can be classified into benign pleural effusion and malignant pleural effusion. Malignant pleural effusion is encountered at the advanced stage of disease progression and often associates with poor prognosis [1]. Malignant pleural effusion in patients with metastatic cancers or malignant pleural mesothelioma, may often appear at the late stage of disease and significantly reduce the patient's life quality and survival [2, 3]. The incidence of benign pleural effusions is twice as malignant effusions and has diverse causes and manifestations [4]. There are several common benign pleural effusions that caused by tuberculosis, pneumonia, congestive heart failure, hypoproteinemia, etc.

Clinical outcome of benign pleural effusion depends greatly on its original disease. For this reason, once a patient is first diagnosed with the pleural effusion, it is necessary to determine if the patient has transudates or exudates [5]. Etiological diagnosis should be performed to achieve optimal treatment. However, etiological diagnosis is very difficult in some circumstances, such as few cases of malignant pleural effusion. It has been reported that metastatic cancer of unknown primary site accounts for approximately 3% of all malignant neoplasms [6]. In the present report, we report a case of malignant pleural effusion caused by squamous cell carcinoma of unknown primary site. More importantly, malignant pleural effusion was completely relieved for 15 months by fortunate treatment with the anti-tuberculosis

Anti-tuberculosis therapy for malignant pleural effusion

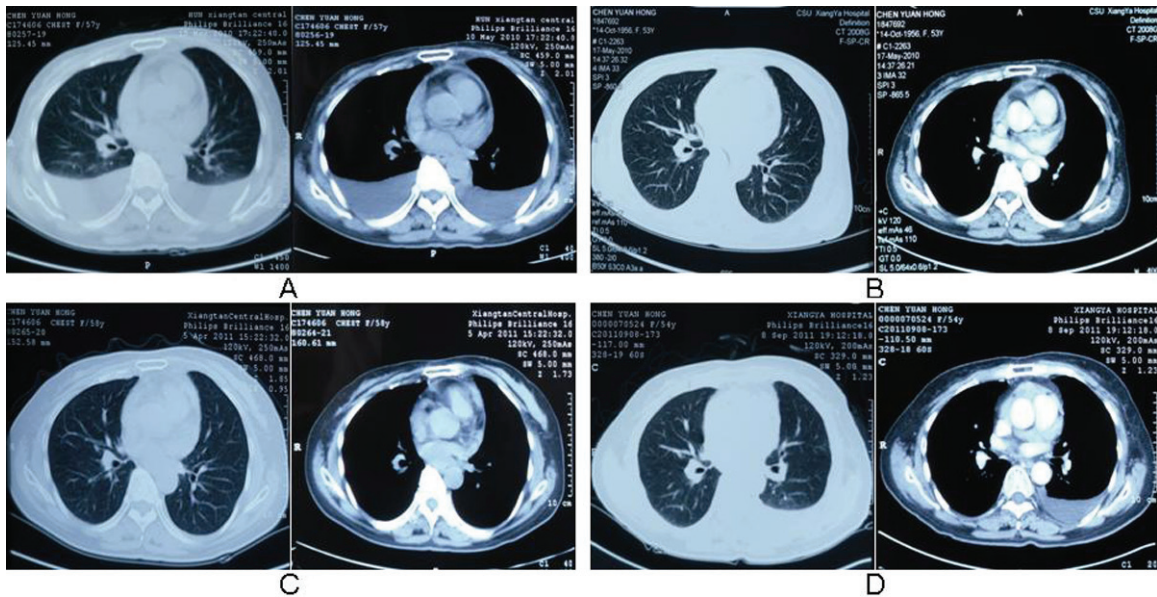


Figure 1. Computed tomography of the patient. A. Initial examination. Chest CT revealed bilateral pleural effusion, but no tumor was found in the lung and pleura; B. One week after anti-tuberculosis therapy, the patient's pleural effusion was eliminated; C. Eleven months later, there was still no pleural effusion; D. Sixteen months later, Chest CT revealed left pleural effusion, pleural thickness and pericardium nodules.

combined therapy of isoniazid, pyrazinamide, rifampentine and ethambutol.

Case presentation

A 54-year-old female patient was hospitalized in June 2010 because of cough and dyspnea. The patient had the symptoms of intermittent cough, breathing difficulty after activities and chest pain for 10 days. She also had clinical symptoms of light fever (body temperature rose at 37.5°C) in the afternoon, fatigue, and night sweat. Physical examination revealed dull sound on percussion and decreased breath sounds in the low lung areas by auscultation. Computed tomography (CT) revealed bilateral pleural effusion (Figure 1A). But no tumor was found in the lung, pleura and in other sites. We conducted thoracic puncture and identified bloody pleural effusion. No carcinoma cells were found in the pleural effusion. The serum carcinoembryonic antigen (CEA) level was 300 ng/mL in blood test. The patient also had a positive result (greater than 10 mm, ++) in purified protein derivative (PPD) skin test. The patient was primarily diagnosed as tuberculous pleurisy according to clinical manifestations and auxiliary examination, but metastatic carcinoma remained to be excluded. We planned to conduct thoracoscopy after pretreatment of

isoniazid, pyrazinamide, rifampentine and ethambutol. One week after treatment, the pleural effusion was eliminated (Figure 1B), along with reduced CEA (131.9 ng/mL). Two months after anti-tuberculosis treatment, pyrazinamide was subtractive. Four months after treatment, the anti-tuberculosis treatment was forced to discontinuation because of skin pruritus, erythema and rash. The CEA subsequently increased gradually again. Clinical manifestations and auxiliary examinations in the follow-up periods are shown in Table 1. The patient felt light chest pain in August 2011. The symptoms of cough and breathing difficulties relapsed in September 2011. Chest CT revealed left pleural effusion (Figure 1D), pleural thickness and pericardium nodules. Single photon emission computed tomography (SPECT) revealed that multiple bone metastatic lesions (Figure 2A). But no primary tumor was found by positron emission tomography-computed tomography (PET-CT). Thoracoscopy and biopsy were conducted. The pleural nodules specimen was identified as squamous cell carcinoma by pathological diagnosis (Figure 2B-D).

Discussion

We experienced a rare case of patient who had malignant pleural effusion from carcinoma of

Anti-tuberculosis therapy for malignant pleural effusion

Table 1. The patient's records of symptoms, chest CT and CEA

Time	Clinical symptoms	Chest CT	CEA
Onset	cough, dyspnea, chest pain, light fever, night sweat.	bilateral pleural effusion	300 (ng/mL)
1 week	symptoms disappeared	pleural effusion disappeared	131 ng/mL
1 month	no symptoms	no pleural effusion	30 ng/mL
4 months	pruritus, erythemas, rash.	no pleural effusion	13 ng/mL
6 months	no symptoms	no pleural effusion	23 ng/mL
9 months	no symptoms	no pleural effusion	50 ng/mL
12 months	no symptoms	no pleural effusion	72 ng/mL
15 months	light chest pain	no pleural effusion	536 ng/mL
16 months	chest pain, cough, breathing difficulties	left pleural effusion pleural nodules	712 ng/mL

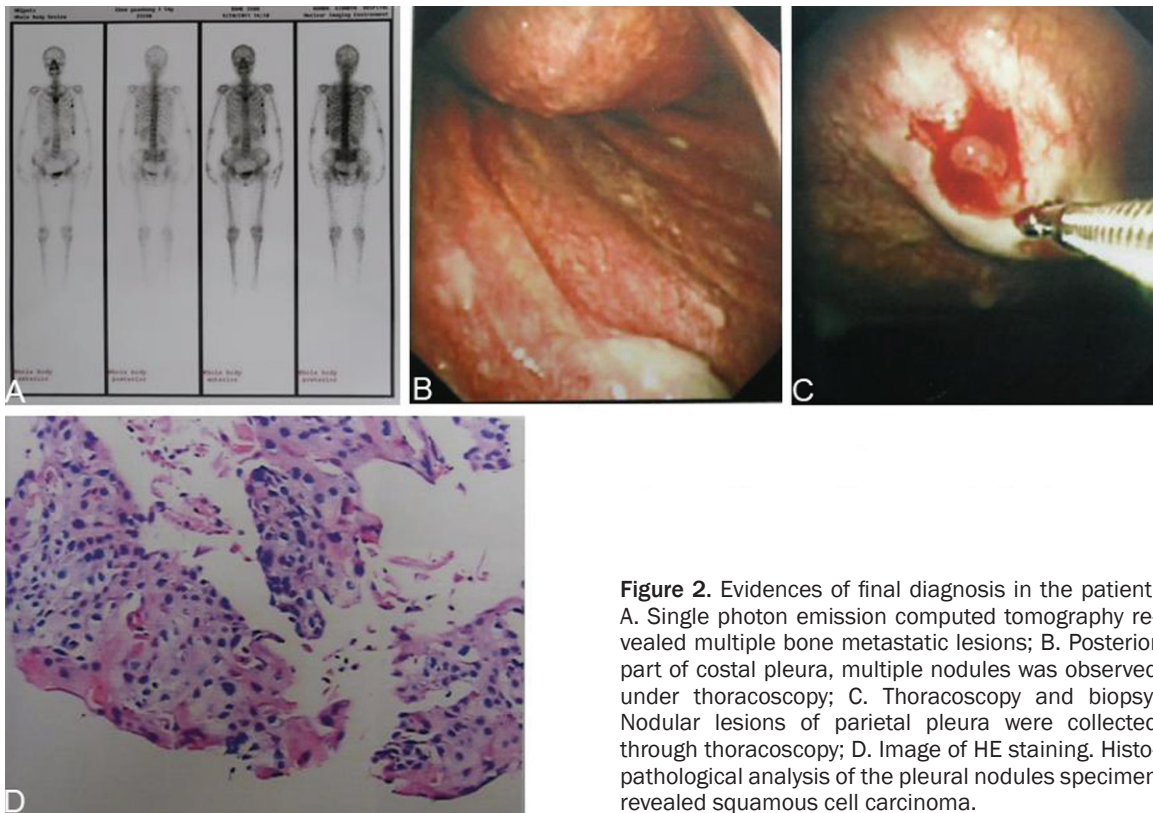


Figure 2. Evidences of final diagnosis in the patient. A. Single photon emission computed tomography revealed multiple bone metastatic lesions; B. Posterior part of costal pleura, multiple nodules was observed under thoracoscopy; C. Thoracoscopy and biopsy. Nodular lesions of parietal pleura were collected through thoracoscopy; D. Image of HE staining. Histopathological analysis of the pleural nodules specimen revealed squamous cell carcinoma.

unknown primary site and got a remarkable clinical remission by treatment of anti-tuberculosis. The patient was finally diagnosed as metastatic squamous cell carcinoma by thoracoscopy and biopsy. When the patient was treated with the anti-tuberculosis therapy, such symptoms as chest pain, fever and night sweat were quickly relieved, the pleural effusion disappeared, and the serum level of CEA was reduced. During the follow-up period, clinical symptoms of the patient, pleural effusion and serum CEA were changed consistently. CEA is a tumor marker for many carcinomas. Moreover,

the tumor marker index from serum and lavage CEA levels might be useful for predicting the prognosis of non-small cell lung cancer patients [7]. For this patient, the primary tumor site remained unknown in the final diagnosis. It has been reported that lung cancer and mesothelioma are common causes of malignant pleural effusion. Moreover, elevated CEA level can be found in small-sized peripheral-lung squamous cell carcinomas [8]. Tuberculous pleurisy was excluded, so we suspect that malignant pleural effusion in this patient was most possibly caused by small-sized peripheral-lung squa-

mous cell carcinoma. Metastatic pleural effusion from lung cancer has a particularly poor prognosis [9]. Therefore, it deserves much attention to the effective treatment on this patient who achieved 15 months of complete clinical remission.

During the whole process, no anticancer chemotherapy and radiotherapy were given to this patient. So the anti-tuberculosis combined therapy of isoniazid, pyrazinamide, rifapentine and ethambutol is the only explanation for the elimination of pleural effusion and reduction of serum CEA level. So the susceptibility to anti-tuberculosis chemotherapy is not always helpful to confirm that the pleural effusion is definitely caused by tuberculous pleurisy. To date, little is known about whether the anti-tuberculosis medicines have effect on human carcinoma. However, ethambutol was reported to have a considerable antitumour activity against Lewis lung carcinoma [10]. Rifapentine is a cyclopentyl rifamycin, which kills tuberculosis bacteria by inhibiting bacterial RNA polymerase. Also, a study demonstrated the presence of dose-dependent pyrazinamide-mediated quantitative and qualitative changes in rats [11]. Based on these literatures, it is possible that some antitubercular drugs may have potential anticancer activity in some carcinomas, such as small-sized peripheral-lung squamous cell carcinoma with high CEA level. Therefore, further experiments and the understanding of such antitubercular agents as isoniazid, pyrazinamide, rifapentine and ethambutol are required for the better treatment in malignant pleural effusion.

Conclusion

We reported a rare case of the patient who had malignant pleural effusion caused by squamous cell carcinoma of unknown primary site and high level of CEA. The malignant pleural effusion was relieved for 15 months after treatment with the anti-tuberculosis combined therapy of isoniazid, pyrazinamide, rifapentine and ethambutol. Therefore, some anti-tubercular drugs may have potential anticancer activity in some carcinomas.

Consent

Written informed consent was obtained from the patient for publication of this case report.

Declaration

The authors declare that they have no competing interests.

Abbreviations

CT, Computed tomography; CEA, Carcinoembryonic antigen; PPD, purified protein derivative; PET-CT, positron emission tomography-computed tomography; SPECT, Single photon emission computed tomography.

Address correspondence to: Dr. Qihua Gu, Department of Respiratory Medicine, Xiangya Hospital affiliated to Central South University, Changsha City, Hunan, 410008, P.R. China. E-mail: guqihua@yahoo.com.cn

References

- [1] Sakr L, Maldonado F, Greillier L, Dutau H, Loundou A, Astoul P. Thoracoscopic assessment of pleural tumor burden in patients with malignant pleural effusion: prognostic and therapeutic implications. *J Thorac Oncol* 2011; 6: 592-597.
- [2] Basso SM, Mazza F, Marzano B, Santeufemia DA, Chiara GB, Lumachi F. Improved quality of life in patients with malignant pleural effusion following videoassisted thoracoscopic talc pleurodesis. Preliminary results. *Anticancer Res* 2012; 32: 5131-5134.
- [3] Haas AR, Sterman DH. Novel intrapleural therapies for malignant diseases. *Respiration* 2012; 83: 277-292.
- [4] Thomas R, Lee YC. Causes and management of common benign pleural effusions. *Thorac Surg Clin* 2013; 23: 25-42.
- [5] Light RW. Pleural effusions. *Med Clin North Am* 2011; 95: 1055-1070.
- [6] Pavlidis N, Briasoulis E, Hainsworth J, Greco FA. Diagnostic and therapeutic management of cancer of an unknown primary. *Eur J Cancer* 2003; 39: 1990-2005.
- [7] Tomita M, Shimizu T, Ayabe T, Yonei A, Onitsuka T. Carcinoembryonic antigen level in serum and pleural lavage fluid in non-small cell lung cancer. *Thorac Cardiovasc Surg* 2010; 58: 350-353.
- [8] Nagashima T, Sakao Y, Mun M, Ishikawa Y, Nakagawa K, Masuda M, Okumura S. A Clinicopathological Study of Resected Small-Sized Squamous Cell Carcinomas of the Peripheral Lung: Prognostic Significance of Serum Carcinoembryonic Antigen Levels. *Ann Thorac Cardiovasc Surg* 2013; Epub ahead of print.

Anti-tuberculosis therapy for malignant pleural effusion

- [9] Froudarakis ME. Pleural effusion in lung cancer: more questions than answers. *Respiration* 2012; 83: 367-376.
- [10] Coluccia M, Fanizzi FP, Giannini G, Giordano D, Intini FP, Lacidogna G, Loseto F, Mariggio MA, Nassi A, Natile G. Synthesis, mutagenicity, binding to pBR 322 DNA and antitumour activity of platinum(II) complexes with ethambutol. *Anticancer Res* 1991; 11: 281-287.
- [11] Bondarenko LB, Shayakhmetova GM, Byshevets TF, Kovalenko VM. Pyrazinamide potential effects on male rats DNA fragmentation, bone type I collagen amino acid composition, reproductive capability and posterity antenatal and postnatal development. *Acta Pol Pharm* 2012; 69: 843-850.