

Original Article

Aberrant staining patterns of E-cadherin and β -catenin: a potential diagnostic value for distinguishing vulvar intraepithelial neoplasia from non-neoplastic vulvar lesions

Bo Li¹, Qingfu Zhang², Ling Ouyang¹, Lin Jia¹, Xue Han¹, Yang Zhou¹, Xin Tong¹, Zixuan Song¹, Shulang Zhang¹, Xueshan Qiu²

¹Department of Obstetrics and Gynecology, Shengjing Hospital of China Medical University, Shenyang, 110004, China; ²Department of Pathology, the First Affiliated Hospital of China Medical University, Shenyang 110001, China

Received May 14, 2013; Accepted May 29, 2013; Epub June 15, 2013; Published July 1, 2013

Abstract: Histologically, vulvar intraepithelial neoplasm (VIN) is a proliferative disorder of the female vulva. No single clinical characteristic or pathognomonic feature facilitates the diagnosis of VIN, and the agreement between different pathologists on the diagnoses varies significantly. In this study, we evaluate the immunohistochemical expression patterns of E-cadherin and β -catenin in 22 patients with VIN and 10 patients with non-neoplastic vulvar lesions. Our results showed that membranous staining for E-cadherin and β -catenin was observed in squamous epithelial cells of all control non-neoplastic vulvar samples. Abnormal E-cadherin (17/19, 89.5%) and β -catenin (15/19, 78.9%) staining occurred more frequently in usual-type VIN than in non-neoplastic vulvar lesions ($P=0.000$ and $P=0.000$, respectively). However, in differentiated VIN, only 1 patient showed abnormal E-cadherin and β -catenin immunohistochemical expressions, which did not differ significantly. The abnormal expression of E-cadherin and β -catenin proteins might be useful in distinguishing VIN from non-neoplastic vulvar squamous epithelium lesions in problematic cases.

Keywords: β -catenin, E-cadherin, vulvar intraepithelial neoplasia, immunohistochemistry

Introduction

Vulvar intraepithelial neoplasias (VINs) are pre-cancerous changes defined as proliferative intraepithelial squamous lesions that display abnormal growth, exhibiting lack of cell maturation and crowding of cells [1]. The new classification divides VIN into 2 groups based on the incidence: usual and differentiated types [2]. The usual type occurs mainly in young women and is associated with human papilloma virus (HPV) infection, while the differentiated type is HPV-negative and occurs in older women. E-cadherin is a member of a multifunctional family of calcium-dependent, transmembrane glycoproteins. In vitro experiments have shown that downregulation of E-cadherin expression occurs in vulvar squamous cell carcinomas [3]. β -Catenins are closely related proteins that play a key role in cell adhesion, activation of

transcriptional factors, and in Wnt wingless-signaling pathways [4]. Recent studies showing the changes in the staining patterns have indicated that the E-cadherin/ β -catenin complex plays an important role in the development of normal cells and cancer [5]. However, the expression of the E-cadherin/ β -catenin complex in VIN is still unclear. Here, we tried to identify the immunohistochemical profile of VIN by using E-cadherin and β -catenin proteins, and thus, determine the potential diagnostic markers that can aid in distinguishing VIN from non-neoplastic vulvar lesions.

Materials and methods

Case selection

A total of 22 cases of VIN and 10 cases of non-neoplastic vulvar lesions were obtained from

Aberrant staining patterns of E-cadherin and β -catenin in VIN

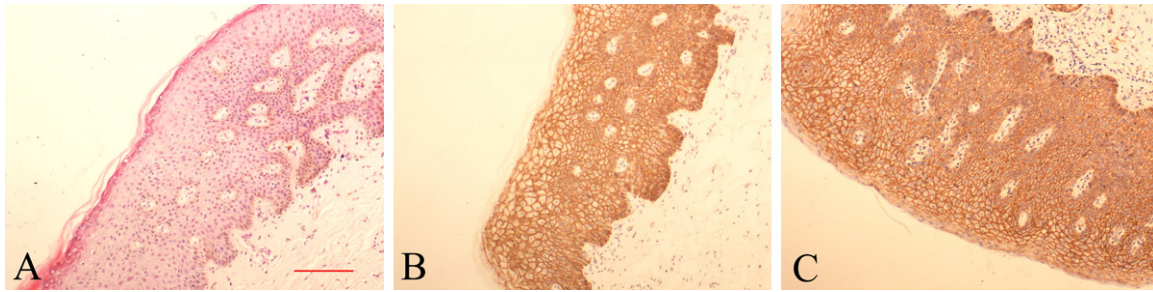


Figure 1. In the non-neoplastic vulvar lesions (A), E-cadherin (B) and β -catenin (C) stained intensely in a membranous distribution throughout the epithelium. (Original magnification $\times 100$, scale bar, 20 μm).

the Department of Obstetrics and Gynecology, Shengjing Hospital of China Medical University from January 2005 to April 2012. The study was approved by the Medical Research Ethics Committee of China Medical University and the informed consent was obtained from all patients. All of the enrolled patients underwent curative surgical resection without having chemotherapy or radiation therapy. According to the 2004 classification system of International Society for the Study of Vulvar Disease (ISSVD), Of the 22 patients, 19 (86.4%) had usual-type VIN and 3 (13.6%) had differentiated VIN. The patients mean age was 43 years (range 23-68). non-neoplastic vulvar lesions including lichen sclerosus ($n=5$), vulvar dystrophy ($n=3$), squamous cell hyperplasia ($n=2$), the patients mean age was 49 years (range 42-62).

Immunohistochemistry staining

All of the specimens were formalin-fixed and paraffin-embedded. Serial sections 4- μm thick were cut and mounted on aminopropyltriethoxysilane-coated glass slides for routine light microscopy examination and immunohistochemical (IHC) analysis. monoclonal mouse anti-human antibody directed against β -catenin and E-cadherin (Clone β -catenin-1 M3539 and E-cadherin clone NCH-38; diluted 1:100, DAKO company) were used for IHC analysis. The sections were incubated with the primary antibody at 4°C overnight and were then treated with 3% H_2O_2 and 5% rabbit serum at 37°C for 1 h. Next, the sections were incubated with the secondary antibody and streptavidin-peroxidase complex for 30 min (SP kit, MaiXin technologies company, China). Slides were visualized using 3,3-diaminobenzidine. Sections were stained with non-specific antibodies to provide a negative control for each reaction. Staining intensity

was scored semiquantitatively from 0 to 3, as previously described [6]. Specimens in which 90% or more of the cells showed well-localized membranous stainings were scored as (3+); those displaying reduced membranous immunoreactivity were scored as (2+); Heterogeneous stainings (cytoplasm staining; mixed cell membrane and cytoplasm stainings) were scored as (1+); no immunolabeling were scored as (0). Score 0-2 was considered abnormal E-cadherin and β -catenin expression. All the slides were re-assessed by 2 pathologists independent of the original pathology report.

Statistical analysis

SPSS18.0 software was employed to analyze all data. Statistical analysis was based on χ^2 test. $P<0.05$ is considered as statistical significance.

Results

E-cadherin is expressed on the membranes of normal epithelial cells

E-cadherin and β -catenin have strong positive distributions throughout the membranes of the squamous epithelium in all non-neoplastic vulvar lesions, while they showed negative expressions at the cytoplasm and nucleus (**Figure 1**). In the usual-type VIN (**Figure 2**), the abnormal expression of E-cadherin was 89.5% (17/19), including 12 cytoplasm stainings and 5 mixed cell/membrane and cytoplasm stainings, with no cases showing no immunolabeling or reduced membranous immunoreactivity, which was significantly higher than that among cases of non-neoplastic vulvar lesions. A similar staining pattern was observed in β -catenin expression, with 11 cases of cytoplasmic expressions and the others consisting of mixed cell/mem-

Aberrant staining patterns of E-cadherin and β -catenin in VIN

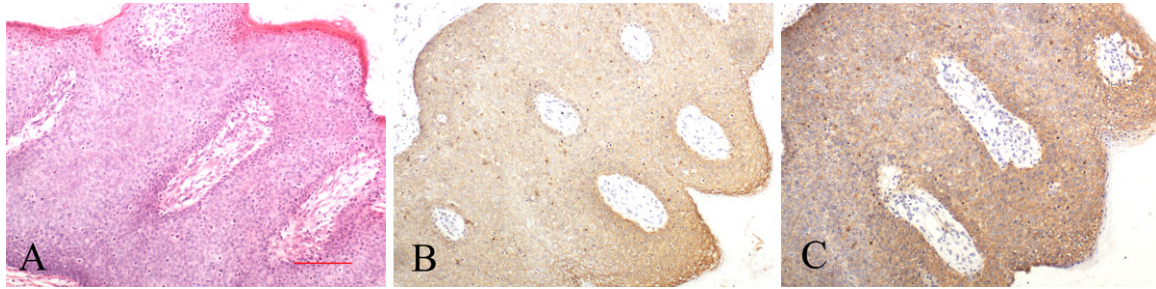


Figure 2. Vulvar intraepithelial neoplasia of the usual type (A), E-cadherin protein showed mixed cell membrane and cytoplasm stainings in Vulvar intraepithelial neoplasia of the usual type (B), β -Catenin protein showed cytoplasm staining usual VIN (C). (Original magnification $\times 100$, scale bar, 20 μm).

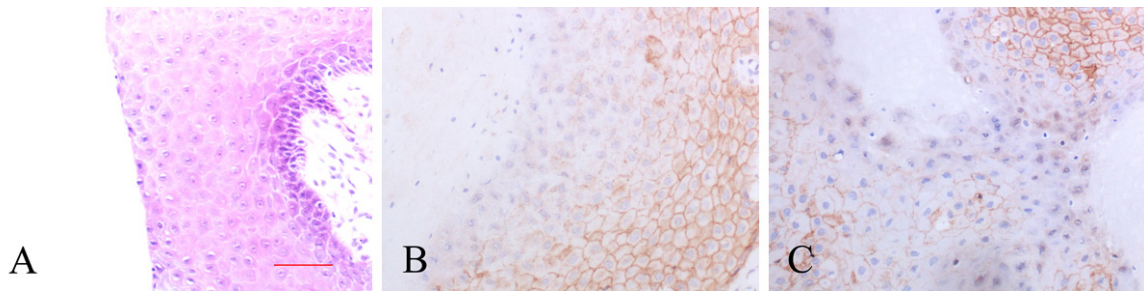


Figure 3. Vulvar intraepithelial neoplasia of the differentiated type, The epidermis is thickened, abnormal atypical keratinocytes in the context of a fully differentiated vulvar epithelium (A), Immunostaining for E-cadherin showed reduced expression in differentiated VIN (B). β -Catenin protein showed reduced expression in differentiated VIN (C). (Original magnification $\times 200$, scale bar, 10 μm).

Table 1. Relationship between the expressions of E-cadherin and β -catenin in VIN

E-cadherin expression	β -Catenin expression		Significance Correlation
	normal	abnormal	
Normal (n=4)	3 (75.0%)	1 (25.0%)	$\chi^2=5.615$, $p=0.046$;
Abnormal (n=18)	3 (16.7%)	15 (83.3%)	

expressions. The correlation between E-cadherin and β -catenin expressions was statistically significant ($X^2=5.615$, $p=0.046$; **Table 1**).

Discussion

brane and cytoplasm stainings. In differentiated-type VIN (**Figure 3**), only 1 patient showed reduced membranous immunoreactivity in E-cadherin and β -catenin, which did not differ significantly. Nuclear-positive β -catenin expression was not observed.

Correlation between E-cadherin and β -catenin abnormal expression in VIN

The results of E-cadherin and β -catenin co-expression in 22 VIN samples are shown in **Table 1**. Among the 18 samples with abnormal positive expressions of E-cadherin, 15 showed abnormal expressions of β -catenin, whereas among the 4 cases showing normal E-cadherin expressions, 3 showed normal β -catenin

VIN is characterized by the disruption of normal epithelial cell maturation with associated abnormal nuclei, cell crowding, and abnormal mitotic figures. Further, it has been sub-classified into different pathogenetic subtypes, namely classic (warty and basaloid) type, which accounts for approximately 90% of the cases, and differentiated (simplex) type, accounting for the remaining 10% [7]. However, the application of histologic criteria to diagnose VIN shows considerable inter-observer variability, and the diagnosis of VIN continues to be a challenge when it is based on the histopathologic criteria alone.

In recent years, p16INK4a(p16), p53, and Ki67 have been shown to aid in distinguishing VIN from normal vulvar epithelium. Additionally,

Aberrant staining patterns of E-cadherin and β -catenin in VIN

p16 has been shown to be negative in normal vulvar squamous epithelium and squamous cell hyperplasia, while in HPV-associated VIN, it shows diffuse positivity, even though it is negative in VIN not associated with HPV [8]. Moreover, the staining intensity, number of stained cells, and their distribution have been arbitrarily interpreted by different authors, thereby causing artificial errors. Immunostaining for p53 has been proposed as a valuable strategy for the identification of VIN [9]. However, a number of VIN cases have been shown to be immunonegative for p53. Moreover, Ki67 showed intense immunoreactivity in normal basal and parabasal cells, as well as high expression in inflammatory and reactive cases [10]. Considering all these observations, the immunostaining of P16, p53, and Ki67 is considered to be limited in confirming the diagnosis of VIN [11].

E-cadherin is a crucial transmembrane glycoprotein that is involved in mediating calcium-dependent cell-cell adhesion through homophilic interactions and controlling cell polarity and morphogenesis [12]. β -Catenin is a double-functional molecule in the E-cadherin-catenin complex. The E-cadherin/ β -catenin complex is known to regulate cellular functions such as adhesion, proliferation, differentiation, and survival. Moreover, the aberrant expression of the E-cadherin/ β -catenin complex has been implicated in the oncogenesis of carcinomas [13]. To our knowledge, our results showed for the first time the expression of E-cadherin and β -catenin in VIN and compared it with the results of non-neoplastic squamous epithelial lesions of the vulva. The condition is reflective of an early and pre-invasive event in the neoplastic transformation of vulvar squamous epithelia during which E-cadherin and β -catenin accumulate in the cells. The abnormal expression patterns of E-cadherin and β -catenin in VIN can be used as markers to distinguish between proliferating squamous epithelia lesions or to predict a potential diagnostic value of intraepithelial neoplasia. The concomitant use of E-cadherin/ β -catenin complex and P16, P53, and Ki67 immunostains might be effective for the diagnosis of VIN.

Disclosure of conflict of interest

The authors declare that they have no competing interests.

Consent from patients was received from the patient before publication.

Address correspondence to: Dr. Ling Ouyang, Department of Obstetrics and Gynecology, Shengjing Hospital of China Medical University, Shenyang 110004, China. E-mail: ouyangl1964@126.com

References

- [1] Kennedy CM, Boardman LA. New approaches to external genital warts and vulvar intraepithelial neoplasia. *Clin Obstet Gynecol* 2008; 51: 518-526.
- [2] Terlouw A, Blok LJ, Helmerhorst TJ, van Beurden M. Premalignant epithelial disorders of the vulva: squamous vulvar intraepithelial neoplasia, vulvar Paget's disease and melanoma in situ. *Acta Obstet Gynecol Scand* 2010; 89: 741-748.
- [3] Zannoni GF, Prisco MG, Vellone VG, De Stefano I, Scambia G, Gallo D. Changes in the expression of oestrogen receptors and E-cadherin as molecular markers of progression from normal epithelium to invasive cancer in elderly patients with vulvar squamous cell carcinoma. *Histopathology* 2011; 58: 265-275.
- [4] Valenta T, Hausmann G, Basler K. The many faces and functions of β -catenin. *EMBO J* 2012; 31: 2714-2736.
- [5] Al Moustafa AE, Kassab A, Darnel A, Yasmeen A. High-risk HPV/ErbB-2 interaction on E-cadherin/catenin regulation in human carcinogenesis. *Curr Pharm Des* 2008; 14: 2159-2172.
- [6] Jawhari A, Jordan S, Poole S, Browne P, Pignatelli M, Farthing MJ. Abnormal immunoreactivity of the E-cadherin-catenin complex in gastric carcinoma: relationship with patient survival. *Gastroenterology* 1997; 112: 46-54.
- [7] McCluggage WG. Recent developments in vulvovaginal pathology. *Histopathology* 2009; 54: 156-173.
- [8] O'Neill CJ, McCluggage WG. p16 expression in the female genital tract and its value in diagnosis. *Adv Anat Pathol* 2006; 13: 8-15.
- [9] Hantschmann P, Sterzer S, Jeschke U, Friese K. P53 expression in vulvar carcinoma, vulvar intraepithelial neoplasia, squamous cell hyperplasia and lichen sclerosus. *Anticancer Res* 2005; 25: 1739-1745.
- [10] Brustmann H, Naudé S. Expression of topoisomerase II α , Ki-67, proliferating cell nuclear antigen, p53, and argyrophilic nucleolar organizer regions in vulvar squamous lesions. *Gynecol Oncol* 2002; 86: 192-199.
- [11] Medeiros F, Nascimento AF, Crum CP. Early vulvar squamous neoplasia: advances in classification, diagnosis, and differential diagnosis. *Adv Anat Pathol* 2005; 12: 20-26.

Aberrant staining patterns of E-cadherin and β -catenin in VIN

- [12] Canel M, Serrels A, Frame MC, Brunton VG. E-cadherin-integrin crosstalk in cancer invasion and metastasis. *J Cell Sci* 2013; 126: 393-401.
- [13] Tian X, Liu Z, Niu B, Zhang J, Tan TK, Lee SR, Zhao Y, Harris DC, Zheng G. E-cadherin/ β -catenin complex and the epithelial barrier. *J Biomed Biotechnol* 2011; 2011: 567305.