

Original Article

PTK7 protein is decreased in epithelial ovarian carcinomas with poor prognosis

Haiyan Wang^{1*}, Guimei Li^{2*}, Yongxiang Yin³, Jianjun Wang¹, Hai Wang¹, Wei Wei¹, Qing Guo¹, Henghui Ma¹, Qunli Shi¹, Xiaojun Zhou¹, Jiandong Wang^{1*}

¹Department of Pathology, Jinling Hospital, Southern Medical University, Nanjing 210002, China; ²Department of Pathology, Jingdu Hospital, Nanjing 210002, China; ³Department of Pathology, Wuxi Maternal and Child Health-Care Hospital, Wuxi 214000, China. *Equal contributors.

Received September 12, 2014; Accepted October 31, 2014; Epub October 15, 2014; Published November 1, 2014

Abstract: Epithelial ovarian cancer is the most common tumor of ovary. PTK7 plays an important role in tumors. Till now, there is no report about the role of PTK7 in ovarian epithelial neoplasms. This study aims to investigate the expression of PTK7 protein in epithelial ovarian tumors, and its relationship with clinical pathological characteristics. In this study, immunohistochemical staining was used to detect the expression of PTK7 protein in 14 samples of normal fallopian tube epithelium and 204 cases of epithelial ovarian tumor. The relationship between the expression of PTK7 and pathological indicators was statistically analyzed. Kaplan-Meier survival function was used to analyze the prognosis. The expression of PTK7 was found in 92.86% (13/14) of normal fallopian tube epithelium and 45.10% (92/204) of epithelial ovarian tumor tissues. The expression level of PTK7 was significantly decreased from the benign, the intermediate type, to malignant ovarian epithelial tumors ($P < 0.001$), and decreased from the normal control group to serous carcinomas ($P < 0.001$). The expression of PTK7 was significantly different in type I and type II epithelial ovarian carcinomas ($P < 0.001$). PTK7 protein expression was associated with clinical stages ($P = 0.038$) and metastases ($P = 0.038$) in ovarian borderline serous tumors. PTK7 protein expression was associated with clinical stages ($P = 0.011$), WHO grading ($P = 0.004$), and MDACC grading ($P < 0.001$) in ovarian serous carcinomas. The survival analysis showed that patients with negative expression of PTK7 protein had a poorer outcome than those with positive expression ($P = 0.017$). These results indicate that PTK7 protein may be a tumor suppressor and a potential prognostic marker in ovarian serous carcinomas.

Keywords: Epithelial tumors of the ovary, protein tyrosine kinase 7, clinical pathological characteristics, prognosis

Introduction

Ovarian cancer is one of the most common and lethal cancers in women. Epithelial ovarian cancers comprise the vast majority of ovarian malignancies, which are most commonly serous carcinomas [1]. In 2013, about 22,240 new cases diagnosed and 14,030 deaths from ovarian cancer occurred in the United States [2]. As ovarian cancer is often asymptomatic in its early stages or presents with vague symptoms mimicking extra-ovarian disease, more than two thirds of the patients with ovarian cancer were diagnosed at advanced stage and the overall survival is very poor. Despite advances in surgery and chemotherapy, overall cure rate has remained approximately 30%. The poor clinical outcome mainly comes from the high

percentage of cases being diagnosed at an advanced stage and the frequent emergence of chemoresistance. An improved understanding of the molecular mechanisms underlying ovarian cancer may lead to the development of more effective therapeutic strategies.

The receptor protein tyrosine kinase 7 (PTK7), known as colon carcinoma kinase 4 (CCK4) [3] was first identified as a protein overexpressed in colon cancer cell lines [4]. The PTK7 gene organized into 20 exons [5], is a receptor tyrosine kinase-like molecule containing an extra-cellular domain with seven immunoglobulin-like loops, a transmembrane domain, and a defective tyrosine kinase domain that resembles a catalytic domain but lacks catalytic activity [6]. PTK7 is classified as a so-called pseudokinase,

Table 1. Relationship between the patient's histologic subtypes and PTK7 expression in 204 epithelial ovarian carcinomas

Cell type	No.	PTK7		Rate (%)	X ²	P value
		Negative	Positive			
A. Benign tumor						
Endometrioid cyst	11	2	9	81.81	1.000	
Serous cyst	6	1	5	83.33		
Mucinous cyst	6	1	5	83.33		
	23	4	19	82.61		
B. The intermediate type						
Borderline serous tumor	51	28	23	45.10		
	51	28	23	45.10		
C. Malignant tumor						
Serous carcinoma	97	69	28	28.87	0.000*	
Mucinous carcinoma	5	3	2	40.00		
Endometrioid carcinoma	13	4	9	69.23		
Clear-cell carcinoma	15	4	11	73.33		
	130	80	50	38.46		
Total	204	112	92	45.10	15.383	0.000*

*P < 0.001.

while no specific ligand has yet been identified [7]. Pseudokinase PTK7 is a Wnt co-receptor and an essential regulator of planar cell polarity (PCP) and directional cell motility in vertebrate development and embryogenesis [8-10]. Other data suggest that the stabilized full-length membrane PTK7 up-regulates the Akt and c-Jun pathways, and down-regulates the p53 pathways leading to the cell survival signaling [11]. Full-length PTK7 also suppresses ERK and CREB-mediated gene expression and cell motility. The proteolysis of PTK7 ectodomain (Ig1-Ig7) by MT1-MMP and ADAMs generates the soluble sPTK7 form. The subsequent cleavage of the C-terminal membrane PTK7 fragment by γ -secretase releases the intracellular domain (cPTK7). The soluble sPTK7 species binds the full-length membrane PTK7 and activates the RhoA [12] and p38a pathways, which regulate the actin cytoskeleton and the expression of the migratory genes, including IL1B. The intracellular PTK7 domain fragment, cPTK7, enters the cell nucleus and induces the RAS/p90RSK/CREB signaling resulting in the CREB and ATF1 phosphorylation at Ser133 and Ser63, respectively, and the expression of the pro-migratory genes, including cadherin-11 (CDH11).

The expression of PTK7 is frequently deregulated in cancers. Up-regulation of PTK7 was

known in various cancers including colon cancer [3, 13], gastric cancer [14], lung cancer [15, 16], acute myeloid leukemia [17], breast cancer [18], esophageal squamous cell carcinoma [19], liposarcoma samples of all five subtypes and in liposarcoma cell lines [20]. There is no report about the role of PTK7 in ovarian epithelial neoplasms. This study aims to investigate the expression of PTK7 in epithelial ovarian tumor.

Material and methods

Patients and clinicopathologic variables

The study cohort consisted of 204 epithelial ovarian tumor tissue samples and 14 normal fallopian tube tissue samples obtained from patients who underwent surgery for benign gynecological diseases from the years 2001 to 2013 at Jinling Hospital, Nanjing, China (**Table 1**). All hematoxylin-and eosin-stained slides were reviewed by two gynecological pathologists to verify the diagnosis, histological grade, and stages. Pathological stage and histological subtype were determined for each surgical specimen according to 2002 International Federation of Gynecology and Obstetrics (FIGO) criteria, and Pathology and Genetics Tumors of the Breast and Female Genital Organs (World Health Organization, WHO 2003). A two-tier (low-grade and high-grade) system was used to define the differentiation of ovarian serous carcinomas. A dualistic model proposed by Nik [21] was used to groups various types of epithelial ovarian cancers into two broad categories, designated type I and type II. The record of patients reviewed in the context of clinicopathological information, including 51 cases of serous tumors and 97 cases of serous carcinoma. 83 patients with serous carcinoma were followed up until March 2012. The records of patients who were alive at follow-up or who did not die of disease were considered to be censored. None of the patients received preoperative chemotherapy or radiation therapy. This

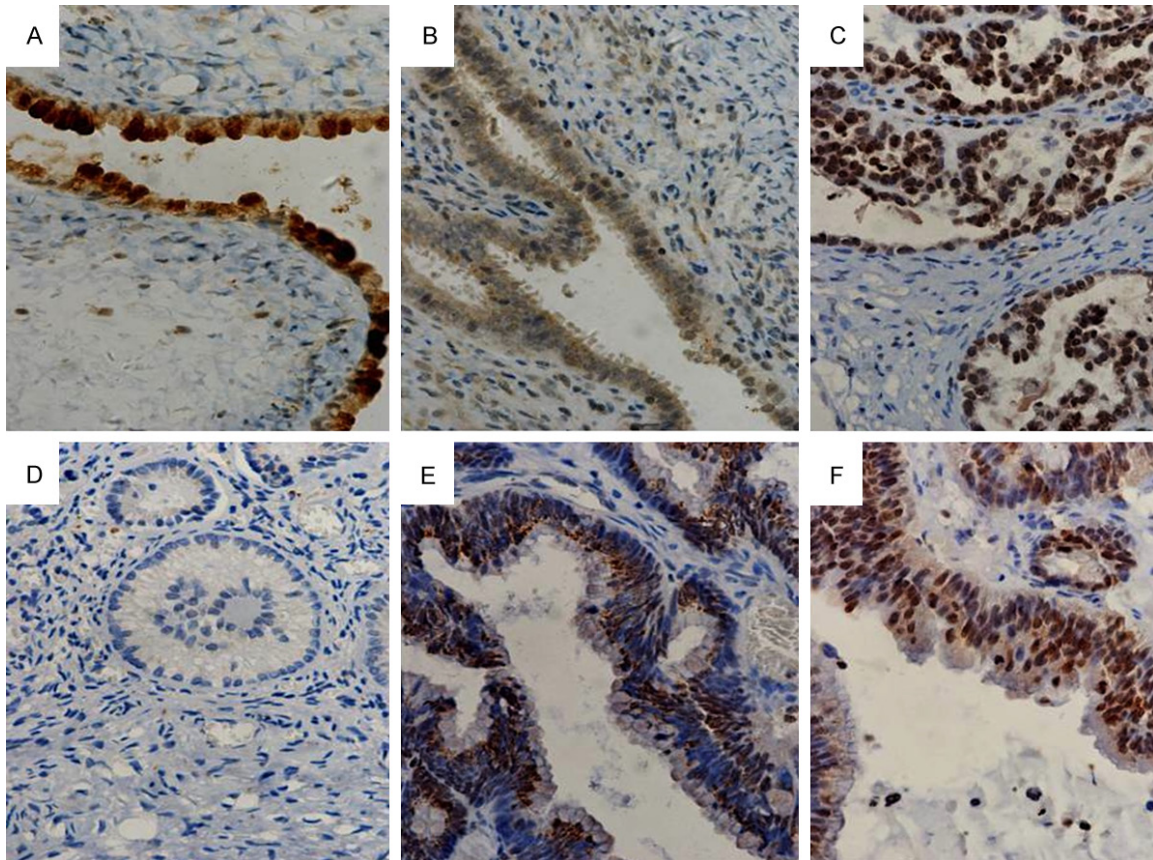


Figure 1. A: Expression of PTK7 was strongly positive expression in mucinous cyst; B: The expression of PTK7 was weakly positive expression in endometrioid cyst; C: The expression of PTK7 was strongly positive in endometrioid carcinoma; D: The expression of PTK7 was negative in ovarian endometrioid carcinoma; E: The expression of PTK7 was strongly positive in mucinous carcinoma; F: The expression of PTK7 was strongly positive in clear-cell carcinoma; (EnVision $\times 400$).

investigation was performed after approval was obtained from the Ethics Committee of Jinling Hospital. Informed consent was obtained from each patient.

Immunohistochemistry

Sections from surgical specimens had been fixed in 10% formalin and embedded in paraffin and were used for immunohistochemical staining according to a standard method. Briefly, each 4- μ m tissue section was deparaffinized and rehydrated. After rehydration through a graded ethanol series, the sections were autoclaved in 10 mM citrate buffer (pH 6.0) at 120°C for 2 min for antigen retrieval, then cooled to 30°C and washed with phosphate-buffered saline (PBS, pH 7.3). After endogenous peroxidase had been quenched with aqueous 3% H_2O_2 for 10 minutes and washed with PBS, the sections were incubated at 4°C overnight with primary rabbit polyclonal anti-PTK7 anti-

bodies (Abgent, 9765 Clairemont Mesa Blvd, Suite C, San Diego, CA 92124) at a dilution of 1:100 and then washed with PBS. Next, the sections were incubated with secondary antibody (Dako REAL EnVision Detection System, Dako, UK) for 20 min at room temperature. This was followed by the color development with 3, 3'-diaminobenzidine solution for 2 min and counterstained with hematoxylin for 3 min. After counterstaining, slides were washed with PBS, dehydrated, cleared in xylene, and mounted in neutral balsam.

The PTK7 staining of cytoplasmic and nucleus was independently evaluated for immunoreactivity by two pathologists who were double-blinded to clinical data according to the scoring criteria described previously. The evaluation was analyzed according to both the percentage of positive cells and the intensity of cytoplasmic and nucleus staining. PTK7 expression was assessed for intensity (0 = no staining, 1 =

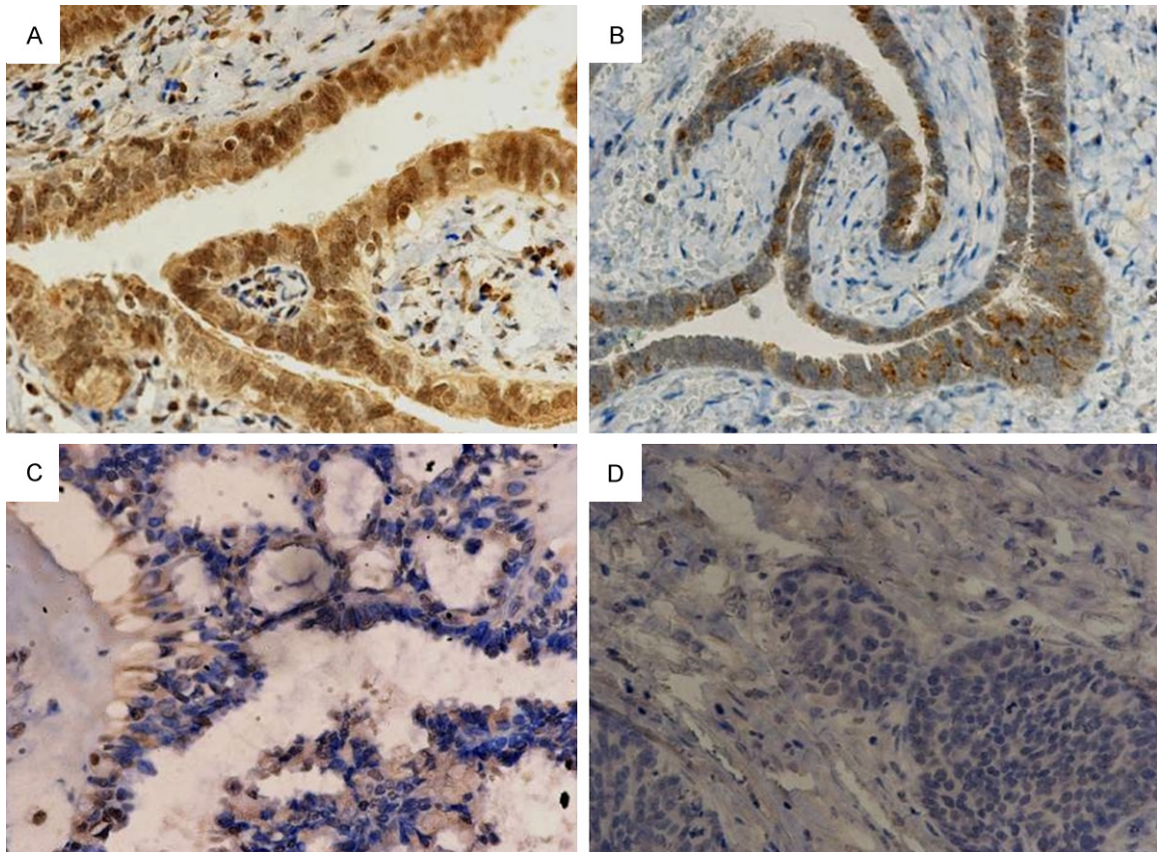


Figure 2. A: The expression of PTK7 was strongly positive expression in normal fallopian tube epithelium; B: The expression of PTK7 was strongly positive expression in benign serous ovarian tumors; C: The expression of PTK7 was weakly positive in borderline serous ovarian tumors; D: The expression of PTK7 was negative in ovarian serous carcinoma.

Table 2. Percentage of expression of PTK7 in type I and type II epithelial ovarian carcinomas

Type	No	PTK7		Rate (%)	χ^2	P value
		Negative	Positive			
Type I tumors	48	15	33	68.75	29.459	0.000*
Low-grade serous carcinoma	21	7	14			
Low-grade endometrioid carcinoma	7	1	6			
Clear cell carcinoma	15	4	11			
Mucinous carcinoma	5	3	2			
Type II tumors	82	65	17	20.73		
High-grade serous carcinoma	76	62	14			
High-grade endometrioid carcinoma	6	3	3			
Total	130	80	50	38.46		

* $P < 0.001$.

weak, 2 = moderate, 3 = strong) and the percentage of positive cells (0 = 0%, 1 ≤ 10%, 2 = 10% to 50%, 3 = 51% to 80%, 4 ≥ 80% positive cells) as defined previously. The scores for intensity and percentage were multiplied and a cut-off of 6 was used.

Statistical analysis

Chi-square test (Fisher's exact test) was used to assess the associations of PTK7 protein expression with clinicopathological variables. Survival curves were constructed using the

Decreased expression of PTK7 in ovarian carcinomas

Table 3. Percentage of expression of PTK7 in epithelium of normal oviduct, benign, borderline, and malignant serous carcinomas

Group	N	PTK7		Rate (%)	χ^2	P value
		Negative	Positive			
Contrast group	14	1	13	92.86	0.521 (a/b) 10.140 21.507	0.001 (a/c) 0.000* (a/d)
Benign group	6	1	5	83.33		0.102 (b/c)
Borderline group	51	28	23	45.10	3.900	0.048 (c/d)
Malignant group	97	69	28	28.87		0.012 (b/d)

* $P < 0.001$.

Table 4. Comparison of the general characteristics of the in negative and the positive of PTK7 in ovarian borderline serous carcinomas

Characteristic	N	PTK7		Rate (%)	χ^2	P value
		Negative	Positive			
Clinical stages						
I	32	14	18	56.25		
II, III	19	14	5	26.32	4.314	0.038*
Metastases						
Yes	19	14	5	26.32		
No	32	14	18	56.25	4.314	0.038*
The position of tumors						
Single	36	17	19	52.78		
Double	15	11	4	26.67	2.916	0.088
Age						
≤40	35	19	16	45.71		
>40	16	9	7	43.75	0.017	0.896

* $P < 0.05$.

Kaplan-Meier method and the differences between the curves were compared by the log-rank test. P -values < 0.05 (two-sided) were considered statistically significant. All analyses were performed by SPSS software (version 16.0, Chicago, IL).

Results

PTK7 expression in epithelial ovarian tumors and its correlation with histological subtypes

Positive staining was noted in 45.10% (92/204) of epithelial ovarian tumor samples. As shown in **Figure 1A-F** and **Figure 2A-D**, PTK7 staining was localized predominantly in the cytoplasm and some in nucleus. The expression of PTK7 protein was significantly decreased from the benign to malignant ovarian epithelial tumors ($P < 0.001$). PTK7 protein expression was vari-

ously expressed according to the histological subtype in epithelial ovarian carcinomas ($P < 0.001$) and was predominantly expressed in benign epithelial ovarian tumors in our study (**Table 1**). The expression of PTK7 was significantly different in type I and type II epithelial ovarian carcinomas ($P < 0.001$). The expression of PTK7 was more frequently expressed in type I than type II (**Table 2**).

PTK7 Expression in ovarian serous tumor and normal fallopian tube

The positive rate of PTK7 in normal fallopian tube epithelial expression was 92.86% (13/14), in benign serous tumors was 83.33% (5/6), in the borderline serous tumor expression was 45.10% (23/51), and in serous carcinoma was 28.87% (28/97) respectively. The expression of PTK7 protein was significantly decreased from normal control group, benign,

borderline and to malignant ovarian serous tumors ($P < 0.001$) (**Figure 2A-D**). And in the two comparisons, the other groups were statistically significant except for benign serous tumors and serous tumors (**Table 3**).

PTK7 expression in ovarian borderline serous tumors and its correlation with clinicopathological features

The relationship between PTK7 expression and clinicopathological parameters was depicted in **Table 4**. The association of PTK7 expression and clinicopathological features was analyzed statistically and demonstrated a direct relationship between PTK7 expression and clinical stages and metastases ($P = 0.038$ and 0.038), while PTK7 expression and other features failed to reach statistical significance in our study (**Table 4**).

Table 5. Comparison of the general characteristics of serous ovarian carcinomas with negative and positive expression of PTK7

Characteristic	N	PTK7		Rate (%)	χ^2	P value
		Negative	Positive			
Clinical stages						
Early (I, II)	19	9	10	52.63		
Advanced (III, IV)	78	60	18	23.07	6.499	0.011*
Who's grades						
1, 2	28	16	12	42.86		
3	55	47	8	14.55	8.131	0.004*
No data	14					
MDACC's grade						
Low	21	7	14			
High	76	62	14		18.651	0.000*
Metastasis						
Yes	43	32	11	25.58		
No	54	37	17	31.48	0.406	0.524
Number of tumor						
Single	41	27	14	34.15		
Double	56	42	14	25.00	0.964	0.326
Maximum diameter of the tumor (cm)						
≤5	31	23	8	25.80		
5-10	25	21	4	16.00		
≥10	18	13	5	27.77	1.062	0.588
No data	23					
Age						
≤50	39	27	12	30.78		
50-55	23	15	8	34.78		
≥55	35	27	8	22.86	1.076	0.584

* $P < 0.05$.

PTK7 expression in serous ovarian cancers and its correlation with clinicopathological features

The relationship between PTK7 expression and clinicopathological parameters was depicted in **Table 5**. The association of PTK7 expression and clinicopathological features was analyzed statistically and demonstrated a positive relationship between PTK7 expression and Clinical stages, WHO grading and MDACC grading ($P = 0.011$, 0.004 , and <0.001), while PTK7 expression and other features failed to reach a statistical significance in our study (**Table 5**).

Association of PTK7 expression with the overall survival among serous ovarian cancer patients

Using the follow-up data of the 83 patients in conjunction with the results from the PTK7 IHC

staining experiments, we showed that positive expression cases had a significantly favorable overall survival (OS) than negative cases ($P = 0.017$) (**Figure 3**).

Discussion

Recent literatures revealed the function of PTK7 and its signaling pathway both during development and cancer progression. Most studies have indicated that PTK7 acts as an important regulator of both non-canonical Wnt/PCP and canonical Wnt/ β -catenin signaling to promote the migration and proliferation of tumor cells. Meng *et al* found that PTK7 inhibited apoptosis of colon cancer cells by mitochondrial pathway [22]. Shin *et al* found that the reduction of PTK7 expression inhibits tube formation, migration, and invasion of endothelial cells and angiogenesis [23]. PTK7 was known as an oncogene in various cancers.

In this study, we evaluated the expression of PTK7 protein and the relationship between PTK7 status and clinical features in a relatively large cohort of patients with epithelial ovarian tumors. Our results show that the expression of PTK7 protein significantly decreased from the benign to malignant ovarian epithelial tumors including serous ovarian tumors. In addition, the current study showed that the expression of PTK7 was more frequently expressed in the early clinical and no transfer of borderline ovarian serous tumors (**Table 4**). The expression of PTK7 was more frequent positive in the early clinical and well-differentiated serous ovarian cancer (**Table 5**). Our study was designed to include a large sample size to decrease bias of the results, according to the reporting of expression profiling of the ovarian surface kinome [24]. In Pejovic's study, PTK7 displayed a distinctive linear decrease trend in expression from normal, high risk (two or more first-degree relatives with ovarian and/or breast cancer or

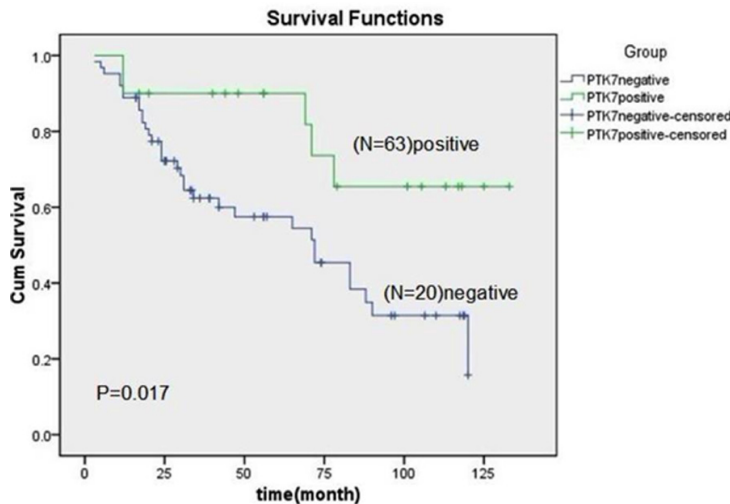


Figure 3. Comparison of the Kaplan-Meier survival curves between two groups ($P < 0.05$).

they had a personal history of breast cancer and a first-degree relative with breast and/or ovarian cancer), and malignant epithelium by using semiquantitative reverse transcription polymerase chain reaction and tissue array of 202 ovarian cancer samples [24]. Our study showed that the expression of PTK7 protein decreased and was in consistence with down-regulation of PTK7 mRNA reported by Pejovic *et al.* Based on these results, we postulate that PTK7 may play a role of tumor suppressor in epithelial tumors of the ovary. Interestingly, the deletion of chromosome 6p, where the PTK7 gene is located (6p12.2-21.1) [25], was also found in certain cancers including breast cancer [26]. The molecular mechanisms of decreased expression in ovarian epithelial tumors should to be explored in next study.

On the basis of a series of morphologic and molecular genetic studies, Nik *et al* proposed a dualistic model that divides the various histological types of EOCs into two broad categories designated type I and type II [21]. Type I tumors comprise low-grade serous, low-grade endometrioid, mucinous, and clear cell carcinomas. Type II tumors are composed of high-grade serous, high-grade endometrioid, undifferentiated carcinomas, and malignant mixed mesodermal tumors (carcinosarcomas). Our study showed that the positive expression of PTK7 was more frequent in type I than in type II. PTK7 may be a molecular marker for studying the origin and a dualistic model of ovarian cancers.

Lin *et al* reported that PTK7 expression was significantly related to the favorable overall survival and disease free survival of gastric cancer [27]. In the present study, the survival analysis showed that patients with negative expression of PTK7 protein had a poorer outcome than those with positive expression. Our data indicate that PTK7 (**Figure 3**) may be a potential prognostic marker in ovarian serous carcinoma.

In summary, we found that the PTK7 expression was significantly relevant to histological classification of epithelial ovarian cancers, the clinical stages and metastasis of borderline ovarian

serous tumors. The expression of PTK7 protein significantly decreased from the benign, borderline and to malignant ovarian epithelial tumors as well as from normal control group, benign, borderline and to malignant ovarian serous tumors. PTK7 acts as a tumor suppressor in epithelial tumors of the ovary and it may be a potential prognostic marker in ovarian serous carcinomas.

Acknowledgements

This work was supported in part by the National Natural Science Foundation of China (81371611, 81171391, and 81372743) and the National Basic Research Priorities Program 973 Project (2014CB744504) from the Ministry of Science and Technology of China. Wuxi City Health Bureau research projects (MD201309).

Disclosure of conflict of interest

None.

Address correspondence to: Dr. Jiandong Wang, Department of Pathology, Jinling Hospital, Southern Medical University, Nanjing 210002, China. E-mail: jd_wang@outlook.com

References

- [1] Jemal A, Bray F, Center MM, Ferlay J, Ward E and Forman D. Global cancer statistics. *CA Cancer J Clin* 2011; 61: 69-90.
- [2] Siegel R, Naishadham D and Jemal A. Cancer statistics, 2013. *CA Cancer J Clin* 2013; 63: 11-30.

- [3] Mossie K, Jallal B, Alves F, Sures I, Plowman GD and Ullrich A. Colon carcinoma kinase-4 defines a new subclass of the receptor tyrosine kinase family. *Oncogene* 1995; 11: 2179-2184.
- [4] Lee ST, Strunk KM and Spritz RA. A survey of protein tyrosine kinase mRNAs expressed in normal human melanocytes. *Oncogene* 1993; 8: 3403-3410.
- [5] Jung JW, Ji AR, Lee J, Kim UJ and Lee ST. Organization of the human PTK7 gene encoding a receptor protein tyrosine kinase-like molecule and alternative splicing of its mRNA. *Biochim Biophys Acta* 2002; 1579: 153-163.
- [6] <Organization of the human PTK7 gene encoding a receptor protein.pdf>.
- [7] Lin Y, Zhang LH, Wang XH, Xing XF, Cheng XJ, Dong B, Hu Y, Du H, Li YA, Zhu YB, Ding N, Du YX, Li JY and Ji JF. PTK7 as a novel marker for favorable gastric cancer patient survival. *J Surg Oncol* 2012; 106: 880-886.
- [8] Lu X, Borchers AG, Jolicoeur C, Rayburn H, Baker JC, Tessier-Lavigne M. PTK7/CCK-4 is a novel regulator of planar cell polarity in vertebrates. *Nature* 2004; 430: 93-8.
- [9] Yen WW, Williams M, Ammasi Periasamy MC, Burdsal C, Keller R, Lu X and Sutherland A. PTK7 is essential for polarized cell motility and convergent extension during mouse gastrulation. *Development* 2009; 136: 2039-2048.
- [10] Hayes M, Naito M, Daulat A, Angers S and Ciruna B. Ptk7 promotes non-canonical Wnt/PCP-mediated morphogenesis and inhibits Wnt/ β -catenin-dependent cell fate decisions during vertebrate development. *Development* 2013; 140: 1807-1818.
- [11] Golubkov VS and Strongin AY. Downstream signaling and genome-wide regulatory effects of PTK7 pseudokinase and its proteolytic fragments in cancer cells. *Cell Commun Signal* 2014; 12: 15.
- [12] Golubkov VS, Chekanov AV, Cieplak P, Aleshin AE, Chernov AV, Zhu W, Radichev IA, Zhang D, Dong PD and Strongin AY. The Wnt/planar cell polarity protein-tyrosine kinase-7 (PTK7) is a highly efficient proteolytic target of membrane type-1 matrix metalloproteinase: implications in cancer and embryogenesis. *J Biol Chem* 2010; 285: 35740-35749.
- [13] Saha S, Bardelli A, Buckhaults P, Velculescu VE, Rago C, St Croix B, Romans KE, Choti MA, Lengauer C, Kinzler KW and Vogelstein B. A phosphatase associated with metastasis of colorectal cancer. *Science* 2001; 294: 1343-1346.
- [14] Gorringe KL, Boussioutas A and Bowtell DD. Novel regions of chromosomal amplification at 6p21, 5p13, and 12q14 in gastric cancer identified by array comparative genomic hybridization. *Genes Chromosomes Cancer* 2005; 42: 247-259.
- [15] Endoh H, Tomida S, Yatabe Y, Konishi H, Osada H, Tajima K, Kuwano H, Takahashi T and Mitsudomi T. Prognostic model of pulmonary adenocarcinoma by expression profiling of eight genes as determined by quantitative real-time reverse transcriptase polymerase chain reaction. *J Clin Oncol* 2004; 22: 811-819.
- [16] Chen R, Khatri P, Mazur PK, Polin M, Zheng Y, Vaka D, Hoang CD, Shrager J, Xu Y and Vicent S. A Meta-analysis of Lung Cancer Gene Expression Identifies PTK7 as a Survival Gene in Lung Adenocarcinoma. *Cancer Res* 2014; 74: 2892-2902.
- [17] Müller-Tidow C, Schwäble J, Steffen B, Tidow N, Brandt B, Becker K, Schulze-Bahr E, Halfter H, Vogt U and Metzger R. High-throughput analysis of genome-wide receptor tyrosine kinase expression in human cancers identifies potential novel drug targets. *Clin Cancer Res* 2004; 10: 1241-1249.
- [18] Gärtner S, Gunesch A, Knyazeva T, Wolf P, Högel B, Eiermann W, Ullrich A, Knyazev P and Ataseven B. PTK 7 Is a Transforming Gene and Prognostic Marker for Breast Cancer and Nodal Metastasis Involvement. *PLoS One* 2014; 9: e84472.
- [19] Shin WS, Kwon J, Lee HW, Kang MC, Na HW, Lee ST and Park JH. Oncogenic role of protein tyrosine kinase 7 in esophageal squamous cell carcinoma. *Cancer Sci* 2013; 104: 1120-1126.
- [20] Gobble RM, Qin LX, Brill ER, Angeles CV, Ugras S, O'Connor RB, Moraco NH, DeCarolis PL, Antonescu C and Singer S. Expression profiling of liposarcoma yields a multigene predictor of patient outcome and identifies genes that contribute to liposarcomagenesis. *Cancer Res* 2011; 71: 2697-2705.
- [21] Nik NN, Vang R, Shih Ie M and Kurman RJ. Origin and pathogenesis of pelvic (ovarian, tubal, and primary peritoneal) serous carcinoma. *Annu Rev Pathol* 2014; 9: 27-45.
- [22] Meng L, Sefah K, O'Donoghue MB, Zhu G, Shangguan D, Noorali A, Chen Y, Zhou L and Tan W. Silencing of PTK7 in colon cancer cells: caspase-10-dependent apoptosis via mitochondrial pathway. *PLoS One* 2010; 5: e14018.
- [23] Shin WS, Maeng YS, Jung JW, Min JK, Kwon YG and Lee ST. Soluble PTK7 inhibits tube formation, migration, and invasion of endothelial cells and angiogenesis. *Biochem Biophys Res Commun* 2008; 371: 793-798.
- [24] Pejovic T, Pande NT, Mori M, Mhawech-Fauceglia P, Harrington C, Mongoue-Tchokote S, Dim D, Andrews C, Beck A, Tarumi Y, Djilas J, Capuccini F, Caballero O, Huang J, Levy S, Tsiamouri A, Cain J, Bagby GC, Strausberg RL,

Decreased expression of PTK7 in ovarian carcinomas

- Simpson AJ and Odunsi KO. Expression profiling of the ovarian surface kinome reveals candidate genes for early neoplastic changes. *Transl Oncol* 2009; 2: 341-349.
- [25] Banga SS, Ozer HL, Park SK and Lee ST. Assignment of PTK7 encoding a receptor protein tyrosine kinase-like molecule to human chromosome 6p21.1-->p12.2 by fluorescence in situ hybridization. *Cytogenet Cell Genet* 1997; 76: 43-44.
- [26] Piao Z, Lee KS, Kim H, Perucho M and Malkhosyan S. Identification of novel deletion regions on chromosome arms 2q and 6p in breast carcinomas by amplotype analysis. *Genes Chromosomes Cancer* 2001; 30: 113-122.
- [27] Lin Y, Zhang LH, Wang XH, Xing XF, Cheng XJ, Dong B, Hu Y, Du H, Li YA, Zhu YB, Ding N, Du YX, Li JY and Ji JF. PTK7 as a novel marker for favorable gastric cancer patient survival. *J Surg Oncol* 2012; 106: 880-886.