

Case Report

Epithelioid angiosarcoma at chest wall which needs to be carefully distinguished from malignant mesothelioma: report of a rare case

Chuifeng Fan^{1,2}, Yang Liu^{1,2}, Xuyong Lin^{1,2}, Yuchen Han^{1,2}, Anguang He^{1,2}, Enhua Wang^{1,2}

¹Department of Pathology, First Affiliated Hospital and College of Basic Medical Sciences of China Medical University, Shenyang 110001, China; ²Institute of Pathology and Pathophysiology, China Medical University, Shenyang 110001, China

Received September 10, 2014; Accepted October 31, 2014; Epub December 1, 2014; Published December 15, 2014

Abstract: Angiosarcoma is a malignant soft tissue tumor the cells of which variably recapitulate the morphologic and functional features of normal endothelium. Most lesions are located in the deep muscles of the lower extremities followed by the arm, trunk and head and neck. Herein we present a case of epithelioid angiosarcoma which is a variant of angiosarcoma at chest wall in a 73-year-old female. Morphologically, the tumor cells are arranged predominantly in luminal structures which can be seen in both angiosarcoma and malignant mesothelioma. Most of the tumor cells are large rounded “epithelioid” cells with abundant eosinophilic cytoplasm which can be also seen in both tumors. The epithelioid of cytomorphology and the localization at chest wall of this case may remind of a diagnosis of malignant mesothelioma which should be carefully distinguished from epithelioid angiosarcoma from imaging and morphology. CT scanning of the patient shows a mass at her chest wall, the majority of which is around the rib but not inside the lung which indicates a tumor originates more likely from soft tissues of chest wall but not pleura. Immunohistochemical staining shows that the tumor cells are positive for cytokeratin, CD31, Vimentin and WT1, and negative for CEA, TTF-1, Calretinin, Mesothelial Cell (MC), CD56, CK19, and Hepatocyte. Thus this case is diagnosed as epithelioid angiosarcoma but not malignant mesothelioma. From this case we suggest that carefully reading and understanding of the imaging are a very important clue for appropriate diagnosis. A misdiagnosis may occur on the basis of misunderstanding of tumor localization and a consequent inappropriate immunohistochemical staining programme.

Keywords: Angiosarcoma, chest wall, mesothelioma

Introduction

Epithelioid angiosarcoma is a rare variant of angiosarcoma composed predominantly of large endothelial cells with epithelioid morphology [1, 2]. Architecturally the cells are arranged in the patterns featuring normal endothelium. Most lesions segregate in deep soft tissue, though some may occur as cutaneous tumors. About 1/3 of angiosarcomas express cytokeratin along with endothelial markers and more than that percentage of cases are cytokeratin positive in epithelioid angiosarcomas, which provides close mimicry with carcinoma and sometime malignant mesothelioma [1, 3]. Cases of angiosarcoma occur in the chest wall are relatively rare. The structure of the chest wall is complicated, the most inner part of which is

pleura, which is adjacent to the lung. Malignant mesothelioma is a relatively common malignant tumor of the pleura. Epithelioid angiosarcoma composed predominantly of “epithelioid” cells which may mimic malignant mesothelioma. Therefore, angiosarcomas occur in the chest wall should be distinguished from malignant mesothelioma. The diagnosis should be based on both the exact location of the tumor and the morphology. As usual, the information of imaging is very important for the correct pathological diagnosis.

Case presentation

Clinical history

A 73-year-old female referred to our hospital for complaining of a left chest pain without cough-

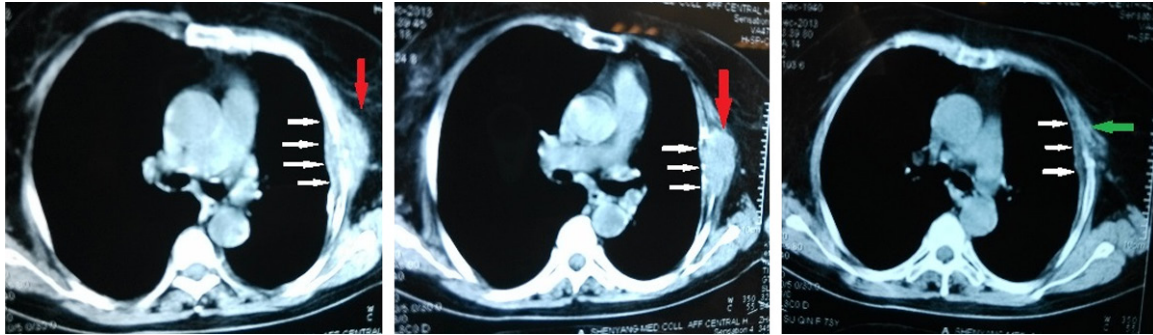


Figure 1. Imaging of the tumor. CT scan of the tumor at chest wall shows a mass about 4.5 cm × 4.2 cm around the rib (red arrow). The mass is located outside but close to the lung. The rim around the mass and adjacent lung tissue is smooth and shows no apparent invasion of lung and changes in the pleura (white arrow) which indicate a tumor of soft tissue of chest wall but not pleura and lung. The rib is corrupted by the tumor (green arrow).

ing and fever in the past one week. Computed tomography scan showed that there was a round, solitary, well-circumscribed nodule in the left chest wall (**Figure 1**). The diameter of the nodule was about 4.5 cm × 4.2 cm. The mass is located outside but close to the lung and shows no apparent invasion of the lung and changes in pleura which indicates a tumor of soft tissue of the chest wall but not the pleura and lung. The rib is corrupted by the tumor. In the current visit, the patient underwent biopsy of the tumor. The blood CEA, AFP, CA125, CA153, and CA19-9 of the patient are at normal levels.

Materials and methods

The resected specimens were fixed with 10% neutral buffered formalin and embedded in paraffin blocks. Tissue blocks were cut were cut into 4 μm-thick sections. The sections were dewaxed in xylene and rehydrated stepwise in descending ethanol series. Then the sections were boiled in citrate buffer (pH 6.0) for 90 seconds (time until the fire was turn off) within an autoclave (30 extra seconds to cool down by cold water). Endogenous peroxidase activity and non-specific binding were blocked with 3% H₂O₂ and non-immune sera, respectively. The sections were then incubated with the following primary antibodies: cytokeratin (CK, AE1/AE3, 1:50, DAKO), cytokeratin 5/6 (CK 5/6, 1:200, DAKO), cytokeratin 7 (CK7, 1:200, DAKO), cytokeratin 18 (CK18, 1:200, DAKO), cytokeratin 19 (CK19, 1:200, DAKO), CD56 (1:200, DAKO), vimentin (1:200, DAKO), carcinoembryonic antigen (CEA, 1:100, DAKO), thyroid transcription factor 1 (TTF-1, 1:100, DAKO), calretinin (1:100, DAKO), WT1 (1:500, DAKO), Mesothelial Cell

(MC, 1:200, DAKO), P53 (1:200, DAKO), and Ki67 (1:200, DAKO) overnight at 4°C. Thereafter, the catalyzed signal amplification system (Maixin Biotechnology, Fuzhou, Fujian, China) was used for staining of these proteins according to the manufacturer's instructions. The antibodies were detected by a standard avidin-biotin complex method with biotinylated secondary antibodies (Maixin) and an avidin-biotin complex (Maixin), and developed with diaminobenzidine. Counterstaining was done lightly with hematoxylin, and the sections were dehydrated in alcohol before mounting. Appropriate negative (obtained by omission of the primary antibodies) controls were used throughout.

Results

Gross features

The samples inspected are obtained by needle aspiration biopsy. The imaging of the tumor was described as above. The imaging also shows a mass in the petrous parts of the right parietal bone of the patient, which can't be ruled out of a metastasis lesion. The lesion in the parietal bone was not biopsied and the patient didn't receive surgery.

Microscopic features

Histologically, the tumor shows obvious vasoformative growth with complex anastomosing channels with blood red cells inside which are important clues for diagnosis of angiosarcoma (**Figure 2A-D**). However, it should be noted that because the specimen is a biopsy tissue, bleeding may occur. Therefore, judging of the vessel-like cavities can't be simply relied on the pres-

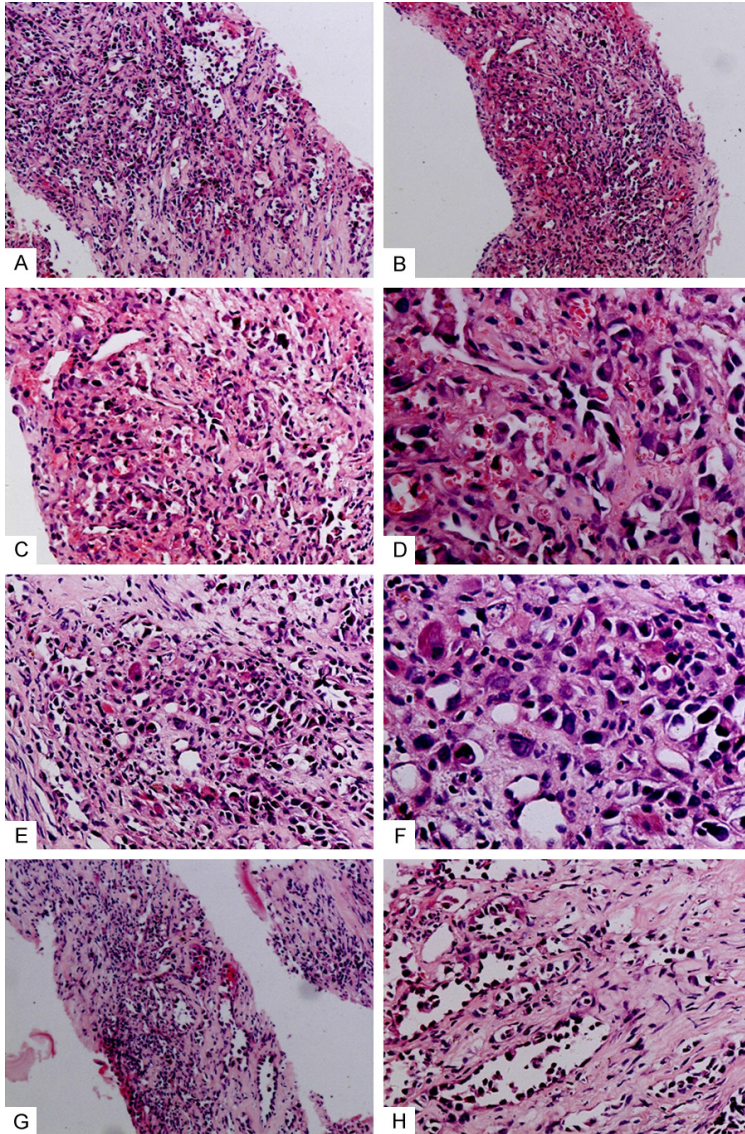


Figure 2. Morphological change of the tumor. A-D. The tumor cells show obvious vasoformative growth with complex anastomosing channels with blood red cells inside which are important clues for diagnosis of angiosarcoma. E, F. Tumor cells are large rounded “epithelioid” cells with abundant eosinophilic cytoplasm and relatively high nuclear grade. In some areas, the tumor cells are arranged in small nests without apparent luminal. G, H. Some Areas with relative open but not apparent anastomosing channels may lead to consideration of adenocarcinoma or malignant mesothelioma.

ence of the red blood cells. As seen in **Figure 2E, 2F**, most of the tumor cells are large rounded “epithelioid” cells with abundant eosinophilic cytoplasm and relatively high nuclear grade. In some areas, the tumor cells are arranged in small nests without apparent luminal which may mimic poorly differentiated carcinoma. Some Areas with relative open but not apparent

anastomosing channels may lead to consideration of both adenocarcinoma and malignant mesothelioma (**Figure 2G, 1H**). The “epithelioid” morphology of the tumor cells may also be pit-fall for consideration of these diagnoses.

Immunohistochemistry

Immunohistochemical staining (**Figure 3**) showed that the tumor cells were diffusely and strongly positive for CD31, cytokeratin, vimentin, focally positive for WT1, CK7 and CK18, and negative for calretinin, MC, TTF-1, CEA, CK19, Hepatocyte, and CD56. Ki67 index was more than 50%. Percentage of P53 nuclear accumulation was more than 50%.

Discussion

The chest wall contains complicated mesenchymal tissues, including bone, fat, fiber, blood vessels, and muscles, and the pleura is the innermost structure of it. Malignant mesothelioma is a relatively common tumor of the pleura. Moreover the malignant tumors in the lung can often invade the chest wall. Therefore, tumors occur in the chest wall should be differentiated not only based on the histological findings, but also on the exact location of the tumor. The imaging is frequently used to provide important clues. The cell morphology of the angiosarcoma shows diversity [1, 4-6].

The differential diagnosis becomes complicated when it mimics fibroblasts or epithelial cells [1, 7-12]. In this case, the tumor cells are epithelioid large cells, forming luminal structures, which can lead to the consideration of malignant mesothelioma. However, when carefully observed, these luminal structures show to be anastomosing channels, though some relative separate channels could

Epithelioid angiosarcoma on chest wall

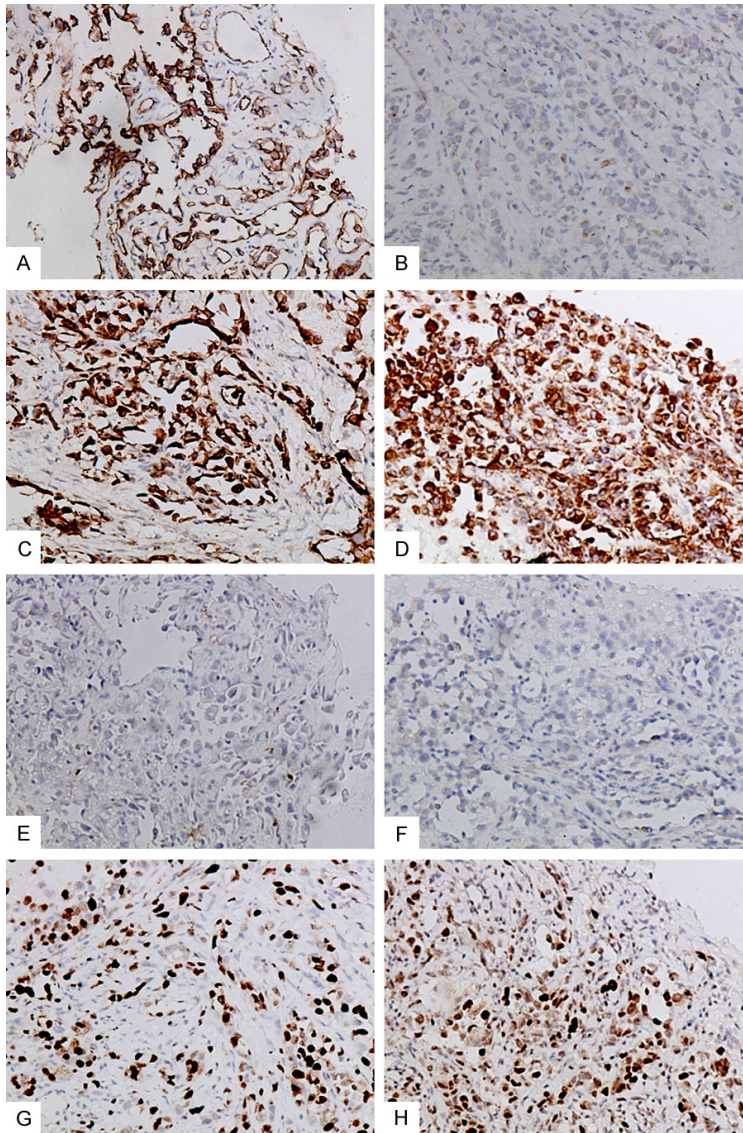


Figure 3. Immunohistochemical staining of the tumor. A. The cells were entirely positive for CD31. B. The tumor cells were negative for MC. C. Positive expression of CK (pan) in the tumor cells. D. Positive expression of vimentin in the tumor cells. E. Negative expression of CEA. F. Negative expression of TTF-1. G. Ki67 index was more than 50%. H. The percentage of nuclear accumulation of P53 was more than 50%.

be very cheating. There are red blood cells inside these structures which is also a characteristic feature of angiosarcoma. However, for biopsy specimens, there may be illusions caused by the tissue damages and bleeding. From the imaging we can see that the tumor is located around the rib but not inside the lung. Though it is close to the pleura, the pleura showed no apparent changes, such as invasion and thickening. This information from the imaging indicates that the possibility of malignant

mesothelioma for the tumor is very low. Further immunohistochemical staining shows that the tumor cells were positive for vascular marker, CD31, but negative for the mesothelioma markers, MC and calretinin. So the diagnosis of epithelioid angiosarcoma can be made. It seems simple. However, it is not the case. Because in the clinic, there will be a number of reasons (subjective or objective) resulting in the lack of communication between the pathology doctors and patients. Sometime the imaging data can't be smoothly sent to the doctor's hands. Then it can occur that a pathological diagnosis of biopsy tissues is made relying on only the microscopic findings, or with simple interpretation of the imaging findings, which may greatly increase the chances of misdiagnosis. Thus, this style of diagnostic approach which has potential risk should be noted and avoided.

Angiosarcoma is highly aggressive and frequently metastasizes [1, 9-15]. This patient has also a skull mass which has not been biopsied. We cannot know whether it is the same kind of tumor as in the chest wall. However, it cannot be ruled out that the mass in the skull is the primary lesion which metastasized to the chest wall, or vice versa. Because the two lesions in the patient were discovered

almost simultaneously, it is almost impossible to confirm the metastasis from one site to another. Some cases diagnosed with angiosarcoma have multifocal lesions. For this case, the possibility for multiple lesions also exists.

In conclusion, epithelioid angiosarcoma at the chest wall is relatively rare and needs to be carefully differentiated with malignant mesothelioma, based on both imaging and histopathological findings. The imaging information

plays important roles in determining the tumor's exact location, appropriate immunohistochemistry program and final proper pathological diagnosis. This full use of the clinical information is a recommended and reasonable diagnostic mode to minimize misdiagnosis. In this case, the exact understanding of the location of the lesion has showed particular importance.

Acknowledgements

Written informed consent was obtained from the patient for publication of this case report and accompanying images. A copy of the written consent is available for review by the Editor-in Chief of this Journal.

Disclosure of conflict of interest

None.

Address correspondence to: Dr. Enhua Wang, Department of Pathology, First Affiliated Hospital and College of Basic Medical Sciences of China Medical University, Shenyang 110001, China. Tel: +86 24 23261638; Fax: +86 24 23261638; E-mail: wangeh@hotmail.com

References

- [1] Fletcher CDM, Unni KK, Mertens F. World health organization classification of tumors. Pathology and genetics of tumors of soft tissue and bone. Lyon: IARC Press; 2002.
- [2] Lang J, Chen L, Chen B, Chen K, Liu A, Li J, Wang J. Epithelioid angiosarcoma of the spine: A case report of a rare bone tumor. *Oncol Lett* 2014; 7: 2170-2174.
- [3] Hart J, Mandavilli S. Epithelioid angiosarcoma: a brief diagnostic review and differential diagnosis. *Arch Pathol Lab Med* 2011; 135: 268-72.
- [4] Mark RJ, Poen JC, Tran LM, Fu YS, Juillard GF. Angiosarcoma: A report of 67 patients and a review of the literature. *Cancer* 1996; 77: 2400-2406.
- [5] Fletcher CD. Vascular tumors: an update with emphasis on the diagnosis of angiosarcoma and borderline vascular neoplasms. *Monogr Pathol* 1996; 38: 181-206.
- [6] Fedok FG, Levin RJ, Maloney ME, Tipirneni K. Angiosarcoma: current review. *Am J Otolaryngol* 1999; 20: 223-231.
- [7] Krüger S, Kujath P, Johannisson R, Feller AC. Primary epithelioid angiosarcoma of the adrenal gland case report and review of the literature. *Tumori* 2001; 87: 262-265.
- [8] Triantafyllidou K, Lazaridis N, Zaramboukas T. Epithelioid angiosarcoma of the maxillary sinus and the maxilla: a case report and review of the literature. *Oral Surg Oral Med Oral Pathol Oral Radiol Endod* 2002; 94: 333-337.
- [9] Dainese E, Pozzi B, Milani M, Rossi G, Pezzotta MG, Vertemati G, Tricomi P, Sessa F. Primary pleural epithelioid angiosarcoma: A case report and review of the literature. *Pathol Res Pract* 2010; 206: 415-419.
- [10] Selim A, Khachemoune A, Lockshin NA. Angiosarcoma: a case report and review of the literature. *Cutis* 2005; 76: 313-317.
- [11] Gagner JP, Yim JH, Yang GC. Fine-needle aspiration cytology of epithelioid angiosarcoma: a diagnostic dilemma. *Diagn Cytopathol* 2005; 33: 429-433.
- [12] Balaji GG, Arockiaraj JS, Roy AC, Deepak B. Primary epithelioid angiosarcoma of the calcaneum: a diagnostic dilemma. *J Foot Ankle Surg* 2014; 53: 239-242.
- [13] Kok VC, Liu TW, Lin HH, Ou H, Cheng SH, Liu MC, Huang AT. Concomitant renal cell carcinoma and metastatic epithelioid angiosarcoma with microangiopathy. *J Formos Med Assoc* 1995; 94: 48-52.
- [14] Peacock ZS, Lam DK, Cox DP, Schmidt BL. Metastatic epithelioid angiosarcoma to the mandible: report of a case and review of the literature. *Int J Oral Maxillofac Surg* 2013; 42: 702-706.
- [15] Hynes SO, Attah CB, Ingoldsby H, Kolcow W, Macneill B, Veerasingham D, Orosz Z. Through the looking glass: primary epithelioid angiosarcoma in the left atrium, a unique site for a rare malignancy. *APMIS* 2013; 121: 664-667.