

Case Report

Intracranial multiple germ cell tumors: a case report and review of literature

Ping Yang^{1*}, Liang Li^{2,3*}, Weiping Kuang¹, Bo Li¹, Bin Zhou¹, Jingjing Yang⁴, Huiyong Huang²

¹Department of 3rd Neurosurgery, Brains Hospital of Hunan Province, Changsha, China; ²Institute of Diagnostics of Traditional Chinese Medicine, ³Department of Anatomy, Hunan University of Chinese Medicine, Changsha, China; ⁴Department of Chronic Disease, Center for Disease Control and Prevention of Yuhua District, Changsha, China. *Equal contributors.

Received September 29, 2014; Accepted November 26, 2014; Epub December 1, 2014; Published December 15, 2014

Abstract: Intracranial multiple germ cell tumors (GCTs) are rare. In this article, we reported a case of intracranial multiple GCTs in an 18-year-old boy with symptoms of psychosis for 8 months also. Tumors in the pineal, sellar region, corpus callosum, bilateral lateral ventricles and fourth ventricle were confirmed by enhanced magnetic resonance imaging (MRI) and stereotactic biopsy. Immunohistochemical analysis results demonstrated that the tumor cells were positive for CD117 and placental alkaline phosphatase (PLAP). The patient was treated by radiotherapy and the prescribed radiation doses were 18 Gy. After near 24 months of follow-up, no local recurrence and distant metastasis has been found.

Keywords: Intracranial multiple germ cell tumors, symptoms of psychosis, pineal, sellar region, corpus callosum, lateral ventricles

Introduction

Intracranial germ cell tumors (GCTs) are uncommon, with diversity of clinical manifestations and diagnosis of this kind of disease is full of challenge [1]. Generally speaking, most GCTs are gonadal in origin. When they happen inside the calvarium, the primary sites are commonly in midline structures, especially the pineal and neurohypophyseal regions [2]. GCTs occur frequently in the corpus callosum [3], thalami [4], basal ganglia [5], temporal lobe [6], cerebello-pontine angle [7], medulla oblongata [8] and external acoustic meatus [9], while cases of GCTs with intracranial extension have been rarely reported. Here we reported a rare case of intracranial multiple GCTs in an 18-year-old boy treated in our institution. This present study was performed to enhance our understanding of the tumors in our population.

Case report

An 18-year-old boy presented with an 8-month history of hypoglycemia, emotional lability, big temper and poor academic performance. He had

been admitted to a local hospital and scanned with magnetic resonance imaging (MRI). It was reported inhomogeneous long T1 and long T2 abnormal signals existed near the anterior horns of bilateral lateral ventricles, but the original MRI materials were missed. He was diagnosed of viral encephalitis and treated with acyclovir for half a month. But as a result, it can not help. When he was transferred to our hospital, he had symptoms of low-grade fever, excessive daytime lethargy, polyuria, polydipsia, nausea, vomiting, irritability, armpit hair reduction, pubic hair reduction and beating others.

Laboratory investigations revealed: white blood cell (WBC) $12.88 \times 10^9/L$, urine specific gravity 1.01, total triiodothyronine (TT3) 0.42 ng/mL, total thyroid hormone (TT4) 2.5 ug/dL, free triiodothyronine (FT3) 1.05 pg/mL, free thyroid hormone (FT4) 0.3 ug/dL, luteinizing hormone (LH) 0 mIU/mL, follicle-stimulating hormone (FSH) 0.38 mIU/mL, testosterone (TSTO) 6.36 ng/dL. The α -fetoprotein (AFP) levels of both serum and cerebrospinal fluid (CSF) were 10 ng/mL. The β -human chorionic gonadotropin (β -HCG) levels of both serum and CSF were 0.00 ng/mL.

Intracranial multiple germ cell tumors

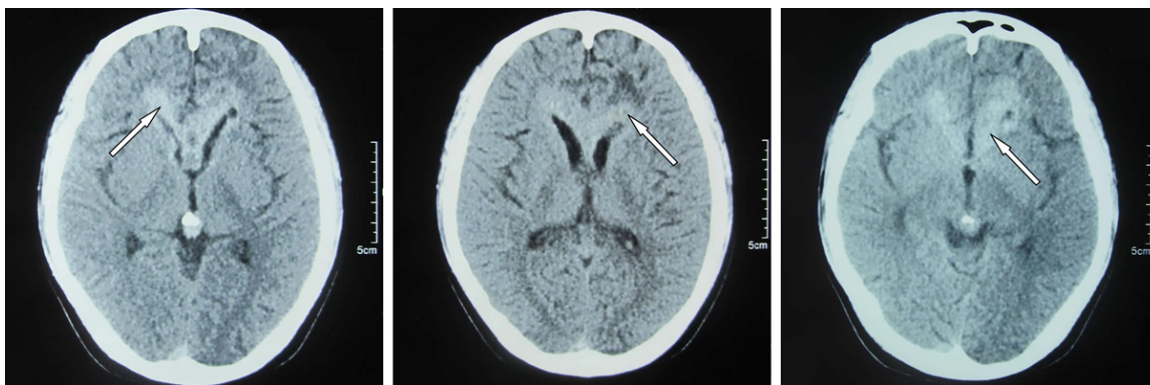


Figure 1. CT scans findings. Axial images showing high density with multiple irregular lesions.

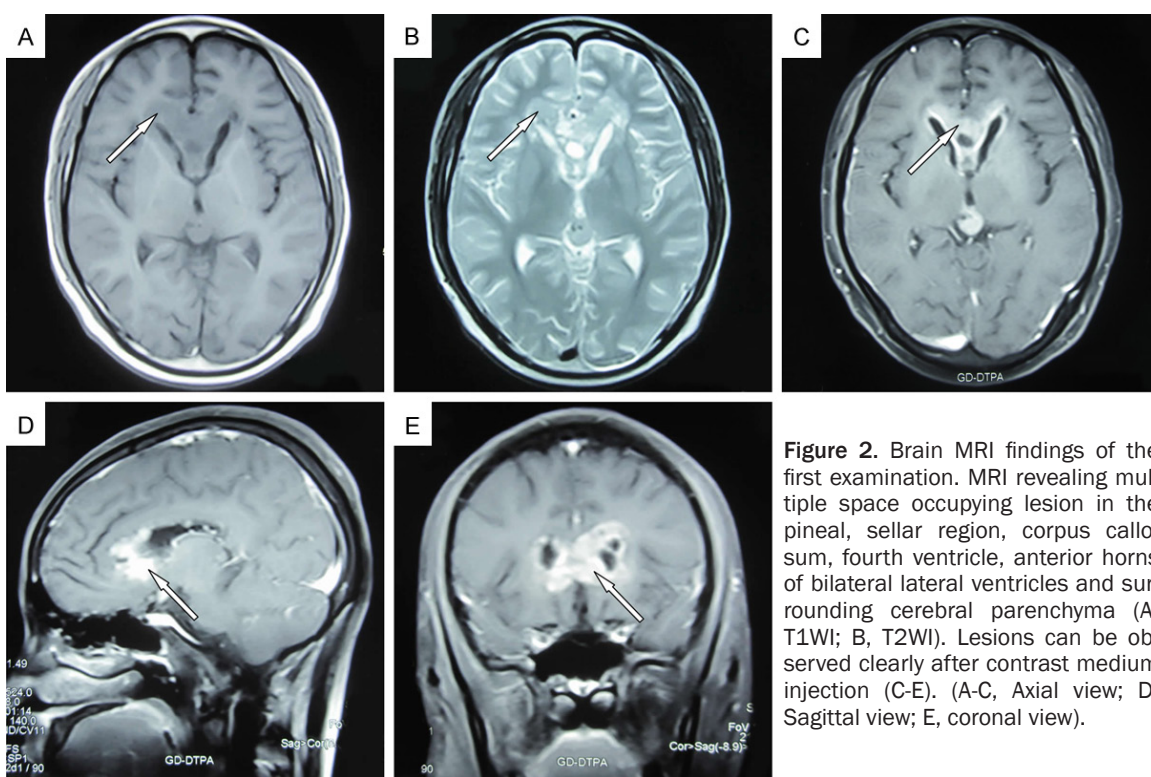


Figure 2. Brain MRI findings of the first examination. MRI revealing multiple space occupying lesion in the pineal, sellar region, corpus callosum, fourth ventricle, anterior horns of bilateral lateral ventricles and surrounding cerebral parenchyma (A, T1WI; B, T2WI). Lesions can be observed clearly after contrast medium injection (C-E). (A-C, Axial view; D, Sagittal view; E, coronal view).

The brain computer tomography (CT) scans showed multiple irregular high-density lesions, some of which were accompanied by cystic degeneration and mass effect (**Figure 1**). Enhanced MRI revealed multiple similar round, nodular, massive long T1 and long T2 signal lesions locating in the pineal, sellar region, corpus callosum, fourth ventricle, anterior horns of bilateral lateral ventricles and surrounding cerebral parenchyma. The lesion in pineal region (1.5 cm in diameter) had small nodular short T2 signal. The lesion in sellar region (1.5 cm in diameter) had invaded pituitary stalk

already. Anterior horns of bilateral lateral ventricles were irregular, which had invaded corpus callosum and white matter deep in the frontal lobe. Mild edema existed around the lesions. The signal was heterogeneous and became inhomogeneous enhancement remarkably on T1-weighted (T1WI) MRI (**Figure 2**). There was no abnormality in the spinal cord with enhanced MRI (**Figure 3**).

The right corpus callosum had been chosen for stereotactic biopsy. Immunohistochemical staining showed cell patterns of germinoma

Intracranial multiple germ cell tumors

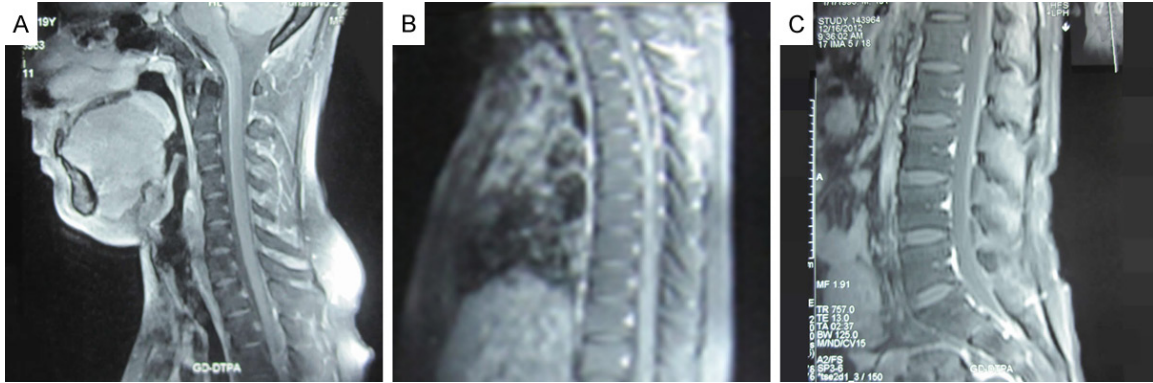


Figure 3. Spinal cord MRI findings. Sagittal T1WI images of the neck (A), chest (B) and abdomen (C) showing no distant metastasis to the spinal cord after contrast medium injection.

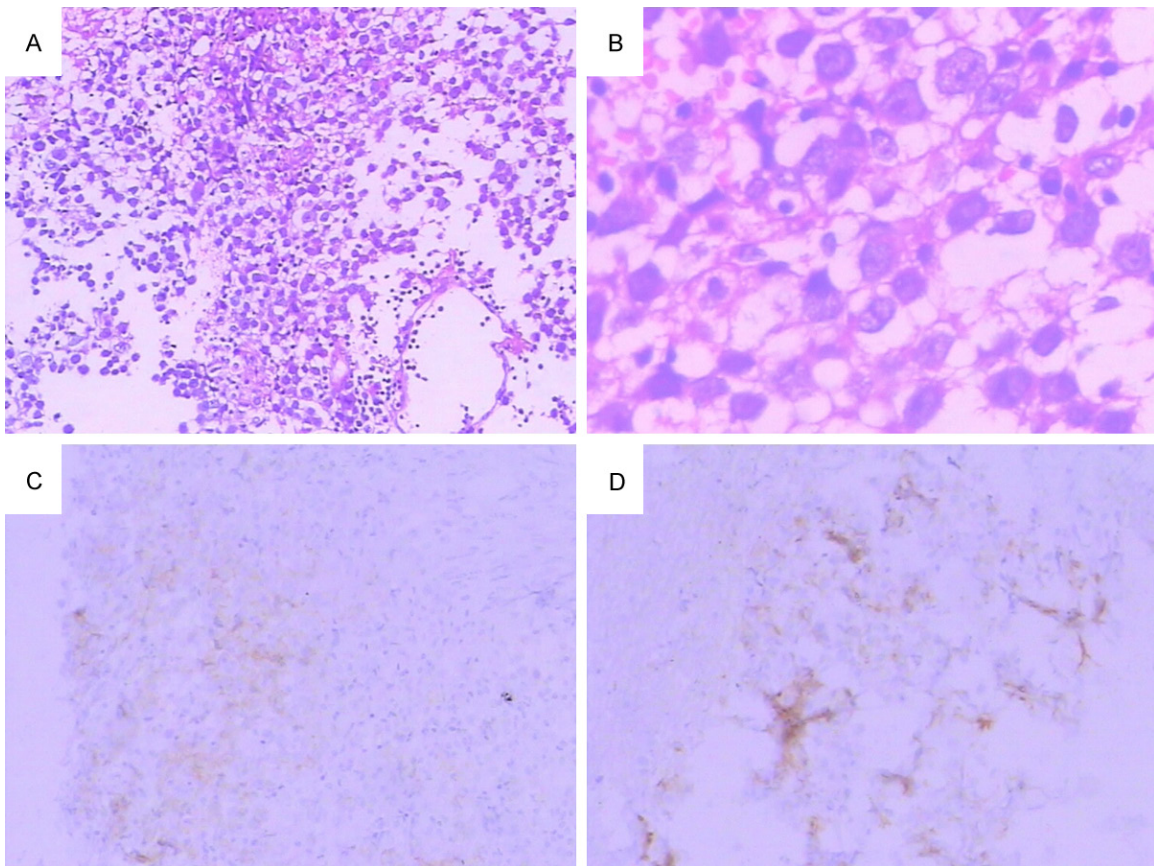


Figure 4. Histological features of the tumor. Photomicrograph showing marked infiltration of lymphocytes and plasma cells and macrophages including giant cells (H&E stain, A, 100 \times , B, 400 \times). Immunohistochemical analysis results demonstrating the tumor cells were positive for CD117 (C, 400 \times) and PLAP (D, 400 \times).

with large clear cells and small lymphoid elements. CD117 and placental alkaline phosphatase (PLAP) positive cells can be observed easily (**Figure 4**). The patient was treated with X-ray radiation therapy. The prescribed radiation doses were 18 Gy, with 3 Gy per fraction, 5 fractions per week.

Every 6 months, he visited our hospital for follow-up evaluation of his serum levels of LH, FSH, TSTO, β -HCG and thyroid function, as well as MRI findings. LH, FSH, and β -HCG were normal in the history of follow-up all the time whereas he had hypothyroidism, diabetes insipidus and low level of TSTO.

Intracranial multiple germ cell tumors

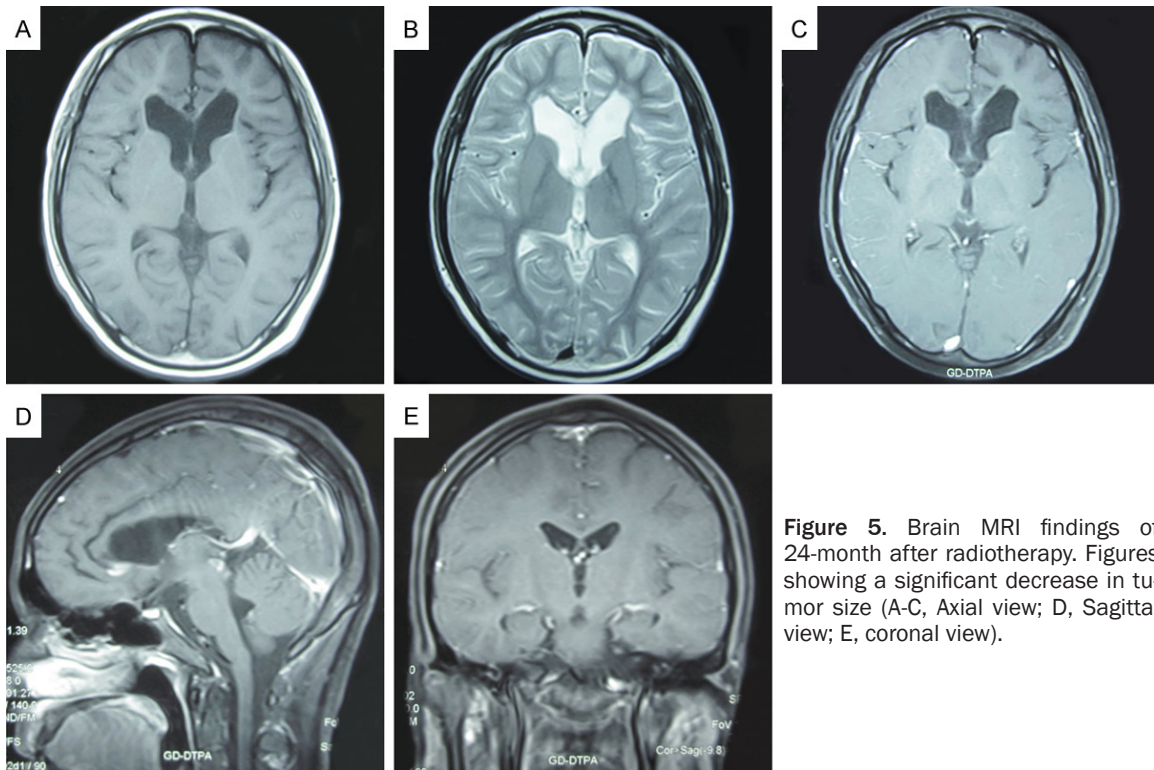


Figure 5. Brain MRI findings of 24-month after radiotherapy. Figures showing a significant decrease in tumor size (A-C, Axial view; D, Sagittal view; E, coronal view).

We performed follow-up with brain MRI at 6, 12, 18 and 24 months respectively after the first MRI in our hospital. MRI of 6-month showed the intensity of intracystic contents had changed. MRI of 24-month revealed that multiple lesions in the pineal, sellar region, corpus callosum, fourth ventricle, anterior horns of bilateral lateral ventricles and surrounding cerebral parenchyma shrank more than before. High signal occurred on T2-weighted (T2WI) MRI and mild enhancement can be seen on enhanced scans. The anterior horns of bilateral lateral ventricles enlarged (**Figure 5**).

Discussion

Intracranial multiple GCTs are rare in intracranial tumors. No similar cases have been reported. These malignant intracranial tumors usually occur in children and adolescents [10]. Intracranial multiple lesions are used to being mentioned in association with aggressively infiltrative tumors such as gliomas, demyelinating diseases and multiple sclerosis [11]. Normally, the occurrence of intracranial multiple GCTs is extremely rare and seldom to be considered among preoperative differential diagnoses.

The patient with symptoms of psychosis visited a local hospital. Based on the brain MRI findings showing lesions at cerebral parenchyma around bilateral lateral ventricles, he was diagnosed of viral encephalitis. Antiviral and anti-psychotic treatment was performed, but that didn't work. On the contrary, the symptoms became aggravated because the characteristic of the lesions was still unknown. The first time he visited our institution, the diagnosis of GCTs was difficult to be defined owing to lack of neurologic syndrome and other more information. When he had the symptoms of degeneration of secondary sexual characteristics and diabetes insipidus gradually, we started thinking about the possibility of compression to hypophysis caused by tumor [12]. Then the boy received a full examination of sex hormones. All contents were normal except low level of TSTO, so we thought maybe this disease was related to GCTs. In clinic, studies have confirmed that the GCTs need to be diagnosed by stereotactic biopsy [13]. By thinking it over, we decided to choose the right corpus callosum for operation in the end. Nowadays immunohistochemical staining for CD117 and PLAP is a well known method for diagnosis [14, 15]. The results of stereotactic biopsy showed that the tumor cells

were positive for CD117 and PLAP. Finally the diagnosis of intracranial multiple GCTs has been confirmed. As for the origin of the tumor in this disease, we've argued for a long time. Because the original MRI materials in the local hospital were missed, we can not draw a conclusion. The majority of us believed the psychiatric symptoms were caused by onset of the corpus callosum.

Intracranial GCTs mainly occurs in the pineal region, suprasellar region or basal ganglia region, and can easily spread through the cerebrospinal fluid (CSF) [16]. We inferred intracranial multiple lesions came into being through the spread of CSF in this case. At the same time, the spinal cord may be affected too. But fortunately, no lesions had been found with spinal cord enhanced MRI. Radiation therapy has been regarded as standard therapy for GCTs in central nervous system [17]. The patient received it and then leaved hospital. The boy came back to our institution every 6 months. No evidence has showed regrowth of the lesions and all the psychiatric symptoms have been nearly cured. But there still exit hypothyroidism and Low level of TSTO, which we'll continue to trace.

To the best of our knowledge, we describe the first case of intracranial multiple GCTs which has been followed up for 24 months with radiation therapy for the tumor itself. The case shows intracranial multiple GCTs has no specificity at clinical manifestations. When the patient was found has symptoms of psychosis, endocrine alteration and space occupying lesion in the head, stereotactic biopsy and pathological examination should be used to diagnose definitely as soon as possible, so that misdiagnosis can be avoided.

Acknowledgements

This work was supported by grants from the National Natural Science Foundation of China (No. 81302899, 81373551), Scientific Research Program of Chinese Medicine of Hunan Province (No. 2013111). We are grateful for the support by the Department of Radiation and Pathology, Brains Hospital of Hunan Province, Changsha, China.

Disclosure of conflict of interest

None.

Address correspondence to: Dr. Huiyong Huang, Institute of Diagnostics of Traditional Chinese Medicine, Hunan University of Chinese Medicine, Science and Education Park, Yuelu District, Changsha 410208, China. Tel: + 86 731 8845 8717; Fax: + 86 731 8845 8111; E-mail: huanghy68@126.com

References

- [1] Mufti ST and Jamal A. Primary intracranial germ cell tumors. *Asian J Neurosurg* 2012; 7: 197-202.
- [2] Villano JL, Virk IY, Ramirez V, Propp JM, Engelhard HH and McCarthy BJ. Descriptive epidemiology of central nervous system germ cell tumors: nonpineal analysis. *Neuro Oncol* 2010; 12: 257-264.
- [3] Chuan Aaron FS, Dawn CQ, Kenneth CT, Hoe NW, Yen SS and Chee Kian T. Primary human chorionic gonadotropin secreting germinoma of the corpus callosum. *Surg Neurol Int* 2013; 4: 137.
- [4] Sartori S, Laverda AM, Calderone M, Carollo C, Viscardi E, Faggini R and Perilongo G. Germinoma with synchronous involvement of midline and off-midline structures associated with progressive hemiparesis and hemiatrophy in a young adult. *Childs Nerv Syst* 2007; 23: 1341-1345.
- [5] Kawai N, Miyake K, Nishiyama Y, Yamamoto Y, Miki A, Haba R, Imai T, Tamiya T and Nagao S. Targeting optimal biopsy location in basal ganglia germinoma using (11)C-methionine positron emission tomography. *Surg Neurol* 2008; 70: 408-413; discussion 413.
- [6] Utsuki S, Oka H, Tanizaki Y, Kondo K and Fujii K. Radiological features of germinoma arising from atypical locations. *Neurol Med Chir (Tokyo)* 2005; 45: 268-271.
- [7] Fujiwara K, Uenohara H, Suzuki H and Sakurai Y. Intracranial germinoma with syncytiotrophoblastic giant cells in the cerebellopontine angle—case report. *Neurol Med Chir (Tokyo)* 2002; 42: 132-136.
- [8] Yen PS, Chou AS, Chen CJ, Jung SM, Chuang HL and Scott RM. Primary medulla oblongata germinoma: a case report and review of the literature. *J Neurooncol* 2003; 62: 339-342.
- [9] Zhao R, Wang J, Ba Y and Zhang Q. Metastasis germinomas of the external acoustic meatus: in a 19-year-boy: a case report. *Int J Clin Exp Pathol* 2013; 6: 1416-1421.
- [10] Tamaki N, Lin T, Shirataki K, Hosoda K, Kurata H, Matsumoto S and Ito H. Germ cell tumors of the thalamus and the basal ganglia. *Childs Nerv Syst* 1990; 6: 3-7.
- [11] Zhang XJ, Piao YS, Chen L, Tang GC, Wei LF, Yang H and Lu DH. [Multiple intracranial le-

Intracranial multiple germ cell tumors

- sions: a clinicalpathologic study of 62 cases]. Zhonghua Bing Li Xue Za Zhi 2011; 40: 599-603.
- [12] Kobayashi T, Kageyama N, Kida Y, Yoshida J, Shibuya N and Okamura K. Unilateral germinomas involving the basal ganglia and thalamus. J Neurosurg 1981; 55: 55-62.
- [13] Aldana PR, MacGregor TL, James HE, Marcus RB Jr and Indelicato DJ. Titanium screws as fiducial markers for image-guided stereotactic proton irradiation in pediatric central nervous system tumors: a technical report. Pediatr Neurosurg 2010; 46: 227-231.
- [14] Miyanohara O, Takeshima H, Kaji M, Hirano H, Sawamura Y, Kochi M and Kuratsu J. Diagnostic significance of soluble c-kit in the cerebrospinal fluid of patients with germ cell tumors. J Neurosurg 2002; 97: 177-183.
- [15] Takeshima H and Kuratsu J. A review of soluble c-kit (s-kit) as a novel tumor marker and possible molecular target for the treatment of CNS germinoma. Surg Neurol 2003; 60: 321-324; discussion 324-325.
- [16] Qu B, Du L, Huang Y, Yu W, Cai B, Xu S and Ma L. Clinical analysis of intracranial germinoma's craniospinal irradiation using helical tomotherapy. Chin J Cancer Res 2014; 26: 247-254.
- [17] Sands SA, Kellie SJ, Davidow AL, Diez B, Villablanca J, Weiner HL, Pietanza MC, Balmaceda C and Finlay JL. Long-term quality of life and neuropsychologic functioning for patients with CNS germ-cell tumors: from the First International CNS Germ-Cell Tumor Study. Neuro Oncol 2001; 3: 174-183.