

Case Report

Primary neuroendocrine tumor of the testis: a study of clinicopathological features

Xu'e Han^{1*}, Lihua Yu^{2*}, Shuyun Yang³, Jinfeng Zheng⁴

¹Department of Laboratory Medicine, 456th Hospital of Jinan Military Command, Jinan 250031, China; ²Department of Laboratory Medicine, The Sanatorium of Jinan Military Command, Qingdao 266071, China; ³Department of Pathology, Armed Police Corps Hospital of Shanxi Province, Taiyuan 030006, China; ⁴Department of Pathology, The General Hospital, Jinan Military Command, Jinan 250031, China. *Equal contributors.

Received January 23, 2014; Accepted February 25, 2014; Epub March 15, 2014; Published April 1, 2014

Abstract: This study aimed to explore the clinicopathological characteristics and differential diagnosis of primary neuroendocrine tumor (G1) of the testis. In this paper, we analyze the clinical, histomorphological and immunohistochemical findings, treatment and prognosis of a patient with primary neuroendocrine tumor of the testis, and discuss the relevant literature. A 52-year-old man presented with a painless testicular swelling since 6 months. Histopathological examination showed that the tumor cells were arranged in island and beam patterns. The tumor cells were uniform, polygonal and had moderately eosinophilic cytoplasm and fine granular nuclear chromatin. Immunohistochemical staining showed that the tumor cells were positive for cytokeratin, CD56, synaptophysin and chromogranin A, and negative for inhibin, placental alkaline phosphatase and alpha-fetoprotein. Primary neuroendocrine tumor of the testis is a rare tumor with characteristic imaging features. Its accurate diagnosis depends on the morphological and immunohistochemical findings. These tumors should be differentiated from metastatic neuroendocrine carcinomas, teratomas with carcinoid, seminomas, Sertoli cell tumors and granulosa cell tumors. The treatment of most primary neuroendocrine tumors involves surgical resection combined with other therapies and usually results in a good prognosis.

Keywords: Testis, neuroendocrine tumor, immunohistochemistry, differential diagnosis

Introduction

Primary neuroendocrine tumor of the testis is extremely rare and accounts for only 0.23% of all testicular tumors [1]. Thus far, no epidemiological data are available for this type of tumor, and no incidence model has been established. Here, we report a case of primary neuroendocrine tumor of the testis, and discuss its clinicopathological features, diagnosis, differential diagnosis, treatment and prognosis as well as the relevant literature.

Case report

Clinical findings

A 52-year-old man presented with a painless swelling in the testis for 6 months. He had a progressively increasing scrotal mass without a

testicular bulge, and pain and difficulty during urination. He had no history of testicular trauma, endocrine diseases and secondary sexual characteristics of the signs. A physical examination revealed a relatively fixed, hard mass measuring 3.0 × 2.5 × 2.5 cm in the right testis. Ultrasonography showed that the right testis was enlarged, and contained a 2.7 × 2.5 × 2.2 cm, well-defined mass. The right testicular parenchyma showed uneven echogenicity with scattered areas of strong echogenicity. The left testis was normal. Apart from the right testicular tumor, positron emission tomography-computed tomography examination showed no lesions or metastases in other body tissues, organs or lymph nodes. A right testicular tumor was confirmed, and unilateral orchiectomy was performed. The patient provided informed consent, and the study was approved by the medical ethics committee of our hospital.

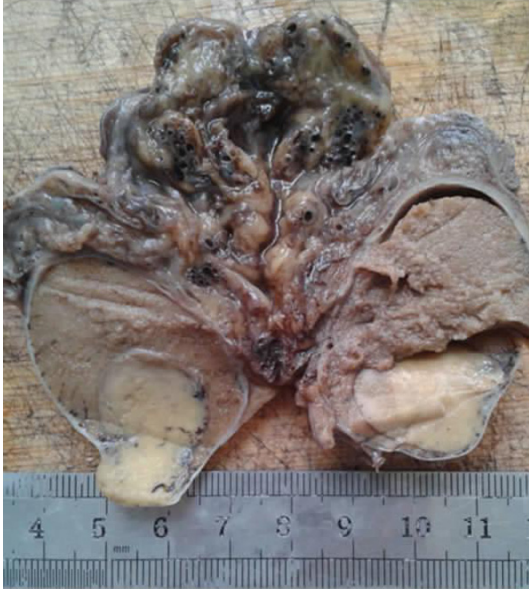

Figure 1. Macroscopic features of primary neuroendocrine tumor of the testes. The well-defined tumor shows a yellowish cut surface and has infiltrated the tunica albuginea.

Macroscopic examination

The resection specimen consisted of the right testis and tumor, spermatic cord and epididymis. The cut surface of the right testis showed a firm, gray-yellow mass measuring $2.7 \times 2.5 \times 2.2$ cm with focal calcification and no hemorrhage or necrosis (**Figure 1**). The right epididymis measured $4 \times 1.7 \times 1$ cm, and its section appeared yellowish white, solid, soft and free of the tumor.

Histopathological examination and immunohistochemical analysis

The resected specimen was fixed with 4% neutral formaldehyde, followed by conventional dehydration, paraffin embedding, sectioning, and hematoxylin and eosin (HE) staining. Immunohistochemical staining was performed using the EnVision two-step method. Antibodies to cytokeratin (CK), CD56, synaptophysin (Syn), chromogranin A (CgA), inhibin, placental alkaline phosphatase (PLAP), alpha-fetoprotein (AFP) and Ki67 were purchased from Beijing Zhong Shan Biotech Corp.

Light microscopic observation showed that the tumor cells were arranged in beam and island patterns. The tumor cells were uniform, circular or polygonal, had moderately eosinophilic,

granular cytoplasm, with a small amount of lipid, argyrophilic nuclear chromatin, round-to-oval, uniform nuclei and few mitotic figures (**Figure 2A-C**). The tumor had abundant blood vessels and fibrovascular stroma with calcium deposits or calcifications. Electron microscopy showed neurosecretory granules, granular nuclear chromatin and non-prominent nucleoli. On immunohistochemical analysis, the tumor cells were found to be positive for CK (**Figure 3A**), Syn (**Figure 3B**), CgA (**Figure 3C**), CD56, and negative for inhibin, PLAP and AFP. The Ki-67 labeling index was less than 2% (**Figure 3D**).

Pathological diagnosis

The diagnosis was primary neuroendocrine tumor (G1) of the right testis with invasion of the tunica albuginea. The epididymis and vas deferens were free of the tumor.

Discussion

Clinical features

The incidence of testicular tumor is low, and these tumors account for only 1% of all tumors [2]. Primary testicular neuroendocrine tumors are exceedingly rare, and few cases have been reported in the literature. These patients typically present between the second and ninth decades of life, with an average age at presentation of 46 years [3, 4]. These tumors originate from neuroendocrine cells, which are distributed in all tissues and organs of the body. Two types of neuroendocrine tumors have been described, namely, carcinoid and neuroendocrine carcinoma. According to the 2010 World Health Organization classification of gastrointestinal neuroendocrine tumors (fourth edition) [5], these tumors are divided into two categories: neuroendocrine tumors and neuroendocrine carcinomas. The former are divided into G1, G2 and G3 levels according to their proliferation index. The prognosis of neuroendocrine tumors (G1) is good, while that of neuroendocrine carcinomas is poor. Testicular neuroendocrine tumors can be divided into primary and secondary types. Secondary neuroendocrine carcinomas can metastasize from pulmonary or gastrointestinal neuroendocrine carcinomas. In contrast, primary neuroendocrine tumors are believed to have originated in the testicle itself from testicular germ cells [6]. Studies have shown that most carcinoid tumors

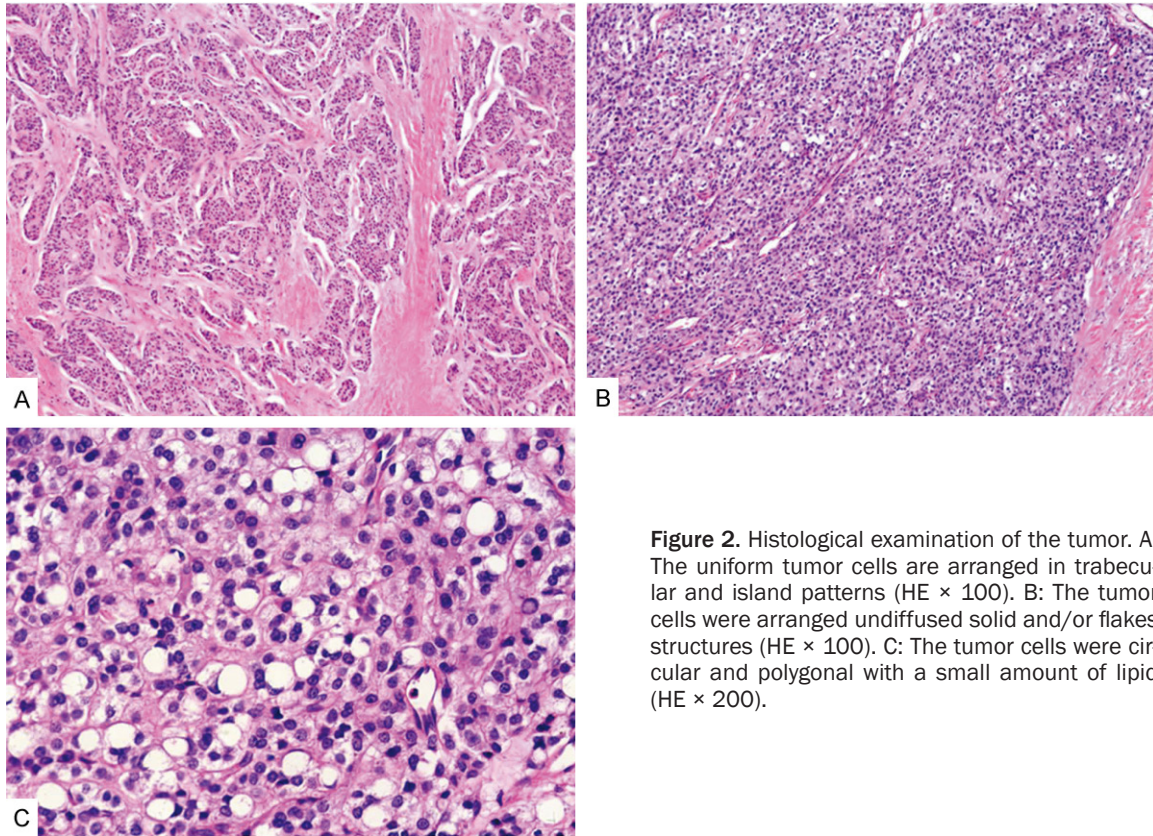


Figure 2. Histological examination of the tumor. A: The uniform tumor cells are arranged in trabecular and island patterns (HE \times 100). B: The tumor cells were arranged undiffused solid and/or flakes structures (HE \times 100). C: The tumor cells were circular and polygonal with a small amount of lipid (HE \times 200).

of the testis originate from Kulchitsky cells in the embryonic primitive intestinal mucosa [7]. The main clinical manifestation of these tumors is a painless testicular swelling or lump. Some patients have testicular tenderness. The bioactive substances secreted by testicular neuroendocrine tumor cells transfuse into the peripheral blood via the renal vein, and some of these substances are not inactivated by the liver. Therefore, approximately 10% of patients present with skin flushes, diarrhea, asthma and symptoms of cardiac damage (known as carcinoid syndrome) [8]. Primary testicular neuroendocrine tumor (G1) rarely cause carcinoid syndrome or metastasize; however, there have been some reports of these tumors metastasizing to the lymph nodes, liver, skin and skeletal muscles [9]. Besides a tumor of right testicles, the PET-CT examination show no lesions and metastasis of other body tissues and organs and lymph nodes in our case, also nor neuroendocrine syndrome. Therefore, in our patient, the clinical, imaging, histopathological and immunohistochemical findings supported the diagnosis of a primary testicular neuroendocrine tumor (G1).

Differential diagnosis

Testicular neuroendocrine tumor (G1) should be distinguished from metastatic neuroendocrine carcinoma, testicular teratoma with carcinoid, seminoma, Sertoli cell tumor and granulosa cell tumor.

Metastatic neuroendocrine carcinoma

The primary lesion commonly originates from the lung or digestive tract, and occasionally from the urogenital tract, adrenal gland or prostate. Testicular metastatic neuroendocrine carcinoma generally involves both testes and is associated with multifocal and vascular invasion. In contrast, patients with primary neuroendocrine tumors (G1) usually present with a long history of unilateral testicular swelling or lump, and typically do not have tumors of other tissues or organs.

Testicular teratoma with carcinoid

The composition of this tumor is complicated, and includes a visible teratoma component as well as carcinoid. Previously primary carcinoid

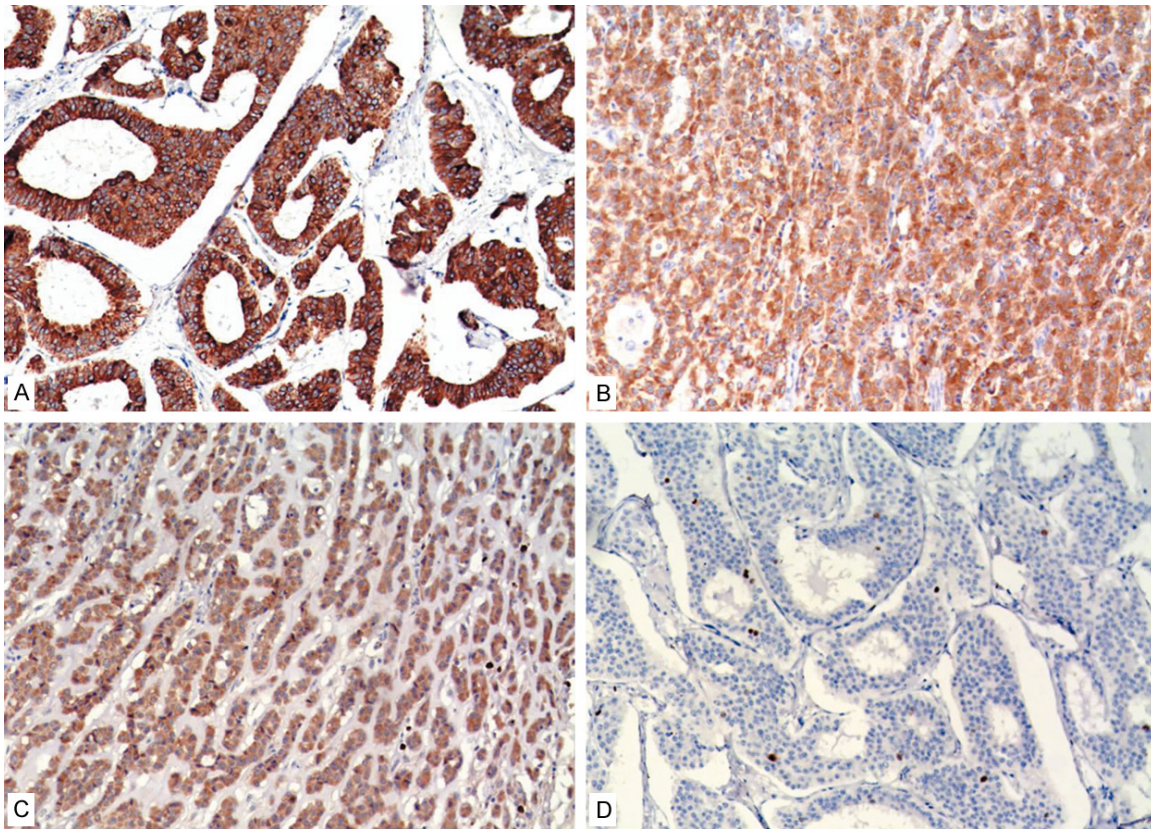


Figure 3. Immunohistochemical analysis of the tumor (Envision × 200). A: The tumor cells are positive for CK. B: The tumor cells are strongly positive for Syn. C: The tumor cells are strongly positive for CgA. D: The Ki-67 labeling index of the tumour cells is less than 2%.

tumor with testicular teratoma was called testicular mixed carcinoid; these tumors account for approximately 20% of primary testicular carcinoid tumors. The tumor is encapsulated with a thin layer of fibrous connective tissue, and contains tissues such as sebaceous glands, sweat glands and cartilage, which is lined with stratified squamous epithelium. The tumor cells of carcinoid tumor are of a consistent size and shape, form irregular islands, trabeculae or small adenoid arrangements and show an invasive growth pattern. On immunohistochemical analysis, the tumor cells are positive for CK, CD56, Syn, CgA and S-100.

Seminoma

Seminoma is a germ cell tumor of the testis. On microscopic examination, the tumor cells can be seen to be arranged in diffuse patches, divided by slim fiber interval into flake, funicles or lobules. The interstitium shows lymphocytic infiltration or lymphoid follicles. The tumor cells

are round or polygonal, with well-defined boundaries, transparent and mild eosinophilic granular cytoplasm containing glycogen and lipid. Immunohistochemical analysis shows that the tumor cells are positive for CD117, PLAP, vimentin, CK8/18 and prostate-specific antigen (PSA), and negative for CD56, Syn and CgA.

Sertoli cell tumor

Sertoli cell tumor is relatively rare, accounting for 1% of testicular tumors. It can occur at any age, but typically occurs in middle-aged persons. The tumor appears as a solid, white or gray nodule, with a diameter of less than 3 cm. On microscopy, the tumor cells are seen to be arranged in a funicular, solid nest, solid tubular or cribriform pattern. The interstitium shows fibrous stroma or dense fibrous stroma often accompanied with hyaline degeneration. Immunohistochemical analysis shows that the tumor cells are positive for vimentin and inhibin and negative for CK, CD56, Syn and CgA.

Granulosa cell tumor

Adult testicular granulosa cell tumor is quite rare, and tends to occur in persons aged 16-67 years. This tumor is associated with high estrogen levels, which usually cause breast development. Malignant tumors are often greater than 7 cm in diameter, and show vascular infiltration, hemorrhage and necrosis. Microscopic examination shows that the tumor cells are arranged in follicle, island, beam or ring shapes, or fake sarcomatoid arrangement. The follicles often have Call-Exner small body structure, the tumor cells was round or oval and nucleus was common nuclear ditch.

Treatment and prognosis

Primary neuroendocrine tumor (G1) is diagnosed on the basis of clinical, ultrasonographic, histopathological and immunohistochemical findings. In the case of neuroendocrine tumor (G1), surgical resection with close follow-up is the treatment of choice for low-grade tumors [10]. Current treatment of the disease generally involves surgical resection combined with post-operative radiation and chemotherapy. The extent and manner of excision depend on the nature, size and site of the tumor, the depth of invasion, lymph node metastasis, etc. [11, 12]. The survival rate of patients with primary testicular neuroendocrine tumor with lymph node and lung metastases can be increased with chemotherapy (cisplatin and etoposide; ifosfamide, epirubicin and octreotide), radiation therapy, etc. [13]. Some authors have reported that cisplatin-based chemotherapy regimens are the most useful to prevent tumor metastasis. Tumor size and carcinoid syndrome are features associated with a malignant course. Patients with carcinoid syndrome have a poor prognosis [14]. Our patient underwent surgery and received two cycles of chemotherapy 2 months after the surgery. The patient does not have metastases to the regional lymph nodes or other organs. He is alive and well, and regularly attends follow-up appointments.

Acknowledgements

This work was partly supported by the President Fund (Grant No. 2011M02) from the General Hospital, Jinan Military Command, China.

Disclosure of conflict of interest

The authors have no conflicts of interest to declare.

Address correspondence to: Dr. Jinfeng Zheng, Department of Pathology, The General Hospital, Jinan Military Command, Shifan Road 25, Jinan, Shandong Province, 250031, China. Tel: +86 531 51666857; Fax: +86 531 51666857; E-mail: zjfmf@163.com

References

- [1] Berdjis CC, Mostofi FK. Carcinoid tumors of the testis. *J Urol* 1977; 118: 777-782.
- [2] Sun GH, Fang DB, Shen ZJ, Cai SL. The diagnosis of testicular tumors (57 case reports). *National J Andrology* 2003; 9: 364-366.
- [3] Kato N, Motoyama T, Kameda N, Hiruta N, Emura I, Hasegawa G, Murata T, Kimura M, Tsuda H, Ishihara T. Primary carcinoid tumor of the testis: immunohistochemical, ultrastructural and FISH analysis with review of the literature. *Pathol Int* 2003; 53: 680-685.
- [4] Reyes A, Moran CA, Suster S, Michal M, Dominguez H. Neuroendocrine carcinomas (carcinoid tumor) of testis: A clinicopathologic and immunohistochemical study of ten cases. *Am J Clin Pathol* 2003; 120: 182-187.
- [5] Bosman FT, Carneiro F, Hruban RH. WHO classification of tumors of the digestive system. *Lyo: IARC Press*; 2010. pp: 13-15.
- [6] Rathert M, Ubrig B, Atkins DJ, Roth S. Carcinoid tumor of the testis. *Urologe A* 2011; 50: 340-342.
- [7] Merino J, Zuluaga A, Gutierrez-Tejero F, Del Mar Serrano M, Ciani S, Nogales FF. Pure testicular carcinoid associated with intratubular germ cell neoplasia. *J Clin Pathol* 2005; 58: 1331-1333.
- [8] Kato N, Motoyama T, Kameda N, Hiruta N, Emura I, Hasegawa G, Murata T, Kimura M, Tsuda H, Ishihara T. Primary carcinoid tumor of the testis: Immunohistochemical, ultrastructural and FISH analysis with review of the literature. *Pathol Int* 2003; 53: 680-685.
- [9] Reyes A, Moran CA, Suster S, Michal M, Dominguez H. Neuroendocrine carcinomas (carcinoid tumor) of the testis: A clinicopathologic and immunohistochemical study of ten cases. *Am J Clin Pathol* 2003; 120: 182-187.
- [10] Stroosma OB, Delaere KP. Carcinoid tumours of the testis. *BJU Int* 2008; 101: 1101-1105.
- [11] Pectasides D, Glotsos J, Bountouroglou NG, Dadioti PA, Athanassiou AE. Primary carcinoid of the testis with metastases. Case report and review of the literature. *J BUON* 2002; 7: 153-6.
- [12] Neely D, Gray S. Primary carcinoid tumour of the testis. *Ulster Med J* 2011; 80: 79-81.
- [13] Sasaki M, Emura M, Kim U, Shinbo M, Shima T, Suzuki N, Tomioka S, Tanaka M, Nakatsu H, Murakami S, Suzuki Y. Primary carcinoid tumor

Primary neuroendocrine tumor of the testis

of the testis metastatic to the para-aortic lymph nodes in six years after the first operation: a case report. *Hinyokika Kiyo* 2009; 55: 233-236.

- [14] Pectasides D, Glotsos J, Bountouroglou NG, Dadioti PA, Athanassiou AE. Primary carcinoid

of the testis with metastases. Case report and review of the literature. *J BUON* 2002; 7: 153-156.