Int J Clin Exp Pathol 2014;7(4):1823-1825
www.ijcep.com /ISSN:1936-2625/IJCEP1402003

Letter to Editor

Epidermal cyst of the skin with ossification: report of two cases

Mitsuaki Ishida, Muneo Iwai, Akiko Kagotani, Nozomi Iwamoto, Hidetoshi Okabe

Department of Clinical Laboratory Medicine and Division of Diagnostic Pathology, Shiga University of Medical Science, Shiga, Japan

Received February 2, 2014; Accepted February 26, 2014; Epub March 15, 2014; Published April 1, 2014

Epidermal cyst of the skin, also referred to as epidermoid or infundibular cyst, is a common benign cystic lesion and is thought to occur from damage to the pilosebaceous units [1]. This kind of lesion is unilocular, histopathologically lined by a stratified squamous epithelium containing a granular layer, and filled with laminated and/or basket-weave keratin within the cyst, which is believed to represent follicular infundibular derivation [1]. It is not uncommon for it to be accompanied by acute inflammation, leading to the disruption of the cyst wall, with the development of foreign body reaction.

Ossification of the skin is an unusual lesion, and is classified as primary and secondary [2-4]. Primary cutaneous ossification is a lesion without a demonstrable preexisting condition. The secondary form has been most commonly reported to be associated with cutaneous tumors or inflammatory conditions [2-4]. Most cases of cutaneous ossification are secondary in nature, and the most common causes of the secondary lesions include pilomatricoma and melanocytic nevus (osteonevus of Nanta) [2-4]. Albeit extremely rare, epidermal cyst with ossification has been reported in the English language literature [2-4]. Herein, we describe two cases of epidermal cyst with ossification and discuss the histogenesis of cutaneous ossification.

Case 1

A 71-year-old Japanese male presented with a long-standing tumorous lesion of the back. Physical examination revealed a well-circumscribed subcutaneous tumor, measuring 3 x 3 cm in diameter, in his back. Total resection of the tumor was performed under a clinical diagnosis of epidermal cyst.

Histopathological study of the resected specimen revealed the presence of a well-circumscribed unilocular cyst in the dermis. The cyst was covered by squamous epithelium with a granular layer (**Figure 1A**, **1B**). The squamous cells were without atypia, and no mitotic figures were observed (**Figure 1A**, **1B**). Laminated and/or basket-weave keratin was present within the cyst (**Figure 1A**, **1B**). Mild and focal lymphocytic infiltration was noted around the cyst wall (**Figure 1B**). Above-mentioned histopathological features were typical for epidermal cyst of the skin. A peculiar finding of the present case was the presence of mature bone near the cyst on the side of the subcutis (**Figure 1A**, **1B**). The bone tissue was laminated, and osteoblasts were present around the bone tissue (**Figure 1A**, **1B**). However, osteoclasts were not observed. Moreover, no cartilaginous tissue was present.

Accordingly, an ultimate diagnosis of epidermal cyst with ossification was made.

Case 2

A 43-year-old Japanese female presented with a painful nodule in the left cheek. Physical examination revealed a relatively well-circumscribed reddish subcutaneous nodule, measuring 5 x 4 mm in diameter, in the left cheek. Under a clinical diagnosis of epidermal cyst, surgical resection of the nodule was performed.

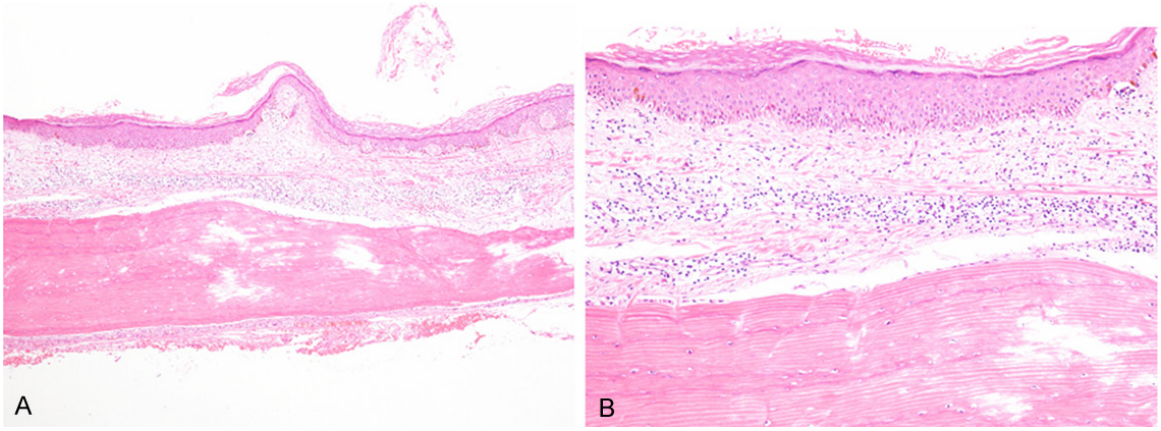

Figure 1. Histopathological features of Case 1. A. A unilocular cyst is covered by squamous epithelium containing a granular layer, and cornified material is present within the cyst. Laminated bone is observed under the cyst. HE, x 40. B. Laminated bone tissue with osteoblasts is present under the epidermal cyst. HE, x 200.

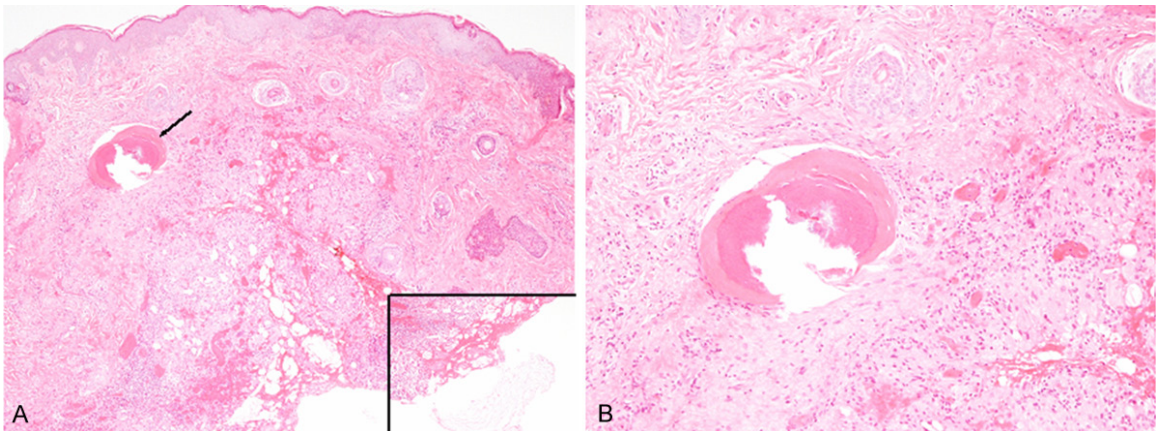

Figure 2. Histopathological features of Case 2. A. Inflammatory granulation tissue and bone (arrow) are observed in the dermis. Cornified material is also present within inflammatory granulation tissue (inset). HE, x 40. B. Laminated bone tissue is present near the inflammatory granulation tissue. HE, x 200.

Histopathological examination of the nodule demonstrated the presence of inflammatory granulation tissue, which was composed of neutrophils, macrophages, foreign body-type giant cells, and fibroblasts, in the dermis (**Figure 2A**). Although the cyst wall was not observed, cornified material was noted within the inflammatory granulation tissue (**Figure 2A**, inset). A peculiar finding was the presence of mature bone tissue near the inflammatory granulation tissue (**Figure 2A** arrow). The bone tissue was laminated and osteoblasts were present around the bone tissue (**Figure 2B**). However, neither osteoclasts nor cartilaginous tissue were observed.

Accordingly, an ultimate diagnosis of ruptured epidermal cyst with ossification was made.

Cutaneous ossification is a rare condition. Burgdorf and Nasemann analyzed the clinicopathological features of this type of lesion [3], and in their series, 35 cases of cutaneous ossification were present among 20,000 consecutive biopsy specimens (0.175%). We reviewed the clinicopathological features of the three large previously reported case series of cutaneous ossification, which included 271 cases in total as shown in **Table 1** [2-4]. The secondary form was observed in 82.7% of all cases, and the most common cause was pilomatricoma (20.7%), followed by melanocytic nevus (18.8%), inflammation or trauma (9.6%), and basal cell carcinoma (7%). Epidermal cyst is a rare association of cutaneous ossification, which accounted for only 2.6% of this type of lesion. In addition, we analyzed 7,804 consecutive speci-

Table 1. Summary of the causes of cutaneous ossification

Primary	47 (17.3%)
Secondary	224 (82.7%)
Pilomatricoma	56 (20.7%)
Melanocytic nevus	51 (18.8%)
Basal cell carcinoma	19 (7%)
Epidermal cyst	7 (2.6%)
Inflammation or trauma	26 (9.6%)

mens of skin biopsy or resection at our institute and found 14 cases of cutaneous ossification (0.18%), which corresponded to the frequency reported by Burgdorf and Nasemann [3]. In our series, all cases were of the secondary form, and no primary ossification was included. The most common cause of cutaneous ossification was pilomatricoma (6 cases), followed by osteonevus of Nanta (3 cases), epidermal cyst (2 cases), fat necrosis (2 cases), and seborrheic keratosis (1 case).

The concise mechanism underlying ossification in the skin remains unclear. Burgdorf and Nasemann proposed two mechanism by which this lesion may occur [3]: (i) dislocation of primitive mesenchymal cells that differentiate normally into osteoblasts and (ii) transformation of primitive mesenchymal cells into osteoblasts that produce bone or metaplastic transformation of other undermined dermal cells stimulated by an appropriate cellular milieu. Primary ossification of the skin may be due to the mechanism of (i), and the secondary form may be caused by the mechanism of (ii) [3]. Moreover, two types of normal ossification of the bone are well recognized. The first type is enchondral ossification, which occurs in most of the long bones of the skeleton and involves a cartilaginous template that is subsequently ossified and replaced. The second form is membranous bone formation, which is characterized by direct bone formation without the cartilaginous analogue. Primary cutaneous ossification sometimes accompanies the cartilaginous tissue, therefore, these cases are associated with enchondral ossification [3]. Secondary ossification usually contains no cartilaginous tissue [3], thus, this form of ossification is associated with membranous bone formation. The present two cases did not have any cartilaginous tissue, therefore, membranous bone formation may be associated with ossification in the present two cases of epidermal cysts.

Osteogenesis is thought to be dependent on a variety of factors including the concentration of calcium and phosphorus ions, pH, hypoxia, and osteogenic enzymes [3, 5], and an appropriate environment is required for ossification. Some factors, such as bone morphogenetic proteins (BMPs), are thought to be associated with cutaneous ossification [5]. It has been suggested that tissue injury, such as trauma or infection, and hypoxia may induce expression of BMPs on endothelial cells, resulting in osteoblastic differentiation [5]. In Case 2, the lesion contained inflammatory granulation tissue presumably due to rupture of the epidermal cyst, therefore, inflammation may be associated with bone formation. Although the cause of ossification is unclear in Case 1, possible mild ischemic change due to the long-standing presence of the cyst might be associated with development of ossification. Additional studies are needed to clarify the histogenesis of cutaneous ossification, including the molecular mechanisms involving factors such as BMPs.

Disclosure of conflict of interest

None.

Address correspondence to: Dr. Mitsuaki Ishida, Department of Clinical Laboratory Medicine and Division of Diagnostic Pathology, Shiga University of Medical Science, Tsukinowa-cho, Seta, Otsu, Shiga, 520-2192, Japan. Tel: +81-77-548-2603; Fax: +81-77-548-2407; E-mail: mitsuaki@belle.shiga-med.ac.jp

References

[1] McGavran MH, Binnington B. Keratinous cysts of the skin. Identification and differentiation of pilar cysts from epidermal cysts. Arch Dermatol 1966; 94: 499-508.

[2] Roth CI, Stowell RE, Helwig EB. Cutaneous ossification: report of 120 cases and review of the literature. Arch Pathol 1963; 76: 44-54.

[3] Burgdorf W, Nasemann T. Cutaneous osteomas: a clinical and histopathologic review. Arch Derm Res 1977; 260: 121-135.

[4] Conlin PA, Jimenez-Quintero LP, Rapini RP. Osteomas of the skin revisited: a clinicopathologic review of 74 cases. Am J Dermatopathol 2002; 24: 479-483.

[5] Kim ES, Kim KJ, Chang SE, Lee MW, Choi JH, Moon KC, Koh JK. Metaplastic ossification in a cutaneous pyogenic granuloma: a case report. J Dermatol 2004; 31: 326-329.