Int J Clin Exp Pathol 2014;7(4):1809-1813
www.ijcep.com /ISSN:1936-2625/IJCEP1402024

Letter to Editor

Adenosquamous carcinoma of the tongue: a case report with review of the literature

Mitsuaki Ishida, Muneo Iwai, Akiko Kagotani, Nozomi Iwamoto, Hidetoshi Okabe

Department of Clinical Laboratory Medicine and Division of Diagnostic Pathology, Shiga University of Medical Science, Shiga, Japan

Received February 9, 2014; Accepted March 2, 2014; Epub March 15, 2014; Published April 1, 2014

Adenosquamous carcinoma is a rare distinct clinicopathological entity characterized histopathologically by components of both squamous cell carcinoma and adenocarcinoma [1]. This type of carcinoma is described in a variety of sites, including lung, pancreas, and uterine cervix, while the head and neck region is a relatively rare origin for this type of tumor [1]. The existence of adenosquamous carcinoma of the head and neck has been disputed because some investigators had considered it as a high-grade mucoepidermoid carcinoma. Gerughty *et al*. reported a series of 10 cases of adenosquamous carcinoma of the head and neck region, and first defined this tumor in 1968 [2]. The larynx is the most frequent site of adenosquamous carcinoma in the head and neck region [1], and the tongue is a relatively rare site [2-6]. Herein, a case of adenosquamous carcinoma of the tongue is described as well as the histogenesis and clinicopathological features of this type of tumor.

A 71-year-old Japanese female presented with a painful tongue tumor. Physical examination revealed a reddish tumor with hemorrhage and surface erosion, measuring 30 x 20 mm in diameter, in the left side of the tongue. Magnetic resonance imaging showed a tumor in the left side of the tongue (**Figure 1**), and no lymph node swelling and metastatic lesions were detected. Biopsy from the tongue tumor demonstrated an invasive squamous cell carcinoma, and subsequently, chemotherapy (tegafur and nedaplatin) was performed. Then, the tumor regressed, and a total resection of the tongue tumor was performed with 10 mm margins.

Histopathological study of the resected specimen revealed infiltrative proliferation of atypical squamous cells accompanied by surface erosion and the tumor had invaded into the striated muscle layer of the tongue (**Figure 2A**). The atypical squamous cells had large round to oval nuclei containing conspicuous nucleoli and formed variable-sized nests (**Figure 2A**, **2B**). An intraepithelial lesion was noted, which was composed of proliferated atypical squamous cells within the entire layer of the squamous epithelium (**Figure 2A**, **2B**). Although no keratin pearl formation was present, individual keratinization and intercellular bridges were observed (**Figure 2B**). Approximately 60% of the tumor was composed of the above-mentioned squamous cell carcinoma component, and an adenocarcinoma component was also observed within the tumor, especially at the lower invasive portion. The adenocarcinoma component consisted of proliferated atypical cells forming fused and/or cribriform glands (**Figure 2C**). These atypical glandular cells had eccentrically-located large round to oval nuclei containing conspicuous nucleoli and some of these tumor cells had intracytoplasmic mucin. Necrotic material was present within the glands (**Figure 2C**, **2D**). A transition between squamous cell carcinoma and adenocarcinoma components was present. The squamous cell carcinoma was present at the periphery of the tumor nests, and the adenocarcinoma component was observed in the center of the tumor nests (**Figure 2C**). Mitotic figures were easily found (25/10 high-power fields). Lymphatic tumor invasion was noted, but no vascular invasion was observed.

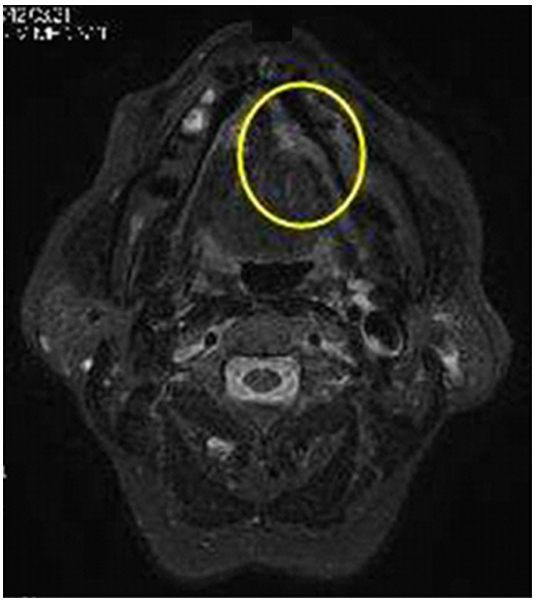

Figure 1. Magnetic resonance imaging showing a tumor in the left side of the tongue (within the circle).

Immunohistochemical studies were performed using an autostainer (Ventana) by the same method as previously reported [7-11]. **Table 1** summarizes the immunohistochemical results. Cytokeratin 7 was expressed in the adenocarcinoma component, but not in the squamous cell carcinoma component (**Figure 3A**). Cytokeratin 20 was not expressed in both components. Carcinoembryonic antigen and CA19-9 were expressed only in the adenocarcinoma component (**Figure 3B**). In contrast, p63 and p40 were expressed only in the squamous cell carcinoma component (**Figure 3C**). p53 and p16 were not expressed in both components.

According to these histopathological and immunohistochemical results, an ultimate diagnosis of adenosquamous carcinoma of the tongue was made.

The post-operative course was uneventful, and no tumor recurrence or metastasis has been observed during one month of medical follow-up.

The diagnostic criteria of adenosquamous carcinoma of the head and neck region first defined by Gerughty *et al*. are as follows: a neoplasm to be composed of an admixture or separate areas of squamous cell carcinoma and adenocarcinoma [2]. The criteria used to identify squamous cell carcinoma component are the presence of two or more of the following histopathological features: (i) intercellular bridging, (ii) keratin pearl formation, (iii) parakeratotic differentiation, (iv) individual cell keratinization, and (v) cellular arrangement showing a pavementing or mosaic pattern. The criterion used to identify an adenocarcinoma component is the demonstration of intracytoplasmic mucin [2]. However, a recent World Health Organization Classification does not require the presence of intracytoplasmic mucin for diagnosis of adenocarcinoma even in the presence of true glandular formation [1]. In the present case, no keratin pearl formation was present, but individual keratinization and intercellular bridges, which corresponded to squamous cell carcinoma, were observed. Moreover, these tumor cells were immunohistochemically positive for squamous cell markers (p63 and p40). Further, the present case had an adenocarcinoma component that was composed of the neoplastic cells containing eccentrically-located large nuclei with conspicuous nucleoli forming fused and/or cribriform glands, and some tumor cells had intracytoplasmic mucin. Immunohistochemically, these neoplastic cells lacked the expression of squamous cell markers but showed positive staining for carcinoembryonic antigen and CA19-9.

The most important differential diagnostic consideration of adenosquamous carcinoma is mucoepidermoid carcinoma. The most important clue differentiating from mucoepidermoid carcinoma is the presence of a squamous cell carcinoma *in situ* component [1]. Adenosquamous carcinomas always have a surface squamous cell carcinoma *in situ* (dysplasia) component, but is absent in mucoepidermoid carcinomas [1]. This finding reflects the histogenesis of both tumors: adenosquamous carcinoma originates from the basal cells of the surface epithelial cells that are capable of divergent differentiation to a glandular component. In contrast, mucoepidermoid carcinoma originates from the seromucinous ducts [12]. The intermediate cells are observed only in mucoepidermoid carcinomas, and keratin pearls are usually present in adenosquamous carcinomas and are limited in mucoepidermoid carcinomas [1]. Moreover, the glandular component is usually observed in the lower invasive parts of adenosquamous carcinomas, but is widely intermingled with mucoepidermoid carcinomas [1]. The present case showed squa-

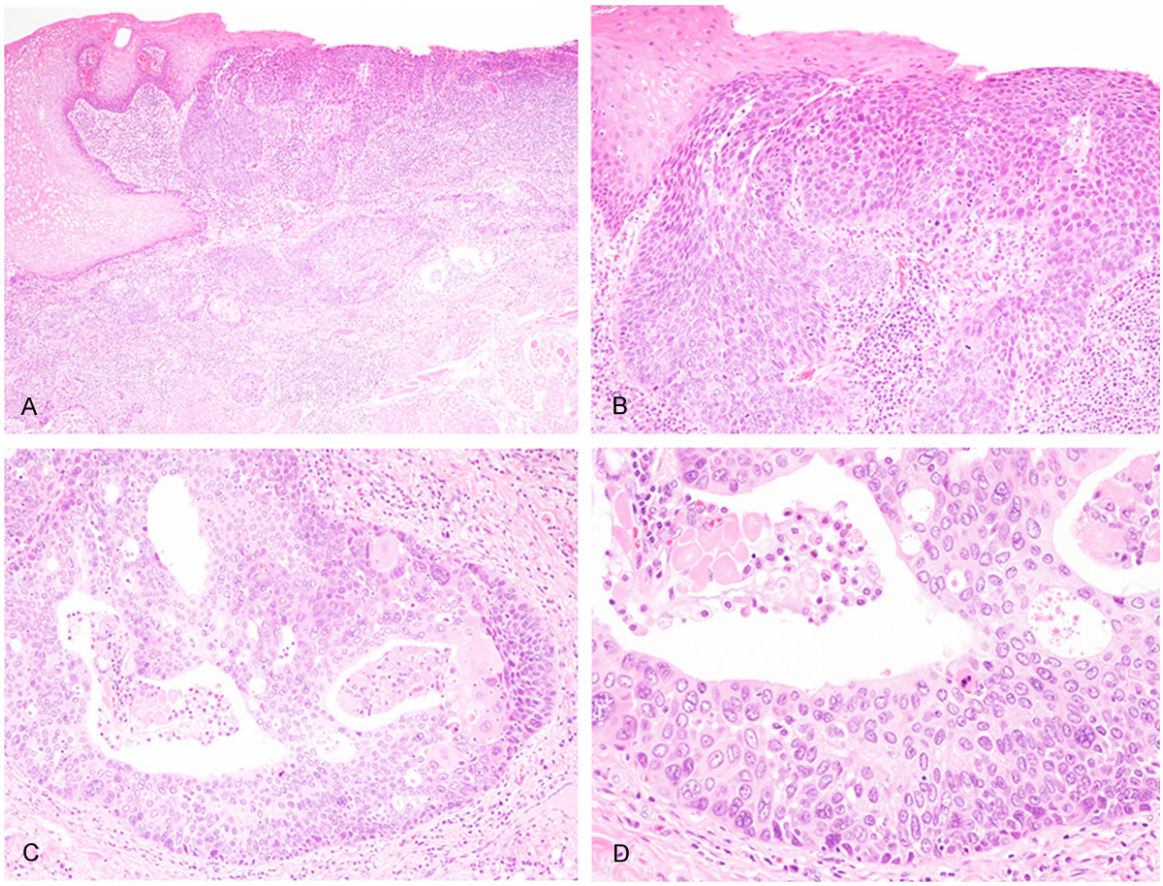

Figure 2. Histopathological features of the tongue tumor. A. Invasive neoplastic growth composes of atypical squamous cells. The tumor has invaded into the muscular layer. Intraepithelial component is also present. HE, x 40. B. Intraepithelial component is comprised of proliferation of atypical squamous cells containing large oval nuclei within the entire layer of the squamous epithelium. HE, x 200. C. The tumor nest is composed of squamous cell carcinoma component at the periphery of the nest and adenocarcinoma component in the center of the nest. HE, x 200. D. Adenocarcinoma component consists of the neoplastic cells containing eccentrically-located large nuclei with nucleoli in the cribriform gland. HE, x 400.

Table 1. Summary of immunohistochemical results of adenosquamous carcinoma of the tongue

Antibody	Squamous cell carcinoma component	Adenocarcinoma component
Cytokeratin (AE1/AE3)	+	+
Cytokeratin 7	-	+
Cytokeratin 20	-	-
Carcinoembryonic antigen	-	+
CA19-9	-	+
p63	+	-
p40	+	-
p53	-	-
p16	-	-

mous cell carcinoma *in situ*, and the adenocarcinoma component was present at the lower invasive parts. Moreover, no intermediate cells were observed. Therefore, the possibility of mucoepidermoid carcinoma was excluded, and a diagnosis of adenosquamous carcinoma was made.

Immunohistochemical characteristics of adenosquamous cell carcinoma have not been widely discussed, and only a few immunohistochemical studies have been reported [3-5]. In another case of an adenosquamous carcinoma of the tongue, Sheahan *et al*. reported that the adenocarcinoma component was positive for cytoker-

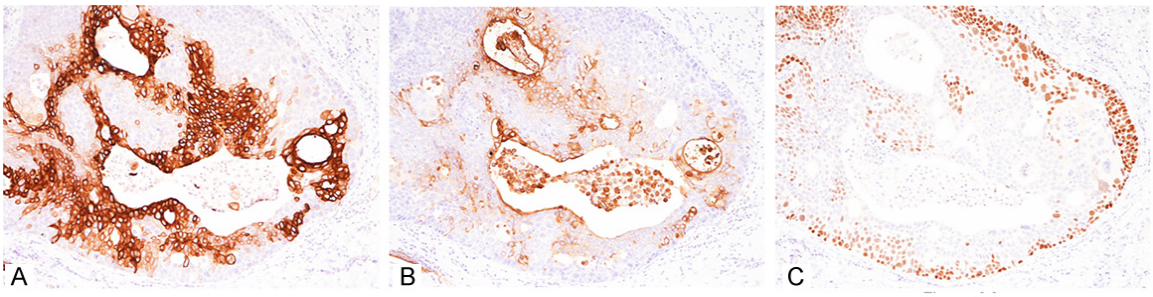

Figure 3. Immunohistochemical features of the tongue tumor. (A, B) Cytokeratin 7 (A) and carcinoembryonic antigen (B) are expressed only in the adenocarcinoma component, x 200. (C) p63 is expressed only in the squamous cell carcinoma component, x 200.

Table 2. Clinicopathological features of adenosquamous carcinoma of the tongue

Case No.	Age/Gender	Metastasis	Outcome (months)	Reference
1	54/Male	Lungs, liver, lymph nodes, bone marrow, kidneys, adrenal glands, and colon	Died of disease (9)	[2]
2	53/Male	Lung, liver, lymph nodes	Died of disease (180)	[2]
3	60/Male	Lung, liver, lymph nodes	Died of disease (12)	[2]
4	78/Female	Lymph nodes	Died of disease (4)	[3]
5	42/Male	None	Not available	[4]
6	22/Female	Recurrence in the floor of the mouth	Died of disease (12)	[5]
7	42/Male	Mediastinum	Died of disease (34)	[6]
8	65/Female	None	Not available	[6]
9	48/Male	Lymph nodes	Alive without disease (3.5)	[6]
10	87/Female	Lymph nodes	Alive with disease (9)	[6]
11	65/Female	None	Alive without disease (4)	[13]
Present Case	71/Male	None	Alive without disease (1)	

atin 7, but not in the squamous cell carcinoma component, and cytokeratin 20 was not expressed in both components [5]. Carcinoembryonic antigen was expressed in the adenocarcinoma component of two reports [3, 4], but was negative in one report [5]. Carcinoembryonic antigen and CA19-9 were expressed in the adenocarcinoma component of the present case. Moreover, a recent study demonstrated that overexpression of p53 protein was observed in 15 of 18 cases of this type of tumor [6], which was not seen in the present case. The expression of p16 was observed in three of 4 cases of adenosquamous carcinoma of the tongue, and none of the cases detected human papilloma virus in the tumor [6]. The present case had no expression of p16. Accordingly, the pathogenesis of adenosquamous carcinoma of the tongue may have no association with human papilloma virus infection.

Table 2 summarizes the clinicopathological features of 11 previously reported cases of adenosquamous carcinoma of the tongue as well as the present one [2-6, 13]. This type of carcinoma mainly affects middle-aged persons (average age 57.25 years; range 22 to 87 years). However, a case of adenosquamous carcinoma of the tongue occurring in a 22-year-old without history of significant medication and smoking has been reported [5]. Males are slightly more commonly affected (males: females 7: 5). Eight of these cases had metastatic lesions, and the most common site was the lymph node. The prognosis of this type of carcinoma is very poor; 6 patients died of disease (**Table 2**). It has been recognized that adenosquamous carcinoma of the head and neck region also shows a more aggressive clinical course than conventional squamous cell carcinoma [2, 6, 13, 14]. Masand *et al*. summarized the clinicopathological features of 93 cases of adenosquamous

carcinoma of the head and neck region [6]. The most frequent site was the larynx (48.4%), and local recurrence, and both regional and distant metastases were frequently observed (35.9%, 47.4%, and 24.7%, respectively), and 36.6% of patients died of disease [6]. These findings correspond to adenosquamous carcinoma of the tongue. Therefore, the correct diagnosis of adenosquamous carcinoma, especially the detection of the adenocarcinoma component and differentiation from mucoepidermoid carcinoma, is very important because this type of carcinoma of the head and neck region including the tongue shows a highly aggressive clinical course.

Disclosure of conflict of interest

None.

Address correspondence to: Dr. Mitsuaki Ishida, Department of Clinical Laboratory Medicine and Division of Diagnostic Pathology, Shiga University of Medical Science, Tsukinowa-cho, Seta, Otsu, Shiga, 520-2192, Japan. Tel: +81-77-548-2603; Fax: +81-77-548-2407; E-mail: mitsuaki@belle.shiga-med.ac.jp

References

[1] Cardesa A, Zidar N, Alos L. Adenosquamous carcinoma. In: Barnes L, Eveson JW, Reichart P, Sidransky D, eds. World Health Organization Classification of Tumours. Pathology and Genetics of Head and Neck Tumours. Lyon: IARC Press, 2005. pp: 130-131.

[2] Gerughty RM, Hennigar GR, Brown FM. Adenosquamous carcinoma of the nasal, oral and laryngeal cavities. A clinicopathologic survey of ten cases. Cancer 1968; 22: 1140-1155.

[3] Izumi K, Nakajima T, Maeda T, Cheng J, Saku T. Adenosquamous carcinoma of the tongue: report of a case with histochemical, immunohistochemical, and ultrastructural study and review of the literature. Oral Surg Oral Med Oral Pathol Oral Radiol Endod 1998; 85: 178-184.

[4] Abdelsayed RA, Sangueza OP, Newhouse RF, Singh BS. Adenosquamous carcinoma: a case report with immunohistochemical evaluation. Oral Surg Oral Med Oral Pathol Oral Radiol Endod 1998; 85: 173-177.

[5] Sheahan P, Fitzgibbon J, Lee G, O'Leary G. Adenosquamous carcinoma of the tongue in a 22-year-old female: report of a case with immunohistochemistry. Eur Arch Otorhinolaryngol 2003; 260: 509-512.

[6] Masand RP, El-Mofty SK, Ma XJ, Luo Y, Flanagan JJ, Lewis JS Jr. Adenosquamous carcinoma of the head and neck: relationship to human papillomavirus and review of the literature. Head and Neck Pathol 2011; 5: 108-116.

[7] Ishida M, Iwai M, Yoshida K, Kagotani A, Okabe H. Sebaceous carcinoma associated with Bowen's disease: a case report with emphasis on the pathogenesis of sebaceous carcinoma. Int J Clin Exp Pathol 2013; 6: 3029-3032.

[8] Toriyama A, Ishida M, Amano T, Nakagawa T, Kaku S, Iwai M, Yoshida K, Kagotani A, Takahashi K, Murakami T, Okabe H. Leiomyomatosis peritonealis disseminata coexisting with endometriosis within the same lesions: a case report with review of the literature. Int J Clin Exp Pathol 2013; 6: 2949-2954.

[9] Ishida M, Hodohara K, Yoshida K, Kagotani A, Iwai M, Yoshii M, Okuno K, Horinouchi A, Nakanishi R, Harada A, Yoshida T, Okabe H. Occurence of anaplastic large cell lymphoma following IgG4-related autoimmune pancreatitis and cholecystitis and diffuse large B-cell lymphoma. Int J Clin Exp Pathol 2013; 6: 2560-2568.

[10] Ishida M, Yoshida K, Kagotani A, Iwai M, Yoshii M, Okuno K, Horinouchi A, Nakanishi R, Harada A, Yoshida T, Okuno T, Hodohara K, Okabe H. Anaplastic lymphoma kinase-positive large B-cell lymphoma: A case report with emphasis on the cytological features of the pleural effusion. Int J Clin Exp Pathol 2013; 6: 2631-2635.

[11] Ishida M, Hodohara K, Yoshii M, Okuno H, Nakanishi R, Horinouchi A, Nakanishi R, Harada A, Iwai M, Yoshida K, Kagotani A, Yoshida T, Okabe H. Methotrexate-related Epstein-Barr virus-associated lymphoproliferative disorder occurring in the gingiva of a patient with rheumatoid arthritis. Int J Clin Exp Pathol 2013; 6: 2237-2241.

[12] Napier SS, Gormely JS, Newlands C, Ramsay-Baggs P. Adenosquamous carcinoma. A rare neoplasm with an aggressive course. Oral Surg Oral Med Oral Pathol Oral Radiol Endod 1995; 79: 607-611.

[13] Scully C, Porter SR, Speight PM, Eveson JW, Gale D. Adenosquamous carcinoma of the mouth: a rare variant of squamous cell carcinoma. Int J Oral Maxillofac Surg 1999; 28: 125-128.

[14] Keelawat S, Liu CZ, Roehm PC, Barnes L. Adenosquamous carcinoma of the upper aerodigestive tract: a clinicopathologic study of 12 cases and review of the literature. Am J Otolaryngol 2002; 23: 160-168.