

Case Report

Usefulness of minor salivary gland biopsy in the diagnosis of IgG4-related disease: a case report

Kentaro Doe, Kazuhisa Nozawa, Takashi Okada, Kurisu Tada, Ken Yamaji, Naoto Tamura, Yoshinari Takasaki

Department of Internal Medicine and Rheumatology, Juntendo University School of Medicine, Tokyo, Japan

Received March 7, 2014; Accepted April 10, 2014; Epub April 15, 2014; Published May 1, 2014

Abstract: Although considered essential for diagnosing IgG4-related disease (IgG4-RD), biopsy of target organs is often difficult to perform. Such was the case of a 56-year-old man admitted with general malaise and weight loss. Computed tomography revealed swelling of the submandibular gland, mild dilatation of the main pancreatic duct, renal involvement, periaortitis, and swelling of the lymph nodes in the abdominal cavity. Laboratory testing revealed elevated serum IgG4 level. These findings were suggestive of IgG4-RD; however, the patient refused consent for biopsy of the target organs for a definitive diagnosis for the invasiveness. Therefore, we tried to perform a biopsy from minor salivary gland, which revealed no sign of clinical abnormality because the biopsy is not an invasive diagnostic procedure. As a result, the biopsy revealed significant IgG4-positive plasma cell infiltration, allowing for definitive IgG4-RD diagnosis. Administration of oral prednisolone (30 mg/day) effectively improved all symptoms. These findings indicate that minor salivary gland biopsy is an effective means of IgG4-RD diagnosis in patients for whom biopsy of target organs is difficult even if there were no sign of clinical abnormality in appearance.

Keywords: IgG4-related disease, Mikulicz's disease, minor salivary gland, periaortitis, submandibular gland

Introduction

IgG4-related disease (IgG4-RD) is a recently recognized disease characterized by multi-organ involvement, elevated IgG4 concentration, and tumefaction or tissue infiltration by IgG4-positive plasma cells [1]. The clinical pattern of IgG4-RD is wide ranging; the target organs include those of the central nervous system as well as the lacrimal and salivary glands, biliary duct, pancreas, lung, kidney, thyroid, liver, gastrointestinal tract, prostate, retroperitoneum, and aorta. In 2011, the Ministry of Health, Labor and Welfare of Japan (MHLW) formed the IgG4-RD Study Group to establish the diagnostic criteria for IgG4-RD [2]. In the determination of whether a patient meets these criteria, review of the results of histopathologic examination is considered highly important. However, in some cases it is difficult to obtain tissue biopsy samples from target organs. We report our diagnosis of one such case by biopsy of minor salivary glands instead of a biopsy of the affected target organs.

Case report

A 56-year-old man was admitted to our hospital with general malaise and weight loss (12 kg loss during two months). The patient had no history of disorder, allergy, smoking, or habitual drinking. Physical examination revealed no abnormal physical findings, a body temperature of 36.8°C, blood pressure of 118/68 mmHg, and pulse of 66 bpm. In contrast, whole-body computed tomography (CT) scan for the detection of internal organ involvement revealed swelling of the submandibular gland, mild dilatation of the main pancreatic duct, renal involvement, arterial wall thickening, and swelling of the lymph nodes around the pancreas. Review of the imaging results also revealed renal lesions appearing as multiple patchy lesions without contrast enhancement (**Figure 1A**) as well as arterial wall thickening with homogeneous enhancement, suggesting the existence of periaortitis (**Figure 1A**, arrow).

Laboratory testing revealed a leukocyte level of 9400/ μ L, a neutrophil level of 6401/ μ L, a lym-

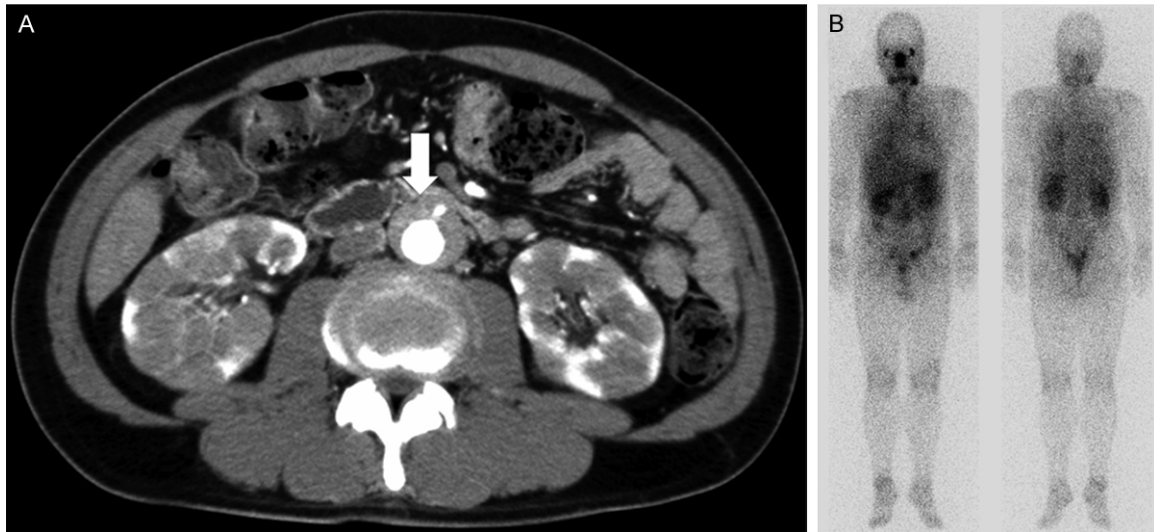

Figure 1. Detection of (A) renal lesions and periaortitis by computed tomography (CT) and (B) gallium-67 (Ga) accumulation on the submandibular gland, bilateral renal, and around the aorta by Ga scintigraphy.

phocyte level of 2058/ μ L, an eosinophil level of 460/ μ L, a hemoglobin level of 13.6 g/dL, a platelet count of 27.4×10^4 / μ L, a C-reactive protein level of 0.7 mg/dL (normal, <0.2 mg/dL), a total protein level of 9.2 g/dL (normal, 6.5-8.5 g/dL), an albumin level of 3.4 g/dL (normal, 4.0-5.2 g/dL), an aspartate aminotransferase (AST) level of 26 IU/L (normal, 5-37 IU/L), an alanine aminotransferase (ALT) level of 36 IU/L (normal, 6-43 IU/L), a lactate dehydrogenase (LDH) level of 174 IU/L (normal, 119-221 IU/L), a gamma glutamyl transpeptidase (γ -GTP) level of 21 IU/L (normal, 0-75 IU/L), a total bilirubin level of 0.37 mg/dL (normal, 0.4-1.2 mg/dL), a direct bilirubin level of <0.05 mg/dL (normal, 0.1-0.3 mg/dL), an Amy level of 57 IU/L (normal, 43-124 IU/L), a Lip level of 12 IU/L (normal, 14-56 IU/L), a carbohydrate antigen 19-9 level of 23 U/mL (normal, 0-37 U/mL), a Span-1 antigen level of 11 U/mL (normal, 0-30 U/mL), a soluble interleukin-2 receptor level of 1260 U/mL (normal, 145-519 U/mL), a KL-6 level of 288 U/mL (normal, 0-499 U/mL), a CH50 level of 50.9 IU/mL (normal, 25-54 IU/mL), a C3 level of 113 mg/dL (normal, 69-128 mg/dL), a C4 level of 27 mg/dL (normal, 14-36 mg/dL), a C1q level of 1.5 μ g/mL (normal, 0-3 μ g/mL), an IgG level of 3728 mg/dL (normal, 870-1700 mg/dL), an IgG4 level >1500 mg/dL (normal, 4.8-105 mg/dL), and an IgG4/IgG percentage of 40.2%.

Antibody testing revealed the patient to be weakly positive for antinuclear antibody (20 \times ;

speckled pattern) but negative for other auto-antibodies such as anti-DNA, anti-SS-A, anti-U1RNP, anti-Scl-70, anti-Jo-1, anti-CCP antibody, MPO-ANCA, and PR3-ANCA. Paraproteinemia and monoclonal gammopathy was not detected by serum protein electrophoresis. Urinalysis revealed a slightly elevated urinary NAG level (8.0 IU/L) and urinary β 2MG level (353 μ g/L) but did not reveal the presence of glycosuria or proteinuria. Gallium-67 (Ga) scintigraphy for differential diagnosis revealed gallium accumulation on the submandibular gland, the bilateral renal, and around the aorta, a finding that accorded with the CT findings. Endoscopic ultrasonography revealed diffuse pancreatic hypoechoic areas, bile duct wall thickening, and dilatation of the main pancreatic duct in the absence of tumor lesions. These findings accorded with endoscopic ultrasonography findings previously reported to be indicative of autoimmune pancreatitis [3].

Based on the finding of elevated serum IgG4 level and review of the imaging results, we suspected IgG4-RD. Although we had initially planned to perform biopsy of the affected organs, as revealed by inspection of the imaging results, the patient would not consent to biopsy due to concerns regarding its invasiveness and the need to undergo general anesthesia to obtain histological samples. However, he consented to biopsy of the minor salivary glands, which can be performed relatively non-invasively, allowing us to test whether biopsy of

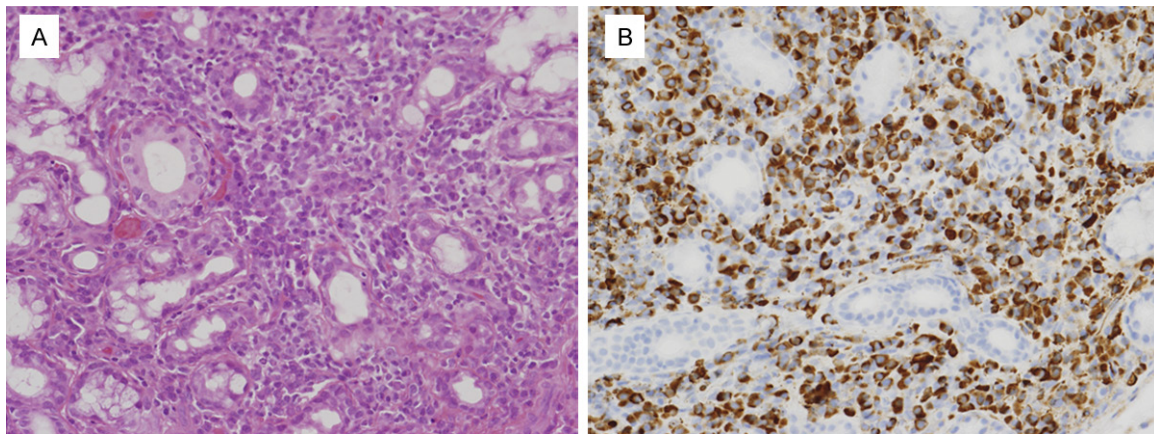


Figure 2. Detection of (A) infiltration of lymphocytes and plasma cells in the minor salivary glands by hematoxylin and eosin staining and (B) a number of IgG4-positive plasma cells per high-power field >100 and a percentage of IgG4-positive to IgG-positive plasma cells >40% by IgG4 immunostaining (original magnification $\times 40$).

the minor salivary glands could be an alternative method of diagnosing IgG4-RD in patients for whom biopsy of the affected organs is difficult.

Hematoxylin and eosin (HE) staining revealed infiltration of lymphocytes and plasma cells (**Figure 2**, left panel) in the minor salivary glands, while immunohistochemical staining revealed the number of IgG4-positive plasma cells per high-power field (HPF) to be over 100 and the percentage of IgG4-positive to IgG-positive plasma cells (IgG4+/IgG+) to be over 40% (**Figure 2**, right panel). These findings allowed us to achieve a definitive diagnosis according to the 2011 MHLW IgG4-RD Study Group diagnostic criteria for IgG4-RD [2]. After initiation of treatment by administration of 30 mg/day (0.5 mg/kg) of prednisolone, the patient's symptoms dramatically improved before disappearing completely. After 1 year follow up, serum IgG4 level decreased from over 1500 mg/dl to 150 mg/dl, and dosage of prednisolone could be changed to 10 mg/day without recurrence. Swelling of the submandibular gland, mild dilatation of the main pancreatic duct, renal involvement, periaortitis, and swelling of the lymph nodes in the abdominal cavity had disappeared. Our results indicated that biopsy of the minor salivary glands could indeed be used as an alternative method of diagnosis. The study participant provided informed consent, and the study design was approved by the appropriate ethics review boards.

Discussion

IgG4-RD is a newly emerging disease entity of unknown etiology characterized by multiorgan involvement, elevated IgG4 concentration, and tumefaction or tissue infiltration by IgG4-positive plasma cells [1]. The clinical pattern of IgG4-RD is wide-ranging, with target organs including those of the central nervous system as well as the lacrimal and salivary glands, biliary duct, pancreas, lungs, kidneys, thyroid, liver, gastrointestinal tract, prostate, retroperitoneum, and aorta. As such, diagnosis of IgG4-RD may encompass various diseases, including Mikulicz's disease, autoimmune pancreatitis, hypophysitis, Riedel thyroiditis, interstitial pneumonitis, interstitial nephritis, prostatitis, lymphadenopathy, retroperitoneal fibrosis, inflammatory aortic aneurysm, and inflammatory pseudotumor.

In cases of suspected IgG4-RD, histopathologic examination is considered highly important in the exclusion of malignancies [4] and other diseases [5] and mandatory in the establishment of definitive diagnosis of IgG4-RD [2]. However, it often is difficult to perform biopsy of several organs located in the peritoneal cavity, such as the pancreas, retroperitoneum, and periaorta. Moreover, IgG4-RD mainly affects middle-aged to elderly men who often have complications that prevent performance of biopsy. Minor salivary gland biopsy, a minimally invasive procedure that does not require general anesthesia, was first reported as a method of diagnosing Sjögren syndrome by Chisholm and Mason in

1968 [6]. Since then, minor salivary gland biopsy has also been reported a means of diagnosing other diseases, including amyloidosis [7], sarcoidosis [8], and lymphoma [9].

Although IgG4-RD is distinct from Sjogren syndrome, several researchers have indicated that minor salivary gland biopsy may be useful in IgG4-RD diagnosis. Baer et al. reported the usefulness of minor salivary gland biopsy in the diagnosis of Mikulicz's disease [10]. This is a first case report, which can be diagnosed as IgG4-RD by minor salivary gland biopsy. Moreover, we previously have reported the similar case of IgG4-RD with retroperitoneal fibrosis [11]. In the case, the number of IgG4-positive plasma cells per HPF did not exceed 10 and the percentage of IgG4+/IgG+ did not exceed 40% in the minor salivary gland specimens. Thus, our previous report did not fulfill the histopathologic criteria for IgG4-RD diagnosis, allowing us to diagnosis the patient with only "possible" IgG4-RD [2, 11]. In contrast to our previous case, the number of IgG4-positive plasma cells per HPF exceeded 100 and the percentage of IgG4+/IgG+ exceeded 40% in the minor salivary gland specimens of the patient; hence, we were able to diagnosis him with "definitive" IgG4-RD in the present case. Moreover, we investigated other IgG4-RD patients who have been treated in our hospital, and confirmed that 57.1% (4/7) of the patients with IgG4-RD revealed the positive finding in minor salivary gland biopsy (data not shown). Although analysis of a larger number of patients is required for confirmation of our findings, we strongly suggest that minor salivary gland biopsy is useful for IgG4-RD diagnosis in patients for whom target organ biopsy is difficult to perform.

In conclusion, although histopathologic examination of target organs is currently considered essential for the definitive diagnosis of IgG4-RD, target organ biopsy is often difficult to perform unless the affected organs are located in a superficial region. Based on our findings regarding its effectiveness as reported here, minor salivary gland biopsy is a useful procedure in IgG4-RD diagnosis in a certain population of patients for whom we propose its use.

Disclosure of conflict of interest

None.

Address correspondence to: Dr. Kentaro Doe, Department of Internal Medicine and Rheumatology, Juntendo University School of Medicine, 2-1-1 Hongo, Bunkyo-ku, Tokyo 113-8421, Japan. Tel: +81-3-5802-1067; Fax: +81-3-5800-4893; E-mail: kdoe@juntendo.ac.jp

References

- [1] Umehara H, Okazaki K, Masaki Y, Kawano M, Yamamoto M, Saeki T, Matsui S, Sumida T, Mimori T, Tanaka Y, Tsubota K, Yoshino T, Kawa S, Suzuki R, Takegami T, Tomosugi N, Kurose N, Ishigaki Y, Azumi A, Kojima M, Nakamura S, Inoue D; Research Program for Intractable Disease by Ministry of Health, Labor and Welfare (MHLW) Japan G4 team. A novel clinical entity, IgG4-related disease (IgG4RD): general concept and details. *Mod Rheumatol* 2012; 22: 1-14.
- [2] Umehara H, Okazaki K, Masaki Y, Kawano M, Yamamoto M, Saeki T, Matsui S, Yoshino T, Nakamura S, Kawa S, Hamano H, Kamisawa T, Shimosegawa T, Shimatsu A, Nakamura S, Ito T, Notohara K, Sumida T, Tanaka Y, Mimori T, Chiba T, Mishima M, Hibi T, Tsubouchi H, Inui K and Ohara H. Comprehensive diagnostic criteria for IgG4-related disease (IgG4-RD), 2011. *Mod Rheumatol* 2012; 22: 21-30.
- [3] Hoki N, Mizuno N, Sawaki A, Tajika M, Takayama R, Shimizu Y, Bhatia V and Yamao K. Diagnosis of autoimmune pancreatitis using endoscopic ultrasonography. *J Gastroenterol* 2009; 44: 154-159.
- [4] Kamisawa T, Chen PY, Tu Y, Nakajima H, Egawa N, Tsuruta K, Okamoto A and Hishima T. Pancreatic cancer with a high serum IgG4 concentration. *World J Gastroenterol* 2006; 12: 6225-6228.
- [5] Strehl JD, Hartmann A and Agaimy A. Numerous IgG4-positive plasma cells are ubiquitous in diverse localised non-specific chronic inflammatory conditions and need to be distinguished from IgG4-related systemic disorders. *J Clin Pathol* 2011; 64: 237-243.
- [6] Chisholm DM and Mason DK. Labial salivary gland biopsy in Sjögren's disease. *J Clin Pathol* 1968; 21: 656-660.
- [7] Hachulla E, Janin A, Flipo RM, Saïle R, Facon T, Bataille D, Vanhille P, Hatron PY, Devulder B and Duquesnoy B. Labial salivary gland biopsy is a reliable test for the diagnosis of primary and secondary amyloidosis. A prospective clinical and immunohistologic study in 59 patients. *Arthritis Rheum* 1993; 36: 691-697.
- [8] Fatahzadeh M and Rinaggio J. Diagnosis of systemic sarcoidosis prompted by orofacial manifestations: a review of the literature. *J Am Dent Assoc* 2006; 137: 54-60.

Minor salivary gland biopsy in IgG4-RD diagnosis

- [9] Berrebi D, Lescoeur B, Faye A, Faure C, Vilmer E and Peuchmaur M. MALT lymphoma of labial minor salivary gland in an immunocompetent child with a gastric *Helicobacter pylori* infection. *J Pediatr* 1998; 133: 290-292.
- [10] Baer AN, Gourin CG, Westra WH, Cox DP, Greenspan JS, Daniels TE; Sjögren's International Collaborative Alliance. Rare diagnosis of IgG4-related systemic disease by lip biopsy in an international Sjögren syndrome registry. *Oral Surg Oral Med Oral Pathol Oral Radiol* 2013; 115: e34-e39.
- [11] Doe K, Hohtatsu K, Lee S, Nozawa K, Amano H, Tamura N and Takasaki Y. Case report: usefulness of lip biopsy for the diagnosis of IgG4-related diseases with retroperitoneal fibrosis: report of a case. *Nihon Naika Gakkai Zasshi* 2011; 100: 1645-1647.